

Speckled variance optical coherence tomography for the assessment of nail involvement in acrodermatitis continua of Hallopeau: A case study

**Andrea Conti, Silvana Ciardo,
Victor Desmond Mandel, Laura Bigi
and Giovanni Pellacani**

Abstract

Noninvasive techniques for nail imaging would be useful for confirming diagnosis and monitoring treatment response at the microscopic level in patients with nail psoriasis. However, the use of ultrasound and high-resolution magnetic resonance imaging in nail evaluation is limited. Optical coherence tomography (OCT) produces high-resolution images of transversal tissue sections and represents an optimal approach to the study of the nail. This study used a multibeam OCT instrument to produce speckled variance OCT (SV-OCT) blood-flow images, which were used to measure the degree of change over successive scans. Nail changes, inflammation and response to therapy were evaluated in a 75-year-old female patient with psoriasis who had severe acrodermatitis continua of Hallopeau of the hands, treated for 4 weeks with 40 mg adalimumab (administered subcutaneously every other week) and 25 mg prednisone (administered orally, daily). SV-OCT provided a detailed assessment of the nail structures in relation to inflammation of psoriatic tissues. Restoration of the normal anatomy of the nail apparatus was apparent following adalimumab treatment; SV-OCT evaluation correlated with clinical appearance. SV-OCT may have a diagnostic role and provide an objective tool to assess clinical and subclinical inflammation in nail psoriasis.

Keywords

Acrodermatitis continua of Hallopeau, nail disease, psoriasis, speckled variance optical coherence tomography, therapy

Department of Dermatology, University of Modena and Reggio Emilia, Modena, Italy

Corresponding author:

Andrea Conti, Department of Dermatology, University of Modena and Reggio Emilia, 71 Via del Pozzo, Modena 41122, Italy.

Email: a.conti.dermo@gmail.com



Introduction

Nail involvement represents a clinically important aspect of psoriasis and psoriatic arthritis. Lesion severity is evaluated using the Nail Psoriasis Severity Index (NAPSI) or the modified NAPSI score.^{1,2} Several studies have reported the use of ultrasonography and high-resolution magnetic resonance imaging (MRI) in nail evaluation, but the use of these techniques is difficult owing to image resolution/quality and accessibility/cost, respectively.³⁻⁵ However, the use of noninvasive techniques for nail imaging could help to achieve a correct diagnosis and to monitor the response to therapy at the microscopic level. Optical coherence tomography (OCT) produces high-resolution images of transversal tissue sections at a depth of 2 mm, and represents an optimal approach to the study of the nail.⁶⁻⁹

A multibeam OCT instrument that uses swept-source OCT with a central wavelength of 1305 nm is commercially available. It scans an area of skin measuring 6 mm × 6 mm to a depth of up to 2 mm, with a lateral resolution better than 7.5 μm and an axial resolution better than 5 μm.¹⁰ For the detection of blood flow, the instrument is made to repeatedly scan the same area of skin. Each scan is processed in the normal way to produce a cross-sectional image of the skin.² These images have pixel sizes of ~4.5 μm in each dimension.¹¹ A proprietary algorithm is used to compare successive scans, producing a blood-flow image that represents the degree of change that occurred (speckled variance). The blood-flow image is presented as an overlay drawn in red over the standard structural image (grey scale).

This case study reports the preliminary experience with speckled variance OCT (SV-OCT) for the assessment of nail changes, inflammation and response to therapy in a 75-year-old female patient with psoriasis who had severe acrodermatitis continua of Hallopeau of the hands.

Case study

A 75-year-old female patient, who had moderate-to-severe psoriasis and severe acrodermatitis continua of Hallopeau of the hands since 2011, came to the attention of the Department of Dermatology at the University of Modena and Reggio Emilia, Modena, Italy, after a rapid worsening of her symptoms.

The patient was treated sequentially with standard regimens of methotrexate, acitretin, cyclosporine A, etanercept and infliximab; however, there were no significant improvements in her condition. In 2014, the patient was started on a new treatment with adalimumab (starting dose of 80 mg, administered subcutaneously, followed by 40 mg after 1 week, then 40 mg every other week) in combination with prednisone (25 mg, administered orally, daily).

Since the severe nail involvement was the main problem for the patient, ongoing evaluations were concentrated on this aspect of her condition.

A target nail (fourth finger of the patient's right hand) was scanned using the multibeam OCT instrument. Evaluations were performed at baseline and after 4 weeks' treatment with 40 mg adalimumab (administered subcutaneously every other week) and 25 mg prednisone (administered orally, daily).

Before treatment commenced, the patient's fingers showed areas of erythema and scaling, and severe onychodystrophy with painful pustules involving the nail bed (Figure 1a). SV-OCT showed a marked thickening and irregularity of the superficial and ventral layer with waving of the superficial nail plate; some hyper-reflective spots were present. Image analysis showed diffuse red areas in the nail bed (Figure 2a; the colour version of this image is available online).

After 4 weeks' treatment, complete clearance of pustules with initial nail regrowth was observed (Figure 1b). In this phase of the disease, SV-OCT showed a regular

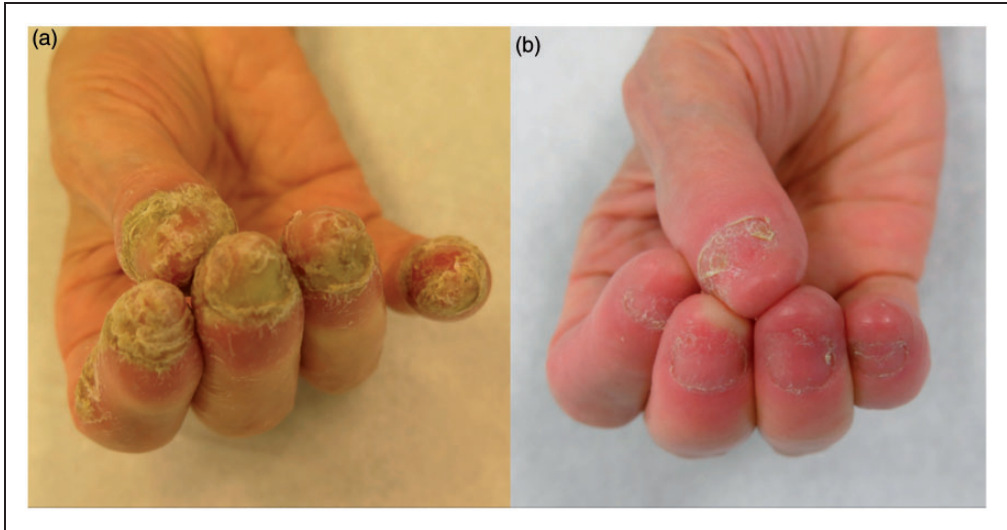


Figure 1. Representative clinical images from a 75-year-old female patient with psoriasis who had severe acrodermatitis continua of Hallopeau of the hands. (a) Clinical appearance of the fingers before treatment showing erythema, scaling, onychodystrophy and pustules involving the nail bed. (b) Clinical appearance after 4 weeks' treatment with 40 mg adalimumab (administered subcutaneously every other week) and 25 mg prednisone (administered orally, daily) showing complete clearance of the pustules with nail regrowth. The colour versions of these images are available at: <http://imr.sagepub.com>.

aspect of the superficial and the deeper layers of the nail plate with a marked reduction of the blood-flow signal (red areas, in the colour version of this image available online) and an increase in reflectance of the nail bed (Figure 2b).

Discussion

Few data are available on the use of OCT in assessing nail disease.^{6,7} Some studies have demonstrated the potential use of OCT compared with high-resolution ultrasound for the evaluation of nails in healthy subjects and in patients with psoriatic arthritis; they showed the capability of OCT to detect subclinical signs of nail involvement in patients with psoriasis.^{8,9} It is important to diagnose psoriatic arthritis early, to allow therapeutic interventions to be started quickly, thus helping to prevent permanent disability. In the present case, the following

signs were observed prior to treatment: a thickening, irregularity and waving of the nail plate with some hyper-reflective spots; alteration of the nail bed with decreased reflectivity and increased vascularization; alteration of the proximal area, corresponding to the nail matrix, with thickening of the epidermal layer and increased blood flow. Detection of blood flow by means of SV-OCT allowed a more detailed assessment of the nail structures in relation to the presence of inflammation of the tissues in psoriatic disease. This case study showed that red areas were clearly present in the active phase of the disease and considerably reduced after treatment, with the restoration of a normal anatomy of the nail apparatus. These evaluations seem to correlate with clinical aspects of the disease. Findings observed in this case indicate that SV-OCT could have a diagnostic role, and could serve as an objective tool to assess clinical and

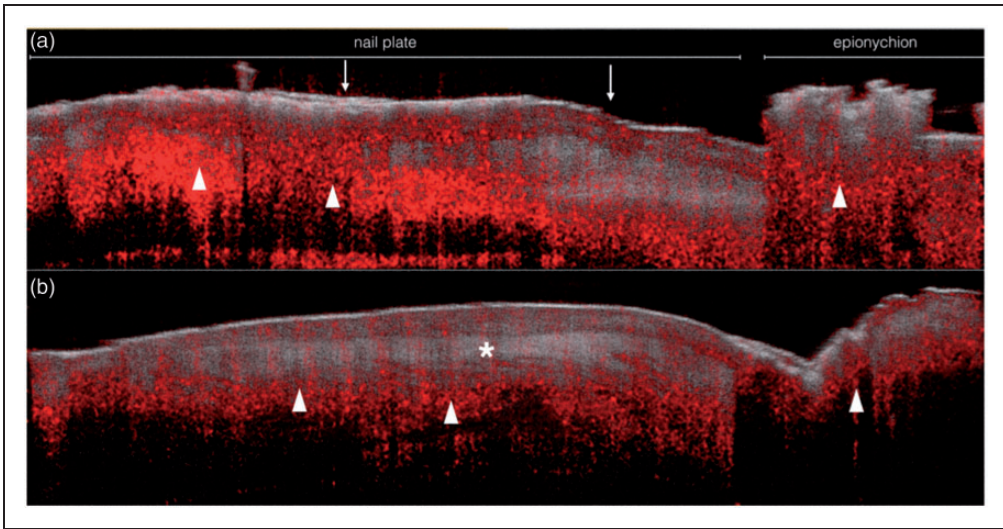


Figure 2. Representative speckled variance optical coherence tomography (SV-OCT) images from a 75-year-old female patient with severe acrodermatitis continua of Hallopeau of the hands. (a) SV-OCT image prior to treatment showed thickening and irregularity of the superficial and ventral layer with waving of the superficial nail plate (↓). Image analysis showed diffuse red areas in the nail bed (large arrowheads). (b) SV-OCT image after 4 weeks' treatment with 40 mg adalimumab (administered subcutaneously every other week) and 25 mg prednisone (administered orally, daily) showing a regular aspect of the superficial and the deeper layers of the nail plate (*) with marked reduction of the blood flow signal (red areas) and an increase in reflectance of the nail bed (large arrowheads). The colour versions of these images are available at: <http://imr.sagepub.com>.

subclinical inflammation in nail psoriasis. Therefore, a study involving case series and patients with subclinical disease is warranted.

In conclusion, this preliminary clinical experience showed that SV-OCT has the potential to be used in the assessment of nail involvement in psoriatic disease, and could be useful as an objective measure to assess response to therapy.

Declaration of conflicting interest

The authors declare that there are no conflicts of interest.

Funding

This work received funding from the European Union Seventh Framework Programme for

research, technological development and demonstration under grant agreement 'ADVANCE' no. 621015.

References

1. Rich P and Scher RK. Nail psoriasis severity index: a useful tool for evaluation of nail psoriasis. *J Am Acad Dermatol* 2003; 49: 206–212.
2. Cassell SE, Bieber JD, Rich P, et al. The modified Nail Psoriasis Severity Index: validation of an instrument to assess psoriatic nail involvement in patients with psoriatic arthritis. *J Rheumatol* 2007; 34: 123–129.
3. Scarpa R, Soscia E, Peluso R, et al. Nail and distal interphalangeal joint in psoriatic arthritis. *J Rheumatol* 2006; 33: 1315–1319.
4. Gutierrez M, Wortsman X, Filippucci E, et al. High-frequency sonography in the evaluation of psoriasis: nail and skin involvement. *J Ultrasound Med* 2009; 28: 1569–1574.

5. Aydin SZ, Castillo-Gallego C, Ash ZR, et al. Ultrasonographic assessment of nail in psoriatic disease shows a link between onychopathy and distal interphalangeal joint extensor tendon enthesopathy. *Dermatology* 2012; 225: 231–235.
6. Mogensen M, Thomsen JB, Skovgaard LT, et al. Nail thickness measurements using optical coherence tomography and 20-MHz ultrasonography. *Br J Dermatol* 2007; 157: 894–900.
7. Sattler E, Kaestle R, Rothmund G, et al. Confocal laser scanning microscopy, optical coherence tomography and transonychia water loss for *in vivo* investigation of nails. *Br J Dermatol* 2012; 166: 740–746.
8. Aydin SZ, Ash ZR, Del Galdo F, et al. Optical coherence tomography: a new tool to assess nail disease in psoriasis? *Dermatology* 2011; 222: 311–313.
9. Aydin SZ, Castillo-Gallego C, Ash ZR, et al. Potential use of optical coherence tomography and high-frequency ultrasound for the assessment of nail disease in psoriasis and psoriatic arthritis. *Dermatology* 2013; 227: 45–51.
10. Holmes J, Hattersley S, Stone N, et al. Multi-channel Fourier domain OCT system with superior lateral resolution for biomedical applications. *Biomedical Optics (BiOS)* 2008, 68470O-68470O-9.
11. Murtaza A and Renuka P. Signal processing overview of optical coherence tomography systems for medical imaging. SPRABB9; June 2010: Texas Instruments Incorporated.