

Direct exchange endoprosthetic reconstruction with tumour prosthesis for periprosthetic knee infection associated with segmental bone defects

Manjunath Ramappa · Ian McMurtry · Andrew Port

Received: 23 May 2009 / Accepted: 12 November 2009 / Published online: 12 January 2010
© Springer-Verlag 2009

Abstract Revision knee arthroplasty for infection poses a treatment challenge. The presence of massive osteolysis limits the treatment options in this cohort. Controversy exists in the management of these patients. Direct exchange arthroplasty has provided good results in the presence of infection, but whether this is appropriate in the presence of massive bone defects associated with the infection is undetermined. We present our experience in revision knee arthroplasty for infection associated with massive bone defects. The aim of the study is to present the preliminary results of a direct exchange endoprosthetic reconstruction with tumour prosthesis for periprosthetic infection associated with segmental bone defects. This is a retrospective study of prospectively collected data, involving six patients with periprosthetic infection and massive bone defects treated by direct exchange tumour prostheses between 2003 and 2007 (four distal femoral replacements and two total femoral replacements). The mean age and follow-up were 74.2 (± 5.2) years and 32.5 (± 8.2) months respectively. Each patient had an infected revised knee arthroplasty at the time of referral to our institution. *Staphylococcus aureus* was the most common causal organism. The mean duration of antibiotics was 6 weeks intravenous therapy followed by 3.5 months oral. The recurrences of infection, pain or immobility were outcome criteria considered failures. Our success rate was 80%. Salvage of infected revised knee arthroplasty by direct exchange endoprosthetic

reconstruction has provided an effective means of pain relief, joint stability and improved mobility in our cohort. It reduces morbidity through earlier mobilisation and avoids a second major operation.

Keywords Arthroplasty · Knee · Replacement · Limb salvage · Prosthesis-related infections · Osteolysis

Introduction

A periprosthetic infection with segmental bone defect is a surgical disaster. Treatment is often demanding, involves multiple complex operations and is associated with significant morbidity and health care costs [2, 16]. The preferred management of large bone defects in this scenario has not been established [7]. The severity of bone loss largely influences implant selection, and the problem is often associated with poor surrounding soft tissues [11].

The management of periprosthetic knee infection may be divided broadly into the use of component-retention or component-exchange procedures [12]. Component retention procedures include either arthroscopic [6] or open [5] debridement with antibiotic therapy. They have poor results in eradication of chronic infections [21]. Component-exchange procedures, which form the mainstay of treatment of chronic infections, include either a one-stage direct exchange or a two-stage delayed reconstruction. Additional treatment includes meticulous debridement and use of antibiotic impregnated bone cement. Indeed, there is no single investigation available at the time of re-implantation which can accurately predict the likelihood of a successful outcome [12]. However, the concept of a single-stage procedure with one episode of hospitalisation gained popularity in the 1990s [20].

M. Ramappa (✉)
Teaching and Research Fellow, Department of Orthopaedics,
James Cook University Hospital, Middlesbrough TS4 3BW, UK
e-mail: manjuramappa@doctors.org.uk

I. McMurtry · A. Port
Consultant Orthopaedic Surgeon, Department of Orthopaedics,
James Cook University Hospital, Middlesbrough, UK

There is now long-term follow-up evidence in favour of a direct exchange arthroplasty for infection. The results for direct exchange are comparable with a two-stage strategy [1, 2, 4, 8, 12, 17, 19, 21]. These reports suggest that direct exchange arthroplasty is likely to decrease the overall health care costs, reduce morbidity and technical difficulty associated with multiple surgical procedures [2, 4, 12]. Several factors which favour patient selection for direct exchange have been advocated also. These include good soft tissues with antibiotic sensitive organisms, especially gram-positive cocci, and minimal osteolysis. However, these selection criteria are not always applicable. Infected arthroplasty is often associated with osteolysis [12], especially so in a revision setting. Bone loss occurs due to a combination of infection, disuse and surgery itself. The greater the number of revision surgeries, the more bone is lost. A temporary spacer, as used in a two-stage procedure, can lead to an unstable joint especially in the presence of extensive osteolysis. Other issues e.g. age, poor soft tissues, comorbidities, antibiotic-resistant microorganisms can complicate this already difficult treatment group as well. Recent studies have indicated advantages with either of these methods, but there are no definite guidelines as to which method to be followed [1, 2, 4, 8, 12, 17, 21]. Additionally, there are no previous published results or guidelines for the salvage of infected revision arthroplasties associated with massive osteolysis.

The aim of this study was to present the preliminary results of direct exchange endoprosthetic reconstruction using a tumour prosthesis for periprosthetic infections associated with segmental bone defects.

Materials and methods

Between March 2003 and December 2007, six direct exchange arthroplasty procedures (four distal femoral replacements and two total femoral replacements) with tumour prostheses were performed for chronic periprosthetic knee infections associated with severe bone loss (Figs. 1, 2, 3, 4, 5, 6) [3]. This was a retrospective review of prospectively collected data. Chronic infection was defined as persistent infection greater than 1 month from the index operation. Four patients (patients A, D, E and F) had infected knee prostheses (and underwent distal femoral replacements) and two patients (patients B and C) had combined infected hip and knee prostheses (Table 1). These two patients underwent total femoral replacements. All patients were managed in collaboration with the infectious diseases department at our institution. The cohort had one male and five female patients. At clinical presentation, all patients were wheelchair-bound secondary to pain and instability. Radiographs revealed a failing

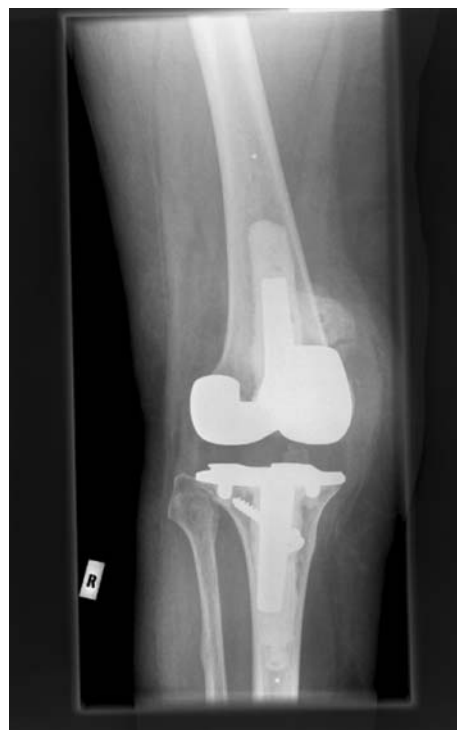

Fig. 1 Preoperatively infected right revision knee replacement with osteolysis

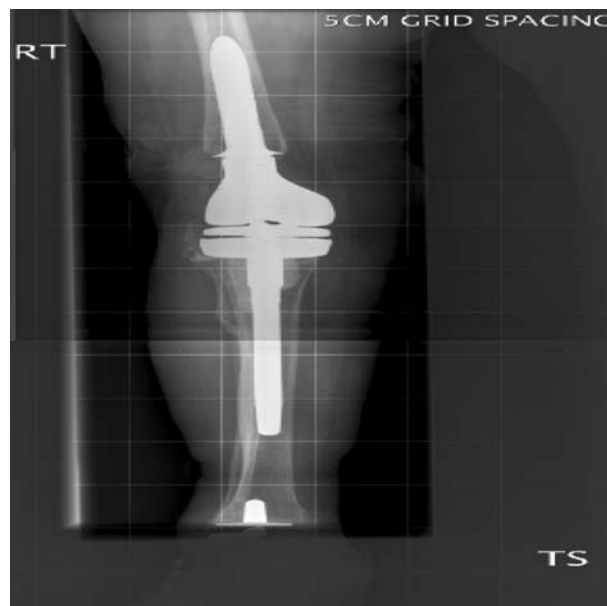


Fig. 2 Postoperative direct exchange right distal femoral replacement for patient in Fig. 1

prosthesis with extensive osteolysis. Preoperative C reactive protein (CRP), erythrocyte sedimentation rate (ESR) and peripheral leucocytes count were measured for all patients. Preoperative aspiration and intraoperative tissue samples were sent for microbiology. One patient had a

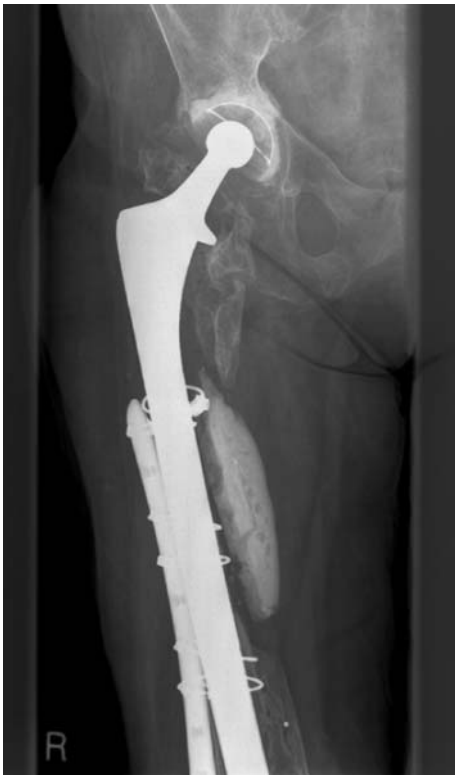

Fig. 3 Preoperatively infected metalwork right femur with osteolysis, showing proximal femur

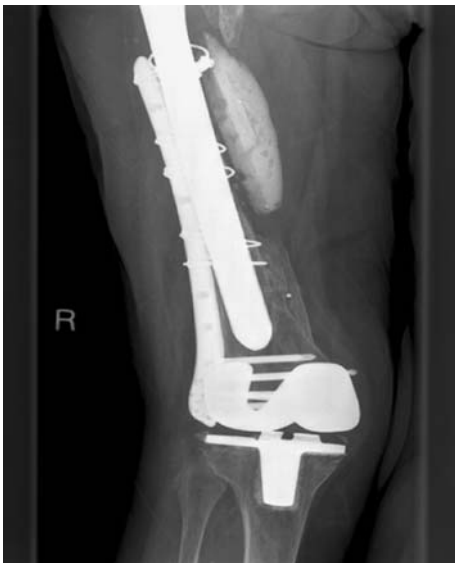

Fig. 4 Preoperatively infected metalwork right femur with osteolysis showing distal femur for the patient in Fig. 3

chronic draining sinus in the knee (patient C). Two patients (patients B and C) had previously had extensive surgeries in the whole femur, which again failed secondary to sepsis. Subsequently, these two patients were treated with a total femoral replacement.

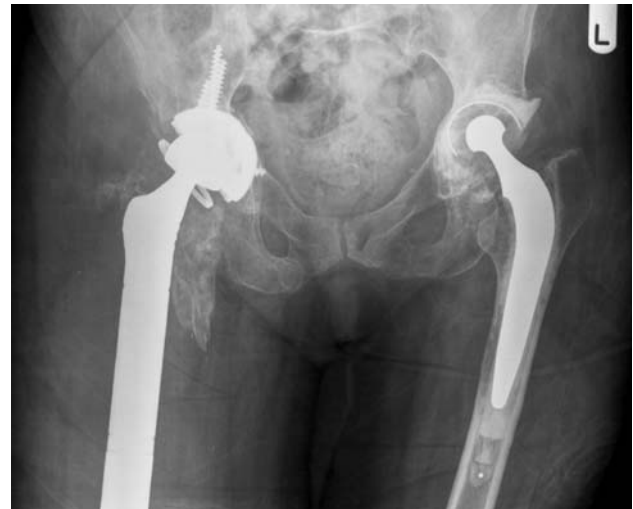

Fig. 5 Postoperative direct exchange right total femoral replacement for patient in Fig. 3, showing proximal prosthesis

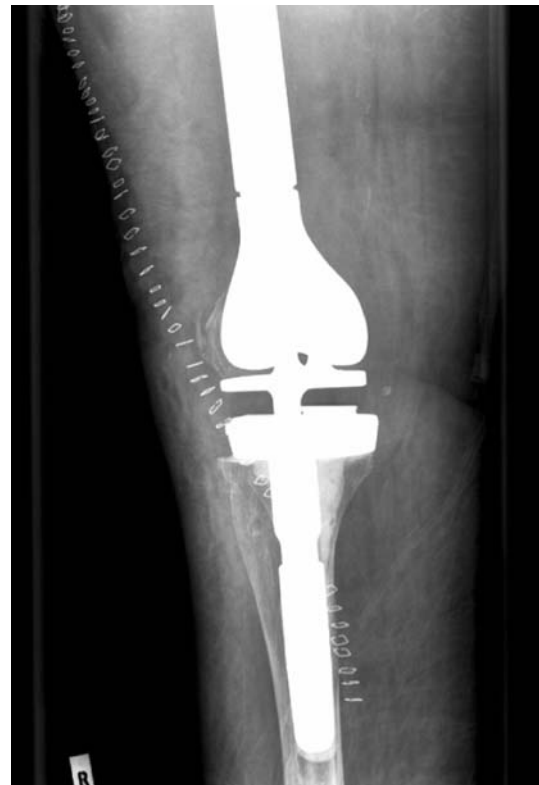

Fig. 6 Postoperative direct exchange right total femoral replacement for patient in Fig. 3, showing distal prosthesis

The presence of infection was confirmed by a positive culture of joint aspirate or by intraoperative culture, or both, in addition to inflammatory changes [18]. Infection was diagnosed microbiologically when more than one tissue culture revealed similar organisms. Pre- and postoperative pain and functional assessments were assessed using the Oxford knee scoring system.

Table 1 Patient characteristics

Patient	Age (years)	Sex	Side	Previous surgery	Co-morbidity	Last follow-up (months)
A	79	F	Left	Primary TKA (2003)	Hypertension, ischaemic heart disease, Recurrent urinary tract infection, Peripheral vascular disease	36
B	61	F	Left	Primary THA (2000) Revision THA (2002) TKA (2003)	Hypoalbuminemia, rheumatoid arthritis	24
C	85	F	Right	Primary THA (1990) Revision THA (2002) years, TKA (2002), LISS plate for periprosthetic (TKA site) fracture (2003)	Hypertension	18
D	74	F	Right	Primary TKA (25) Revision TKA (12) Re-revision TKA (8)	Rheumatoid arthritis, anaemia	60
E	72	F	Right	Primary TKA (11 years), Revision TKA (4 years)	Hypertension, iron deficiency anaemia	24
F	84	M	Right	Primary TKA (15 years), Revision TKA (8 years)	Hypertension, ischaemic heart disease	Death at 6 months

THA total hip arthroplasty

TKA total knee arthroplasty

Tumour prostheses used were the modular replacement system and global modular replacement system (Stryker) distal femoral and total femoral replacement products. The distal femoral replacement product consisted of a modular rotating hinge with tibial rotating component. The total femoral product also consists of a tripolar hip with constrained acetabular insert. Femoral components have extension pieces and stems to alter the length. The correct length was decided intraoperatively in order to maintain satisfactory soft tissue tension and leg lengths. A medium viscosity bone cement with 1 g tobramycin to 40 g of cement powder was used.

The surgical technique for the distal femoral replacement was in the supine position with an extended medial parapatellar approach. A lateral approach was used for the total femoral replacement. Patients who underwent total femoral replacements had periprosthetic infections at ipsilateral hip and knee joints with minimal viable bone. The existing cement and surrounding dead and infected soft and bony tissue were thoroughly debrided. The removal and debridement was followed by a fresh set-up for the reinsertion of implants. A drain was inserted through a point different from the skin incision and taken out at 24–36 h.

Postoperatively teicoplanin, 400 mg twice daily, was given until intraoperative culture sensitivity results became available. Antibiotics were then changed appropriately as per advice from the infectious diseases department. The inflammatory markers CRP, ESR, WBC were used to

monitor progress as well as physical examination of the patient. Blood tests were performed at twice weekly intervals initially. When the patient was prescribed oral antibiotics, the inflammatory markers were monitored at weekly intervals and, depending on the response, the frequency of the test was altered accordingly. Serial radiographs were obtained in the immediate postoperative period and at 6, 12 months and annually thereafter to evaluate for loosening, dislocation and osteolysis. The persistence of infection, pain or immobility was considered as a failure of the intervention.

Results

At final follow-up, five out of the six patients were alive. The mean age at the time of direct exchange was 74.2 years (61–85). The preoperative means for peripheral leucocyte count, CRP and ESR were 7.3 (± 5.1), 29.6 (± 14.3) and 44 (± 5.2) respectively. The mean follow-up was 28 months (18–60). On average, the postoperative mobilisation was with a frame at 5 days and with two sticks at 2 weeks. The average preoperative antibiotic duration was 4 weeks. Four patients were positive for organisms on preoperative aspirate and two patients on intraoperative cultures. The infecting microorganisms cultured are shown in Tables 1 and 2. Some joints had more than one microorganism. The mean duration of intravenous and oral antibiotic therapy was 6 (± 1) weeks and 3.5

Table 2 Demonstrates microorganisms cultured and antibiotics used for the treatment

A combination of antibiotics was required in each patient. Most common infecting microorganism was *Staphylococcus aureus*

Patient	Microorganisms	Antibiotics
A	MRSA	Teicoplanin, flucloxacillin, rifampicin
B	<i>Staphylococcus aureus</i>	Flucloxacillin, rifampicin
C	<i>Staphylococcus aureus</i> , <i>Streptococcus pyogenes</i>	Tazocin, teicoplanin, flucloxacillin
D	<i>Streptococcus pyogenes</i> , <i>E. coli</i>	Tazocin, vancomycin
E	<i>Staphylococcus aureus</i>	Flucloxacillin, rifampicin
F	<i>Pseudomonas</i> , <i>Streptococcus pyogenes</i>	Vancomycin, fusidic acid, rifampicin, doxycycline

(± 1.2) months respectively as per guidelines from the infectious diseases department. Antibiotic therapy was completed in five patients, and one patient (patient F) died before completion of antibiotic therapy. In patients who completed antibiotic therapy, the CRP was less than 10, and the ESR and WBC count were within normal limits at the end of antibiotic treatment.

Three patients (A, B, E) had no pain, and two patients (C, D) had mild pain at last follow-up. The mean Oxford knee scores pre- and postoperatively at 6, 24 weeks and last follow-up were 58.5, 39.2, 37.4 and 35.4 respectively. One patient (A) had recurrence of infection at 3 months postsurgery. This patient had a history of poor peripheral perfusion. However, it eventually settled by the seventh postoperative month. One patient (E) required intervention by plastic surgeons for soft tissue cover at the same setting. There were no intraoperative complications. There was no evidence of radiological loosening, dislocation or further osteolysis identified at last follow-up (Figs. 1, 2, 3, 4b). There was no recurrence of infection at last follow-up. In patients with total femoral replacement (B, C), the postoperative mobility was slower but this was expected. One patient (F) required prolonged pain relief due to instability in the opposite knee. This patient also had associated comorbid factors; hypertension and ischaemic heart disease. This patient sustained a myocardial infarction leading to death at 6 months postoperatively. This patient was still on suppressive doses of oral antibiotics at the time of death. Five out of six patients (80%) successfully completed the course of antibiotics without recurrence of infection, pain or immobility.

Discussion

Revision arthroplasty which becomes infected continues to be a therapeutic challenge. Options are often limited, and therapeutic strategies remain controversial. This cohort of infected revision joint replacements is fortunately rare. The surgeon's experience is important in these extensive

procedures. The senior authors who performed these surgeries provide a lower limb revision arthroplasty service in our tertiary referral centre. Extensive bone loss necessitates a skeletal reconstruction with a tumour prosthesis, usually treated in a centre with specialist revision surgeons, specialist microbiologists and plastic surgeons. A major advantage of a modular endoprosthetic system is its intraoperative flexibility, which enables the surgeon to reconstruct defects of any size with minimal preoperative planning. Instead of performing a resection to match a prosthesis customised on the basis of imaging studies that are 4–8 weeks old, the surgeon can concentrate on performing the best possible resection indicated for the patient at the time of surgery.

In two studies from the Endo-Klinik in Germany, 76 of 104 and 22 of 31 infected total knees were infection-free after a minimum of 2 years follow-up after single-stage exchanges. Cure rates in these studies were 73 and 71% respectively [23]. Recently, more promising results have been reported; Buechel et al. [24] had a 90.9% success rate at an average of 10 years.

There is no definite evidence that a delayed reconstruction can completely eradicate deep infection. A prosthetic joint remains indefinitely at risk of infection [14, 22]. The delay between stages can result in a more difficult second procedure because of extensive scarring, progressive osteolysis and decreased bone density. The greatest functional effect of multiple procedures seems to be a reduction in the quality and function of the extensor mechanism [12]. The increased cost and morbidity secondary to prolonged treatment in a delayed reconstruction is another concern. A recent study has shown that the period of infection before reimplantation and bacterial virulence or resistance were not predictive factors for failure of revision total knee arthroplasty for sepsis [1, 8]. However, the premise of treating infected prosthesis with meticulous surgical technique and appropriate antimicrobial therapy remains unchanged.

Jameson et al. [15] have shown that a combination of antibiotic impregnated cement and intravenous antibiotics

provides better results than either alone. They showed that the initial elution of antibiotics in the cement provides sufficient protection against the formation of bacterial biofilm on the prosthesis. We have also used a similar combination of antibiotics in our study.

Failure in our cohort would have resulted in amputation or disarticulation. Direct exchange endoprosthetic reconstruction has been suggested to minimise patient morbidity and health care costs and facilitate simplicity in the surgical procedure [1]. A temporary spacer, as in a two-stage procedure, was considered to be unstable in the presence of massive bone defects.

The CRP, ESR and microbiological cultures are shown to be accurate monitors of deep infection [12]. Postsurgery, the trend of these inflammatory markers dictates antibiotic treatment. A specialist antibiotic service is essential to complement the specialist surgery in eradicating infection. Indeed, the success of this procedure is determined by successful eradication of infection. The duration of antibiotic therapy does not seem to alter the incidence of recurrent or persistent infection, [13] hence the need for appropriate antibiotic therapy. Uncontrollable variables like differences in patient population, the antibiotic guidelines and variation in antibiotic resistance of the identified micro-organisms make comparisons of this cohort with previous studies difficult.

We have assumed that if patients were given the choice of either one or two operations, with approximately similar results, most patients would opt for one procedure instead of having a delayed reconstruction with an interim period with an unstable joint, as would be needed in a two-stage procedure. Indeed, some results have showed at least 89% success rate with direct exchange which are comparable with two-stage exchange procedures.

Our success is attributable to the following factors. First, meticulous surgical technique by experienced surgeons—there were no intraoperative complications; second, the availability of appropriate implant and theatre resources; third, the availability on-site of a specialist antibiotic service; and finally, good patient compliance derived by providing patients with a clear understanding of the surgery and the postoperative outcome.

This procedure is not without challenges. Osteolysis, poor soft tissues and drug-resistant microorganisms can pose a problem with direct exchange arthroplasty. Osteolysis is often underestimated on preoperative radiographs. The exact extent is determined during surgery following debridement. This is exemplified by the two patients who underwent total femoral replacements; they had a minimal amount of viable non-infected femoral remaining after debridement as both had infected hip and knee revision prostheses. The morbidity after failed treatment of an infected revision arthroplasty is substantial, and direct

exchange should be considered only in centres which deal with revision arthroplasty frequently.

Another concern is the low survival rates of tumour prostheses around the knee. Guo et al. [10] have reported a 5-year survival of 70.5% for a locally designed and fabricated stainless steel endoprosthesis for tumours around the knee. Increased failure rates were seen at the proximal tibia prosthesis. Gitelis et al. [9] have also shown increased failure rates to be associated with proximal tibia prostheses. In our cohort, the deficiency was mainly in the femur. Windhager et al. [24] have reported a success rate of 77.8% in the treatment of infected tumour knee prostheses by direct exchange, a figure similar to our study.

The obvious limitation of this study is the small number of patients. However, this is a complex subset of patients not commonly seen in routine practice.

Conclusion

Limb salvage by endoprosthetic reconstruction using tumour prostheses has been found useful for treating a cohort of patients with periprosthetic infection associated with segmental bone loss. Multidisciplinary support from plastic surgeons and specialist microbiologists is essential. Our results have shown this strategy to provide effective pain relief, stability and improved mobility.

Conflict of interest statement There are no conflicts of interests with any of the authors involved in the study.

References

1. Bauer T, Piriou P, Lhotellier L, Leclerc P, Mamoudy P, Lortat-Jacob A (2006) Results of reimplantation for infected total knee arthroplasty: 107 cases. *Rev Chir Orthop Reparatrice Appar Mot* 92(7):692–700
2. Buechel FF (2004) The infected total knee arthroplasty: just when you thought it was over. *J Arthroplasty* 19(Suppl 1):51–55
3. Buechel FF, Femino FP, D'Alessio J (2004) Primary exchange revision arthroplasty for infected total knee replacement: a long-term study. *Am J Orthop* 33:190–198
4. De Cloedt P, Emery R, Legaye J, Lokietek W (1994) Infected total knee prosthesis. Guidance for therapeutic choice. *Rev Chir Orthop Reparatrice Appar Mot* 80(7):626–633
5. Deirmengian C, Greenbaum J, Lotke PA, Booth RE Jr, Lonner JH (2003) Limited success with open debridement and retention of components in the treatment of acute staphylococcus aureus infections after total knee arthroplasty. *J Arthroplasty* 18(Suppl 1):22–26
6. Dixon P, Parish EN, Cross MJ (2004) Arthroscopic debridement in the treatment of the infected total knee replacement. *J Bone Joint Surg Br* 86(1):39–42
7. Engh GA, Ammeen DJ (1999) Bone loss with revision total knee arthroplasty: defect classification and alternatives for reconstruction. *Instr Course Lect* 48:167–175

8. Gacon G, Laurencon M, Van de Velde D, Giudicelli DP (1997) Two stages reimplantation for infection after knee arthroplasty. Apropos of a series of 29 cases. *Rev Chir Orthop Reparatrice Appar Mot* 83(4):313–323
9. Gitelis S, Yergler JD, Sawlani N, Schiff A, Shott S (2008) Short and long term failure of the modular oncology knee prosthesis. *Orthopedics* 31(4):362
10. Guo W, Ji T, Yang R, Tang X, Yang Y (2008) Endoprosthetic replacement for primary tumours around the knee: experience from Peking University. *J Bone Joint Surg Br* 90(8):1084–1089
11. Gupta S, Chu A, Ranawat A, Slamin J, Ranawat C (2007) Review article: osteolysis after total knee arthroplasty. *J Arthroplasty* 22(6):787–799
12. Hart WJ, Jones RS (2006) Two-stage revision of infected total knee replacements using articulating cement spacers and short-term antibiotic therapy. *J Bone Joint Surg Br* 88(8):1011–1015
13. Hoad-Reddick DA, Evans CR, Norman P, Stockley I (2005) Is there a role for extended antibiotic therapy in a two-stage revision of the infected knee arthroplasty. *J Bone Joint Surg Br* 87-B:171–174
14. Inmann RD, Gallegos KV, Brause BD, Redecha PB, Christian CL (1984) Clinical and microbiological features of prosthetic joint infection. *Am J Med* 77:47–53
15. Jämsen E, Huhtala H, Puolakka T, Moilanen T (2009) Risk factors for infection after knee arthroplasty. A register-based analysis of 43, 149 cases. *J Bone Joint Surg Am* 91(1):38–47
16. Leone JM, Hanssen AD (2006) Management of infection at the site of a total knee arthroplasty. *Instr Course Lect* 55:449–461
17. Meek RM, Masri BA, Dunlop D, Garbuz DS, Greidanus NV, McGraw R, Duncan CP (2003) Patient satisfaction and functional status after treatment of infection at the site of a total knee arthroplasty with use of the PROSTALAC articulating spacer. *J Bone Joint Surg Am* 85-A(10):1888–1892
18. Mirra JM, Amstutz HC, Matos M, Gold R (1976) The pathology of the joint tissues and its clinical relevance in prosthesis failure. *Clin Orthop Relat Res* 117:221–240
19. Siegel A, Frommelt L, Runde W (2000) Therapy of bacterial knee joint infection by radical synovectomy and implantation of a cemented stabilized knee joint endoprosthesis. *Chirurg* 71:1385–1391
20. Sculco TP (1993) The economic impact of infected total joint arthroplasty. *Instr Course Lect* 42:349–351
21. Silva M, Tharani R, Schmalzried TP (2002) Results of direct exchange or debridement of the infected total knee arthroplasty. *Clin Orthop* 404:125–131
22. Tattevin P, Cremieux AC, Pottier P et al (1999) Prosthetic joint infection: when can prosthesis salvage be considered? *Clin Infect Dis* 29:292–295
23. Von Foerster G, Kluber D, Kabler U (1991) Mid- to long-term results after treatment of 118 cases of periprosthetic infections after knee joint replacement using one-stage exchange surgery. Article in German. *Orthopade* 20:244–252
24. Windhager R, Leithner A, Hohegger M (2006) Revision of tumour endoprostheses around the knee joint. Review and own results. *Orthopade* 35(2):176–183