

Original Research Article

Lymph Node Diameter as a Predictor of Lymph Node Metastasis in Patients with Colorectal Neuroendocrine Neoplasms

Kaoru Fujikawa, Shingo Noura, Yozo Suzuki and Hiroshi Takeyama

Department of Surgery, Toyonaka Municipal Hospital, Toyonaka, Japan

Abstract

Objectives: The ideal cut-off value for the diameter of metastasis-positive lymph nodes (LNs) in patients with colorectal neuroendocrine neoplasms (NENs) is unclear. Thus, in this study, we investigated the correlation between the LN diameter and LN metastasis.

Methods: A total of 148 LNs of 42 patients with colorectal NEN who underwent surgical dissection or local resection from April 2010 to March 2016 were included in the present study. The LN diameters were measured on computed tomography, and LN metastases were either pathologically proven or evaluated during the follow-up period.

Results: Overall, 18 (12.2%) LNs were positive for LN metastasis, and 130 (87.8%) were negative. The short diameter in metastatic-positive LNs was longer than that in negative LNs (4.9 [3.0-6.3] vs. 2.0 [1.0-2.0] mm; $P = 0.01$). An LN of >3 mm predicted LN metastasis with 88.8% sensitivity and 78.5% specificity with an area under the curve of 0.852.

Conclusions: Surgical resection with lymphadenectomy should be considered for patients with LNs of >3 mm in diameter.

Keywords

carcinoid tumor, colorectal neoplasms, lymphatic metastasis, lymph nodes, neuroendocrine neoplasms

J Anus Rectum Colon 2022; 6(2): 129-133

Introduction

Neuroendocrine neoplasm (NEN) is a rare malignancy, constituting approximately 2% of all neoplasms; 54.5% of NENs occur in the gastrointestinal tract, predominately in the small intestine (44.7%), followed by the rectum (19.6%), appendix (16.7%), and colon (10.6%)[1]. The incidence of gastrointestinal tract NENs in Japan is increasing, with an incidence of 2.10 per 100,000 in 2005 and 3.51 per 100,000 in 2010[2]. This increase reflects the widespread use of endoscopy and increased awareness of NENs among clinicians and pathologists.

In the World Health Organization classification of NENs, which was published in 2019, NENs are categorized into

five groups according to their pathological features: NET G1, G2, G3, neuroendocrine carcinoma (NEC), and mixed neuroendocrine-non-NEN. The survival of patients with NEN differs among each of the pathological grades. In colorectal NEN, NET G1 has the best prognosis, followed by those with NET G2[3]. Colorectal NENs without lymph node (LN) or distant metastasis have a good prognosis; the cause-specific 5-year survival rates of patients with NENs of the colon and rectum are 94.1% and 94.9%, respectively[1].

When planning the therapeutic strategy for NENs, it is crucial to detect the extent of the primary tumor, LN metastasis, and the existence of distant metastasis. The tumor size and LN status are reported to be important predictors of survival[1]. In cases of colorectal NENs, along with LN metas-

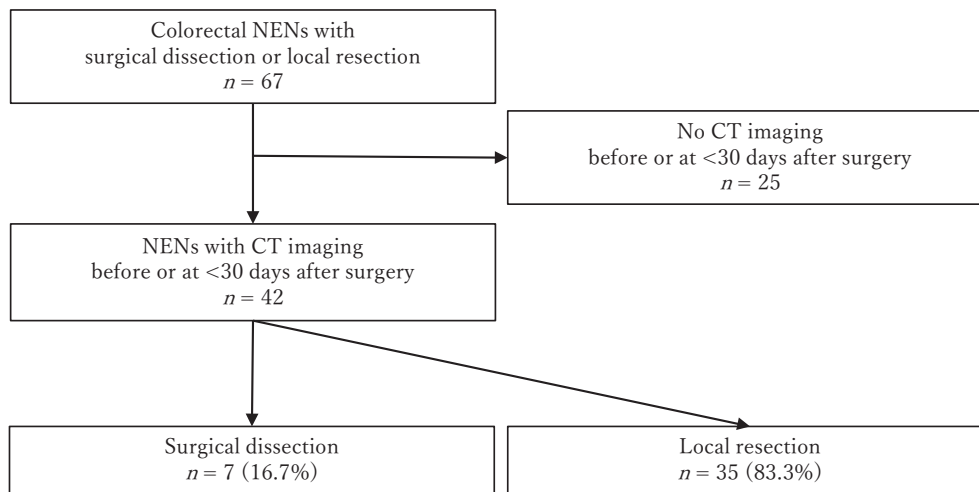


Figure 1. Forty-two patients with colorectal neuroendocrine neoplasms who underwent surgical dissection or local resection were included.

tasis, tumors of >10 mm, NET G2 or NEC, muscularis propria (MP) invasion, and lymphovenous invasion are considered absolute indications for surgery due to the high rate of LN metastasis[4].

Prior to treatment, LNs are evaluated for metastasis by computed tomography (CT), magnetic resonance imaging, and endoscopic ultrasound. The importance of CT imaging has been demonstrated, and CT is a widely used diagnostic tool in the assessment of LNs, and LN enlargement on CT is generally regarded as a sign of metastasis. However, at present, there is no consensus about the optimal cut-off value of the LN diameter on CT for predicting metastasis in patients with colorectal NENs.

The aim of this study was to investigate the correlation between the LN size and LN metastasis.

Methods

1. Patient recruitment and data

This was a retrospective study in Toyonaka Municipal Hospital. We reviewed our registry from April 2010 to March 2016. A total of 67 patients with colorectal NENs who underwent surgical dissection or local resection (endoscopic mucosal resection, endoscopic submucosal dissection, or transanal excision) at our hospital were enrolled. Twenty-five of these patients who did not undergo CT imaging before or at <30 days after surgery were excluded from our study (Figure 1).

For each patient, we collected perioperative clinical data and pathological data. The tumors were diagnosed and classified according to the 2019 Japan Neuroendocrine Tumor Society Clinical Practice Guidelines for Gastroenteropancreatic Neuroendocrine Neoplasms[4]. The treatment plan was determined in accordance with the guidelines in principle.

2. LN evaluation

We generally performed contrast-enhanced CT with a slice thickness of 1.25 mm. The CT images were obtained using a spiral multi-detector CT. We reviewed the CT images to obtain information regarding this study (e.g., the number of visible LNs, location, and size). Regional LNs consist of three locations, pericolic/perirectal, intermediate, and main LNs. In addition, lateral pelvic LNs are included as a fourth group in the rectum NENs. The diameter was calculated for all LNs in each case, and the shortest value was used as an indicator. All of these indicators were measured without knowledge of the pathological findings, other than the location of the primary tumor.

Each variable was measured on CT images and analyzed in relation to the pathologically proven LN involvement. For patients who underwent endoscopic or local resection, an LN was diagnosed as metastasis-negative if there was no recurrence after a follow-up period of at least 36 months. During the follow-up period, the LNs were assessed by CT of the abdomen and pelvis.

3. Statistical analysis

Quantitative variables were compared using the Mann-Whitney U test, and categorical variables were compared using chi-squared tests. The optimal metastatic LN size was evaluated using a receiver operating characteristic (ROC) curve analysis, with the cut-off value determined by calculating the area under the curve (AUC). P values of <0.05 were considered to indicate statistical significance. Representative values are expressed as the median [1st quartile-3rd quartile]. All statistical analyses were performed using the JMP software program (ver. 14.2.0; SAS Institute, Tokyo, Japan).

Written consent has been obtained from all patients to

Table 1. Patient Characteristics (n = 42).

Age (median [IQR], years)	62 [53.8–69.3]
Gender (male/female)	30/12
Resection (colorectal resection with lymph node dissection/transanal resection/endoscopic resection)	7/2/33
Tumor location (colon/rectum)	4/38
Tumor diameter (median [IQR], mm)	4.9 [3.7–8.3]
Central depression (yes/no)	11/31
Histology (G1/G2/NEC)	36/5/1
Depth (M–SM/MP–)	38/4
Lymphatic invasion (yes/no)	5/37
Vascular invasion (yes/no)	4/38
Extent of lymph node metastasis (yes/no)	6/36

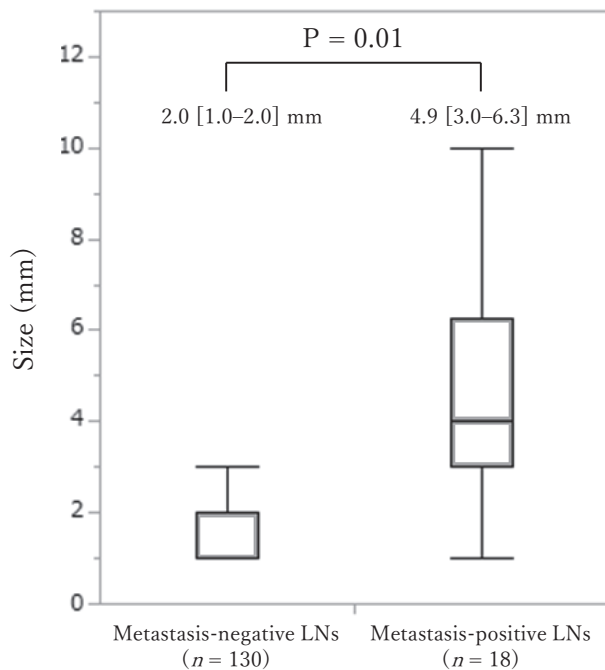


Figure 2. The short diameter of metastasis-positive lymph nodes (LN) was longer than that of metastasis-negative LNs (4.9 [3.0–6.3] vs. 2.0 [1.0–2.0] mm; $P = 0.01$). Data are median [IQR].

publish the information, including photographs. The present retrospective study was approved by the institutional review board of Toyonaka Municipal Hospital (2020-02-05).

Results

1. Patient characteristics

The patient characteristics are reported in Table 1. The median age was 62 (53.8–69.3) years, and there were 30 (71.4%) males and 12 (28.6%) females. Seven (16.7%) patients underwent colorectal resection with LN dissection. Two (4.8%) patients underwent transanal resection, and 33 (78.6%) patients underwent endoscopic resection. There

were 38 (90.5%) rectal NENs and 4 (9.5%) colon NENs; the median tumor size of the NENs was 4.9 [3.7–8.3] mm. Eleven (26.2%) NENs showed central depression. Of the 42 primary NENs, 36 (85.7%) patients were diagnosed with NET G1, 5 (11.9%) were diagnosed with NET G2, and 1 (2.4%) was diagnosed with NEC. The depth of tumor invasion was within the submucosa (SM) in 38 (90.4%) cases, confined within the MP in 2 (4.8%) cases and beyond the MP in 2 (4.8%) cases. Five (11.9%) NENs showed lymphatic invasion and 4 (9.5%) showed venous invasion. The number of LNs dissected per case and metastasis-positive LNs was 16.3 and 5.3, respectively.

We measured and analyzed CT images of 148 LNs. Eighteen (12.2%) of the LNs were LN metastasis-positive, whereas 130 (87.8%) were LN metastasis-negative. Six (14.3%) patients were positive for LN metastasis, and 36 (85.7%) were negative. All metastasis-positive LNs were dissected and pathologically proven. The median follow-up period was 69 months.

2. Outcomes

The LN short diameter was longer in metastasis-positive LNs than in metastasis-negative LNs (4.9 [3.0–6.3] vs. 2.0 [1.0–2.0] mm; $P = 0.01$) (Figure 2).

To analyze the accuracy of the prediction, we performed an ROC analysis (Figure 3). When an LN of >3.0 mm in diameter was detected on CT, the LN metastasis was diagnosed with 88.8% (16/18) sensitivity and 78.5% (102/130) specificity. Using this criterion, the AUC reached 0.852.

3. LN metastasis in metastasis-positive or metastasis-negative patients

Of the 42 patients, 36 (85.7%) patients were negative for LN metastasis, and 6 (14.3%) were positive. The maximum LN diameter in metastasis-positive patients was longer than that in metastasis-negative patients (7.5 [5.3–10.5] vs. 2.0 [1.0–2.0]; $P = 0.001$). Table 2 demonstrates the association between patients with or without LN metastasis and the number of LNs detected on CT. The number of measurable

LN per case in the metastasis-positive patients was larger than that in the metastasis-negative patients (7.5 [6.0-10.5] vs. 2.0 [1.0-3.0]; $P = 0.002$). We detected more LNs of ≥ 3 mm in size in the metastasis-positive patients than in the metastasis-negative patients (4.0 [4.0-4.8] vs. 0.0 [0.0-0.0]; $P = 0.003$). We detected LNs of ≥ 3 mm in short diameter in 12 patients; 6 (50.0%) of these patients had metastasis-positive LNs.

Discussion

Generally, an LN diameter of >10 mm has been commonly accepted as a predictor of LN metastasis in colorectal cancer. In contrast, the metastasis-positive LNs detected by CT in patients with NEN were smaller[5]. The accuracy of LN staging by CT for patients with colorectal NEN is unclear. From this viewpoint, we conducted the present study to investigate the sensitivity and specificity of CT in predicting LN metastasis.

We compared the CT findings and found that a short di-

ameter of >3.0 mm on CT images was a predictor of LN metastasis.

Tanaka et al. investigated the large diameter of LNs on CT in 21 cases of colorectal NEN and performed an ROC analysis to identify the optimal cut-off value for predicting LN metastasis. They revealed that LNs of >3 mm on CT predicted LN metastasis with 100% sensitivity and 82.4% specificity, with an AUC of 0.8971. The longest diameter of the LNs observed on the CT was 4.3 ± 0.89 mm in LN-positive patients and 0.89 ± 0.43 mm in LN-negative cases.

Based on the response evaluation criteria in solid tumors, the LN size should only be measured by the short diameter[6]. Thus, Tanaka et al. may have obtained different results if they had used the short diameter. However, they reported that a diameter of >3 mm was a predictor of LN metastasis, and this indicates that smaller LNs were positive for LN metastasis in comparison to colorectal cancer.

Kim et al. performed a study of 40 cases of rectal NEN using formaldehyde-fixed, paraffin embedded blocks and measured the diameter of the dissected LNs. They revealed that 24.5% of LNs of <5 mm in size were positive for metastasis. The short diameter of the LNs was 4.41 mm in the LN-positive patients and 1.93 mm in the LN-negative patients[7].

As they used formaldehyde-fixed specimens, it is possible that the morphology differed from that of fresh specimens or the values measured on CT images. It is reported that when analyzing formalin-fixed LNs, 10%-20% shrinkage or a reduction of 1 mm in size (in comparison to fresh LNs) can be expected[8]. However, considering the results of both studies, it is necessary to rethink the possibility of LN metastasis, even if when LNs are smaller in size.

The LN shape, the internal pattern on contrast-enhanced CT, and uptake on PET CT and SPECT can also predict LN metastasis. Tanaka et al. reported that there was no correlation between LN metastasis and the short/long axis diameter ratio. This could be influenced by the fact that the dissected LNs in NENs are smaller than those in colorectal cancer. The internal pattern has also been evaluated; however, no significant correlation was found between LN metastasis and a heterogeneous internal pattern[5].

Albanus et al. performed a study of 54 cases of NEN using ^{68}Ga -DOTATATE PET CT and contrast-enhanced CT to investigate the uptake of LNs. In their study, ^{68}Ga -

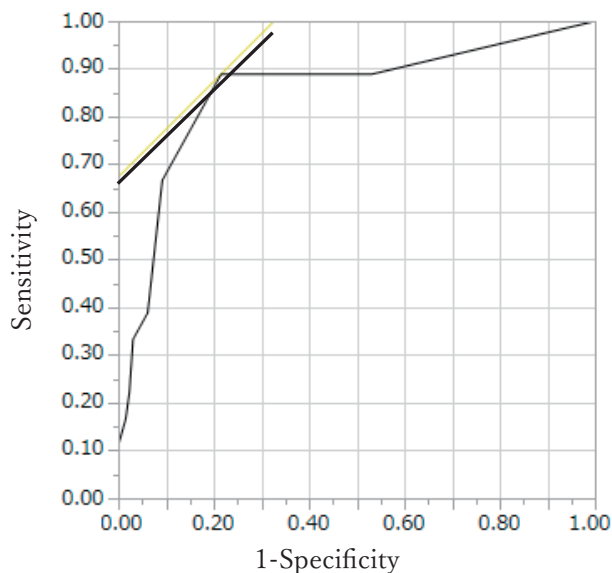


Figure 3. The prediction of lymph node (LN) metastasis according to the diameter of all LNs measured on computed tomography (CT) (AUC = 0.852). LNs of >3 mm in diameter on CT showed 89% sensitivity and 78% specificity in the prediction of pathologically-positive LNs.

Table 2. Patients with Metastatic Lymph Nodes (LN) and the Numbers of Measurable LNs per Patient on Computed Tomography.

	Metastasis-negative patients (n = 36)	Metastasis-positive patients (n = 6)	P
Total (median [IQR])	2.0 [1.0-3.0]	7.5 [6.0-10.5]	0.002
>3 mm LN (median [IQR])	0.0 [0.0-0.0]	4.0 [4.0-4.8]	0.003

DOTATATE PET CT showed 92% sensitivity and 83% specificity, whereas contrast-enhanced CT showed 64% sensitivity and 59% specificity in the detection of LN metastasis[9].

The present study was associated with some limitations. First, it was a retrospective study that was performed in a single institution with a relatively small number of patients. This was because colorectal NEN is a rare entity. A multi-institutional survey should be conducted to obtain more reliable findings. Second, the follow-up period was relatively short, as late recurrence is observed in some patients with NEN. We evaluated recurrence at 3 years after resection; however, the possibility that more patients would develop LN recurrence over a longer follow-up period cannot be ruled out. Long-term surveillance is needed for a detailed study. Despite these limitations, our findings indicate that even small-sized LNs can be positive for metastasis in patients with colorectal NEN.

In conclusion, an LN of >3 mm in short diameter predicted LN metastasis with 88.8% sensitivity and 78.5% specificity, with an AUC of 0.852. Surgical resection with lymphadenectomy should be considered for LNs of >3 mm.

Conflicts of Interest

There are no conflicts of interest.

Author Contributions

Kaoru Fujikawa: Substantial contributions to the conception or design of the work; or the acquisition, analysis, or interpretation of data for the work; AND Drafting the work or revising it critically for important intellectual content; AND Final approval of the version to be published; AND Agreement to be accountable for all aspects of the work in ensuring that questions related to the accuracy or integrity of any part of the work are appropriately investigated and resolved.

Shingo Noura: Substantial contributions to the conception or design of the work; or the acquisition, analysis, or interpretation of data for the work; AND Drafting the work or revising it critically for important intellectual content; AND Final approval of the version to be published; AND Agreement to be accountable for all aspects of the work in ensuring that questions related to the accuracy or integrity of any part of the work are appropriately investigated and resolved.

Yozo Suzuki: Substantial contributions to the conception or design of the work; or the acquisition, analysis, or interpretation of data for the work; AND Drafting the work or revising it critically for important intellectual content; AND Final approval of the version to be published; AND Agreement to be accountable for all aspects of the work in ensur-

ing that questions related to the accuracy or integrity of any part of the work are appropriately investigated and resolved.

Hiroshi Takeyama: Substantial contributions to the conception or design of the work; or the acquisition, analysis, or interpretation of data for the work; AND Drafting the work or revising it critically for important intellectual content; AND Final approval of the version to be published; AND Agreement to be accountable for all aspects of the work in ensuring that questions related to the accuracy or integrity of any part of the work are appropriately investigated and resolved.

Approval by Institutional Review Board (IRB)

IRB code: 2020-02-05-3

Institution: Institutional review board of Toyonaka Municipal Hospital

References

1. Maggard MA, O'Connell JB, Ko CY. Updated population-based review of carcinoid tumors. *Ann Surg.* 2004 Jul; 240(1): 117-22.
2. Ito T, Sasano H, Tanaka M, et al. Epidemiological study of gastroenteropancreatic neuroendocrine tumors in Japan. *J Gastroenterol.* 2010 Feb; 45(2): 234-43.
3. Jernman J, Välimäki MJ, Louhimo J, et al. The novel WHO 2010 classification for gastrointestinal neuroendocrine tumours correlates well with the metastatic potential of rectal neuroendocrine tumours. *Neuroendocrinology.* 2012; 95(4): 317-24.
4. JNETS Neuroendocrine Neoplasms Clinical Practice Guidelines Committee. Clinical practice guidelines for lead neuroendocrine neoplasms (GEP-NEN). 2nd ed. Tokyo: Kanehara-shuppan; 2019. 179 p.
5. Tanaka T, Nozawa H, Kawai K, et al. Lymph node size on computed tomography images is a predictive indicator for lymph node metastasis in patients with colorectal neuroendocrine tumors. *In Vivo.* 2017 Sep; 31(5): 101-17.
6. Eisenhauer EA, Therasse P, Bogaerts J, et al. New response evaluation criteria in solid tumours: revised RECIST guideline (version 1.1). *Eur J Cancer.* 2009 Jan; 45(2): 228-47.
7. Kim BC, Kim YE, Chang HJ, et al. Lymph node size is not a reliable criterion for predicting nodal metastasis in rectal neuroendocrine tumours. *Colorectal Dis.* 2016 Jul; 18(7): O243-5.
8. Kawai K, Morikawa T. The effect of formalin fixation on the size of pelvic sidewall lymph nodes. *Int J Colorectal Dis.* 2018 Oct; 33(10): 1493-5.
9. Albanus DR, Apitzsch J, Erdem Z, et al. Clinical value of 68Ga-DOTATATE-PET/CT compared to stand-alone contrast enhanced CT for the detection of extra-hepatic metastases in patients with neuroendocrine tumours (NET). *Eur J Radiol.* 2015 Oct; 84(10): 1866-72.

Journal of the Anus, Rectum and Colon is an Open Access journal distributed under the Creative Commons Attribution-NonCommercial-NoDerivatives 4.0 International License. To view the details of this license, please visit (<https://creativecommons.org/licenses/by-nc-nd/4.0/>).