

# Insulin degludec overdose in an adolescent with type 1 diabetes: proactive management including monitoring using the Freestyle Libre flash glucose monitoring system

Harmony Thompson<sup>1</sup>, Helen Lunt<sup>1,2</sup>, Cate Fleckney<sup>1</sup> and Steven Soule<sup>1,2</sup>

<sup>1</sup>Department of Endocrinology and Diabetes, Canterbury District Health Board, Christchurch, New Zealand and

<sup>2</sup>Department of Medicine, University of Otago Christchurch, Christchurch, New Zealand

Correspondence  
should be addressed  
to H Lunt

**Email**  
[helen.lunt@cdhb.health.nz](mailto:helen.lunt@cdhb.health.nz)

## Summary

An adolescent with type 1 diabetes and a history of self-harm, which included intentional overdoses and insulin omission, presented with an insulin degludec overdose. She had been commenced on the ultra-long-acting insulin, degludec, with the aim of reducing ketoacidosis episodes in response to intermittent refusal to take insulin. Insulin degludec was administered under supervision as an outpatient. Because it was anticipated that she would attempt a degludec overdose at some stage, the attending clinicians implemented a proactive management plan for this (and related) scenarios. This included long-term monitoring of interstitial glucose using the Abbott Freestyle Libre flash glucose monitor. The patient took a witnessed overdose of 242 units of degludec (usual daily dose, 32 units). She was hospitalised an hour later. Inpatient treatment was guided primarily by interstitial glucose results, with capillary and venous glucose tests used as secondary measures to assess the accuracy of interstitial glucose values. Four days of inpatient treatment was required. The patient was managed with high glycaemic loads of food and also intermittent intravenous dextrose. No hypoglycaemia was documented during the admission. In summary, while a degludec overdose may require several days of inpatient management, in situations where proactive management is an option and the dose administered is relatively modest, it may be possible to avoid significant hypoglycaemia. In addition, this case demonstrates that inpatient interstitial glucose monitoring may have a role in managing insulin overdose, especially in situations where the effect of the insulin overdose on glucose levels is likely to be prolonged.

## Learning points:

- Degludec overdoses have a prolonged effect on blood glucose levels, but if the clinical situation allows for early detection and management, treatment may prove easier than that which is typically needed following overdoses of a similar dose of shorter acting insulins.
- Inpatient real-time interstitial monitoring helped guide management, which in this context included the prescription of high dietary carbohydrate intake (patient led) and intravenous 10% dextrose (nurse led).
- Use of inpatient interstitial glucose monitoring to guide therapy might be considered 'off label' use, thus, both staff and also patients should be aware of the limitations, as well as the benefits, of interstitial monitoring systems.
- The Libre flash glucose monitor provided nurses with low cost, easy-to-use interstitial glucose results, but it is nevertheless advisable to check these results against conventional glucose tests, for example, capillary 'finger-stick' or venous glucose tests.

## Background

There is a small body of information already available about the inpatient management of insulin overdose with the ultra-long-acting insulin, degludec. The novel aspect of this case relates to monitoring of the patient's glucose using the Libre flash interstitial glucose monitor, both before and after the overdose. Flash glucose monitoring was used to facilitate inpatient dosing of both oral carbohydrate and also intravenous dextrose.

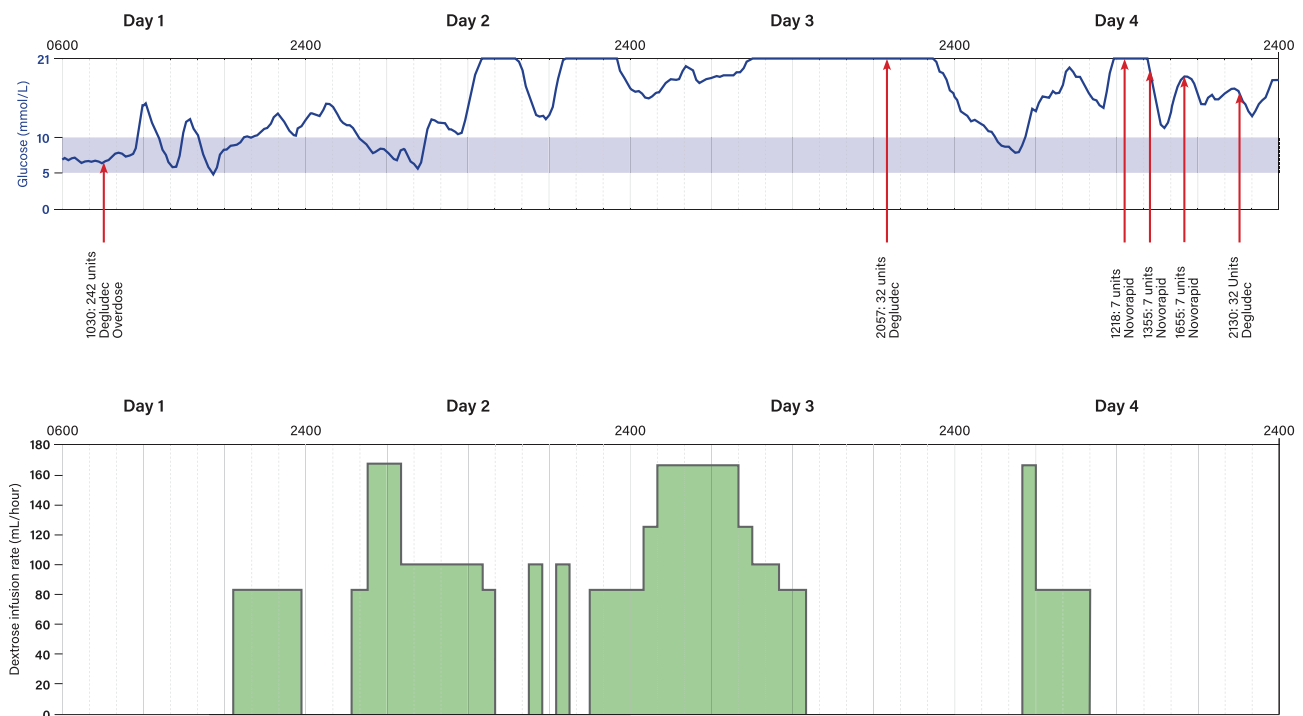
## Case presentation

The patient, aged 16 years, had a 5-year history of type 1 diabetes. Her chronic self-harm behaviours included self-inflicted burns, intentional overdoses of her psychotropic medications, insulin omission leading to ketoacidosis and also insulin overdoses with insulin aspart, Penmix 30 and glargine. She presented frequently to the Emergency Department, in relation to self-harm behaviours. It was anticipated that she would continue to underdose and overdose on insulin. The patient was transferred to degludec as her basal insulin, primarily to reduce ketoacidosis following insulin refusal. She had also refused to undertake regular capillary finger-stick glucose

monitoring during previous hospitalisations and was therefore provided with the Libre system for monitoring of interstitial glucose, for both outpatient and also inpatient use. At the time of her current presentation, HbA1c was 75 mmol/mol and her prescribed insulins were degludec 32 units mane, Penmix 30 38 units mane and aspart up to ten units as a correction for hyperglycaemia. She was well nourished with a BMI z-score of 1.54.

Outpatient insulin injections were supervised by a family member. Access to degludec was restricted to one 3 mL pre-filled insulin pen injector per injection session. Her family reported that instead of taking her usual morning doses of insulins, they observed her taking 242 units of degludec. She presented to hospital an hour later. Inpatient interstitial glucose was recorded every hour with the Libre reader (Fig. 1). She was encouraged to eat high carbohydrate food to maintain an interstitial glucose above 5 mmol/L. Documentation of dietary intake showed that, in addition to being provided with hospital food, the patient ate 'take-away' foods, such as pies and chips.

A 10% dextrose intravenous infusion was titrated against interstitial glucose (Fig. 1), with the aim of maintaining glucose between 10 and 20 mmol/L, thereby



**Figure 1**

The figure summarises inpatient management over 4 days. Subcutaneous insulin dose and time is shown by the red arrows. The blue line represents interstitial glucose results and the green areas represent intravenous infusion rates of 10% dextrose.



providing some margin for error, should interstitial glucose results 'over-read' the true glucose value. Intravenous access was poor and the dextrose infusion paused several times in relation to this. The trough interstitial glucose level was 5.2 mmol/L, and the patient was asymptomatic throughout the admission. Potassium was monitored twice daily and remained within the normal range. Capillary and venous glucose showed clinically acceptable concordance with interstitial glucose recordings. Plasma insulin was also measured, but results proved difficult to interpret because there was only partial cross-reactivity between degludec and the local clinical laboratory's commercial insulin assay (Roche assay).

## Investigation

Freestyle Libre interstitial glucose monitoring of the glycaemic effect of the insulin overdose was used in this patient, primarily because of patient refusal to allow clinical staff to undertake frequent capillary glucose monitoring. Occasional capillary monitoring was however performed, so that accuracy of the Libre flash glucose monitor could be checked.

## Treatment

The figure outlines inpatient management with intravenous glucose and also describes how and when the patient's usual subcutaneous insulin was re-introduced.

## Outcome and follow-up

Four months after the overdose described earlier, the patient has since presented to the Emergency Department on three occasions, with non-diabetes-related tablet overdoses, but had not overdosed on insulin.

## Discussion

Insulin degludec (Tresiba, Novo Nordisk) is an ultra-long-acting insulin with a duration of action at steady state, of around 42 h (1). It is usually prescribed as a once-daily injection (1). A three-times-a-week injection schedule has been used in research settings in type 2 diabetes, using degludec in higher doses per injection (1). Modest overdoses of double the usual once-daily injection dose may therefore be predicted to have only minimal hypoglycaemic effect, when compared to overdoses of similar amounts (units) of shorter acting insulins. Our patient took eight times her usual dose of degludec.

There are three previously published reports of degludec overdoses, all of which required prolonged hospitalisation in relation to the long half-life of degludec (2, 3, 4). In contrast to these previous reports, the current patient presented to hospital early, did not experience neuroglycopenia or loss of consciousness and was therefore able to tolerate large oral carbohydrate loads as part of her management. Also, the magnitude of her overdose (242 units) was lower than the median reported insulin overdose (when considering all types of insulin) of 900 units (5). This facilitated implementation of a relatively simple inpatient management plan.

Use of the Libre flash glucose monitor would appear to offer some benefits over and above conventional continuous glucose monitoring within the context of this patient's inpatient admission: It is factory calibrated so does not require calibration using capillary tests (6). The sensor is placed in the upper arm, allowing ease of sensor access, for flash monitoring. Also the reader is easy to use. These features translate to ease of use, from the ward staff perspective. Interstitial glucose readings may not however reach optimal accuracy immediately after sensor insertion; thus, a short warm-up period is usually preferred (6). If a new sensor needs to be inserted on the ward, a stand-down period of several hours is therefore advisable, before relying on the new sensor's readings for clinical management.

Interstitial glucose monitoring is not always as accurate and reliable as conventional modes of glucose measurement (6, 7). It is therefore important not to rely entirely on interstitial results and to ensure adjunctive modes of glucose testing. In the current case, we used capillary and venous glucose testing for this purpose.

In conclusion, in the setting of a patient with complex behavioural issues and also type 1 diabetes, Libre flash interstitial glucose monitoring proved to be a convenient method of monitoring glucose during recovery from a degludec overdose, from the ward staff's perspective. Subsequent to the current admission, we have used Libre flash glucose monitoring to help guide management of another patient with complex behavioural issues, who took an intentional overdose of another brand of long-acting insulin.

### Patient's perspective

The patient was asked to compare physical side effect and management of the degludec overdose, with her previous hospitalisations for overdoses of insulin aspart, glargine and Penmix 30. She stated that with degludec she 'felt fine' and 'didn't go low'. When asked what 'not going low' meant for her, she said it meant the overdose was 'pointless and didn't work'. She 'would not try it again' as she had to stay in hospital for 4 days and take time away from paid employment.



---

#### Declaration of interest

H L is on the speakers' bureau for Sanofi, New Zealand.

---

#### Funding

This research did not receive any specific grant from any funding agency in the public, commercial or not-for-profit sector.

---

#### Patient consent

Written informed consent was obtained from the patient and her family for publication of the submitted article and accompanying interstitial glucose data.

---

#### Author contribution statement

Clinical roles of authors: H T, attending acute registrar; H L, diabetes physician; C F, diabetes nurse specialist; S S, physician responsible for the patient's in-hospital care. H T and H L led the case write up and all authors reviewed the final version of the manuscript.

---

#### References

- 1 Rosemarie L, Eda C & Tanenberg RJ. The role of the new basal insulin analogs in addressing unmet clinical needs in people with type 1

- and type 2 diabetes. *Current Medical Research and Opinion* 2017 **33** 1045–1055. (<https://doi.org/10.1080/03007995.2017.1298522>)
- 2 Nakamura Y, Nagai Y, Yoza N, Ishii S, Kato H & Tanaka Y. A case of type 1 diabetes with intentional insulin overdose in which stable glycemic control was obtained by estimating the starting dose of glucose infusion. *Journal of the Japan Diabetes Society* 2017 **60** 769–774. (<https://doi.org/10.11213/tonyoby.60.769>)
- 3 Iijima T, Kase M, Sagara M, Kato K, Shimizu M, Nishida M, Tomotsune T, Tanaka S, Aoki C, Jojima T, *et al.* A case of type 1 diabetic patient who attempted suicide by overdose injection of insulin degludec and lispro. *Journal of the Japan Diabetes Society* 2015 **58** 707–714. (<https://doi.org/10.11213/tonyoby.58.707>)
- 4 Uchida J, Oikawa Y, Katsuki T, Takeda H, Shimada A & Kawai T. Insulin degludec overdose may lead to long-lasting hypoglycaemia through its markedly prolonged half-life. *Diabetic Medicine* 2018 **35** 277–280. (<https://doi.org/10.1111/dme.13557>)
- 5 Johansen NJ & Christensen MB. A systematic review on insulin overdose cases: clinical course, complications and treatment options. *Basic and Clinical pharmacology and Toxicology* 2018 (accessed 23 March 2018). (<https://doi.org/10.1111/bcpt.12957>)
- 6 Ajjan RA, Cummings MH, Jennings P, Leelarathna L, Rayman G & Wilmot EG. Accuracy of flash glucose monitoring and continuous glucose monitoring technologies: implications for clinical practice. *Diabetes and Vascular Disease Research* 2018 **15** 175–184 (accessed 23 March 2018). (<https://doi.org/10.1177/1479164118756240>)
- 7 Ahmed H, El-Laboudi AH, Misra S, Martineau M, Deol P, Sanders A & Oliver N. Intentional large insulin overdose captured on a continuous glucose monitor: a novel case report. *Journal of Diabetes Science and Technology* 2015 **9** 929–931. (<https://doi.org/10.1177/1932296815579691>)

---

Received in final form 27 March 2018

Accepted 3 May 2018