

Case Report

Traumatic L5/S1 bilateral locked facets with bilateral pars fractures – A case report

Fawwaz Bin Shahab¹, Amna Ghouri¹, Manzar Hussain¹, Sadaf Nasir²

¹Department of Neurosurgery, Liaquat National Institute of Postgraduate Studies, ²Department of Radiology, Liaquat National Hospital and Medical College, Karachi, Pakistan.

E-mail: *Fawwaz Bin Shahab - fawwazbinshahab@hotmail.com; Amna Ghouri - dr.amnaghouri@gmail.com; Manzar Hussain - manzar.hoseyn@gmail.com; Sadaf Nasir - dr.sadaf@live.com



*Corresponding author:

Fawwaz Bin Shahab,
Department of Neurosurgery,
Liaquat National Institute of
Postgraduate Studies, Karachi,
Pakistan.

fawwazbinshahab@hotmail.com

Received : 28 November 2022

Accepted : 26 May 2023

Published : 09 June 2023

DOI

10.25259/SNI_1077_2022

Quick Response Code:



ABSTRACT

Background: Although rare, traumatic lumbosacral (L/S) Grade I spondylolisthesis (i.e., Lumbar locked facet syndrome) is characterized by unilateral or bilateral facet dislocations.

Case Description: A 25-year-old male presented following a high velocity road traffic accident with back pain and tenderness at the L/S junction. His radiologic images showed bilateral locked facets at the L5/S1 level with Grade 1 spondylolisthesis, bilateral pars fractures, acute traumatic L5/S1 disc herniation, and disruption of the anterior and posterior longitudinal ligaments. After undergoing a L4-S1 laminectomy with pedicle screw fixation, he became asymptomatic and remained neurologically stable.

Conclusion: L5/S1 facet dislocation whether unilateral or bilateral needs to be diagnosed early and treated with realignment and instrumented stabilization.

Keywords: L5-S1, Lumbosacral (LS), Pars fracture, Road traffic accident (RTA), Traumatic lumbar locked facet

INTRODUCTION

Traumatic L5/S1 unilateral or bilateral facet dislocations with resultant Grade I spondylolisthesis need to be recognized early and appropriately decompressed and stabilized.^[7] Mostly facet dislocations tend to be bilateral with only few cases of unilateral facet dislocations being reported in the literature.^[2,5,10] Here, we present a 25-year-old male who sustained a road traffic accident resulting in low back pain secondary to bilateral L5/S1 locked facets and a L5/S1 disc herniation that warranted surgical decompression and stabilization.

CASE REPORT

Following a high velocity traffic accident, a 25-year-old male presented with back pain and tenderness at lumbosacral (L/S) junction but remained neurologically intact. The computed tomography (CT) scan showed bilateral locked facets at the L5/S1 level with Grade 1 spondylolisthesis, bilateral pars fractures, L5/S1 herniated disc, and disruption of the anterior/posterior longitudinal ligament [Figures 1 and 2]. The patient underwent L4-S1 decompressive

This is an open-access article distributed under the terms of the Creative Commons Attribution-Non Commercial-Share Alike 4.0 License, which allows others to remix, transform, and build upon the work non-commercially, as long as the author is credited and the new creations are licensed under the identical terms.

©2023 Published by Scientific Scholar on behalf of Surgical Neurology International

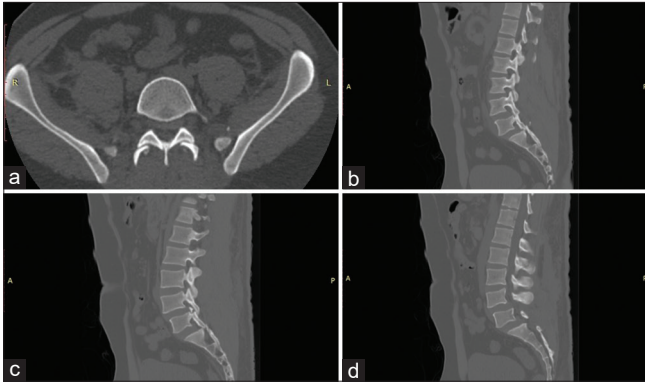


Figure 1: (a) Computed tomography (CT) scan LS spine axial cuts at L5/S1 level. (b) CT scan LS spine sagittal cut at the level of left pars. (c) CT scan LS spine sagittal cut at the level of right pars. (d) CT scan LS spine – Mid sagittal cut.

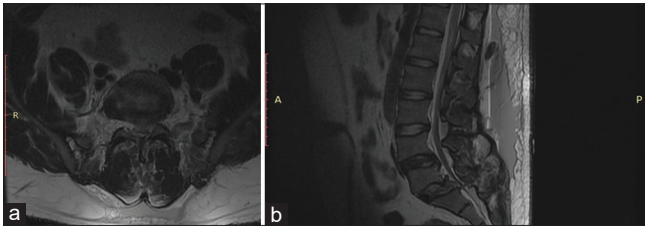


Figure 2: (a) Magnetic resonance imaging (MRI) T2 – Axial cut at L5/S1 level. (b) MRI T2 – Sagittal cut.

laminectomy with L4-S1 pedicle screw fixation. At surgery, there was a sub-fascial hematoma, significant L5/S1 disc fragment, and dural tear that required primary repair. The post-operative period was uneventful, and subsequent plain X-rays showed maintained normal realignment.

DISCUSSION

Fracture dislocations of the L/S spine are rare, with L5/S1 involvement being even less reported than L4/L5.^[4] However, most authors are of the view that significant traumatic forces, including hyperflexion, combined with some degree of distraction and rotation may cause these facets to dislocate.^[1,3,10] Multiplanar and 3D reconstruction of L/S CT aids in diagnosing vertebral locked facets at the L5/S1 level along with plain radiographs.^[12] Accompanying magnetic resonance imaging (MRI) studies look for simultaneous musculoligamentous injuries, dural tears, root injuries, and traumatic disc herniation.^[8,10]

As bilateral facet dislocations result in an unstable 3-column injury, they need to be quickly reduced, decompressed, and fused to avoid the progression or the onset of new neurological dysfunction.^[9,11] Posterior reduction typically involves drilling off the locked facets (facetectomy), or manual manipulation of the posterior elements (levering the spinous process of L5 and S1), followed by fixation of fracture

with pedicle screws.^[1] If there is an accompanying L5/S1 disc herniation (i.e., on the MRI), interbody fusion may also be necessary.^[1,6,10]

CONCLUSION

Traumatic bilateral facet fractures/dislocations, Grade I spondylolisthesis, and disc herniations at the L5/S1 level, documented with X-rays and CT studies, should be decompressed and stabilized early in the clinical course to avoid the onset of new or the progression of neurologic deficits.^[1]

Declaration of patient consent

The authors certify that they have obtained all appropriate patient consent.

Financial support and sponsorship

Nil.

Conflicts of interest

There are no conflicts of interest.

REFERENCES

1. Arnold PM, Malone DG, Han PP. Bilateral locked facets of the lumbosacral spine: Treatment with open reduction and transpedicular fixation. *J Spinal Cord Med* 2004;27:269-72.
2. Boger DC, Chandler RW, Pearce JG, Balciunas A. Unilateral facet dislocation at the lumbosacral junction. Case report and literature review. *J Bone Joint Surg Am* 1983;65:1174-8.
3. De Das S, McCreath SW. Lumbosacral fracture-dislocations. A report of four cases. *J Bone Joint Surg Br* 1981;63-B:58-60.
4. Fok KC, Cheung JP. Traumatic bilateral L4-5 facet fracture dislocation: A case presentation with mechanism of injury. *BMC Musculoskelet Disord* 2019;20:558.
5. Grivas TB, Papadakis SA, Katsiva V, Koufopoulos G, Mouzakis V. Unilateral lumbosacral dislocation: Case report and a comprehensive review. *Open Orthop J* 2012;6:473-7.
6. Im SH, Lee KY, Bong HJ, Park YS, Kim JT. Bilateral locked facets at lower lumbar spine without facet fracture: A case report. *Korean J Spine* 2012;9:278-80.
7. Konan LM, Davis DD, Mesfin FB. Traumatic lumbar spondylolisthesis. In: *StatPearls*. Treasure Island, FL: StatPearls Publishing; 2017.
8. Moon AS, Atesok K, Niemeier TE, Manoharan SR, Pittman JL, Theiss SM. Traumatic lumbosacral dislocation: Current concepts in diagnosis and management. *Adv Orthop* 2018;2018:6578097.
9. Mori K, Hukuda S, Katsuura A, Saruhashi Y, Asajima S. Traumatic bilateral locked facet at L4-5: Report of a case associated with incorrect use of a three-point seatbelt. *Eur Spine J* 2002;11:602-5.
10. Shinohara K, Soshi S, Kida Y, Shinohara A, Marumo K. A rare

case of spinal injury: Bilateral facet dislocation without fracture at the lumbosacral joint. *J Orthop Sci* 2012;17:189-93.

11. Tsirikos AI, Saifuddin A, Noordeen MH, Tucker SK. Traumatic lumbosacral dislocation: Report of two cases. *Spine (Phila Pa 1976)* 2004;29:E164-8.
12. Zheng Z, Wang S, Si D. Analysis and discussion on the facet of the spinal column, spiral CT lock multiplanar reconstruction

and 3D reconstruction. *Zhong Nan Da Xue Xue Bao Yi Xue Ban* 2015;40:1143-7.

How to cite this article: Shahab FB, Ghouri A, Hussain M, Nasir S. Traumatic L5/S1 bilateral locked facets with bilateral pars fractures – A case report. *Surg Neurol Int* 2023;14:200.

Disclaimer

The views and opinions expressed in this article are those of the authors and do not necessarily reflect the official policy or position of the Journal or its management. The information contained in this article should not be considered to be medical advice; patients should consult their own physicians for advice as to their specific medical needs.