



# Vedolizumab Therapy in Refractory Enteropathy Associated With CVID

Dane Johnson, MD<sup>1</sup>, Goo Lee, MD, PhD<sup>2</sup>, and Frederick Weber, MD<sup>1</sup>

<sup>1</sup>Division of Gastroenterology and Hepatology, University of Alabama at Birmingham, Birmingham, Alabama

<sup>2</sup>Department of Pathology, University of Alabama at Birmingham, Birmingham, Alabama

## ABSTRACT

Common variable immunodeficiency (CVID) is a disorder of typically adult-onset hypogammaglobulinemia in the absence of other known causes. Noninfectious gastrointestinal tract manifestations are common, and a subset of patients with CVID present with a severe enteropathy manifesting as severe malabsorption, weight loss, and diarrhea. A 63-year-old man presented with CVID and severe enteropathy who failed to improve with cytomegalovirus therapy, multiple empiric therapies, and corticosteroids. Vedolizumab infusions were initiated with a dramatic, rapid, and durable complete clinical response.

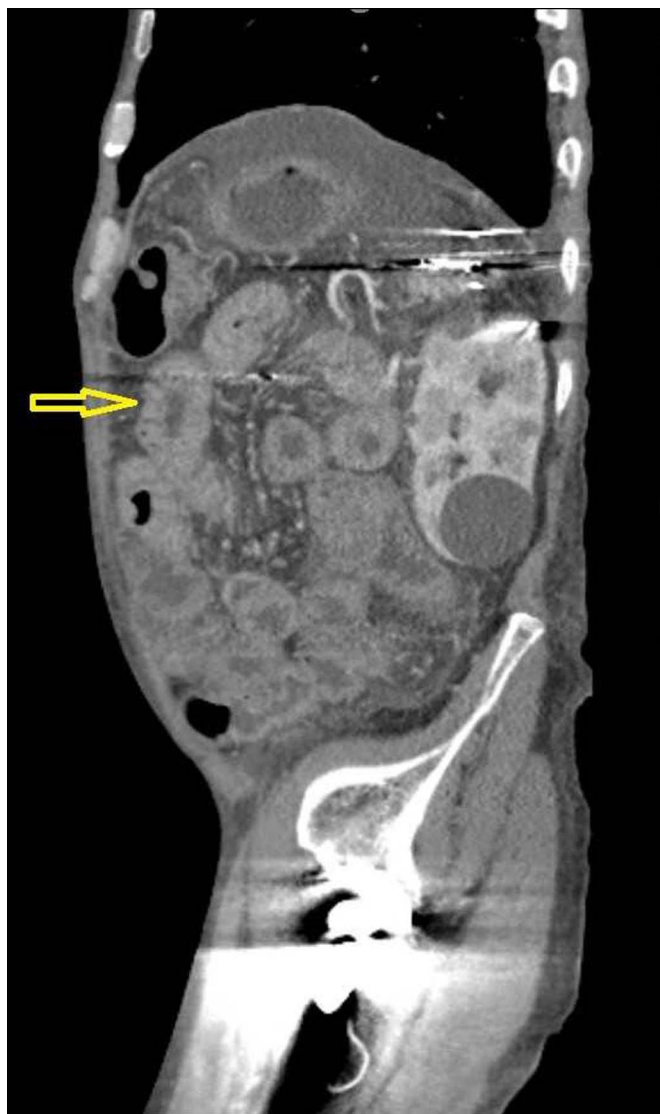## INTRODUCTION

Common variable immunodeficiency (CVID) is a disorder of typically adult-onset hypogammaglobulinemia (low IgG and either low IgA or low IgM) in the absence of other known causes and with inadequate response to validated vaccines. It is the most common adult primary immunodeficiency, affects between 1:25,000 and 1:50,000 individuals, and is associated with infectious, autoimmune, and neoplastic complications. Noninfectious luminal gastrointestinal tract manifestations occur in 15%–20% of patients with CVID and typically manifest symptomatically as bloating, abdominal pain, and diarrhea. A severe enteropathy occurs in a minority of this group and manifests with severe malabsorption, weight loss, hypoalbuminemia, and variable nongluten-dependent villous atrophy; it can require parenteral nutrition and lead to death. CVID-associated nonceliac enteropathy is unresponsive to intravenous immunoglobulin and can be corticosteroid-refractory. Therapies in this setting are not well defined in the existing literature. We report a case of severe corticosteroid refractory CVID-associated enteropathy in which a rapid, dramatic, and durable response to vedolizumab was achieved.

## CASE REPORT

A 63-year-old man with CVID remotely complicated by Burkitt lymphoma and cytomegalovirus (CMV) retinitis presented with severe refractory diarrhea, weight loss, cachexia, anasarca, and severe protein-calorie malnutrition for 6 months' duration. He reported an average of 10 high-volume watery stools per day and 16 lbs. of weight loss such that the body mass index was 17.6 on admission. Complete blood count, comprehensive metabolic panel, and infectious serologies were only notable for minimal macrocytic anemia, serum albumin 2.7 gm/dL, nonpermissive celiac genetic panel, and serum CMV polymerase chain reaction of 2,980 IU/mL, and stool studies revealed no evidence of enteric pathogens. Computed tomography enterography showed diffuse circumferential wall thickening of small bowel loops with segmental thickening of large bowel and rectum suggestive of diffuse enterocolitis (Figure 1). An initial endoscopic evaluation revealed gastroduodenal ulcerations with histologic evidence of gastric atrophy, multifocal gastric intestinal metaplasia, CMV inclusions, and paucity of plasma cells in the duodenum. An endoscopically routine colonoscopy revealed extensive CMV inclusions histologically. He was hospitalized for treatment-refractory, high-volume diarrhea, and CMV enterocolitis.

Sixteen weeks of CMV therapy with foscarnet and letermovir dropped the CMV viral load to 84 IU/mL. Despite trials of antivirals, antibiotics, bile acid binders, pancreatic enzyme replacement, antimotility agents, and a gluten-free diet, his weight loss, frequent loose stools, and anorexia persisted, and his body mass index dropped to 14.8 kg/m<sup>2</sup>. Repeat endoscopy with push enteroscopy revealed endoscopic healing of the prior mucosal ulcerations, but severe mucosal atrophy was noted. Microscopic findings from the duodenal



**Figure 1.** Sagittal view of computed tomography enterography showing diffuse circumferential wall thickening of small bowel loops with the segmental thickening of large bowel and rectum suggestive of diffuse enterocolitis. Arrow points to an area of the thickened small bowel.

biopsy revealed partial villous blunting and epithelial reactive changes (Figures 2 and 3). There are rare foci of crypt epithelial apoptosis and paucity of plasma cells within the lamina propria. No evidence of CMV inclusion was identified in hematoxylin and eosin-stained slides and CMV immunohistochemistry. Before the initiation of steroids, the patient had not been taking nonsteroidal anti-inflammatory drugs, chemotherapy, or other medications commonly associated with enteropathy. Therapy with budesonide and intravenous (IV) corticosteroids did not affect his severe symptoms, and total parenteral nutrition was initiated.

Severe persistent, refractory diarrhea and anasarca at 20 weeks after index presentation led to the initiation of vedolizumab infusions using standard induction dosing of 300 mg IV at initiation, at 2 weeks and at 6 weeks. He had rapid and dramatic

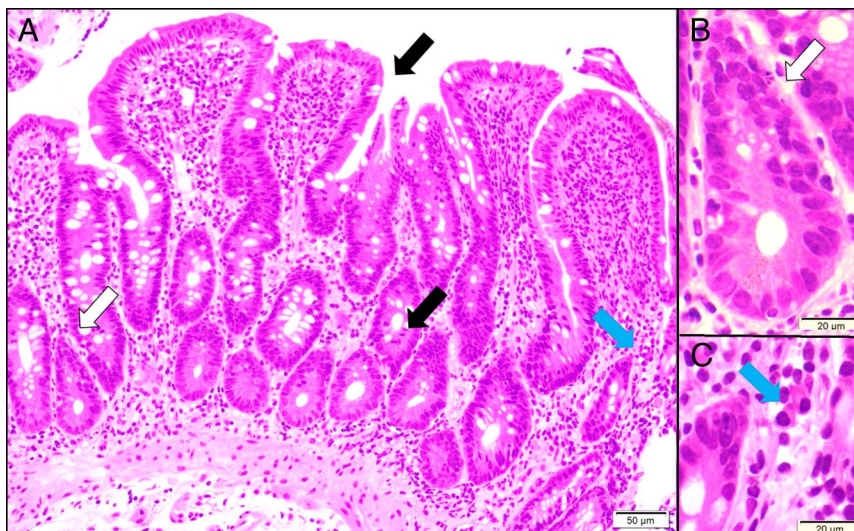
symptomatic improvement within 48 hours of the initial dose, and by the fifth day after his first dose, he was down to 1–2 well-formed bowel movements daily. After 4 weeks on vedolizumab, total parenteral nutrition was stopped, and he had gained 6 lbs. of dry weight. Serum albumin improved, and anasarca resolved. At 8 months of administration of vedolizumab, he remains asymptomatic with 1–2 well-formed bowel movements daily and has had a weight gain of 20 kg.

## DISCUSSION

Enteropathy that is inflammatory/autoimmune and noninfectious occurs in 15%–20% of patients with CVID.<sup>1</sup> Intestinal involvement can lead to the clinical and endoscopic picture of Crohn's disease, ulcerative colitis, celiac disease, or a nongluten-dependent enteropathy, which rarely can be severe with high-volume diarrhea, malabsorption, and weight loss. In these latter patients, endoscopic findings rarely show extensive ulceration. Histologic findings may include increased intraepithelial lymphocytes, villous atrophy, paucity of plasma cells, lamina propria T-cell infiltrates, nodular lymphoid hyperplasia, granulomas, or a graft-vs-host-like histologic image.<sup>2</sup>

Patients with mild enteropathy can be treated symptomatically. Notably, IV immunoglobulin is not helpful consistent with the understood pathophysiology involving abnormal T-cell rather than B-cell function. In a large cohort of 473 individuals with CVID, autoimmune or autoinflammatory conditions were as common as 68% and noninfectious gastrointestinal manifestations as common as 15.4%. Individuals with CVID enteropathy primarily complain of bloating, pain, and diarrhea.<sup>3</sup> Enteropathy associated with CVID can be resistant to a gluten-free diet and is histologically distinct from celiac disease.<sup>4</sup> Guidelines regarding the treatment of CVID enteropathy are lacking. Budesonide has been reported to be successful in case reports.<sup>5</sup> Prednisone and IV corticosteroids have considerable risks of infectious complications in this population. Immunomodulators, such as azathioprine, have shown some benefit in autoimmune enteropathy unassociated with CVID, but there is limited experience in CVID, and the lymphoma risk is problematic in a patient population already at increased risk for lymphoma. Tumor necrosis factor inhibitors, such as infliximab, have shown efficacy in limited case series, although infectious complications have been noted and are of particular concern in the setting of CVID<sup>6</sup>.

Vedolizumab, a humanized monoclonal antibody against the leukocyte  $\alpha 4\beta 7$  integrin receptor that interacts with the gut mucosal addressin cell adhesion molecule-1, is a mechanistically attractive approach in CVID enteropathy in that it affects lymphocyte trafficking to the intestinal mucosa and has a limited risk of opportunistic infections outside the gastrointestinal tract. Reports on vedolizumab therapy in severe CVID-associated enteropathy are quite limited and have shown variable results. Sifers et al<sup>7</sup> described 1 of 7 patients with sustained success after vedolizumab therapy; however, the group was

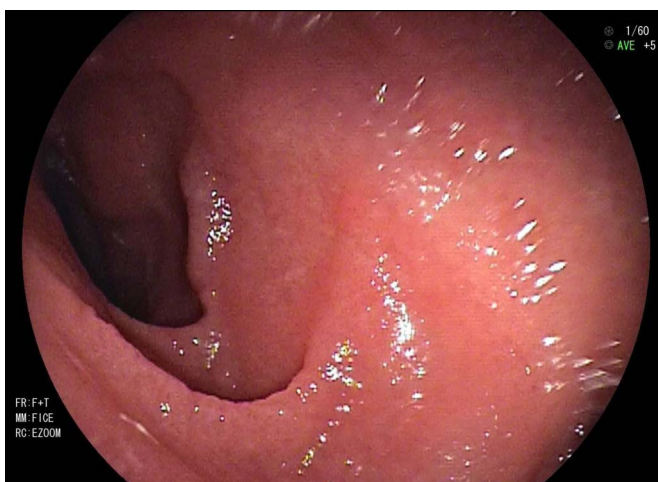


**Figure 2.** (A) Duodenal biopsy at the repeated endoscopy, hematoxylin and eosin stain. Duodenal mucosa showed partial villous blunting and epithelial reactive changes with increased mitotic activity and decreased mucin (black arrows). (B) High magnification for the white arrow in panel A indicated crypt epithelial apoptosis. (C) High magnification for the blue arrow in panel A revealed extremely rare lamina propria plasma cells (overall, 0–3 plasma cells/10 HPF). HPF, high-power field.

clinically heterogeneous, and several were later found to have infections. Another case series showed sustained improvement in 2 of 3 antitumor necrosis factor naïve patients with vedolizumab and noninfectious enteropathy; 1 of the 2 responders had a Crohn's-like phenotype, however.<sup>8</sup> High-quality trials are needed to further assess the safety and efficacy of vedolizumab. Our case highlights an early, dramatic, and durable clinical response to vedolizumab in a patient with severe CVID enteropathy refractory to corticosteroids.

## DISCLOSURES

Author contributions: D. Johnson wrote the article, approved the final article, and is the article guarantor. G. Lee and F. Weber edited the article and approved the final article.



**Figure 3.** Repeat push enteroscopy with endoscopic view of the duodenum. Previously seen endoscopic ulcers have healed, but the mucosa still shows scalloping.

Financial disclosure: None to report

Informed consent was obtained for this case report

Received April 11, 2021; Accepted July 27, 2021

## REFERENCES

- Pikkarainen S, Martelius T, Ristimäki A, Siitonen S, Seppänen MRJ, Färkkilä M. A high prevalence of gastrointestinal manifestations in common variable immunodeficiency. *Am J Gastroenterol.* 2019;114(4):648–55.
- Daniels JA, Lederman HM, Maitra A, Montgomery EA. Gastrointestinal tract pathology in patients with common variable immunodeficiency (CVID). *Am J Surg Pathol.* 2007;31(Issue 12):1800–12.
- Jørgensen SF, Reims HM, Frydenlund D, et al. A cross-sectional study of the prevalence of gastrointestinal symptoms and pathology in patients with common variable immunodeficiency. *Am J Gastroenterol.* 2016;111(10):1467–75.
- Malamut G, Verkarre V, Suarez F, et al. The enteropathy associated with common variable immunodeficiency: The delineated frontiers with celiac disease. *Am J Gastroenterol.* 2010;105(10):2262–75.
- Elnachef N, McMorris M, Chey WD. Successful treatment of common variable immunodeficiency disorder-associated diarrhea with budesonide: A case report. *Am J Gastroenterol.* 2007;102(6):1322–5.
- Chua I, Standish R, Lear S, et al. Anti-tumour necrosis factor- $\alpha$  therapy for severe enteropathy in patients with common variable immunodeficiency (CVID). *Clin Exp Immunol.* 2007;150(2):306–11.
- Sifers T, Hirten R, Mehandru S, Ko HM, Colombel JF, Cunningham-Rundles C. Vedolizumab therapy in common variable immune deficiency associated enteropathy: A case series. *Clin Immunol.* 2020;212:108362.
- Boland BS, Riedl MA, Valasek MA, Crowe SE, Sandborn WJ. Vedolizumab in patients with common variable immune deficiency and gut inflammation. *Am J Gastroenterol.* 2017;112(10):1621.

**Copyright:** © 2021 The Author(s). Published by Wolters Kluwer Health, Inc. on behalf of The American College of Gastroenterology. This is an open access article distributed under the terms of the Creative Commons Attribution-Non Commercial-No Derivatives License 4.0 (CCBY-NC-ND), where it is permissible to download and share the work provided it is properly cited. The work cannot be changed in any way or used commercially without permission from the journal.