

Reverse graft suturing to avoid Descemet's membrane detachment of glycerol-preserved donor cornea used for therapeutic penetrating keratoplasty during COVID-19 to overcome the tissue shortage – A novel surgical technique

Niveditha Narayanan

To overcome tissue shortage during pandemic, we switched to 100% glycerol preservation of the donor cornea, which is economical and provides longer duration of storage than the short and intermediate storage mediums we normally use like McCAREY Kaufman (MK) or cornisol. During our initial few cases of therapeutic penetrating keratoplasty using glycerol preserved donor cornea, we faced spontaneous Descemet's detachments resistant to air tamponade. We tried reverse graft suturing and successfully reinforced Descemet's attachment along with air tamponade, in one of the cases after multiple failed air injections. In the subsequent two cases of infective keratitis needing therapeutic penetrating Keratoplasty, we took eight reverse sutures in between the eight cardinals, to anchor the Descemet's membrane of the graft. Both the grafts showed attached Descemet's and maintained good graft clarity. The reverse corneal suturing technique has not been described to the best of our knowledge and hope this helps our corneal fraternity.

Key words: Covid-19, Descemet's membrane detachment, glycerol-preserved donor cornea, reverse suturing, therapeutic penetrating keratoplasty

Video Available on:
www.ijo.in

Access this article online

Website:
www.ijo.in

DOI:
10.4103/ijo.IJO_2570_21

Quick Response Code:



The worldwide normal donor corneal utility in eye banks is approximately 50%, with maximal usage of optical grades and underutilized therapeutic grades. During the pandemic, many eye banks in India switched to longer duration of storage to compensate for tissue shortage caused by reduced retrieval.^[1,2] The glycerol-preserved donor cornea (GPC) was first introduced by J. H. Singh, who performed the first lamellar keratoplasty using GPC in the year 1961.^[3] GPC is an ideal choice for nonoptical keratoplasty like therapeutic (TPK) in infective keratitis, tectonic, or lamellar keratoplasty. Delayed epithelial healing and persistent stromal edema are the known complications using GPC. We encountered three cases of spontaneous Descemet's detachment (DMD) post TPK using GPC for infective keratitis during pandemic. We tried reverse graft suturing in one of the cases along with air tamponade and succeeded in reattaching the Descemet membrane (DM) (case 1). So in the subsequent two TPKs using GPC, we did reverse graft suturing primarily and no DMD occurred (cases 2 and 3). We report our experience in this work that was approved by our hospital review board and abides the tenets of Helsinki. All our study patients were explained the nature of the procedure, and they duly signed the informed consent.

Cornea and Refractive Services, Medical Research Foundation, Chennai, Tamil Nadu, India

Correspondence to: Dr. Niveditha Narayanan, No 21, Pycrofts Garden Road, Nungambakkam, Chennai - 600 018, Tamil Nadu, India. E-mail: drnvn@snmail.org

Received: 05-Oct-2021
Accepted: 10-Jan-2022

Revision: 02-Nov-2021
Published: 25-Feb-2022

Case Reports

Case 1

A 66-year-old man came with total corneal ulcer that occurred after injury at construction site 15 days back. Corneal scraping grew aerobic Gram-negative bacillus *Burholderia Cepacia*; he underwent TPK with GPC and the corneal button grew *Fusarium* species. On the second week post TPK, he suddenly developed a gradually increasing DMD, for which he underwent air tamponade twice with no improvement [Fig. 1a]. Desperate to find a solution on the third attempt of air injection at 1 month post TPK, reverse corneal suturing in between radial sutures was taken randomly, to anchor the DM.

Intraoperative examination with handheld spectral domain ophthalmic imaging system (Bioptigen Inc.) confirmed the attachment which was also maintained in the postoperative period [Fig. 1b-d].

This is an open access journal, and articles are distributed under the terms of the Creative Commons Attribution-NonCommercial-ShareAlike 4.0 License, which allows others to remix, tweak, and build upon the work non-commercially, as long as appropriate credit is given and the new creations are licensed under the identical terms.

For reprints contact: WKHLRPMedknow_reprints@wolterskluwer.com

Cite this article as: Narayanan N. Reverse graft suturing to avoid Descemet's membrane detachment of glycerol-preserved donor cornea used for therapeutic penetrating keratoplasty during COVID-19 to overcome the tissue shortage – A novel surgical technique. *Indian J Ophthalmol* 2022;70:1042-6.

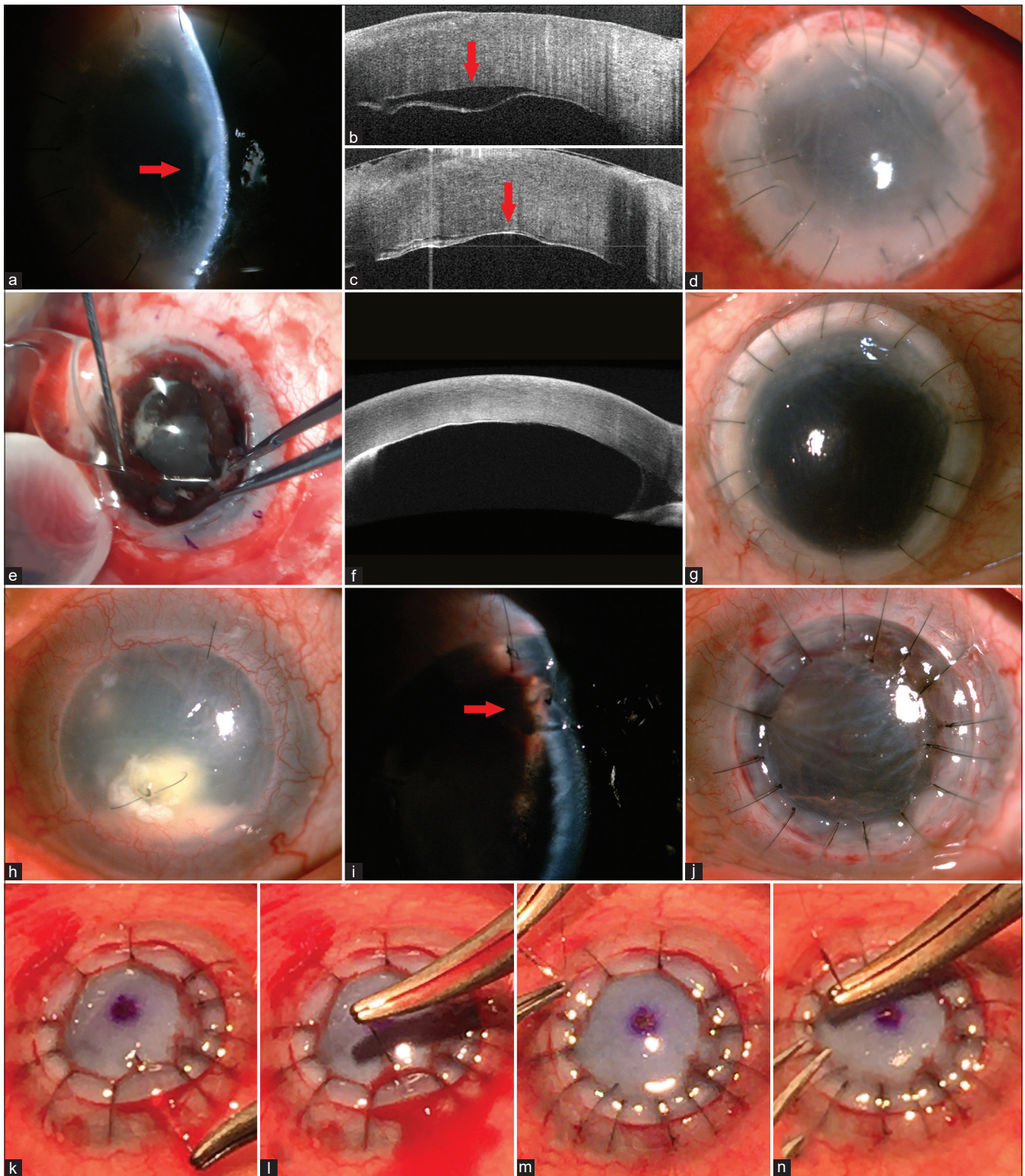


Figure 1: (a) Case 1: slit view of DMD. (b) Case 1: Intra-op Bioptigen of DMD. (c) Case 1: Bioptigen post attached. (d) Case 1: failing graft at 1 month. (e) Case 2: IOL explantation. (f) Case 2: 1 month ASOCT of attached DM. (g) Case 2: clear graft at 1 month. (h) Case 3: infected graft. (i) Case 3: arrow at iris incarceration. (j) Case 3: clear graft at 40 days. (k) Partial thickness host bite at inferior quadrant. (l) Full thickness graft bite the same site. (m) Partial thickness host bite at superior quadrant. (n) Full thickness bite at the same site

Case 2

A 55-year-old female with corneal scar, from an ulcer treated locally 8 years back, came to our hospital for visual rehabilitation,

and had optical PK and extracapsular cataract surgery with IOL implantation in 2014. She underwent complete graft suture removal a year later and maintained 6/15 vision for 6 years.

She stopped topical steroids during pandemic, due to local nonavailability of drugs and reported to us 1 month later, with graft rejection. Though the initial intensive topical and systemic steroids arrested the graft rejection, lack of proper follow-up during the lockdown period caused the situation to escalate to a total graft melt with extruding IOL. When she underwent IOL explantation with TPK using GPC, we did primary reverse suturing [Fig. 1e-g], by applying our experience learned from the previous case. Both the explanted IOL and corneal button showed negative microbiological results.

Case 3

A 74-year-old man came to us for visual rehabilitation with a total corneal opacity that he developed after endophthalmitis postcataract surgery done 1.5 years back elsewhere. He underwent optical PK and his vision improved up to 6/9 that he maintained with regular follow-up for 5 years. During pandemic, he could not maintain regular follow-up, and due to nonavailability of medication in the lock down period, he stopped topical treatment. He reported to us with total graft failure of approximately 2 months duration, then further developed persistent epithelial defect, for which, he underwent amniotic membrane transplantation. With continued lockdown, his follow-ups became more irregular, and he later reported with multiple graft infiltrates due to methicillin-resistant *Staphylococcus epidermidis*. With persistent ulcer in spite of appropriate medical management, we did TPK using GPC along with primary reverse suturing [Fig. 1h-j].

Surgical Technique

We use 100% glycerol prepared by adding 3 g of aluminosilicate molecular sieves (0.2–0.8 mm, Sorbead India) to 5 mL of glycerol (100%) (Molecular biology grade, HiMedia, India) for donor corneal preservation and store it between 2 and 8°C for up to 1 year. All the GPC used in this case series were initially stored in MK medium for 4 days, later in cornisol for 10 days, then transferred to 100% glycerol, and were utilized within 10 days. The age of the corneal donor were 78, 82, and 70 years with specular counts of 2590, 2353, and 2610 cells/mm² for the cases 1–3, respectively. Intraoperatively, GPC was immersed in normal saline to thaw and wash away residual glycerol for 30 min prior to usage. In the case 1 with spontaneous DMD after two failed attempts of air tamponade [Fig. 1a], eight reverse sutures were taken wherever possible, in-between the radial sutures along with air tamponade to reattach DM. Intraoperatively, a handheld spectral domain ophthalmic imaging system (Bioptigen Inc.) was used to confirm the proper DM attachment [Fig. 1b and c]. In the subsequent two cases, where primary reverse suturing was done, the usual steps for TPK was followed up to the stage of eight cardinal sutures. These were briefly as follows: general anesthesia for case 2 and local for case 3, fleringa ring fixation in both, host corneal trephination of 10 mm in case 2 and 8 in case 3, punching oversized donor corneas by 1.0 mm in case 2 and 0.5 in case 3, additional intraocular manipulations as needed, including clearing of exudative debris, cautery of possible bleeders, debridement of nonviable iris tissue and two surgical peripheral iridectomies in both, while IOL explantation with limited anterior vitrectomy in case 2 [Fig. 1e], and retention of IOL in case 3 and finally donor graft anchoring with eight radial sutures using 9-0 nylon in case 2 and 10-0 in case 3. Then, the anterior chamber was reasonably formed with saline and

further suturing depended on the size of the graft. For case 2 with 11 mm graft, two sutures were placed in between each cardinal suture, and one out of the two was a reverse suture. For the case 3 with 8.5 mm graft, the next eight were reverse sutures, taken one in between each cardinal suture. The reverse suture bite starts from the host cornea as a partial thickness bite of 90% depth [Fig. 1k and m] and then continues as a full thickness bite of donor GPC to anchor the DM [Fig. 1l and n]. Care should be taken to avoid iris looping into the host corneal bite by avoiding a full thickness bite and while suturing the GPC by lifting the cornea rather than pressing to anchor DM for the full thickness bites [Fig. 2 and Video 1]. The reverse bite usually ends up being longer than the routine ones. Intracameral voriconazole 50 µgm in 0.1 mL of normal saline for case 1, and vancomycin 1 mg in 0.1 mL of normal saline for cases 2 and 3 were injected. At the end of suturing, all the three cases were stained with moistened strips impregnated with 0.6 mg of fluorescein sodium to check for leaks, identified by dye dilution upon gentle pressure around the suture tract. Detailed postoperative medical management is beyond the scope of this article, but all were maintained on appropriate antimicrobials and adjuvants and none had a recurrent infection up to 3 months postsurgery now.

Results

Case 1 showed attached DM after the reverse suturing combined with the third attempt of air tamponade. Topical steroids were not initiated in this case due to the fungal etiology of the infective keratitis and the graft eventually failed [Fig. 1d]. This patient reported a month later with perforated graft, underwent tectonic PK using a donor cornea stored in MK medium, as it was available, and the removed GPC button showed negative microbiological results. For cases 2 and 3, after epithelial healing, topical prednisolone acetate 1% (Pred Forte; Allergan, Inc., Irvine, California, USA) was started at 8 times per day dosage initially and then tapered weekly. Case 2 was aphakic, maintained good graft clarity, responded well to systemic

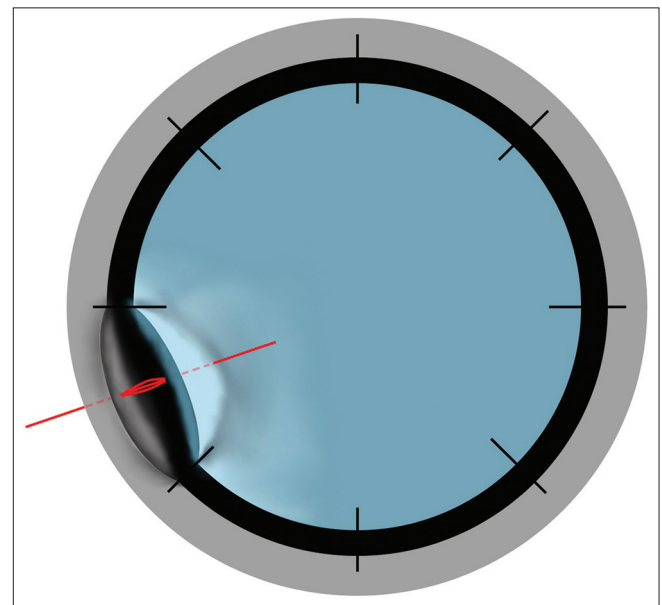


Figure 2: The diagram shows partial thickness bite of host cornea, thread passing through the GHJ, and full thickness bite of the gently lifted edge of the graft

steroids started for choroidal detachment, and her vision pre TPK of PR accurate improved to CFCF [Fig. 1g] at 3 months. Case 3 was pseudophakic, had a better graft clarity, attached retina, and improved from CFCF preop to 6/18 postop [Fig. 1j]. None of the patients had postoperative suture leaks at the site of reverse suture bites or at the graft host junction; checked under slit-lamp bio microscopy, observed with cobalt blue filter, after surface staining with moistened strips impregnated with 0.6 mg of fluorescein sodium. Absence of the leak using GPC could be attributed to the biomechanical stiffness and the varying parallelism of collagen as noted by Wei Chen study.^[4] We considered therapeutic success as anatomical restoration and eradication of infection, and therapeutic failure as loss of globe integrity and recurrence of infection post TPK using GPC. Our first patient achieved partial therapeutic success due to graft perforation though no recurrent infection occurred, but the other two cases achieved therapeutic success, maintained up to 3 months post TPK. Only one out of the three patients achieved good visual improvement, while the first two patients failed to benefit visually.

Discussion

In order to optimize the corneal tissue utilization, a longer duration of corneal preservation is crucial, since it avoids wastage due to nonusage. Among the longer duration of corneal preservation, like the cryopreservation, lyophilization, organ culture, or the gamma radiation, the glycerol preservation has many good attributes. It is relatively inexpensive, easily adaptable by eye banks, does not require specialized instruments, and gives a wide option of storing from room temperature to sub-zero up to -80°C .^[5] It is well documented from the skin and the bone banking that glycerol preservation provides good antimicrobial property.^[6-9] GPC will not induce graft rejection as it is devoid of cells including the epithelium, keratocytes, and the bone marrow-derived cells, which form the major histocompatibility complex antigens and minor H antigens.^[10] The introduction of glycerol corneal preservation started as an experiment in feline eyes by J H Singh, who later started human corneal preservation using 95% glycerol under vacuum to ensure its anhydrous state. In 1961, he achieved glycerol dehydration by adding sodium and calcium alumina silicates as a physical adsorptive agents, obviating the cumbersome vacuum system.^[11] These molecular sieves are synthetic crystals absorbing and trapping water molecules in their pores, thereby dehydrating glycerol. J H Singh performed the first LK after achieving reasonable dehydration of the glycerol preserved corneas.^[3]

When using GPC for PK, poor graft clarity needing subsequent optical PK and persistent epithelial defect are the most commonly known complications. However, when we started using GPC for emergency TPK during pandemic, we encountered spontaneous DMD around a week in the postoperative period, though well attached DM was documented in the early postop days. GPC is thicker and acellular, specifically with the absence of endothelium, which can make it prone for DMD which calls for careful tissue handling. Additionally, the repeated failure to reattach the DM, after attempts of air tamponade could be attributed to the absence of healthy endothelial pump function in GPC. With the acute shortage in donor corneal tissue and increasing emergency cases needing TPK, we resorted to the desperate

attempt of reverse graft suturing along with the third attempt of air injection in one of the initial cases. When we found success with this approach, our preventive reverse suturing in the subsequent two cases was better executed with proper radial placement of sutures in between the cardinal sutures and both had attached DM with good graft clarity up to the last follow-up of 3 months. The mechanical anchoring by the reverse sutures might prevent an easy separation of the DM in GPC lacking endothelium, especially in the initial postop period, when major inflammatory changes occur in the anterior chamber after TPK.

Specific indications for GPC can be lamellar surgery not needing viable endothelium,^[3] corneal melt or perforation needing tectonic support using stiffer cornea with low immunogenicity to neutralize host's persistent inflammation,^[12] therapeutic PK utilizing antimicrobial property of GPC for medically uncontrolled infective keratitis, and PK in poor prognosis eyes with multiple rejections. There are other indications that need to be explored like, as a K-pro bearer reducing graft melts with biomechanically stiffer and less immunogenic GPC. Another area that can be explored is, as a patch graft to cover tube exposure in glaucoma implants, since stiffer GPC especially stored in room temperature,^[7] can be easily trimmed to the desired thickness, and its translucency can be cosmetically more appealing than the white scleral patch grafts visible sub-conjunctivally. In nonseeing eyes with corneal leucoma, which are unsuitable for cosmetic contact lenses, LK using GPC with lamellar corneal tattoo can optimize cosmesis with lesser chances of rejection. Further, varying properties like transmittance, translucence, stiffness, decellularization, anti-immunogenicity, and varying collagen parallelism of GPC with different storage techniques as proven by Wei Chen *et al.* can also be optimized to the needs.^[4] This will help us form proper prevention protocols to optimize GPC usage for the intended surgical goal. Though our novel surgical technique can open up opportunities of GPC usage in certain situations, successful outcome of more number of cases is preferred. The present increase in level of corneal retrieval prevents us from including more cases, hence forming our study limitation. However, by sharing our limited experience, it could prove to be handy, in view of future uncertainties created by the pandemic.

Conclusion

This method of reverse corneal suturing will be useful to avoid DMD when TPK is done using GPC. Though the resultant graft clarity is not good enough to annul the need for optical PK, it can still enhance the chamber visibility, to better titrate postop antimicrobial treatment. Further studies with a bigger sample size and longer duration of follow-up can further shed light on the other aspects of this technique.

Financial support and sponsorship

Nil.

Conflicts of interest

There are no conflicts of interest.

References

1. Chaurasia S, Das S, Roy A. A review of long-term corneal preservation techniques: Relevance and renewed interests in the

- COVID-19 era. *Indian J Ophthalmol* 2020;68:1357-63.
2. Das S, Chaurasia S, Fernandes M, Murthy S. Corneal transplantation and eye banking practices during COVID19-related lockdown period in India from a network of tertiary eye care centers. *Indian J Ophthalmol* 2020;68:2368-71.
 3. King JH Jr, McTigue JW, Meryman HT. Preservation of corneas for lamellar keratoplasty: A simple method of chemical glycerine-dehydration. *Trans Am Ophthalmol Soc* 1961;59:194-201.
 4. Li J, Shi S, Zhang X, Ni S, Wang Y, Curcio CA, Chen W. Comparison of different methods of glycerol preservation for deep anterior lamellar keratoplasty eligible corneas. *Invest Ophthalmol Vis Sci* 2012;53:5675-85.
 5. Roy A, Chaurasia S, Fernandes M, Das S. Impact of nationwide COVID-19 lockdown on keratoplasty and eye banking in India: A survey of cornea surgeons and eye banks. *Indian J Ophthalmol* 2021;69:706-8.
 6. Saegeman VSM, Ectors NL, Lismont D, Verduyck B, Verhaegen J. Short- and long-term bacterial inhibiting effect of high concentrations of glycerol used in the preservation of skin allografts. *Burns* 2008;34:205-11.
 7. Van Baare J, Ligtvoet EEJ, Middelkoop E. Microbiological evaluation of glycerolised cadaveric donor skin. *Transplantation* 1998;65:966-70.
 8. Giovani AMM, Croci AT, Oliveira CRGCM, Filippi RZ, Santos LAU, Maragni GG, *et al.* Comparative study of cryopreserved bone tissue and tissue preserved in a 98% glycerol solution. *Clinics (Sao Paulo)* 2006;61:565-70.
 9. Tomford WW. Bone allografts: Past, present and future. *Cell Tissue Bank* 2000;1:105-9.
 10. Tripathi H, Mehdi MU, Gupta D, Sen S, Kashyap S, Nag TC, *et al.* Long-term preservation of donor corneas in glycerol for keratoplasty: Exploring new protocols. *Br J Ophthalmol* 2016;100:284-90.
 11. McNair JN, King JH. Preservation of cornea by dehydration. *Arch Ophthalmol* 1955;53:519-21.
 12. Lin H-C, Ong SJ, Chao AN. Eye preservation tectonic graft using glycerol-preserved donor cornea. *Eye (Lond)* 2012;26:1446-50.