

A novel homozygous mutation of the calcium-sensing receptor gene associated with apparent autosomal recessive inheritance of familial hypocalciuric hypercalcemia

Nan Li^{1,2}, Xiang Li³, Xiao-Lin Ni³, Xiu-Ying Li^{1,4}, Wei-Bo Xia³, Guo-Qing Yang¹, Yu Pei¹

¹Department of Endocrinology, The First Medical Center, Chinese PLA General Hospital, Beijing 100853, China;

²Department of Endocrinology, The Second Medical Center, Chinese PLA General Hospital, Beijing 100853, China;

³Department of Endocrinology, Key Laboratory of Endocrinology, Ministry of Health, Peking Union Medical College Hospital, Chinese Academy of Medical Science, Beijing 100730, China;

⁴Department of Endocrinology, Liangxiang Teaching Hospital, Capital Medical University, Beijing 102401, China.

To the Editor: Familial hypocalciuric hypercalcemia (FHH) comprises a group of rare hereditary disorders of calcium homeostasis, characterized by lifelong hypercalcemia, usually asymptomatic, and inappropriately low urinary calcium excretion. FHH is genetically heterogeneous. The majority of cases are FHH1, due to inactivating mutations in the calcium-sensing receptor (*CASR*) gene on chromosome 3. FHH2 and FHH3 are due to inactivating mutations in the G protein subunit alpha 11 gene and adaptor related protein complex 2 subunit sigma 1 gene separately.

CASR is the key sensor for extracellular calcium. It plays an important role in regulating parathyroid hormone (PTH) secretion and calcium handling. More than 200 loss-of-function *CASR* mutations have been described previously.^[1] Inactivating mutations in the *CASR* gene elevate the set point of receptor activation by extracellular calcium give rise to hypercalcemia disorders (FHH) and neonatal severe hyperparathyroidism (NSHPT). Patients with severely inactivating *CASR* mutations develop NSHPT with excessive PTH secretion that is not suppressed by elevated serum calcium levels. In contrast, patients with only mild impairment of *CASR* function develop FHH. However, the genotype-phenotype correlation has not been clearly documented.

Herein, we present an acute pancreatitis-onset case of FHH1 caused by homozygous mutation in the *CASR* gene and review the challenging clinical course that reveals the difficulties in the management of this condition. The present study was approved by the Medical Ethics Committee of the Chinese People's Liberation Army

General Hospital (S2017-131-02). Written informed consent was obtained from the patient and his family members for publication of this case report and any accompanying images.

A 12-year-old boy presented to the emergency department with abdominal pain and vomit. He was diagnosed with acute pancreatitis. Laboratory tests showed hypercalcemia (4.70 mmol/L; reference range: 2.09–2.54 mmol/L) and inappropriately normal PTH (26 pg/mL, reference range: 12–88 pg/mL). After feeding restriction, fluid infusion, acid suppression, and other symptomatic supportive treatment, he was cured of pancreatitis. But his hypercalcemia was sustained. Salmon calcitonin injection and fluid infusion were still given to him. Additional tests showed a hypermetabolic nodule located beneath the thyroid and in front of the trachea. He was transferred to the endocrinology department for further diagnosis and therapy.

During the endocrinology evaluation, he reported the following symptoms: a 12-month history of fatigue; bone pain in the bilateral heel. He denied headache, polydipsia, polyuria, constipation, and a history of kidney stones. The past medical and surgical histories were unremarkable. He was born by cesarean section due to intra-uterine distress. He was diagnosed with “cerebral palsy” at 14 months old because he cannot sit alone until 12 months old and still could not walk at 14 months old. Then, he received regular hyperbaric oxygen therapy until 3 years old. He can speak some words when he was 2 years old and can walk independently at 2 and a half years old. The time of eruption and replacement of deciduous teeth was similar to peers. There was no specific family history.

Access this article online

Quick Response Code:



Website:
www.cmj.org

DOI:
10.1097/CM9.0000000000001568

Correspondence to: Yu Pei, Department of Endocrinology, The First Medical Center, Chinese PLA General Hospital, Beijing 100853, China
E-Mail: baby.toe@163.com

Copyright © 2021 The Chinese Medical Association, produced by Wolters Kluwer, Inc. under the CC-BY-NC-ND license. This is an open access article distributed under the terms of the Creative Commons Attribution-Non Commercial-No Derivatives License 4.0 (CCBY-NC-ND), where it is permissible to download and share the work provided it is properly cited. The work cannot be changed in any way or used commercially without permission from the journal.

Chinese Medical Journal 2021;134(15)

Received: 31-01-2021 Edited by: Li-Shao Guo

On physical examination, vital signs and anthropometric measurements were as follows: pulse rate, 76 beats/min; blood pressure, 116/78 mmHg (50th percentile for both systolic and diastolic); weight, 68 kg (>97th percentile); height, 164 cm (>90th percentile). He had a rolling gait without any deformities.

The X-ray examinations of bilateral limbs, skull, spine, and hip did not show any fractures, periarticular erosions, or other bone lesions. Ultrasound of kidneys revealed bilateral kidneys were of normal appearance. Ultrasound of neck showed moderately echogenic nodule beneath the thyroid gland, parathyroid gland origination likely. Further biochemical tests confirmed hypercalcemia (4.00 mmol/L; reference range: 2.09–2.54 mmol/L), inappropriate normal PTH (49.19 pg/mL, reference range: 15.00–65.00 pg/mL), and low urinary calcium excretion (fractional excretion of calcium were 1.07%, 0.05%, and 0.09% on three separate tests).

CASR gene sequencing showed a homozygous mutation in exon 2 (c.178T>G) [Figure 1A], which had generated a substitution of the amino acid cysteine (TGT) to glycine (GGT) at codon 60 (p.C60G). DNA sequence abnormalities could be identified by comparisons with the reference sequence (RefSeq accession number NM_000388.4). We investigated mutant CASR protein function prediction using the online protein prediction program Mutation T@sting (<http://www.mutationaster.org/>) and Polyphen (<http://genetics.bwh.harvard.edu/pph>) [Figure 1D]. Both of these predicted that the substitution of the amino acid glycine at codon 60 to glycine would affect this protein's function.

Pedigree investigation showed that his parents were heterozygous of the same CASR gene mutation [Figure 1B and 1C]. Serum calcium levels of his parents

were normal but overall high (2.42 and 2.47 mmol/L for father and mother; reference range: 2.09–2.54 mmol/L). PTHs were both in the normal range. Fractional excretion of calcium were 0.78% and 1.08%.

We prescribed fluid infusion and alendronate to treat his hypercalcemia. And his serum calcium can be sustained under 3.50 mmol/L.

FHH1 is usually a heterozygous condition with only one mutated CASR allele and an autosomal dominant pattern of inheritance. Homozygous inactivating CASR mutations usually cause NSHPT, which is characterized by severe symptomatic hypercalcemia in the first week of life and high mortality.^[1] The excessively elevated PTH plays an important role in the pathophysiology of NSHPT, therefore, parathyroidectomy has to be performed early in life to correct their clinical symptoms.^[1] The proband of the present study experienced severe hypercalcemia with inappropriately normal PTH and hypocalciuria, which conform to FHH1-like clinical phenotype.

Our proband's parents are both heterozygous of the c.178T>G mutation and both with normal serum calcium in the upper level. Their urine calcium and 25-hydroxyvitamin D levels were both very low. It cannot be concluded that vitamin D deficiency leads to normal serum calcium. With our current information, we cannot rule out an autosomal recessive manner of FHH1 in this family, because the genotypes and phenotypes of other family members are inaccessible. Although FHH1 is generally considered to be an autosomal dominant pattern of inheritance, an autosomal recessive pattern of inheritance with both mutated CASR alleles, has also been reported in six families.^[2] Q459R mutation was discovered in two families, whereas the other four families harbored a P39A, Q27R, L13P, and E671D CASR mutant, respectively.

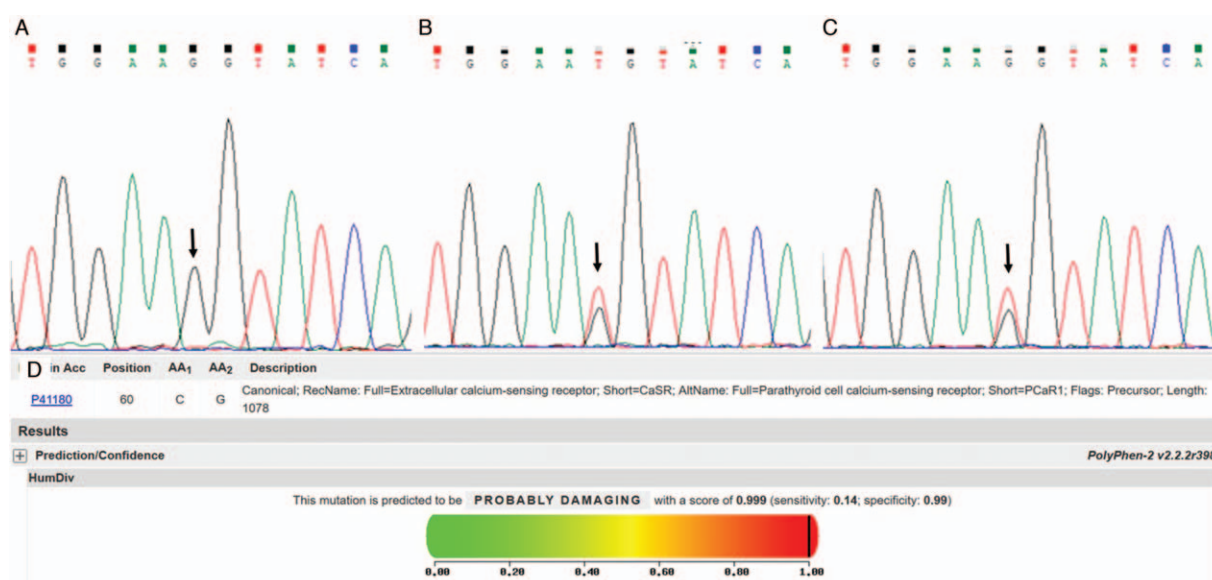


Figure 1: Genetic analysis of CASR in the proband and his parents. Mutation analysis revealed a missense mutation of exon 2 (c.178T>G, p.C60G) on the CASR in the proband (A). A sequence of the proband's father (B) and mother (C) were heterozygous at the same position. (D) Prediction of the impact of p.C60G mutation on the structure and function of the CASR protein using PolyPhen2 showed "probably damaging." CASR: Calcium-sensing receptor.

Functionally, P39A, Q27R, and L13P mutations showed a greater degree of impairment than the other two mutations. Patients with homozygous P39A, Q27R, and L13P mutations appeared to have higher levels of serum calcium (3.50–4.20 mmol/L) when compared with patients with homozygous Q459R and E671D (2.90–3.25 mmol/L). Functional studies showed that P39A and Q27R mutants have some residual activity, L13P mutant activity was severely impaired due to in part to decreased cell surface expression. On the contrary, a mutant of Q459R indicated a 30% to 50% reduction in calcium-dependent activity without expression reduction. It seems that even missense inactivation mutation, the location of the mutation affects protein function and then the clinical phenotype.

CASR protein is a G-protein coupled receptor that has three domains (extracellular, transmembrane, and intracellular). The residue 60 is located in the extracellular domain (ECD) and is one of the 19 cysteine residues of ECD. CASR contains 19 cysteine residues, 17 of which are in ECD, and transmits the signal from the calcium-binding domain to intracellular signaling pathways. The 17 cysteine residues are conserved in mammalian CASRs including human, bovine, rat, and rabbit. And they play an important role in the structure and function of CASR protein. Dimerization is significant to the CASR function. Previous studies showed that mutants of cysteine at codon 60 do affect the expression and dimer formation of the protein, which is critical for signal transduction. Although C60G was not reported previously, mutants of codon 60 have been reported. Patients with heterozygous C60F and C60R exhibited FHH1 clinical phenotype.^[3]

FHH was considered to be a benign course, because symptoms may be frequent but usually mild. Subtotal parathyroidectomy is always followed by persistent hypercalcemia, and it is not recommended. Total parathyroidectomy in FHH is recommended only in some severe cases^[4] on account of leading to hypoparathyroidism and need calcium and calcitriol supplement for life long. Past recommendations for use of medications were rarely or against. Calcimimetic drugs, such as cinacalcet, are allosteric agonist at CASR. They have been approved in adults with primary hyperparathyroidism (PHPT) without surgical option or PHPT resulting from parathyroid carcinoma. Their safety and efficacy in children under 18 years old are not established yet. And the cost of cinacalcet might be another limitation in the long-term use

in FHH1. To reduce blood calcium and prevent recurrent pancreatitis, bisphosphonates can be used in FHH1 patients. However, when the patients' serum calcium returned to the normal range, PTH increased significantly. Therefore, the dosage of the bisphosphonates should be adjusted to decrease the serum calcium and inhibit bone resorption. The family of our proband cannot afford the expense of cinacalcet. Thus, we prescribed the patient alendronate and monitored his symptoms as well as serum calcium level. During the follow-up of about 2 months, his serum calcium can be sustained under 3.50 mmol/L without pancreatitis occurrence.

Our study further extends the heterogeneity of biochemical phenotypes associated with CASR mutations and provides evidence for FHH1 inheritance as an autosomal recessive pattern. The efficacy and safety of long-time bisphosphonates treatment in FHH1 should be further studied.

Acknowledgements

The authors thank the patient and all his family members for their cooperation.

Conflicts of interest

None.

References

1. Lee JY, Shoback DM. Familial hypocalciuric hypercalcemia and related disorders. *Best Pract Res Clin Endocrinol Metab* 2018;32:609–619. doi: 10.1016/j.beem.2018.05.004.
2. Borsari S, Marcocci C, Cetani F. Familial hypocalciuric hypercalcemia type 1 due to a novel homozygous mutation of the calcium-sensing receptor gene. *J Endocrinol Invest* 2017;40:1271–1272. doi: 10.1007/s40618-017-0710-2.
3. García-Castaño A, Madariaga L, Pérez de Nanclares G, Ariceta G, Gaztambide S, Castaño L. Novel mutations associated with inherited human calcium-sensing receptor disorders: a clinical genetic study. *Eur J Endocrinol* 2019;180:59–70. doi: 10.1530/EJE-18-0129.
4. Khairi S, Osborne J, Jacobs MF, Clines GT, Miller BS, Hughes DT, *et al.* Outcome of clinical genetic testing in patients with features suggestive for hereditary predisposition to PTH-mediated hypercalcemia. *Horm Cancer* 2020;11:250–255. doi: 10.1007/s12672-020-00394-2.

How to cite this article: Li N, Li X, Ni XL, Li XY, Xia WB, Yang GQ, Pei Y. A novel homozygous mutation of the calcium-sensing receptor gene associated with apparent autosomal recessive inheritance of familial hypocalciuric hypercalcemia. *Chin Med J* 2021;134:1869–1871. doi: 10.1097/CM9.0000000000001568