

Defining the Location of the Adductor Canal Using Ultrasound

Wan Yi Wong, MMed, MBBS,* Siska Bjørn, MS,† Jennie Maria Christin Strid, MD,‡
Jens Børglum, MD, PhD,‡ and Thomas Fichtner Bendtsen, MD, PhD†

Background and Objectives: The precise location of the adductor canal remains controversial among anesthesiologists. In numerous studies of the analgesic effect of the so-called adductor canal block for total knee arthroplasty, the needle insertion point has been the midpoint of the thigh, determined as the midpoint between the anterior superior iliac spine and base of patella. “Adductor canal block” may be a misnomer for an approach that is actually an injection into the femoral triangle, a “femoral triangle block.” This block probably has a different analgesic effect compared with an injection into the adductor canal. We sought to determine the exact location of the adductor canal using ultrasound and relate it to the midpoint of the thigh.

Methods: Twenty-two volunteers were examined using ultrasound. The proximal end of the adductor canal was identified where the medial border of the sartorius muscle intersects the medial border of the adductor longus muscle. The distal end of the adductor canal is the adductor hiatus, which was also visualized ultrasonographically.

Results: The mean distance from the anterior superior iliac spine to the midpoint of the thigh was 22.9 cm (range, 20.3–24.9 cm). The mean distance from the anterior superior iliac spine to the proximal end of the adductor canal was 27.4 cm (range, 24.0–31.4 cm). Consequently, the mean distance from the midpoint of the thigh to the proximal end of the adductor canal was 4.6 cm (range, 2.3–7.0 cm).

Conclusions: In all volunteers, the midpoint of the thigh was proximal to the beginning of the adductor canal, suggesting that an injection performed at this level is in fact a femoral triangle block.

(*Reg Anesth Pain Med* 2017;42: 241–245)

The exact location of the adductor canal (AC) in the thigh is a matter of debate among anesthesiologists.^{1–4} The location of the AC has become a subject of increasing interest owing to the success of the ultrasound-guided adductor canal block (ACB) for postoperative analgesia after total knee arthroplasty.^{5–7}

An early presentation of a saphenous nerve block in the adductor canal was by Manickham et al⁸ who identified the adductor hiatus using ultrasound; and hence, this distal approach

represents an injection into the true adductor canal. Lund et al introduced a more proximal approach at the midhigh level, defined by anatomical surface landmarks as the midpoint between the anterior superior iliac spine (ASIS) and the base of patella. This approach has become the well-known “ACB.”^{6,9–11}

It is a common notion that the AC is located in the middle of the thigh and that an injection at the midhigh is indeed an injection into the middle of the AC. However, an injection at the midhigh can be into the AC or in the femoral triangle (FT), depending on how the thigh is demarcated. In addition, anatomical variation can make surface landmarks unreliable determinants of the location of the AC.⁴

To explore the clinical effect of the FT block versus the anatomically true ACB, it is necessary to review the exact definitions of the 2 different anatomical regions as well as the various nerves that transverse them.

The FT, also known as “Scarpa's triangle,” is a large triangular space in the proximal part of the thigh.¹² It is bounded by the inguinal ligament proximally, the medial border of the sartorius muscle laterally, and the medial border of the adductor longus muscle medially. The floor of the FT consists of the iliopsoas muscle laterally and the pectineus and adductor longus muscles medially with a small contribution from the adductor brevis muscle.¹² An important internal landmark of the proximal end of the AC is the apex of the FT, which is defined as the intersection between the medial border of the sartorius muscle and the medial border of the adductor longus muscle, which is clearly visualized on ultrasound (Fig. 1).³ The femoral vessels and the femoral nerve run in the proximal part of the FT.³ The branches of the femoral nerve that innervate the anteromedial part of the knee—the saphenous nerve, medial vastus nerve, and medial femoral cutaneous nerve—pass through almost the entire length of the FT from its base to the apex after they branch off the femoral nerve.

The AC is a musculoaponeurotic tunnel from the apex of the FT to the adductor hiatus, between the vastus medialis muscle anterolaterally and the adductor longus and adductor magnus muscles posteromedially. It is roofed in its entire length by the vastoadductor membrane (VAM).^{1,3,4,13} Views conflict regarding the nerves found within the AC. The saphenous nerve is consistently found in the AC. The medial femoral cutaneous nerve runs within the FT and joins the subsartorial plexus between the VAM and the sartorius muscle distal to the apex of the FT.¹² The medial vastus nerve is asserted to lie within the AC in some anatomical textbooks, but cadaver studies specifically studying the trajectory of the medial vastus nerve prove otherwise.^{4,14,15} The medial vastus nerve travels within its own fascial sheath, separate from the AC.^{4,16,17} Özer et al¹⁷ demonstrated that within the FT, the medial vastus nerve was found near the femoral vessels and femoral nerve. However, just proximal to the AC, the medial vastus nerve enters a separate bilayered fascial sheath, distinct from the AC.

This is of clinical significance, as the medial vastus nerve contributes significantly to the innervation of the anteromedial aspect of the knee through its intramuscular, extramuscular, and deep genicular nerves.^{18,19} Therefore, a block of the medial vastus nerve is probably equally important as the saphenous nerve block

From the *Department of Anesthesiology, Intensive Care and Pain Medicine, Tan Tock Seng Hospital, Singapore; †Department of Anesthesiology and Intensive Care Medicine, Aarhus University Hospital, Aarhus, Denmark; and ‡Department of Anesthesiology and Intensive Care Medicine, Zealand University Hospital, University of Copenhagen, Copenhagen, Denmark. Accepted for publication October 12, 2016.

Address correspondence to: Thomas Fichtner Bendtsen, MD, PhD, Department of Anesthesiology, Aarhus University Hospital, Nørrebrogade 44, DK-8000 Aarhus, Denmark (e-mail: tfb@dadlnet.dk).

The authors declare no conflict of interest.

Copyright © 2016 The Author(s). Published by Wolters Kluwer Health, Inc. on behalf of the American Society of Regional Anesthesia and Pain Medicine. This is an open-access article distributed under the terms of the Creative Commons Attribution-Non Commercial-No Derivatives License 4.0 (CCBY-NC-ND), where it is permissible to download and share the work provided it is properly cited. The work cannot be changed in any way or used commercially without permission from the journal.

ISSN: 1098-7339

DOI: 10.1097/AAP.0000000000000539

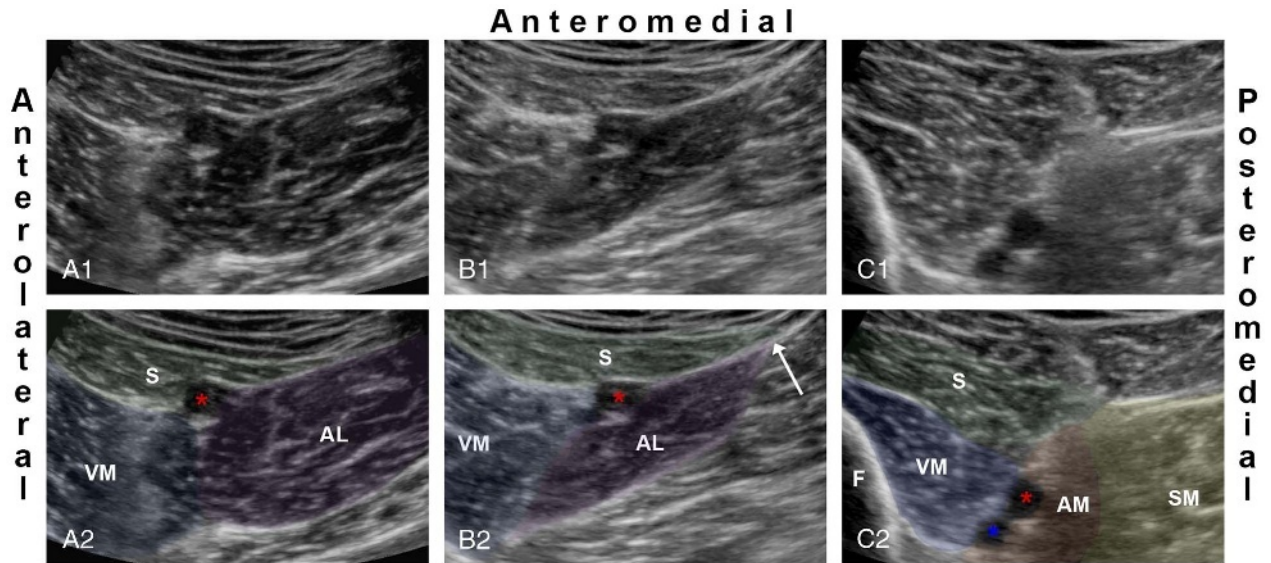


FIGURE 1. The first row shows three ultrasound images at different levels. The second row shows the identical ultrasound images with color markings. A1 and A2 are at the level of the femoral triangle (FT) corresponding to the red arrows in Figure 2. B1 and B2 depict the beginning of the AC defined as the apex of the FT, where the medial border of the sartorius muscle intersects the medial border of the adductor longus muscle (white arrow in B2). This level corresponds to the blue arrows in Figure 2. C1 and C2 depict the distal end of the AC corresponding to the green arrows in Figure 2. AL (purple), adductor longus muscle; AM (orange), adductor magnus muscle; asterisk (blue), femoral artery; asterisk (red), femoral artery; F, femur; S (green), sartorius muscle; SM (yellow), semimembranosus muscle; VM (blue), vastus medialis muscle.

for effective analgesia after a total knee arthroplasty; and an injection specifically delivered into the AC will likely not anesthetize the medial vastus nerve.¹⁷

To the best of our knowledge, no reports or studies have illustrated the correlation between the surface landmarks and ultrasonographic identification of the proximal and distal ends of the AC. This is relevant for the regional anesthesiologist to ensure the accurate placement of a nerve block. Therefore, the aim of this study was to examine and identify the exact location of the AC with ultrasound guidance in relation to the midpoint of the thigh, defined as the midpoint between the ASIS and the base of patella.

METHODS

Twenty-two volunteers with American Society of Anesthesiologists (ASA) physical status I were recruited during a randomized, controlled, clinical trial prospectively approved by the regional ethics committee (MJ: 1-10-72-368-15). The Danish Ethics Committee approved that the additional data sampling for the present separate study did not require additional prior approval. Written, informed consent and demographic data were obtained from all subjects.

The lower limb that was not part of the concurrent clinical trial was chosen for measurements for the purpose of this study. The subjects' thighs were exposed from the ASIS to the patella in the supine position. The distance from the ASIS to the base of patella was measured, and the midpoint of the thigh was marked as the half-distance between the ASIS and the base of patella (Fig. 2). The ultrasound probe (Sonosite X-Porte 5–2 MHz; FUJIFILM SonoSite Inc, Bothell, Washington) was then placed medially and proximally just below the inguinal crease, and the entire trajectory of the femoral artery was scanned systematically. The femoral artery was first identified inside the FT, with the sartorius muscle anteromedially, the vastus medialis muscle

anterolaterally, and the adductor longus posteromedially (Fig. 1A and Fig. 2). The probe was slid distally along the trajectory of the femoral artery until the medial border of the sartorius muscle intersected the medial border of the adductor longus muscle, which is defined as the apex of the FT (Fig. 1B). The AC begins right at the apex of the FT, and this reference point is easy to identify with ultrasound.^{4,18} This point was marked on all subjects (Fig. 1B and Fig. 2). The femoral artery was traced further distally until it diverged from the sartorius muscle between the medial vastus and adductor magnus muscles and exited through the adductor hiatus into the popliteal fossa (Fig. 1C). The adductor hiatus is the distal end of the AC, and it was marked on the thigh (Fig. 2).

The distance from the ASIS to the base of patella and the distance from the ASIS to the midpoint of the thigh were measured in all subjects. The distances from the ASIS to the proximal and distal ends of the AC were also measured (Fig. 2). From these measurements, the distance from the midpoint of the thigh to the beginning of the AC as well as the length of the AC was calculated. Data were analyzed using Stata 13.1 (StataCorp LP, College Station, Texas). Normality of distribution of continuous variables was assessed with Q-Q plots. Continuous normally distributed variables are presented as mean and range, continuous non-normally distributed variables are presented as medians and interquartile range, and categorical variables are presented as count (%).

RESULTS

Thirteen male and 9 female healthy volunteers were included in this study (Table 1). The proximal and distal ends of the AC were ultrasonographically identifiable in all subjects. Table 2 displays the measurements of the length and midpoint of the thigh, the proximal end and length of the AC, and the distance from the midpoint of the thigh to the proximal end of the AC.

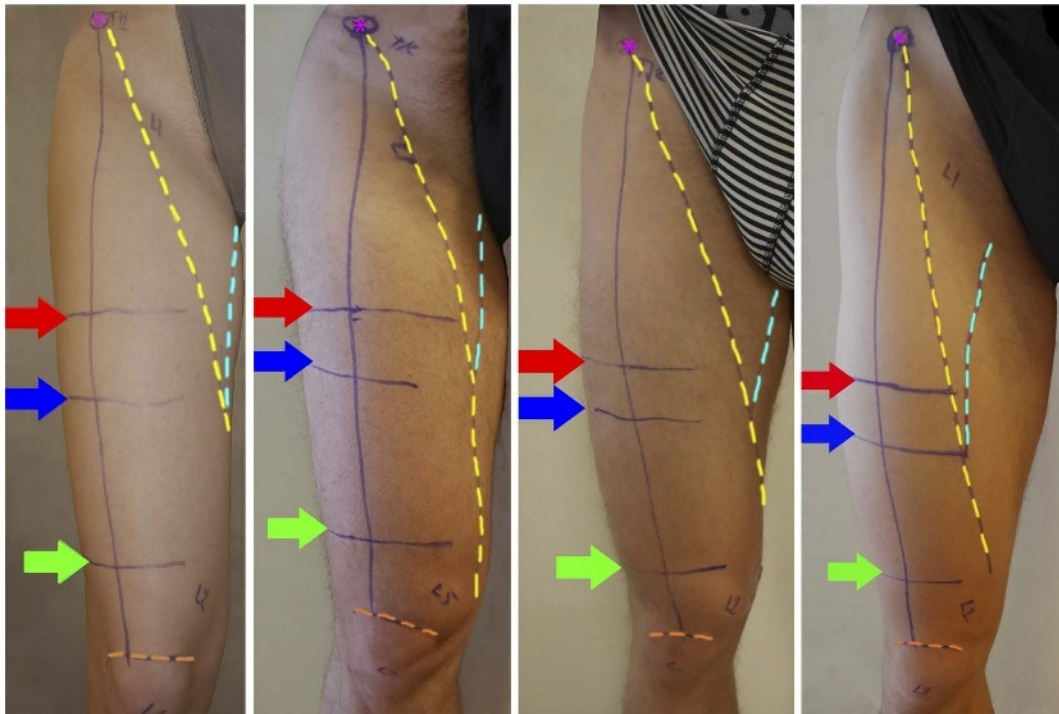


FIGURE 2. The figure shows the thighs of 4 volunteers. The midpoint of the thigh (red arrow) is defined as half the distance between the ASIS (pink asterisk) and the base of patella (orange stippled line) corresponding to the ultrasound images in Figure 1A. The proximal end of the AC (blue arrow) is defined by the intersection of the medial border of the sartorius muscle (yellow stippled line) and the medial border of the adductor longus muscle (cyan stippled line) corresponding to the ultrasound images in Figure 1B. The distal end of the AC is defined as the adductor hiatus (green arrow) corresponding to the ultrasound images in Figure 1C.

The proximal end of the AC was distal to the midpoint of the thigh in all 22 subjects (Table 2).

DISCUSSION

In this study, the proximal end of the AC was located distal to the midpoint of the thigh, defined as half the distance between the ASIS and base of patella, in all of the 22 subjects.

A recent cadaver study by Anagnostopoulou et al²⁰ showed similar results. The proximal end of the AC defined as the “superior foramen of the adductor canal” was distal to the midpoint of the thigh in 13 of the 17 dissected specimens.²⁰ The mean distance from the midpoint of the thigh to the superior foramen of the AC was 6.5 cm (range, 1.8–10.0 cm) compared to 4.6 cm (range, 2.3–7.0 cm) in our study.²⁰ Tubbs et al¹³ also performed a dissection study in 16 specimens and reported a mean distance from the ASIS to the proximal border of the VAM of 28.0 cm

(range, 20.0–32.0 cm). The AC is roofed by the VAM in its entire length, and hence the proximal border of the VAM marks the beginning of the AC. Consequently, the results from the cadaver study corresponds very well with the results seen in the present study, where the mean distance from the ASIS to the ultrasonographically identified proximal end of the AC was 27.4 cm (range, 24.0–31.4 cm).

We recognize that ultrasonography is a different technique for identification of the proximal and distal ends of the AC compared to cadaver dissection, and this technical difference may produce slightly different results despite the easy ultrasonographic recognition of the AC. This difference in methods may explain the four specimens in the study by Anagnostopoulou et al, where the beginning of the AC was proximal to the midpoint of the thigh.²⁰

TABLE 1. Demographics

n = 22	
Age, y	23 [22–24]
Sex, male	13 (59%)
Weight, kg	73 (54–93)
Height, cm	177.3 (157–195)

Continuous non-normal variables are presented as median [IQR].
 Categorical variables are presented as count (%).
 Continuous normal variables are presented as mean (range).

TABLE 2. Measurements of the Location of the Adductor Canal

n = 22	Mean	Range
Length of thigh, cm	45.7	40.5–49.8
Midpoint of thigh, cm	22.9	20.3–24.9
Proximal end of AC, cm	27.4	24.0–31.4
Midpoint of thigh to proximal end of AC, cm	4.6	2.3–7.0
Length of AC, cm	11.5	8.9–14.5

Length of thigh, the distance from ASIS to the base of patella; midpoint of thigh, half the distance from ASIS to the base of patella; proximal end of the AC, the distance from ASIS to start of AC; length of AC, the distance from proximal end of AC to the distal end of AC (adductor hiatus).

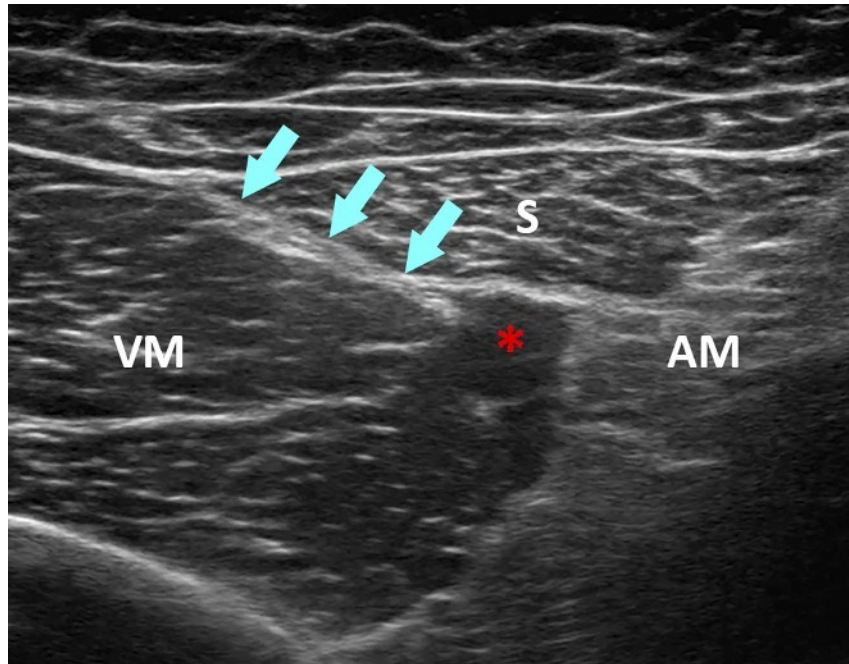


FIGURE 3. The figure shows the ultrasonographic visualization of the adductor canal with the characteristic double contour of the VAM (cyan arrows). AM, adductor magnus muscle; femoral artery (red asterisk); S, sartorius muscle; VM, vastus medialis muscle.

Nonetheless, we can conclude from these cadaver studies as well as from the present study that the midpoint of the thigh is at the level of the FT; and hence, the proximal end of the AC is distal to the midpoint of the thigh in most human beings.

Ultrasound is a useful clinical tool to identify the apex of the FT and the location of the AC. The point where the medial border of the sartorius muscle intersects the medial border of the adductor longus muscle marks the beginning of the AC, which is clearly seen in most human beings using ultrasound (Fig. 1B). The distal end of the AC is identified by the femoral vessels exiting at the adductor hiatus to become the popliteal vessels between the tendons of the adductor magnus muscle (Fig. 1C). The ultrasonographic visualization of the VAM with the characteristic double contour was also visible in most of the subjects (Fig. 3). This can be used as an additional ultrasonographic confirmation of the location of the AC. We recognize most regional anesthesiologists use ultrasound to guide needle insertion from the skin to the target nerve. However, many use surface landmarks rather than ultrasound to identify the level of injection. The most commonly applied surface landmark used to identify the location of the AC is the midpoint between ASIS and base of patella,^{6,9–11} which is proved to be a biased proxy marker of the AC by our results.

The FT and the AC were easily recognized in all our subjects, and we deem ultrasound to be more accurate than the use of surface landmarks to identify the actual location of the AC. Most studies investigating the “ACB” describe the injection as performed at the midpoint between the ASIS and the base of patella, which is not into the AC but in the FT in all studied subjects (Table 2; Fig. 1A and Fig. 2).

An injection at the midhigh level produces an effective block of the femoral nerve branches that innervate the anteromedial part of the knee. Based on our observations, this is mainly an FT injection (Fig. 1A and Fig. 2).^{5,6} Consequently, “ACB” is a misnomer for midhigh blocks that are actually in the FT. It could be speculated that a true ACB may not produce the same effective analgesia after total knee arthroplasty if the medial vastus nerve is an

important contributor to knee innervation. In addition, an injection of a small volume of local anesthetic into the distal part of the true AC can be speculated to spread into the popliteal fossa and anesthetize the posterior branch of the obturator nerve and the popliteal plexus, which provide intra-articular innervation of the knee.⁴ An injection of a large volume of local anesthetic into the FT at the midhigh level may spread proximally and anesthetize the quadriceps' motor branches of the femoral nerve, whereas a large volume injected into the true adductor canal may spread via the popliteal fossa to the sciatic nerve.²¹ Paralysis of the quadriceps femoris and the muscles of the leg would impede ability to ambulate and increase the risk of fall.

The need for a clinical trial comparing the effects of an FT block with a true ACB remains.

CONCLUSIONS

In this study of 22 volunteers, the proximal end of the AC was consistently distal to the midpoint of the thigh. Consequently, an injection at the midpoint between ASIS and the base of patella is in fact an FT block, whereas as true ACB requires a more distal approach. Furthermore, the proximal and distal ends of the AC are easily identified using ultrasound, which is a more reliable method to identify the exact location of the AC compared to surface landmarks and measurements.

REFERENCES

1. Bendtsen TF, Moriggl B, Chan V, Pedersen EM, Børglum J. Defining adductor canal block. *Reg Anesth Pain Med.* 2014;39:253–254.
2. Jaeger P, Lund J, Jenstrup MT, Brøndum V, Dahl JB. Reply to Dr Bendtsen. *Reg Anesth Pain Med.* 2014;39:254–255.
3. Bendtsen TF, Moriggl B, Chan V, Børglum J. Basic topography of the saphenous nerve in the femoral triangle and the adductor canal. *Reg Anesth Pain Med.* 2015;40:391–392.

4. Bendtsen TF, Moriggl B, Chan V, Børglum J. The optimal analgesic block for total knee arthroplasty. *Reg Anesth Pain Med.* 2016;41:711–719.
5. Jæger P, Nielsen ZJ, Henningsen MH, Hilsted KL, Mathiesen O, Dahl JB. Adductor canal block versus femoral nerve block and quadriceps strength: a randomized, double-blind, placebo-controlled, crossover study in healthy volunteers. *Anesthesiology.* 2013;118:409–415.
6. Jæger P, Zaric D, Fomsgaard JS, et al. Adductor canal block versus femoral nerve block for analgesia after total knee arthroplasty: a randomized, double-blind study. *Reg Anesth Pain Med.* 2013;38:526–532.
7. Sørensen JK, Jæger P, Dahl JB, Gottschau B, Stephensen SL, Grevstad U. The isolated effect of adductor canal block on quadriceps femoris muscle strength after total knee arthroplasty: a triple-blinded, randomized, placebo-controlled trial with individual patient analysis. *Anesth Analg.* 2016;122:553–558.
8. Manickam B, Perlas A, Duggan E, Brull R, Chan VW, Ramlogan R. Feasibility and efficacy of ultrasound-guided block of the saphenous nerve in the adductor canal. *Reg Anesth Pain Med.* 2009;34:578–580.
9. Lund J, Jenstrup MT, Jæger P, Sørensen AM, Dahl JB. Continuous adductor-canal-blockade for adjuvant post-operative analgesia after major knee surgery: preliminary results. *Acta Anaesthesiol Scand.* 2011;55:14–19.
10. Jenstrup MT, Jæger P, Lund J, et al. Effects of adductor-canal-blockade on pain and ambulation after total knee arthroplasty: a randomized study. *Acta Anaesthesiol Scand.* 2012;56:357–364.
11. Andersen HL, Gym J, Møller L, Christensen B, Zaric D. Continuous saphenous nerve block as supplement to single-dose local infiltration analgesia for postoperative pain management after total knee arthroplasty. *Reg Anesth Pain Med.* 2013;38:106–111.
12. Cunningham DJ, Robinson A. *Cunningham's Text-book of Anatomy.* Edinburgh: Henry Frowde; 1915.
13. Tubbs RS, Loukas M, Shoja MM, Apaydin N, Oakes WJ, Salter EG. Anatomy and potential clinical significance of the vastoadductor membrane. *Surg Radiol Anat.* 2007;29:569–573.
14. Agur AMR, Dalley AF. *Grant's Atlas of Anatomy.* 12th ed. Philadelphia, PA: Lippincott Williams & Wilkins, 2009; 383.
15. Standring S. *Gray's Anatomy.* 39th ed. Edinburgh, UK: Elsevier Churchill Livingstone; 2005:1470.
16. Andersen HL, Zaric D. Adductor canal block or midhigh saphenous nerve block: same same but different name! *Reg Anesth Pain Med.* 2014;39:256–257.
17. Özer H, Tekdemir I, Elhan A, Turanlı S, Engebretsen L. A clinical case and anatomical study of the innervation supply of the vastus medialis muscle. *Knee Surg Sports Traumatol Arthrosc.* 2004;12:119–122.
18. Burckett-St Laurant D, Peng P, Giron Arango L, et al. The nerves of the adductor canal and the innervation of the knee: an anatomic study. *Reg Anesth Pain Med.* 2016;41:321–327.
19. Kennedy JC, Alexander II, Hayes KC. Nerve supply of the human knee and its functional importance. *Am J Sports Med.* 1982;10:329–335.
20. Anagnostopoulou S, Anagnostis G, Saranteas T, Mavrogenis AF, Paraskeuopoulos T. Saphenous and infrapatellar nerves at the adductor canal: anatomy and implications in regional anesthesia. *Orthopedics.* 2016;39:e259–e262.
21. Goffin P, Lecoq JP, Ninane V, et al. Interfascial spread of injectate after adductor canal injection in fresh human cadavers. *Anesth Analg.* 2016;123:501–503.