



OPEN ACCESS

# Episode of mixed mood with psychotic features secondary to Binswanger disease: a case report with a literature review

Bernadette Mdawar ,<sup>1</sup> Christina Abi Faraj,<sup>2</sup> Munir Khani,<sup>1</sup> Wael Shamseddeen <sup>1</sup>

► Additional material is published online only. To view please visit the journal online (<http://dx.doi.org/10.1136/bcr-2020-238957>).

<sup>1</sup>Department of Psychiatry, American University of Beirut Medical Center, Beirut, Lebanon  
<sup>2</sup>Faculty of Medicine, American University of Beirut, Beirut, Lebanon

## Correspondence to

Dr Wael Shamseddeen; [ws11@aub.edu.lb](mailto:ws11@aub.edu.lb)

BM and CAF contributed equally.

Accepted 10 February 2021

## SUMMARY

Neurodegenerative and mood disorders in the geriatric population might exhibit interchangeable cognitive and behavioural symptoms. This overlap in presentation might raise a diagnostic challenge for psychiatrists evaluating elderly patients who are presenting with such symptoms. Additionally, there is limited data published about early psychiatric manifestations of neurodegenerative disorders in the elderly. We report a case of a 71-year-old with a history of refractory depressive disorder and multiple cardiovascular risk factors presenting with verbalisation of suicidal and homicidal intent as well as mixed mood and psychotic symptoms. The patient was diagnosed with Binswanger's disease (BD). We also provide a literature review of challenging early psychiatric presentations of neurocognitive disorders and a summary of similar cases to help facilitate diagnosis of BD cases in future.

## BACKGROUND

Neurocognitive and mood disorders in the elderly population have interchangeable symptoms. Mixed and depressive mood, behavioural problems such as disinhibition, aggression and cognitive decline are common presentations of both disorders.<sup>1</sup> They also share common cerebrovascular etiopathology.

Late-onset bipolar disorder is often associated with secondary neurologic causes.<sup>2</sup> The evidence of high prevalence of white matter (WM) hyperintensities on MRI among patients with late-onset bipolar disorder supports the vascular mania hypothesis.<sup>3-4</sup> In turn, cerebrovascular disease causes cognitive dysfunction and vascular dementia (VaD), the second most common form of dementia after Alzheimer's disease (AD).<sup>5</sup> Subcortical ischaemic vascular dementia (SIVD) is one form of VaD caused by the occlusion of small vessels resulting in WM ischaemia and multiple lacunar infarctions in subcortical structures.<sup>5</sup>

Data about psychiatric manifestations of SIVD are scarce and outdated unlike data on cognitive and other neurological manifestations. Hence, we present a case of late-onset mixed episode with psychotic features associated with a progressive cognitive impairment secondary to a rare type of SIVD. An informed consent was obtained from patient's next of kin given that he passed away at the time of writing the case. A review of the available literature will follow.

## CASE PRESENTATION

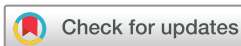The patient was 71-year-old white middle eastern veteran, separated from his wife and children, and living alone with the assistance of his personal companion for daily life activities. He was referred to the emergency department (ED) for admission by his psychiatrist after he had presented to the clinic with a loaded gun threatening to kill his wife and himself. Over the previous 2 months, the patient was having progressive worsening of his chronic low mood and irritability, passive suicidal ideations and impulsive behaviours as evident by spending money excessively and hyperphagia. He also started expressing homicidal thoughts towards his wife if she refused to come back home despite their separation for the previous 10 years.

In the ED, the patient was anxious, irritable, minimally cooperative with staff and exhibited very labile affect. His speech was excessive and disorganised with tangential thoughts and flight of ideas. He also exhibited grandiose and paranoid delusions and perseverated about political topics and marital conflicts.

Home medications included Clomipramine Sustained Release (SR) 75 mg/day, bromazepam 3 mg two times per day and quetiapine 25 mg as needed for anxiety; however, he had a history of medication misuse and noncompliance. Past psychiatric history was positive for benzodiazepine and alcohol use disorder at age 36 after cardiac catheterisation, though, at time of presentation, he had been abstinent from alcohol for more than 10 years. He also had a history of hypertension (HTN) and excessive smoking. At age 37, he was diagnosed with major depressive disorder and underwent a full course of electroconvulsive therapy. As of age 45, patient was hospitalised two times for two distinct depressive episodes after which he continued treatment on outpatient basis for residual depressive symptoms and other behavioural problems affecting his marital relationship and leading to separation.

## INVESTIGATIONS

Investigations done in the ED showed a haemoglobin of 10.3 g/dL, Mean Corpuscular Volume (MCV) of 77.4 fL, an Red Cell Distribution Width (RDW) of 16.8%. Chemistries were relevant for a creatinine level of 1.3 mg/dL, a potassium of 2.8 mmol/L and a magnesium of 1.5 mg/dL. After hydration, electrolytes correction and medical clearance, patient was admitted to psychiatry inpatient unit (PIU) for a



© BMJ Publishing Group Limited 2021. Re-use permitted under CC BY-NC. No commercial re-use. See rights and permissions. Published by BMJ.

**To cite:** Mdawar B, Abi Faraj C, Khani M, et al. *BMJ Case Rep* 2021;**14**:e238957. doi:10.1136/bcr-2020-238957

likely mixed mood episode with psychotic features and for safety concerns due to his suicidal and homicidal thoughts.

While on PIU, repeated electrolytes were normal. Patient continued to have irritable low mood with labile affect. He also exhibited sexually disinhibited behaviours, agitation and aggression towards staff and other patients. In addition, he started reporting intermittent olfactory hallucinations that resolved the next day and were related to his paranoid delusions.

Thus, cognitive testing was performed, and he scored 27/30 on mini-mental status examination and 9 on the frontal assessment battery with deficit mainly on domain of inhibitory control, conceptualisation and sensitivity interference. Orientation, attention, concentration, declarative and procedural memory were within normal limits. Neurology team was consulted, and neurological examination was relevant for impaired abstraction, perseveration and broad-based shuffling gait. Otherwise, sensory, motor and cranial nerve examinations were all normal.

Finally, a brain MRI with gadolinium was done (figure 1), and it showed increased fluid attenuated inversion recovery (FLAIR) signal intensity in the periventricular and subcortical WM, advanced degree of small vessel ischaemic disease and mild diffuse supratentorial atrophy slightly more prominent in frontal lobes. Those findings were suggestive of Binswanger disease (BD)/ dementia. Additionally, few old microbleeds were seen in the right temporo-occipital region and a tiny one in posterior aspect of left temporal lobe. Additional work up showed sinus tachycardia on electrocardiogram (EKG), dyslipidaemia with an LDL: 164 mg/dL, a triglycerides level of 116 mg/dL and an atherosclerotic cardiovascular risk of 34%.

#### DIFFERENTIAL DIAGNOSIS

- ▶ BD.
- ▶ AD.
- ▶ Lewy body dementia.
- ▶ Argyrophilic grain disease.

#### TREATMENT

During his hospitalisation, clomipramine and bromazepam were tapered off with adequate monitoring for possible withdrawal signs. On the other hand, to address his manic and psychotic symptoms, patient was started on carbamazepine XR 200 mg adjusted to single nightly dose after levels of 9.9. The choice of carbamazepine, although considered an alternative rather than first-line treatment, depended on its lower propensity to cause weight gain and, therefore, metabolic side effect when compared with first-line medications. This is particularly relevant given our patient's metabolic syndrome that included obesity (BMI:31), HTN and dyslipidaemia. Risperidone was also initiated and maintained at 2 mg nightly. Other medications were added to control his cardiovascular risk factors: hydrochlorothiazide 12.5 mg/day, telmisartan-amlodipine 80–10 mg/day, atorvastatin 40 mg, bisoprolol fumarate 2.5 mg/day, clopidogrel bisulphate 75 mg/day.

#### OUTCOME AND FOLLOW-UP

Patient remained in the hospital for 10 days during which there was improvement in irritability, agitation and paranoid delusions. He was then transferred to a long-term facility for continuity of care where he died of complicated aspiration pneumonia.

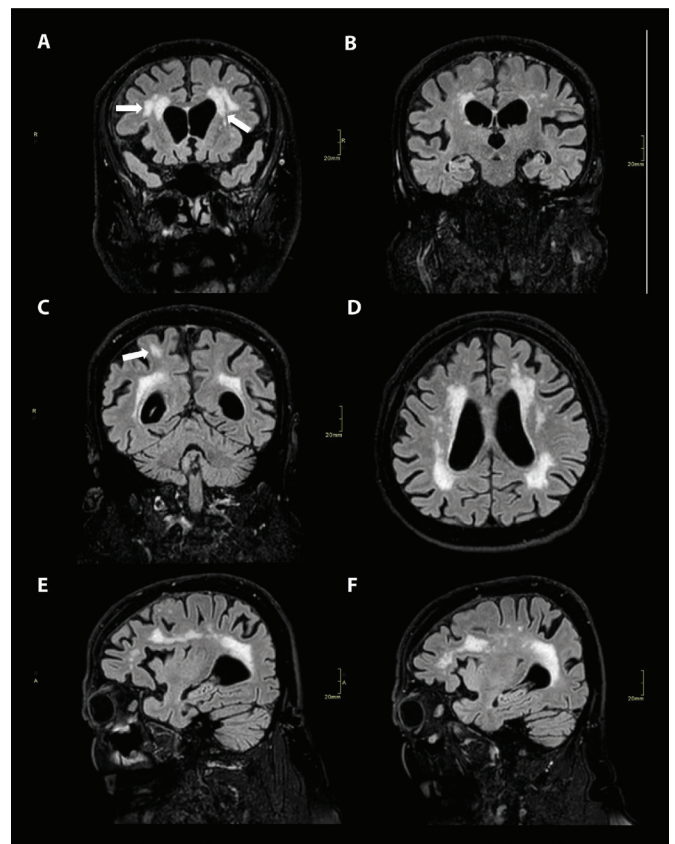
#### DISCUSSION

Our patient presented with a mixed mood episode with psychotic features on a background history of depression

resistant to conventional treatment and prominent cardiovascular risk factors. The clinical presentation and radiological features supported a diagnosis of BD. However, our diagnostic assessment was limited due to the absence of neuropsychological testing, Cerebrospinal Fluid (CSF) inflammatory biomarkers and a pathological diagnosis. Therefore, we were not able to fully rule out other neurodegenerative diseases that can present with a prodrome of psychiatric symptoms (mainly depression and psychosis) such as AD, argyrophilic grain disease and dementia with Lewy bodies. This usually requires a postmortem diagnosis, which was not performed in our patient (see online supplemental table 1 details on the characteristics of each differential diagnosis).

BD, also called subcortical arteriosclerotic encephalopathy, is a form of SIVD with heterogeneous course.<sup>6</sup> It might be misdiagnosed by psychiatrists as a primary affective disorder, especially when symptoms are predominantly psychiatric without preceding major cerebrovascular events or focal neurological deficit. Consequently, this delays the diagnosis and impedes timely therapeutic interventions.<sup>7,8</sup>

The disease equally affects both genders and occurs from the fifth decade onward.<sup>6,9</sup> It has an insidious onset followed by a gradually progressive decline.<sup>10,11</sup> BD's course can vary between



**Figure 1** Brain MRI with gadolinium showing confluent areas of increased FLAIR signal intensity in the periventricular and subcortical white matter of both cerebral hemispheres consistent with an advanced degree of small vessel ischaemic disease. There is prominence of the cerebral sulci and ventricular system consistent with diffuse supratentorial atrophy slightly more prominent in the frontal lobes. (Coronal cut through the frontal lobes (A)—featuring frontal and temporal lobes (B) and parietal lobes (C), (D) axial cut at the level of the lateral ventricles, (E) left and (F) right sagittal cuts at the level of the hippocampus).

episodes of stabilisation, improvement or steeped decline due to the occurrence of transient or acute cerebrovascular events with subsequent cognitive, motor or behavioural disturbances.<sup>10–12</sup> Clinical presentation includes co-occurrence of neurological (motor or sensory), cognitive and psychiatric manifestations.<sup>6</sup> Neurological manifestations can occur at different stages of the disease and patients often manifest pyramidal symptoms with mainly upper neurons and asymmetrical hyperreflexia. Extrapyramidal symptoms, cerebellar signs with gait abnormalities and pseudobulbar signs are more common and usually occur at later stages of the disease.<sup>6–9–11</sup> Similarly, incontinence and impairment of daily living take place. Despite the presence of overlapping features with AD, unlike AD, cognitive impairment in BD is characterised by pronounced frontal executive dysfunction with less prominent memory disturbances.<sup>10–13</sup>

Psychiatric symptoms can prelude the diagnosis of BD; however, unlike neurological manifestations, data on psychiatric presentations are scarce. Symptoms of affective disorders are commonly encountered particularly depressive

symptoms such as reduced activity or interest, apathy and abulia and manic symptoms such as irritability, euphoria and emotional lability.<sup>6–8–9–14</sup> Other presentations comprise personality changes, late-onset paranoid psychosis, confused mental state, behavioural syndrome of frontal lobe type and impaired judgement.<sup>8–15</sup> Actually, the presence of treatment resistant psychiatric symptoms in elderly patients with HTN should raise suspicion of BD.<sup>7</sup> Table 1<sup>7–8–14–17</sup> summarises the case reports of BD that have been chiefly diagnosed following mood, psychotic symptoms and disorganised behaviours (refer to online supplemental table 2 for detailed review of prior case reports).

Depression is the most common psychiatric presentation in BD. It has been hypothesised to be the result of a neurochemical disconnection syndrome as a result of extensive subcortical WM lesions disrupting monoaminergic pathways and leading to neurotransmitters deficiency mainly in frontal lobe.<sup>14</sup> Additionally, WM lesions, irrespective of their location, predominantly affects the metabolism of frontal

**Table 1** Summary of case reports of BD initially presenting with psychiatric manifestations and more delayed neurological symptoms

		N=14	Prevalence (%)	Age (years)±SD (minimum–maximum)
<b>Gender</b>	Female	10	71.4	
	Male	4	28.6	
<b>Mean age at diagnosis of BD</b>				70.79±11.56 (55 – 89)
<b>Risk factors</b>	Hypertension	9	64.3	
	Diabetes mellitus	5	35.7	
	Congestive heart failure	4	28.6	
	Cerebrovascular accident	3	21.4	
	Others	2	14.3	
	None	2	14.3	
	Dyslipidaemia	1	7.1	
	Coronary artery disease	1	7.1	
<b>Psychiatric manifestations</b>	<b>Mean age at diagnosis</b>			69.58±12.77 (50 – 88)
	Depressive symptoms	11	78.6	
	Psychotic symptoms	6	42.9	
	Agitation/aggression	4	28.6	
	Behavioural disturbances of frontal lobe	3	21.4	
	Manic/hypomanic symptoms	2	14.3	
	Suicidal behaviours	2	14.3	
<b>Neurological manifestations</b>	<b>Mean age at diagnosis</b>			70.77±12.27 (52 – 89)
	Forgetfulness/memory impairment	9	64.3	
	Gait abnormalities	7	50	
	Extrapyramidal	6	42.9	
	Urinary incontinence	6	42.9	
	Frontal lobe/dysexecutive	6	42.9	
	Pyramidal	5	35.7	
	Constructional ability impairment	4	28.6	
Pseudobulbar symptoms	3	21.4		
<b>Neuroimaging findings</b>	Periventricular WM hypodensities	12	85.7	
	Frontal/ parietal lobe hypodensities	6	42.9	
	Ventricular enlargement	5	35.7	
	Cortical/gyri/cerebellar atrophy	2	14.3	
	Widening of gyri and/or sulci	1	7.1	
	Cortical hypodensities	1	7.1	
<b>Treatment</b>	Antidepressants	8	57.1	
	Antipsychotics	4	28.6	
	Mood stabilisers	1	7.1	

BD, Binswanger's disease; WM, white matter.

cortices, potentially accounting for the observed executive dysfunction.<sup>18</sup>

The characteristic WM lesions of BD seen on brain MRI<sup>13</sup> are the result of a demyelinating process secondary to pathophysiological changes of HTN. In fact, chronic HTN, invariably described in patients with BD,<sup>6 10 19</sup> leads to arteriosclerosis and lipohyalinosis. This progresses into hypoxia, inflammatory changes of small vessels and causes an increase in blood brain barrier permeability with subsequent release of protease leading to demyelination.<sup>11 13 19 20</sup> Other less frequently described risk factors include smoking, diabetes, hyperlipidaemia, congestive heart failure and arrhythmias.<sup>6 10 19</sup>

Diagnostic criteria for BD have been initially suggested more than 25 years ago as a combination of clinical features, presence of cardiovascular risk factors and extensive WM disease on neuroimaging.<sup>6 21</sup> More recently, FLAIR MRI was recognised as a biomarker for screening and identifying subcortical and periventricular WMH. However, it has low specificity in differentiating WM changes of BD versus those of normal ageing brain or other neurological disorders.<sup>19</sup> Therefore, the use of the widely available diffusion tensor imaging (DTI) or proton magnetic resonance spectroscopy helps identifying at-risk WM lesions undetected by FLAIR and differentiating pathological from normal WM lesions.<sup>19</sup> Other MRI findings include mild to moderate prefrontal and temporo-occipital atrophy, lacunar infarcts and subcortical microbleeds.<sup>10 22</sup> Rosenberg *et al*, in 2015, validated a new 10 points scale for the diagnosis of BD that incorporated clinical criteria such as HTN, diabetes mellitus, hyperreflexia and imbalance, MRI and neuroinflammatory biomarkers in CSF, in addition to neuropsychological testing of executive function and the absence of AD biomarkers. A score of more than 6 is suggestive of BD.<sup>23</sup>

Early diagnosis is crucial in order to halt the progression of psychiatric and cognitive symptoms and preserve patient's quality of life.<sup>9 24</sup> Once a diagnosis of BD is made, successful management should include tight blood pressure control (Systolic Blood Pressure (SBP) <130) and the use of statins, antiplatelets, diet and exercise for the control of other cardiovascular risk factors.<sup>10</sup> Remarkable amelioration of cognition was found with the acetylcholine esterase inhibitor donepezil.<sup>24 25</sup> Evidence about the effectiveness of antidepressants or mood stabiliser for the treatment of the associated affective disorders is limited and comes mainly from case series or case reports. The use of sertraline and citalopram among selective serotonin reuptake inhibitors,<sup>13 14</sup>

tranylcypromine a monoamine oxidase inhibitor,<sup>8</sup> clomipramine and amitriptyline among tricyclics showed improvement of depressive symptoms in BD.<sup>26 27</sup> However, the use of tricyclics is discouraged in elderly patients given their anticholinergic effects. Lithium has been used for the treatment of the manic symptoms.<sup>26</sup> Atypical antipsychotics such as risperidone and olanzapine or typical ones such as chlorpromazine can be used for agitation, disruptive behaviours and psychosis, but caution is required due to possible worsening of extrapyramidal symptoms and increased mortality among elderly population.<sup>7 10</sup> Further studies will be needed to assess the efficacy of conventional psychiatric treatment in the management of behavioural disturbances of BD.

**Twitter** Bernadette Mdawar @bernadette\_G\_Md

**Acknowledgements** The authors would like to thank Dr Youssef Mohsen for his assistance with the radiologic imaging and Mr. Charbel Mourad, senior graphic designer at IT DESIGN PRINT sarl for his assistance in designing the MRI figure.

**Contributors** Manuscript writing/design: BM, CAF. Table design: BM, WS. Manuscript revising: MK, WS.

**Funding** The authors have not declared a specific grant for this research from any funding agency in the public, commercial or not-for-profit sectors.

**Competing interests** None declared.

**Patient consent for publication** Next of kin consent obtained.

**Provenance and peer review** Not commissioned; externally peer reviewed.

**Open access** This is an open access article distributed in accordance with the Creative Commons Attribution Non Commercial (CC BY-NC 4.0) license, which permits others to distribute, remix, adapt, build upon this work non-commercially, and license their derivative works on different terms, provided the original work is properly cited and the use is non-commercial. See: <http://creativecommons.org/licenses/by-nc/4.0/>.

#### ORCID iDs

Bernadette Mdawar <http://orcid.org/0000-0002-2987-6917>

Wael Shamseddeen <http://orcid.org/0000-0001-9717-4979>

#### REFERENCES

- Ng B, Camacho A, Lara DR, *et al*. A case series on the hypothesized connection between dementia and bipolar spectrum disorders: bipolar type VI? *J Affect Disord* 2008;107:307–15.
- Depp CA, Jeste DV. Bipolar disorder in older adults: a critical review. *Bipolar Disord* 2004;6:343–67.
- Tamashiro JH, Zung S, Zanetti MV, *et al*. Increased rates of white matter hyperintensities in late-onset bipolar disorder. *Bipolar Disord* 2008;10:765–75.
- Vasudev A, Thomas A. 'Bipolar disorder' in the elderly: what's in a name? *Maturitas* 2010;66:231–5.
- Roh JH, Lee J-H. Recent updates on subcortical ischemic vascular dementia. *J Stroke* 2014;16:18.
- Caplan LR. Binswanger's disease--revisited. *Neurology* 1995;45:626–33.
- Lawrence RM, Hillam JC. Psychiatric symptomatology in early-onset Binswanger's disease: two case reports. *Behav Neurol* 1995;8:43–6.
- Summergrad P, Peterson B. Binswanger's disease (Part I): the clinical recognition of subcortical arteriosclerotic encephalopathy in elderly neuropsychiatric patients. *J Geriatr Psychiatry Neurol* 1989;2:123–33.
- Babikian V, Ropper AH. Binswanger's disease: a review. *Stroke* 1987;18:2–12.
- Huisa BN, Rosenberg GA. Binswanger's disease: toward a diagnosis agreement and therapeutic approach. *Expert Rev Neurother* 2014;14:1203–13.
- Rosenberg GA, Wallin A, Wardlaw JM, *et al*. Consensus statement for diagnosis of subcortical small vessel disease. *J Cereb Blood Flow Metab* 2016;36:6–25.
- Højer-Pedersen E, Petersen OF. Subcortical arteriosclerotic encephalopathy (Binswanger's disease). presentation of two cases. *Acta Med Scand* 1987;221:409–12.
- Román GC, Erkinjuntti T, Wallin A, *et al*. Subcortical ischaemic vascular dementia. *Lancet Neurol* 2002;1:426–36.
- Venna N, Mogocsi S, Jay M, *et al*. Reversible depression in Binswanger's disease. *J Clin Psychiatry* 1988;49:23–6.
- Nagaratnam N, Nagaratnam K. Psychiatric and behavioral aspects of dementia of the Binswanger type. *Am J Alzheimers Dis* 1998;13:173–8.
- El-Shazly M. Rapid cycling bipolar disorder in a case of Binswanger's disease. *Int J Geriatr Psychiatry* 1994;9:925–7.

#### Learning points

- ▶ Binswanger disease is a form of subcortical ischaemic vascular disease that should be suspected in elderly patients with uncontrolled hypertension, presenting after their fifth decade with late-onset psychiatric disorders refractory to conventional treatment.
- ▶ Brain imaging, mainly fluid attenuated inversion recovery-MRI but more importantly diffusion tensor imaging and proton magnetic resonance spectroscopy are a key diagnostic tool.
- ▶ Treatment includes control of cardiovascular risk factors in addition to standard treatment for dementia and primary psychiatric disorders.

- 17 Pathania M, Malik P, *et al.* A case of hypertension with dementia: common but underdiagnosed. *J Family Med Prim Care* 2018;7:447.
- 18 Tullberg M, Fletcher E, DeCarli C, *et al.* White matter lesions impair frontal lobe function regardless of their location. *Neurology* 2004;63:246–53.
- 19 Rosenberg GA. Binswanger's disease: biomarkers in the inflammatory form of vascular cognitive impairment and dementia. *J Neurochem* 2018;144:634–43.
- 20 Huisa BN, Caprihan A, Thompson J, *et al.* Long-Term blood-brain barrier permeability changes in Binswanger disease. *Stroke* 2015;46:2413–8.
- 21 Bennett DA, Wilson RS, Gilley DW, *et al.* Clinical diagnosis of Binswanger's disease. *J Neurol Neurosurg Psychiatry* 1990;53:961–5.
- 22 Jung W-B, Mun C-W, Kim Y-H, *et al.* Cortical atrophy, reduced integrity of white matter and cognitive impairment in subcortical vascular dementia of Binswanger type. *Psychiatry Clin Neurosci* 2014;68:821–32.
- 23 Rosenberg GA, Prestopnik J, Adair JC, *et al.* Validation of biomarkers in subcortical ischaemic vascular disease of the Binswanger type: approach to targeted treatment trials. *J Neurol Neurosurg Psychiatry* 2015;86:1324–30.
- 24 Perry A, Brat DJ. Practical surgical neuropathology: a diagnostic approach E-Book: a volume in the pattern recognition series: Elsevier health sciences 2017.
- 25 Kwon JC, Kim EG, Kim JW, *et al.* A multicenter, open-label, 24-week follow-up study for efficacy on cognitive function of donepezil in Binswanger-type subcortical vascular dementia. *Am J Alzheimers Dis Other Demen* 2009;24:293–301.
- 26 Joyce EM, Levy R. Treatment of mood disorder associated with Binswanger's disease. *Br J Psychiatry* 1989;154:259–61.
- 27 Turkington D, Geddes J. Delusional depression responding to clomipramine in Binswanger's disease. *J Nerv Ment Dis* 1990;178:459–60.

Copyright 2021 BMJ Publishing Group. All rights reserved. For permission to reuse any of this content visit <https://www.bmj.com/company/products-services/rights-and-licensing/permissions/>  
 BMJ Case Report Fellows may re-use this article for personal use and teaching without any further permission.

Become a Fellow of BMJ Case Reports today and you can:

- ▶ Submit as many cases as you like
- ▶ Enjoy fast sympathetic peer review and rapid publication of accepted articles
- ▶ Access all the published articles
- ▶ Re-use any of the published material for personal use and teaching without further permission

#### Customer Service

If you have any further queries about your subscription, please contact our customer services team on +44 (0) 207111 1105 or via email at [support@bmj.com](mailto:support@bmj.com).

Visit [casereports.bmj.com](http://casereports.bmj.com) for more articles like this and to become a Fellow