

Minimally invasive surgery for spinal fractures due to multiple myeloma

ABSTRACT

Background: Multiple myeloma (MM) presents with spinal lesions in 60% of cases. The combination of osteolytic lesions with multifactorial osteopenia raises specific surgical treatment challenges. Minimally invasive spine surgery (MISS) could be a potential option for MM spinal lesions treatment.

Objective: The objective of this study is to evaluate MISS techniques to treat patients presenting with spine fractures due to MM

Methods: Retrospective analysis of consecutive patients with histology-proven pathological fractures caused by MM treated with MISS between 2009 and 2018. We collected the data from the clinical records on epidemiology, topography of spine lesions, surgical techniques, blood loss, operation time, complications, mean in-hospital time, and clinical evolution.

Results: Twenty-one patients were studied – 13 males and 8 females, with a mean age of 64 years (range 43–83). Mean preoperative spinal instability neoplastic score was 9.8 ± 6 (range 5–16). All cases had a thoracolumbar location – 15 patients underwent kyphoplasty (KP) or vertebroplasty (VP) and 6 were treated with other more complex procedures. All patients had a reduction of pain and/or analgesic load. Vertebral body height increased by a mean of 2.9 mm after VP/KP. Mean hospital stay was 1.3 days for KP/VP and 5.0 days for other MISS procedures. Three patients had complications.

Conclusions: The heterogeneity of techniques used reflected the variety of spine involvement by MM. KP and VP led to shorter hospital stays and less complications, being adequate for lesions without major instability. More complex MISS techniques offer an effective treatment with short delay for starting MM adjuvant treatment.

Keywords: Kyphoplasty, minimally invasive surgical surgery, multiple myeloma, spine fracture, tumor percutaneous pedicle screws stabilization

INTRODUCTION

Multiple myeloma (MM) is a clonal, malignant proliferation of plasmocytes,^[1] representing 1% of all tumors and 13% of all hematological tumors.^[1] Bone involvement is common, affecting 70% of patients with MM.^[2,3] Spine lesions, which are present in 60% of MM patients,^[4] cause wedge fractures with significant axial pain, vertebral collapse, kyphotic deformity, myelopathy, and radiculopathy.^[2,5] Eighty percent of fractures occur in T6-L4 segment with 50% in T11-L1.^[4]

Besides osteolytic lesions, osteopenia is another important feature in MM pathophysiology.^[6] It affects mainly vertebral bodies and less frequently the pedicle or

transverse/spinous processes. It is important to underline that steroids and radiotherapy can also aggravate bone

**RUI REINAS¹, DJAMEL KITUMBA^{1,2},
LEOPOLDINA PEREIRA¹, OSCAR L ALVES^{1,3}**

¹Department of Neurosurgery, Hospital Center of Vila Nova de Gaia/Espinho, ²Department of Neurosurgery, Hospital Américo Boavida, Angola, ³Department of Neurosurgery, Hospital Lusíadas Porto, Portugal

Address for correspondence: Prof. Oscar L Alves, Department of Neurosurgery, Hospital Center of Vila Nova de Gaia/Espinho, Portugal.
E-mail: oscar.l.alves@gmail.com

Submitted: 10-Jan-21


Accepted: 15-Jan-21

Published: 10-Jun-21

This is an open access journal, and articles are distributed under the terms of the Creative Commons Attribution-NonCommercial-ShareAlike 4.0 License, which allows others to remix, tweak, and build upon the work non-commercially, as long as appropriate credit is given and the new creations are licensed under the identical terms.

For reprints contact: WKHLRPMedknow_reprints@wolterskluwer.com

How to cite this article: Reinas R, Kitumba D, Pereira L, Alves OL. Minimally invasive surgery for spinal fractures due to multiple myeloma. J Craniovert Jun Spine 2021;12:117-22.

Access this article online	
Website: www.jcvjs.com	Quick Response Code 
DOI: 10.4103/jcvjs.jcvjs_2_21	

osteopenia,^[7] raising further difficulties to the classical “open” surgical strategy.

The treatment for MM is essentially medical-chemotherapy, bone protection with bisphosphonates, and radiotherapy.^[8] Surgery is indicated to solve some of the associated complications – spinal instability,^[9,10] neurological deficits due to compressive lesions, and pain refractory to the best medical treatment.^[4,11,12] The solitary bone plasmacytoma (SBP), a single lytic lesion without bone marrow plasmacytosis,^[1,8] is a good indication for surgery with curative goal.

Therefore, the benefits associated with minimally invasive spine surgery (MISS) can emerge as a sound option in MM patients, affected simultaneously by osteolysis and osteopenia. Even if it requires a significant amount of surgical expertise, MISS can provide a low approach-related morbidity solution that may accelerate the start of adjuvant systemic therapies.^[13-15] Many studies highlight the role of cement augmented techniques;^[16-18] however, mini-open decompression techniques and percutaneous posterior transpedicular fixation have not yet been validated to treat MM patients. In this study, we review the MISS strategies used to solve the specific issues presented by different MM cases, allowing us to draw general conclusions.

METHODS

Study and Data

We retrospectively reviewed all patients who underwent surgical treatment for spine MM with MISS techniques at the Neurosurgery Department of the Centro Hospitalar de Vila Nova de Gaia/Espinho and Hospital Lusíadas Porto, from 2009 to 2018. Only patients with histology-proven spine disease were included. We collected retrospectively the information from the clinical databases available (SAM clinical software, SAM[®], ACSS – Lisbon, Portugal. SECTRA[®], SECTRA AB – Linköping, Sweden, and the SECTRA imaging software).

Variables

Data collected included demographic variables (age and gender), number and topography of lesions, preoperative Spinal Instability Neoplastic Score (SINS), surgical technique, blood loss, duration of surgery, vertebral body height restoration, complications, re-operations, duration of hospital stay, time to start adjuvant therapies, duration of clinical follow-up, and clinical outcomes (Karnofsky Performance Score [KPS]).

RESULTS

The general features of our patients are displayed in Table 1.

We included in the study 21 consecutive patients with histological diagnosis for MM/SBP, for the period of 2009-2018. The mean follow-up duration was 11.1 ± 9.18 months (5-24 months). The mean age at surgery was 64 years (43-83 years). Thirteen patients were male (62%), and eight were female (38%).

In total, 42 index levels were treated in the 21 patients – 23 in thoracic segment and 19 in lumbar segment [Figure 1]. All patients presenting with spine fractures, regardless of previous diagnosis, had bone samples taken for histological analysis, which allowed “*de novo*” diagnosis of MM or SBP in 8/21 patients (38%). Mean preoperative SINS was 9.8 (range 6-16). Patients submitted to kyphoplasty (KP) or vertebroplasty (VP) scored a mean of 8.8 (range 6–12), whereas those operated with other MISS techniques scored a mean of 12.3 on SINS (range 7–16).

Fifteen patients (71%) were treated with either KP or VP, whereas six patients (29%) were submitted to more complex MISS procedures. VP/KP was performed through a percutaneous transpedicular approach, followed either by direct injection of polymethylmethacrylate (PMMA), balloon dilation before PMMA injection, or placement of a titanium stent (OsseoFix[®], Alphatec Spine, CA, USA). Vertebral body height increased by a mean of 2.9 ± 5.3 mm (range-3.6–16.8 mm) with these techniques.

In six patients (29%), due to major instability or because required bony decompressive procedures would putatively threaten the spine stability, we performed percutaneous pedicle screw fixations, eventually supplemented by decompressive procedures:

- One patient underwent stand-alone pedicle screw fixation – due to a significant breach in the posterior wall, it was decided not to perform KP/VP;
- In one case, VP was performed in combination with posterior fixation to provide anterior column support in a poor bone density spine;

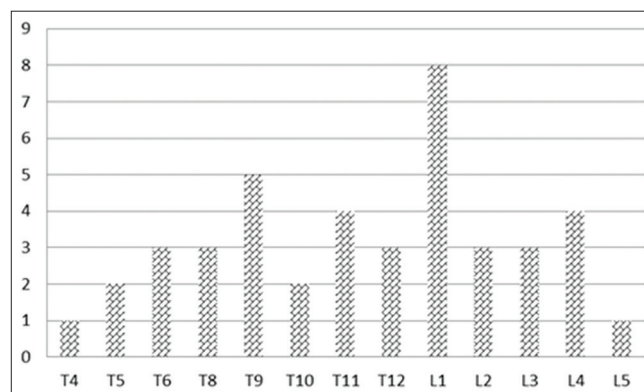


Figure 1: Histogram showing the distribution of the spine levels that were operated (n = 42)

Table 1: Summary of clinical features of patients enrolled in our series described in a chronological sequence

	Age	Gender	Levels	SINS	Approach	HS	OR T	BL	Complications
2009									
Case 1	76	Male	T8; T9	12	VP/KP	1	40	Vestigial	None
Case 2	70	Female	T6; T8; L4	10	VP/KP	2	50	Vestigial	None
Case 3	58	Male	T5; T9	10	VP/KP	1	65	Vestigial	PMMA leak
Case 4	73	Female	L1	7	VP/KP	1	20	Vestigial	None
2012									
Case 5	63	Male	L1; L3	10	VP/KP	2	55	Vestigial	None
Case 6	67	Male	L2; L3; L4	9	VP/KP	1	70	Vestigial	None
2013									
Case 7	47	Female	T10	14	Combined	8	170	250	CSF leak
Case 8	58	Male	T12; L3; L5	11	VP/KP	1	65	Vestigial	None
Case 9	50	Female	L1; L4	6	VP/KP	1	35	Vestigial	None
Case 10	66	Male	T10	13	Posterior	7	80	50	Urinary infection
2015									
Case 11	80	Male	T5	16	Posterior	5	170	150	None
Case 12	43	Female	L1	10	Posterior	5	110	50	None
Case 13	49	Female	T4	12	Posterior	2	150	150	None
2016									
Case 14	61	Male	T11; T12	10	VP/KP	1	50	Vestigial	None
Case 15	73	Male	T6	9	Posterior	3	160	200	None
2017									
Case 16	83	Male	L2; L4	6	VP/KP	1	45	Vestigial	None
Case 18	54	Female	T9; T11; T12; L1	9	VP/KP	1	50	Vestigial	None
Case 17	77	Female	T9	9	VP/KP	1	35	Vestigial	None
Case 18	76	Male	T6; T11; L1	7	VP/KP	1	55	Vestigial	None
2018									
Case 19	77	Male	L1, L2	9	VP/KP	1	40	Vestigial	None
Case 20	52	Male	T7; T8; T9; T12; L1	11	VP/KP	1	65	Vestigial	None

PMMA - Polymethyl methacrylate, HS - Hospital stay in days, OR T - Operation room time in minutes, BL - Blood loss in ml. vestigial <20 ml, SINS - Spinal instability neoplastic score, KP - Kyphoplasty, VP - Vertebroplasty, CSF - Cerebrospinal fluid

- Three patients were submitted to a paramedian mini-open tumor resection and neural decompression, supplemented with percutaneous pedicle screw fixation;
- One case of vertebral body reconstruction with an expandable cylinder inserted through a mini-open retractor after tumor removal.

Mean operative time was 49.3 ± 14.4 min for KP/VP and 152.0 ± 36.9 min for the other techniques. Patients submitted to KP/VP presented with vestigial blood loss (defined as estimated <20 ml), whereas other procedures lead to a mean blood loss of 141.2 ± 94.3 ml. The mean in-hospital stay was 1.13 ± 0.34 days for cement or stent-augmented techniques ($n = 15$), comparing to 5.0 ± 2.3 days for the patients submitted to more complex MISS techniques ($n = 6$). In two patients, a longer hospital stay was explained by more aggressive systemic disease presentation.

All patients, whether subjected to KP/VP or other procedures, had resolution, or significant reduction of pain and analgesic load reduction, from the immediate postoperative period onwards. Eight patients presented initially with neurological

deficits-6 of these (75%) were treated with more complex MISS procedures. Two did not improve their neurological status after the procedures, one from each group. Adjuvant therapies were implemented 3.8 ± 2.1 weeks after surgery [Table 2]. Worth of notice is the fact that four patients of the KP/VP cohort did not interrupt the adjuvant schemes, being treated as planned.

Three patients developed complications: One patient presented with a urinary tract infection; another patient had a small lateral PMMA leak, without any clinical consequences; one case of CSF leak that did not require surgery, but prolonged the duration of hospital stay (an outlayer). There were neither cases of recurrence at levels previously treated nor cases of instrumentation failure.

Patient's outcome was heavily influenced by the systemic disease effects of progressive MM. Nine patients were alive at last follow-up, 8 of them with a KPS >70 – the remaining patient had significant disability due to concomitant severe Parkinson's Disease. Twelve patients died as a consequence of MM or related complications, nevertheless surviving a mean of 14.2 ± 7.6 months after surgery.

Illustrative case

Case 7 describes a 47-year-old female with familiar spastic paraparesis but capable of independent ambulation, who presented with worsening of paraparesis (strength IV) and dorsal pain (visual analogue scale [VAS] 7) in 2012. Dorsal computed tomography (CT) revealed a collapse of D10 due to a lytic lesion of unknown origin with evidence of invasion of the posterior arch and anterolisthesis of D9, causing cord compression, which was confirmed with magnetic resonance imaging [Figure 2]. Similar lytic lesions were described in the adjacent vertebra, but without neurological compromise. The patient scored 14 in the SINS. A D10 corpectomy and insertion of an expandable cylinder was performed through a paramedian mini-open technique supplemented with a percutaneous pedicle fixation from D8 to D12, two-levels above and below the lesion. Histological examination characterized the lytic lesion as a “*de novo*” MM. Postoperative CT confirmed both the appropriate surgical decompression and correct the placement of the instrumentation [Figure 3]. After the procedure, the patient had a significant improvement in pain scores (VAS 2) when she was discharged. At 6 months of follow-up and rehabilitation, her paraparesis had stabilized at a level strength of III/V.

DISCUSSION

Our clinical study demonstrates the high degree of complexity when managing MM patients with spine lesions. The first constraint is diagnostic, as the distribution of spine levels affected by MM fractures overlap with that of the less benign osteoporotic fractures,^[19] which are far more common. For this reason, our protocol of cement-augmented procedures always includes an initial bone biopsy. Accordingly, we found a high number of primary “*de novo*” diagnosis, which represent 38% of our cohort of patients. Togawa *et al.* reported 2.8% of new diagnosis of plasma cells dyscrasias in their series.^[20]

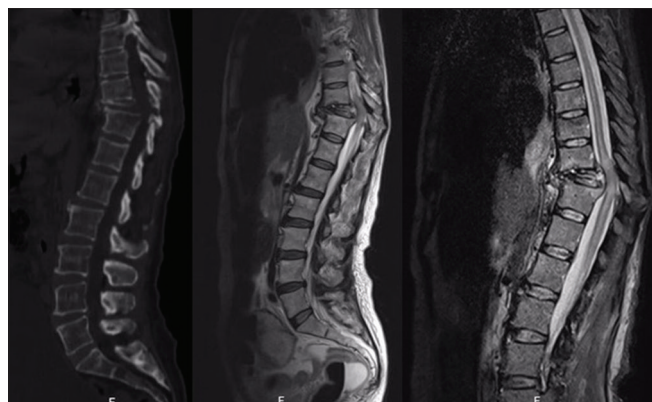


Figure 2: Thoracolumbar computed tomography and magnetic resonance imaging (T2W1 and short-time inversion recovery) showing extensive destruction of D10 with significant retropulsion in the spinal canal, cord compression and kyphotic deformity

Muijs *et al.* similarly found 3.8% of new neoplasms, including two cases of previously undiagnosed MM.^[21] Both authors advocate that in every vertebral fracture treated surgically a diagnostic biopsy should be done, which is in line with our institutional protocol.^[20,21]

Moreover, a significant proportion of MM patients present with spine disease in the thoracolumbar junction,^[19,22] with 50% of lesions concentrated in T11-L1 region. This is a transition zone between a low and high mobile spine, subject to a higher degree of biomechanical stress, leading to an increased incidence of vertebral fractures at these levels. The frequency of fractures in MM is further amplified by the associated poor bone quality due to steroids use and to calcium metabolism impairment, a relevant feature in the pathogenesis of MM fractures.^[22] Thus, in comparison to spine metastatic disease, MM raises additional surgical challenges related to osteopenia, which has a strong impact in the incidence of complications. Zadnik *et al.*^[11] described 14 complications in their cohort of 31 patients, including four cases of instrumentation failure – either rod fracture or loosening of screws. Guzik^[23] reports eight complication in 129: 3 patients suffered from impaired wound healing and

Table 2: Clinical outcomes associated with the different techniques

	Outcomes		
	ΔKPS	RT/CT (weeks)	Mean survival (m)
KP/VP	10.0±9.3	3.3±1.7	30.4±29.5
MIS fixation/decompression	23.3±10.3	4.0±2.3	34.2±21.4

KPS - Karnofsky performance score, RT/CT - Radiotherapy/chemotherapy in weeks, KP - Kyphoplasty, VP - Vertebroplasty, MIS - Minimally invasive surgery, Mean survival in months

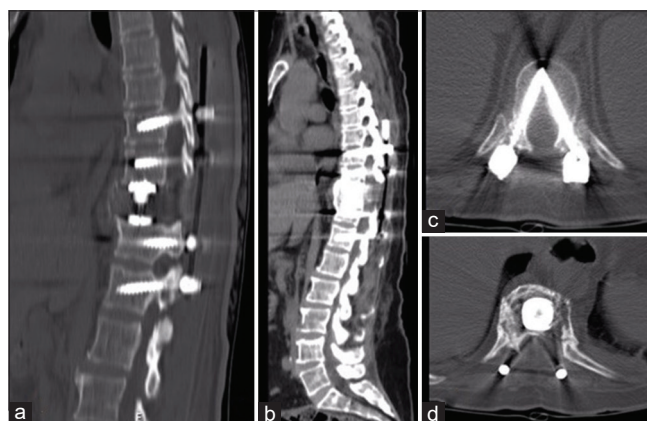

Figure 3: Postoperative computed tomography scans: At day 8 (a) and 2 years after surgery (b and c). Note the long-standing release of spinal cord compression and the significant correction of the kyphotic deformity. Significant decompression was achieved (D). The long construct 2-levels above and below the multiple myeloma lesion, the optimal convergence of percutaneous pedicle screws and the anterior column support afforded by the cylinder contributed to the long-term stability of the hardware construct

2 patients had their instrumentation revised. In our cohort, by using only MISS techniques, no cases of hardware failure were noticed, in relation to the use of long construct or anterior column support with cement or expandable cylinder. The MISS techniques leave intact the posterior ligaments and muscles, namely multifidus muscle, the largest force generating capacity muscle in lumbar spine, which is designed for stability, especially in flexion. This is of paramount importance to preserve spine stability after surgery to reduce hardware complications in a rather osteoporotic spine.

Regarding the KPS, Guzik^[23] reported that the mean KPS for patients with spine tumors (not only MM) treated with VP increased from 60 ± 7.9 to 80 ± 7.9 . They reported similar progression for the stabilization cohort, though their group included MISS and non-MISS patients (54 ± 9.8 – 59 ± 12.2). In our series of enrolling only MM patients, all had favorable outcomes facilitated by the use of MISS techniques, in terms of pain relief, spine stability, and functional status (8 patients out of 9 survivors at last follow-up with KPS > 70).

MISS literature on spine tumors, mostly regarding metastatic disease, offers evidence of less blood loss,^[24,25] less in-hospital stay^[25] and better functional status for these patients,^[24,26] by reducing approach-related morbidity without sacrificing the goal of the procedures.^[27] Although no previous studies focused specifically on MISS in MM disease, our study clearly demonstrates that similar outcomes apply to these patients.

The patients in our cohort started adjuvant therapies on average 3.8 weeks after surgery. Of notice, four patients submitted to cement augmentation did not pause chemotherapy regimens already under way, having been operated between cycles with no subsequent adverse events. MISS techniques provided a quick wound healing due to smaller skin incisions and less soft-tissue damage, in rather catabolic patients due to adjuvant therapies, without any case of wound dehiscence or infection. This is essential to start or resume, in a timely mode, the adjuvant therapy for MM, which is crucial for disease control.^[8,28]

For patients presenting with spinal fractures without instability or spinal cord compression, KP and VP are very effective in treating pain otherwise refractory to medical treatment. KP/VP showed no clinically relevant complications and is associated with a shorter hospitalization time (1.3 ± 0.34 days). Simony *et al.*^[29] reported in their cohort a significant reduction of VAS after VP-7.6-3.2, at 3 months of follow-up. Several authors described similar results in their studies regarding pain control.^[2,14,16,30] Furthermore, these interventions are effective at restoring vertebral body

height, as our series demonstrated (Δ height of 2.9 ± 5.3 mm), with the potential to positively influence sagittal balance. Teng *et al.*^[31] and Dublin *et al.*^[32] reported on the efficacy of cement augmentation on height restoration and overall sagittal balance (29% height restoration for the anterior border and mean reduction in kyphosis of 4.3° ^[31]).

Finally, the surgical strategy should be tailored to individual patients, according to the sagittal and axial location of the MM lesions, the occurrence of instability and spinal cord compression. The SINS score was important in the decision-making regarding the technique choice, especially in assessing the need for additional pedicle screw stabilization and anterior column support.^[33] Pennington *et al.*^[25] report a good intraobserver and interobserver reliability of the SINS score in their meta-analysis, especially among spine surgeons. In our series, patients submitted to cement or stent augmentation scored lower in the SINS score than those submitted to more complex techniques (mean of 8.8 ± 1.7 vs. 12.3 ± 2.6). Robust instrumentation should be performed in patients with instability to provide posterior elements and vertebral body support and thus avoid hardware complications. A more aggressive surgical resection is indicated in cases of spinal cord compression with neurological translation or in case of solitary bone plasmocytoma with a curative intention. Both Xie *et al.* and Huang *et al.* reported that gross total resection reduced local recurrence and progression to MM.^[17,34]

There are some limitations in our study that need to be mentioned. The retrospective nature of the study and the lack of control group submitted to non-MISS techniques limit the strength of the conclusions. Although the number of patients treated with MISS techniques is small, this study includes only MM patients, which is a unique feature in the related literature. Accordingly, the study provides new information on how to treat spine lesions MM-related according to MISS principles, leading to less blood loss, less operating time, hospital stay, less analgesic use, less complications, and less hardware failure because of minimal soft-tissue damage in a peculiar pathology that combines osteolytic lesion with osteopenia.

CONCLUSIONS

Our experience favors the conclusion that MISS techniques applied to MM spine lesions contribute to faster recovery, allow quick starting of adjuvant therapy and reduced approach-related morbidity and hardware failure, due to muscle and ligament sparing, in a pathology that combines osteolytic lesions with osteopenia.

Financial support and sponsorship

Nil.

Conflicts of interest

There are no conflicts of interest.

REFERENCES

- Kasper DL, Hauser SL, Jameson JL, Fauci AS, Longo DL, Loscalzo J, *et al.* Harrison's Principles of Internal Medicine 19th Ed. McGraw-Hill Education PA, USA; 2015. Vol XXXIII. p. 18423.
- Julka A, Tolhurst SR, Srinivasan RC, Graziano GP. Functional outcomes and height restoration for patients with multiple myeloma related osteolytic vertebral compression fractures treated with kyphoplasty. *J Spinal Disord Tech* 2012;27:1.
- Erdem E, Akdol S, Amole A, Fryar K, Eberle RW. Radiofrequency-targeted vertebral augmentation for the treatment of vertebral compression fractures as a result of multiple myeloma. *Spine (Phila Pa 1976)* 2013;38:1275-81.
- Tosi P. Diagnosis and treatment of bone disease in multiple myeloma: Spotlight on spinal involvement. *Scientifica (Cairo)* 2013;2013:104546.
- Bladé J, Kyle RA. Multiple myeloma in young patients: Clinical presentation and treatment approach. *Leuk Lymphoma* 1998;30:493-501.
- Kyle RA, Gertz MA, Witzig TE, Lust JA, Lacy MQ, Dispenzieri A, *et al.* Review of 1027 patients with newly diagnosed multiple myeloma. *Mayo Clin Proc* 2003;78:21-33.
- Huang W, Cao D, Ma J, Yang X, Xiao J, Zheng W, *et al.* Solitary plasmacytoma of cervical spine: Treatment and prognosis in patients with neurological lesions and spinal instability. *Spine (Phila Pa 1976)* 2010;35:E278-84.
- Larocca A, Child JA, Cook G, Jackson GH, Russell N, Szubert A, *et al.* The impact of response on bone-directed therapy in patients with multiple myeloma. *Blood* 2013;122:2974-7.
- Eleraky M, Papanastassiou I, Setzer M, Baaj AA, Tran ND, Vrionis FD. Balloon kyphoplasty in the treatment of metastatic tumors of the upper thoracic spine. *J Neurosurg Spine* 2011;14:372-6.
- Rao G, Ha CS, Chakrabarti I, Feiz-Erfan I, Mendel E, Rhines LD. Multiple myeloma of the cervical spine: Treatment strategies for pain and spinal instability. *J Neurosurg Spine* 2006;5:140-5.
- Zadnik PL, Goodwin CR, Karami KJ, Mehta AI, Amin AG, Groves ML, *et al.* Outcomes following surgical intervention for impending and gross instability caused by multiple myeloma in the spinal column. *J Neurosurg Spine* 2015;22:301-9.
- Sciubba DM, Gokaslan ZL. Diagnosis and management of metastatic spine disease. *Surg Oncol* 2006;15:141-51.
- La Maida GA, Giarratana LS, Acerbi A, Ferrari V, Mineo GV, Misaggi B. Cement leakage: Safety of minimally invasive surgical techniques in the treatment of multiple myeloma vertebral lesions. *Eur Spine J* 2012;21 Suppl 1:S61-8.
- Masala S, Anselmetti GC, Marcia S, Massari F, Manca A, Simonetti G. Percutaneous vertebroplasty in multiple myeloma vertebral involvement. *J Spinal Disord Tech* 2008;21:344-8.
- Berenson J, Pflugmacher R, Jarzem P, Zonder J, Schechtman K, Tillman JB, *et al.* Balloon kyphoplasty versus non-surgical fracture management for treatment of painful vertebral body compression fractures in patients with cancer: A multicentre, randomised controlled trial. *Lancet Oncol* 2011;12:225-35.
- Kyriakou C, Molloy S, Vrionis F, Alberico R, Bastian L, Zonder JA, *et al.* The role of cement augmentation with percutaneous vertebroplasty and balloon kyphoplasty for the treatment of vertebral compression fractures in multiple myeloma: A consensus statement from the International Myeloma Working Group (IMWG). *Blood Cancer J* 2019;9:27.
- Kasperk C, Haas A, Hillengass J, Weiss C, Neben K, Goldschmidt H, *et al.* Kyphoplasty in patients with multiple myeloma a retrospective comparative pilot study. *J Surg Oncol* 2012;105:679-86.
- Dudeny S, Lieberman IH, Reinhardt MK, Hussein M. Kyphoplasty in the treatment of osteolytic vertebral compression fractures as a result of multiple myeloma. *J Clin Oncol* 2002;20:2382-7.
- Musbahi O, Ali AM, Hassany H, Mobasheri R. Vertebral compression fractures. *Br J Hosp Med (Lond)* 2018;79:36-40.
- Togawa D, Lieberman IH, Bauer TW, Reinhardt MK, Kayanja MM. Histological evaluation of biopsies obtained from vertebral compression fractures: Unsuspected myeloma and osteomalacia. *Spine (Phila Pa 1976)* 2005;30:781-6.
- Muijs SP, Akkermans PA, van Erkel AR, Dijkstra SD. The value of routinely performing a bone biopsy during percutaneous vertebroplasty in treatment of osteoporotic vertebral compression fractures. *Spine (Phila Pa 1976)* 2009;34:2395-9.
- Astolfi S, Scaramuzza L, Logroscino CA. A minimally invasive surgical treatment possibility of osteolytic vertebral collapse in multiple myeloma. *Eur Spine J* 2009;18 Suppl 1:115-21.
- Guzik G. Oncological and functional results of the surgical treatment of vertebral metastases in patients with multiple myeloma. *BMC Surg* 2017;17:92.
- Saaddeh YS, Elswick CM, Fateh JA, Smith BW, Joseph JR, Spratt DE, *et al.* Analysis of outcomes between traditional open versus mini-open approach in surgical treatment of spinal metastasis. *World Neurosurg* 2019;130:e467-74.
- Pennington Z, Ahmed AK, Cottrill E, Westbroek EM, Goodwin ML, Sciubba DM. Intra and interobserver reliability of the spinal instability neoplastic score system for instability in spine metastases: A systematic review and meta-analysis. *Ann Transl Med* 2019;7:218.
- Conti A, Acker G, Kluge A, Loebel F, Kreimeier A, Budach V, *et al.* Decision making in patients with metastatic spine. The role of minimally invasive treatment modalities. *Front Oncol* 2019;9:915.
- Hamad A, Vachtsevanos L, Cattell A, Ockendon M, Balain B. Minimally invasive spinal surgery for the management of symptomatic spinal metastasis. *Br J Neurosurg* 2017;31:526-30.
- Walker R, Barlogie B, Haessler J, Tricot G, Anaissie E, Shaughnessy JD Jr. *et al.* Magnetic resonance imaging in multiple myeloma: Diagnostic and clinical implications. *J Clin Oncol* 2007;25:1121-8.
- Simony A, Hansen EJ, Gaurilcik M, Abildgaard N, Andersen MØ. Pain reduction after percutaneous vertebroplasty for myeloma-associated vertebral fractures. *Dan Med J* 2014;61:A4945.
- Malhotra K, Butler JS, Yu HM, Selvadurai S, D'Sa S, Rabin N, *et al.* Spinal disease in myeloma: Cohort analysis at a specialist spinal surgery centre indicates benefit of early surgical augmentation or bracing. *BMC Cancer* 2016;16:444.
- Teng MM, Wei CJ, Wei LC, Luo CB, Lirng JF, Chang FC, *et al.* Kyphosis correction and height restoration effects of percutaneous vertebroplasty. *AJNR Am J Neuroradiol* 2003;24:1893-900.
- Dublin AB, Hartman J, Latchaw RE, Hald JK, Reid MH. The vertebral body fracture in osteoporosis: Restoration of height using percutaneous vertebroplasty. *AJNR Am J Neuroradiol* 2005;26:489-92.
- Murtaza H, Sullivan CW. Classifications in brief: The spinal instability neoplastic score. *Clin Orthop Relat Res* 2019;477:2798-803.
- Xie L, Wang H, Jiang J. Does radiotherapy with surgery improve survival and decrease progression to multiple myeloma in patients with solitary plasmacytoma of bone of the spine? *World Neurosurg* 2020;134:e790-98.