

## ORIGINAL INVESTIGATION

## The impact of IPACK combined with adductor canal block under ultrasound guidance on early motor function after total knee arthroplasty



Fang-Yu Zheng<sup>a,b</sup>, Yong-Bo Liu<sup>c</sup>, Hui Huang<sup>a</sup>, Shuai Xu<sup>d</sup>, Xiao-Jun Ma<sup>a</sup>, Ying-Zhi Liu<sup>a,\*</sup>, Hai-Chen Chu<sup>a</sup>

<sup>a</sup> The Affiliated Hospital of Qingdao University, Department of Anesthesiology, Qingdao, China

<sup>b</sup> Women and Children's Hospital, Qingdao University, Department of Anesthesiology, Qingdao, China

<sup>c</sup> The Affiliated Hospital of Qingdao University, Department of Operating Room, Qingdao, China

<sup>d</sup> The Affiliated Hospital of Qingdao University, Department of Cardiovascular Surgery Intensive Care Unit, Qingdao, China

Received 9 October 2019; accepted 14 April 2021

Available online 26 April 2021

### KEYWORDS

IPACK;  
Peripheral nerve  
blocks;  
Regional anesthesia;  
Adductor canal block;  
Total knee  
arthroplasty

### Abstract

**Background:** This study aimed to evaluate the impact of Infiltration between the Popliteal Artery and Capsule of the posterior Knee (IPACK) combined with an adductor canal block under the guidance of ultrasound on early motor function after Total Knee Arthroplasty (TKA).

**Methods:** A sample of 60 cases who were scheduled for elective unilateral TKA were divided into two groups using random number table method: a group with IPACK combined with an adductor canal block (I group, n = 30), and a group with femoral nerve block combined with superior popliteal sciatic nerve block (FS group, n = 30). Before anesthesia induction was completed, the patients in I group received an ultrasound-guided adductor canal block with 15 mL of 0.375% ropivacaine and an IPACK block with 25 mL of ropivacaine, and the patients in FS group received a femoral nerve block and a superior popliteal sciatic nerve block with 20 mL of 0.375% ropivacaine under ultrasound guidance. Post-operation, all the patients received patient-controlled intravenous analgesia combined with an oral celecoxib capsule to relieve pain and maintain a visual analogue scale score of  $\leq 3$ .

**Results:** The quadriceps femoris muscle strength score was significantly higher in I group than in FS group ( $p = 0.001$ ), while the modified Bromage score were significantly lower and walking distance results were significantly higher in I group than in FS group (both  $p = 0.000$ ).

**Conclusion:** Compared with femoral nerve block combined with superior popliteal sciatic nerve block, IPACK combined with adductor canal block had a mild impact on early motor functions after TKA.

© 2021 Published by Elsevier Editora Ltda. on behalf of Sociedade Brasileira de Anestesiologia. This is an open access article under the CC BY-NC-ND license (<http://creativecommons.org/licenses/by-nc-nd/4.0/>).

\* Corresponding author.

E-mail: [liuyingzhi.1070@163.com](mailto:liuyingzhi.1070@163.com) (Y. Liu).

<https://doi.org/10.1016/j.bjane.2021.04.012>

© 2021 Published by Elsevier Editora Ltda. on behalf of Sociedade Brasileira de Anestesiologia. This is an open access article under the CC BY-NC-ND license (<http://creativecommons.org/licenses/by-nc-nd/4.0/>).

## Introduction

Total Knee Arthroplasty (TKA) is the best treatment option for patients with end-stage joint disease as it provides the benefits of relieving pain and improving joint function.<sup>1</sup> However, despite the effectiveness of this approach, the rehabilitation of limbs after a TKA operation still faces critical challenges. Pain is the most difficult factor to control following TKA; however, the development of an ultrasound-guided nerve block has helped to reduce postoperative pain to a certain extent.<sup>2</sup> Within the model of Enhanced Recovery After Surgery (ERAS), it is required that a patient's pain should be fully controlled after the operation to help achieve early limb autonomous movement, speed up the rehabilitation process, shorten hospital stays, and improve patient satisfaction.<sup>3,4</sup> Femoral nerve block combined with sciatic nerve block is used for postoperative analgesia; while this achieves a satisfactory analgesic effect, it presents the issues of quadriceps femoris weakness and calf weakness, which limit early autonomic exercise and activity of the joints and increase the risk of falls after surgery. Additionally, it can easily cover up peroneal nerve injuries, which occur frequently, as well as other nerve injuries that take place during the operation.<sup>5</sup> Studies have confirmed that an adductor canal block has satisfactory analgesic effects and does not affect quadriceps femoris muscle strength; consequently, it could replace the femoral nerve block.<sup>6,7</sup> However, this method cannot prevent posterior knee pain.

The ERAS model was first proposed by Professor Henrik Kehlet at the Copenhagen University in Denmark in 1997, and it was introduced to China by academician Jieshou Li in 2006. In ERAS, the goals of pain management are to minimize postoperative pain, promote early recovery and rehabilitation, and improve the patient's functional outcomes.<sup>8</sup> Analgesia after TKA has been the focus of several studies in recent years, and it has been found that ultrasound-guided nerve block analgesia can significantly improve patient satisfaction. Following the introduction of ERAS and the improvement of the analgesic effect, a new goal is to achieve self-controlled joint movement as early as possible after an operation. However, limited research has been conducted to date on the early recovery of motor function after an operation. Infiltration between the Popliteal Artery and the Capsule of the Knee (IPACK) is a new method that has been proposed in recent years as a potential alternative to the sciatic nerve block. Its combined use with adductor canal block has a good analgesic effect and little impact on the muscle strength of the affected limbs post-operation, and patients treated with this method can participate in early rehabilitation exercise, have shorter hospital stays, and report improved satisfaction.<sup>9</sup> In the present study, we aimed to evaluate the impact of ultrasound-guided IPACK combined with adductor canal block on limb motor function and early functional rehabilitation of the knee joint in patients undergoing TKA.

## Methods

### Patient information

The ethics committee of the researchers' hospital approved the present study (Medical Ethics Approval Number:

QYFYWZLL 25588). All patients provided written informed consent before undergoing surgery. From January 2018 to August 2018, 60 male and female patients who were scheduled to undergo elective unilateral knee arthroplasty were enrolled in this study. The age range of these patients was 50–80 years, their bodyweight ranged from 50 to 90 kg, and each patient had an American Society of Anesthesiologists (ASA) physical status of I–III. All patients met the following inclusion and exclusion criteria: no history of anesthetic allergy or nerve damage; no infectious diseases; normal coagulation function; and no history of severe hepatorenal insufficiency, psychiatric disorders, or drug dependence.

The patients were divided into two groups according to the random number table method: a group treated with IPACK combined with adductor canal block (I group, n = 30), and a group treated with femoral nerve block combined with superior popliteal sciatic nerve block (FS group, n = 30).

### Surgical procedure

The patient entered the operation room. The venous access was opened, and the patient inhaled oxygen. The patient's pulse, oxygen saturation, electrocardiogram, Bispectral Index (BIS), and invasive arterial blood pressure were monitored. The ultrasound-guided intraplanar needling technique was used to apply the nerve block. The ultrasound probe was covered with an aseptic mantle, the skin was disinfected, and local infiltration anesthesia was induced with 1% lidocaine. The disposable puncture needle was connected to a syringe containing ropivacaine.

In the I group, the IPACK block and adductor canal block were performed under ultrasound guidance. The IPACK block steps can be summarized as follows. The ultrasound probe scanned the popliteal fossa. After the femoral condyle appeared in the field, the ultrasound probe moved toward the head until the femoral shaft appeared, and the popliteal artery was visible. The puncture needle was inserted from the lateral knee joint to the site between the popliteal artery and the femur, and 25 mL of 0.375% ropivacaine was injected. For the adductor canal block, the ultrasound probe was placed at the midpoint of the connecting line between the greater trochanter of the femur and the upper edge of the patella,<sup>10</sup> and the ultrasound-guided puncture was performed. After the site of the needle tip was confirmed, the needle was withdrawn. When it was confirmed that there was no blood on the needle, 15 mL of 0.375% ropivacaine was injected.

Patients in the FS group received the femoral nerve block and superior popliteal sciatic nerve block under ultrasound guidance. For the femoral nerve block, the ultrasound probe scanned the inguinal region of the affected limb on a short-axis transverse section. After successful puncture, the needle was withdrawn, and when it was confirmed that there was no blood inside the needle, 20 mL of 0.375% ropivacaine was injected.<sup>11–13</sup> For the superior popliteal sciatic nerve block, the patient flexed their limbs and knees while lying on their back. The ultrasound probe scanned at 8–10 cm on the lateral knee joint. After successful puncture, the needle was withdrawn, and when it was confirmed that there was no blood inside the needle, 20 mL of 0.375% ropivacaine was injected.

General anesthesia was performed after successful application of the nerve blocks. For anesthesia induction, 20  $\mu\text{g}$  of sufentanil, 1.5  $\text{mg}\cdot\text{kg}^{-1}$  of propofol, and 0.2  $\text{mg}\cdot\text{kg}^{-1}$  of atracurium cis-benzene sulfonate were used, and a laryngeal mask intubation was performed. For anesthesia maintenance, 0.1  $\text{mg}\cdot\text{kg}^{-1}\cdot\text{min}^{-1}$  of propofol was continuously infused, atracurium cis-benzene sulfonate was intermittently injected, and 10  $\mu\text{g}$  of sufentanil was intravenously injected before the skin incision was completed. During the operation, sufentanil was added as necessary according to vital signs, and BIS was maintained within the range 45–60. Patient-controlled intravenous analgesia was given for 48 hours after the operation, consisting of 50  $\mu\text{g}$  of sufentanil, a 6-mg butorphanol tartrate injection, and 8 mg of ondansetron, added with normal saline to achieve a total volume of 100 mL. The background infusion volume was 2  $\text{mL}\cdot\text{h}^{-1}$ , the self-control single additional volume was 2 mL, and the duration was 15 minutes. Celecoxib capsules were taken orally to relieve pain. The visual analogue scale score was maintained at  $\leq 3$  points.

### Main outcomes

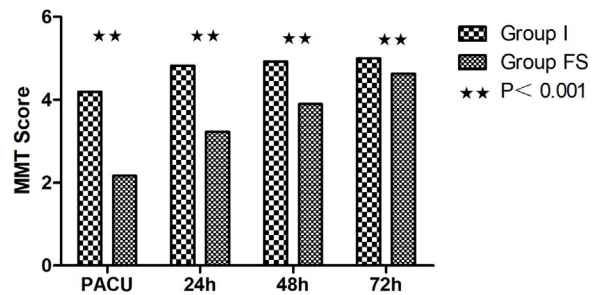
The modified Bromage score and quadriceps femoris muscle strength score at the point of leaving the Postanesthesia Care Unit (PACU) and at 24, 48, and 72 hours post-operation, as well as walking distance at 48 and 72 hours post-operation, were recorded. Secondary outcomes such as incidence of infection, hematoma, and nerve injury caused by the nerve block were recorded.

The quadriceps femur muscle strength score at PACU, 24, 48, and 72 hours after surgery was evaluated using the Manual Muscle Testing (MMT) muscle strength grading standard: failure to contract muscles at all = 0 points; muscles may contract slightly, but the joint cannot move = 1 point; without gravitational resistance, the joint can achieve a full range of motion = 2 points; the joint can resist gravity for a full range of motion, but it cannot exert resistance = 3 points; the joint shows resistance to gravity and partial resistance to motion = 4 points; and the joint shows resistance to gravity and complete resistance to motion = 5 points.

The modified Bromage score at PACU, 24, 48, and 72 hours postoperatively was measured as follows: no motor nerve block in the lower extremity = 0 point; the affected limb cannot lift the leg = 1 point; failure to bend the knee of the affected limb = 2 points; and failure to bend the ankle = 3 points. The distance between the patient's bed and each relevant position in the ward was measured and marked. The patient got out of bed to exercise according to a prescribed route, and the daily walking route was recorded to calculate the walking distance.

### Statistical analysis

Data were statistically analyzed using SPSS 24.0 statistical software. Normally distributed measurement data were expressed as mean  $\pm$  standard deviation ( $\bar{x} \pm \text{SD}$ ), and comparisons between the groups were conducted using a *t*-test. The non-normally distributed measurement data were also compared using a Wilcoxon rank-sum test. Data of the same index acquired at different times were compared using a



**Figure 1** Comparison of Quadriceps muscle strength score (\*\*\*,  $p = 0.001$ ). PACU, when leave the Postoperative Anesthesia Care Unit; MMT score, Manual Muscle Test score (\*\*:  $p < 0.001$ ).

repeated-measures analysis of variance, and counting data were compared using a chi-square test. A  $p$ -value of  $< 0.05$  was considered statistically significant.

### Results

The differences in general characteristics between the two groups were not statistically significant: age ( $p = 0.984$ ); gender ( $p = 0.639$ ); Body Mass Index (BMI) ( $p = 0.610$ ); and ASA physical status ( $p = 0.478$ ) (Table 1).

#### Comparison of quadriceps femoris muscle strength scores after the operation

There was a statistically significant difference between the quadriceps femoris muscle strength scores of the I group and the FS group ( $p < 0.001$ ). The score was significantly higher in the I group than in the FS group at each time point after the operation: 4.2 vs. 2.17 at PACU; 4.83 vs. 3.23 at 24h; 4.93 vs. 3.90 at 48h; and 5.0 vs. 4.63 at 72h (Fig. 1).

#### Comparison of the degree of motor block in the affected limbs

The difference in the degree of the motor block in the affected limbs between the two groups was statistically significant ( $p = 0.000$ ). The Bromage score of the affected limbs was significantly lower in the I group than in the FS group at each time point within 48 hours after the operation: 0.33 vs. 2.97 at PACU; 0.07 vs. 1.20 at 24h; and 0.03 vs. 0.37 at 48h ( $p = 0.000$ ). However, the muscle strength of the affected limbs returned to normal at 72 hours for all patients, and the Bromage score was 0 in both groups (0 vs. 0,  $p = 1.000$ ). Thus, there was no statistically significant difference between the modified Bromage scores of the affected limbs for the two groups at this time point (Fig. 2).

#### Comparison of walking distance at an early stage after the operation

There was a statistically significant difference between the walking distances of the two groups at an early stage after the operation ( $p = 0.000$ ). The difference between the two groups at 72 hours was statistically significant, with a significantly longer distance in the I group than in the FS group

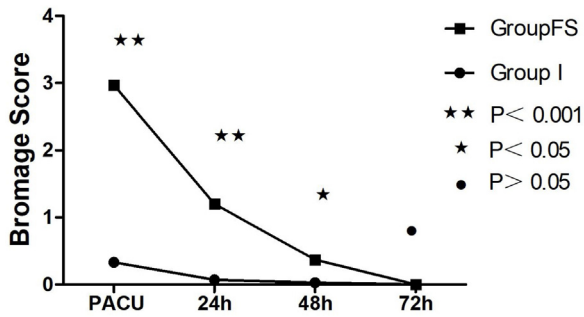
**Table 1** Demographic characteristics of patients undergoing total knee arthroplasty.

Group	Age (years)	Gender, n (Female/Male)	BMI (kg.m <sup>-2</sup> )	ASA grade, n (I/II/III)
I group (n = 30)	67.8 ± 6.4	21/9	27.1 ± 3.4	12/13/5
FS group (n = 30)	67.8 ± 6.7	20/10	26.7 ± 2.7	15/11/4
p-value	0.984	0.639	0.610	0.478

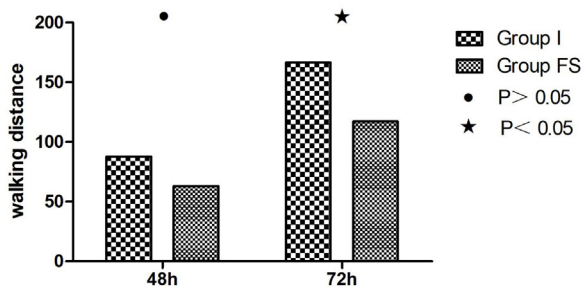
BMI, Body Mass Index; ASA, American Society of Anesthesiologists.

I group: a group with IPACK combined with an adductor canal block.

FS group: a group with femoral nerve block combined with superior popliteal sciatic nerve block.



**Figure 2** Comparison of Bromage score. PACU: when leave the Postoperative Anesthesia Care Unit (●:  $p < 0.05$ ; \*:  $p < 0.05$ ; \*\*:  $p < 0.001$ ).



**Figure 3** Comparison of postoperative walking distance (●:  $p < 0.05$ ; \*:  $p < 0.05$ ).

(167.14 vs. 118.39,  $p = 0.002$ ). However, the difference at 48 hours was not statistically significant (88.21 vs. 63.55,  $p = 0.079$ ) (Fig. 3).

### Comparison of postoperative complications and adverse reactions

No postoperative complications in terms of infection, hematoma, or nerve injury occurred in either group. Foot drop occurred in two patients in the I group and in 28 patients in the FS group. The incidence of the foot drop was thus significantly lower in the I group at a significant level (0.07 vs. 0.93,  $p = 0.00$ ).

### Discussion

A previous study confirmed that an adductor canal block can replace a femoral nerve block to achieve adequate postoperative analgesia, reduce postoperative impact on quadriceps femoris muscle strength, and promote early participation

of patients in functional exercise.<sup>14</sup> However, there remains the issue of posterior knee-joint pain associated with the adductor canal block. The IPACK block approach solves this problem. Previous studies have shown that IPACK combined with an adductor canal block has a better analgesic effect than the latter in isolation and is conducive to the early functional recovery of patients.<sup>15–18</sup>

Quadriceps femoris muscle strength is one of the main indicators for evaluating the early motor function of patients after an operation. The findings of the current study revealed a statistically significant difference between the quadriceps femoris muscle strength scores of the I group and the FS group, with the score in the I group being significantly higher than that in the FS group at each measured time point. The difference between the walking distances for the two groups was statistically significant at an early stage after the operation and at 72 hours post-operation, with a significantly higher distance in the I group than in the FS group. The results of the two groups displayed significantly less impact on the muscle strength of the affected limbs for patients in the I group than for the FS group, indicating that the IPACK treatment was conducive to the early recovery of joint motor function. Dr. Paolo Scimia confirmed similar results in a study showing that IPACK combined with an adductor canal block was an effective method for achieving effective early analgesia and timely postoperative functional rehabilitation, reducing perioperative complications, and shortening hospitalization time.<sup>19</sup>

However, the difference between the walking distances of the two groups was not statistically significant at 48 hours post-operation; this may be due to ward management affecting the distance time after the surgery. After the operation, a drainage tube was in place for 24–48 hours to drain blood from the knee, and it was only after the drainage tube was pulled out that the patient was allowed to participate in out-of-bed activity; this policy thus directly affected walking distance within the first 48 hours. A previous study revealed that some patients undergoing IPACK combined with an adductor canal block can undertake out-of-bed activity immediately after outpatient surgery and can be discharged within 1–2 days.<sup>9</sup> Therefore, in follow-up studies, we will also observe whether patients can undergo out-of-bed activity immediately after the operation (without drainage).

The modified Bromage score is an observation index that is mainly used to evaluate the degree of overall motor block following limb surgery. In the present study, the post-operation modified Bromage score was significantly lower in the I group than in the FS group, indicating a significantly lower degree of motor block in the affected limbs in the I



group than in the FS group. This finding demonstrates that IPACK combined with adductor canal block had little impact on the muscle strength of the lower limbs after the operation and in early functional exercises.

In the present study, the incidence of foot drop was also significantly lower in the I group than in the FS group; this finding was consistent with the modified Bromage score findings and reveals that the IPACK block can significantly reduce foot drop caused by a sciatic nerve block. However, temporary foot drops still occurred in two patients in the I group. Through analysis, we consider that these cases may have been due to infiltration of the common peroneal nerve caused by the drug diffusion. This is consistent with results reported by Niesen et al.,<sup>20</sup> who revealed through fresh corpse autopsy that common peroneal nerve infiltration occurred in two patients, and tibial nerve infiltration occurred in one patient, when IPACK blocked the drug diffusion. These results reveal that, although an IPACK block can help to avoid foot drop caused by a sciatic nerve block, an incorrect injection location also carries a risk of causing temporary foot drop. Further clinical trials are needed to determine the best site for administering the IPACK block, as well as the optimal concentration and volume of liquid medicine to ensure the effectiveness and safety of this method.

## Conclusions

The present study revealed that IPACK combined with an adductor canal block for analgesia after TKA has little impact on postoperative muscle strength, can result in early out-of-bed activity and rehabilitation exercises, is conducive to early self-controlled functional recovery of the knee joint, accelerates the rehabilitation process, and has a superior analgesic effect to the traditional femoral nerve block combined with superior popliteal sciatic nerve block. This treatment approach conforms to the ERAS model.

## Conflicts of interest

The authors declare no conflicts of interest.

## Acknowledgments

None.

## References

1. Brander V, Stulberg SD. Rehabilitation after hip and knee joint replacement. An experience and evidence-based approach to care. *Am J Phys Med Rehabil.* 2006;85:598–118, quiz S119–23.
2. Lu FJ, Shi YS. Analgesia for total knee arthroplasty: a review of lower extremity nerve blocks. *Int J Anesthesiol Resusc.* 2018;39:79–83.
3. Deng QF, Gu HY, Peng WY, et al. Impact of enhanced recovery after surgery on postoperative recovery after joint arthroplasty: results from a systematic review and meta-analysis. *Postgrad Med J.* 2019;94:678–93.
4. Zhu S, Qian W, Jiang C, et al. Enhanced recovery after surgery for hip and knee arthroplasty: a systematic review and meta-analysis. *Postgrad Med J.* 2017;93:736–42.
5. Grape S, Kirkham KR, Baeriswyl M, et al. The analgesic efficacy of sciatic nerve block in addition to femoral nerve block in patients undergoing total knee arthroplasty: a systematic review and meta-analysis. *Anaesthesia.* 2016;71:1198–209.
6. Elkassabany NM, Antosh S, Ahmed M, et al. The risk of falls after total knee arthroplasty with the use of a femoral nerve block versus an adductor canal block: a double-blinded randomized controlled study. *Anesth Analg.* 2016;122:1696–703.
7. Li D, Ma GG. Analgesic efficacy and quadriceps strength of adductor canal block versus femoral nerve block following total knee arthroplasty. *Knee Surg Sports Traumatol Arthrosc.* 2016;24:2614–9.
8. Holm B, Bandholm T, Lunn TH, et al. Role of preoperative pain, muscle function, and activity level in discharge readiness after fast-track hip and knee arthroplasty. *Acta Orthop.* 2014;85:488–92.
9. Thobhani S, Scalercio L, Elliott CE, et al. Novel regional techniques for total knee arthroplasty promote reduced hospital length of stay: an analysis of 106 patients. *Ochsner J.* 2017;17:233–8.
10. Wang CG. Study on the analgesic effect of adductor canal block for total knee arthroplasty. Suzhou University; 2017.
11. Hu HS, Huang JJ, An XF, et al. Effects of different concentrations of ropivacaine on phrenic nerve conduction after intermuscular sulcus brachial plexus block. *Zhejiang Med.* 2018;40:2287–90.
12. Tao Y, Zheng SQ, Xu T, et al. Median effective volume of ropivacaine 0.5% for ultrasound-guided adductor canal block. *J Int Med Res.* 2018;46:4207–13.
13. Christiansen CB, Madsen MH, Rothe C, et al. Volume of ropivacaine 0.2% and common peroneal nerve block duration: a randomised, double-blind cohort trial in healthy volunteers. *Anaesthesia.* 2018;73:1361–7.
14. Wang D, Yang Y, Li Q, et al. Adductor canal block versus femoral nerve block for total knee arthroplasty: a meta-analysis of randomized controlled trials. *Sci Rep.* 2017;7:40721.
15. Sankineani SR, Reddy ARC, Eachempati KK, et al. Comparison of adductor canal block and IPACK block (interspace between the popliteal artery and the capsule of the posterior knee) with adductor canal block alone after total knee arthroplasty: a prospective control trial on pain and knee function in immediate postoperative period. *Eur J Orthop Surg Traumatol.* 2018;28:1391–5.
16. Tran J, Peng PWH, Lam K, et al. Anatomical Study of the Innervation of Anterior Knee Joint Capsule: Implication for Image-Guided Intervention. *Reg Anesth Pain Med.* 2018;43:407–14.
17. Kandarian B, Indelli PF, Sinha S, et al. Implementation of the IPACK (Infiltration between the Popliteal Artery and Capsule of the Knee) block into a multimodal analgesic pathway for total knee replacement. *Korean J Anesthesiol.* 2019;72: 238–44.
18. Reddy GAV, Jangale A, Reddy RC, et al. To compare effect of combined block of adductor canal block (ACB) with IPACK (Interspace between the Popliteal Artery and the Capsule of the posterior Knee) and adductor canal block (ACB) alone on Total knee replacement in immediate postoperative rehabilitation. *Int J Orthod Sci.* 2017;3:141–5.
19. Kampitak W, Tansatit T, Tanavalee A, et al. Optimal location of local anesthetic injection into the interspace between the popliteal artery and posterior capsule of the knee (iPACK) for posterior knee pain after total knee arthroplasty: an anatomical and clinical study. *Korean J Anesthesiol.* 2019;72: 486–94.
20. Niesen AD, Harris DJ, Johnson CS, et al. Interspace between popliteal artery and posterior capsule of the knee (IPACK) injectate spread: a cadaver study. *J Ultrasound Med.* 2019;38:741–5.