

Available online at [www.sciencedirect.com](http://www.sciencedirect.com)

ScienceDirect

journal homepage: [www.elsevier.com/locate/radcr](http://www.elsevier.com/locate/radcr)

## Case Report

# Imaging of primary testicular lymphoma with unusual intraabdominal spread along the spermatic cord and gonadal vein

Prateek Kumar Madaan, MD\*, Pooja Jain, MD, Anuradha Sharma, MD, Amita Malik, MD, Ritu Nair Misra, MD

Department of Radiodiagnosis and Interventional Radiology, VMMC and Safdarjung Hospital, Ring Road, New Delhi 110029, India

## ARTICLE INFO

## Article history:

Received 22 November 2020

Revised 30 November 2020

Accepted 3 December 2020

## Keywords:

Lymphoma

Non-Hodgkin

Primary testicular lymphoma

Testicular neoplasms

Seminal cord

## ABSTRACT

Primary testicular lymphoma (PTL) is a rare Testicular neoplasm found in elderly patients. Imaging features in PTL presenting with contiguous involvement of spermatic cord and extension along gonadal vein have been rarely detailed before. We describe a case of a 50-year-old male who presented with complaints of scrotal swelling and abdominal discomfort. Imaging, which included Ultrasonography and contrast-enhanced computed tomography of chest-abdomen, showed features of aggressive-looking bilateral testicular mass lesions with the distinctive feature of contiguous spread along the spermatic cord and gonadal vein till retroperitoneum and disseminated chest and abdominal metastases. The distinctive feature of contiguous extension along the spermatic cord and gonadal vein can help suggest a diagnosis of PTL on imaging.

© 2020 The Authors. Published by Elsevier Inc. on behalf of University of Washington.

This is an open access article under the CC BY-NC-ND license (<http://creativecommons.org/licenses/by-nc-nd/4.0/>)

## Introduction

Primary testicular lymphoma (PTL) is a very rare testicular tumor accounting for approximately 9% of all testicular tumors and 1% of all Non-Hodgkin's lymphoma (NHL) cases [1,2]. PTL is the most common testicular neoplasm in patients older than 60 years of age and is the most common bilateral testicular neoplasm overall [3]. It has a propensity to dis-

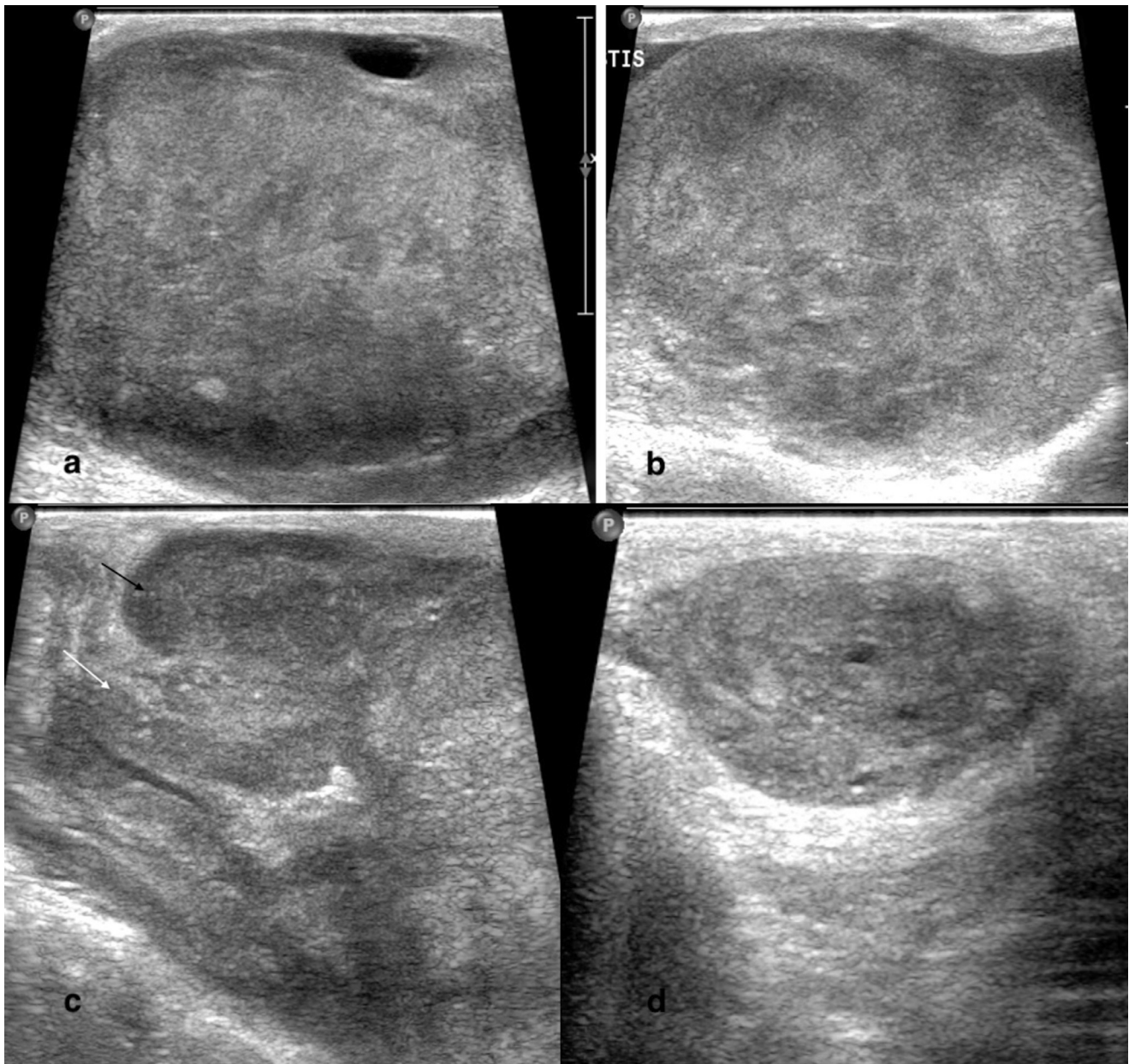
seminate to extranodal sites such as the central nervous system, Waldeyer ring, lungs, pleura, soft tissues, and contralateral testis [1]. PTL presenting with contiguous involvement of spermatic cord and extension along gonadal vein is a rarely described occurrence detailed in only a handful of case reports till now [4–6]. Here, we present a case of an elderly male patient who had bilateral testicular involvement with contiguous extension along the spermatic cord and the gonadal vein till the retroperitoneum. This presentation, although rare,

\* Corresponding author.

E-mail address: [madaan1991@gmail.com](mailto:madaan1991@gmail.com) (P. Kumar Madaan).

<https://doi.org/10.1016/j.radcr.2020.12.003>

1930-0433/© 2020 The Authors. Published by Elsevier Inc. on behalf of University of Washington. This is an open access article under the CC BY-NC-ND license (<http://creativecommons.org/licenses/by-nc-nd/4.0/>)



**Fig. 1** – Ultrasound of scrotum shows Bulky left (a) and right testis (b) with heterogeneously hypoechoic echotexture (c) Bulky left epididymal head (black arrow) and thickened left spermatic cord (white arrow) (d) Thickened and hypoechoic left spermatic cord.

can be used as a clue to differentiate PTL with intrabdominal spread from diffuse NHL with secondary testicular dissemination.

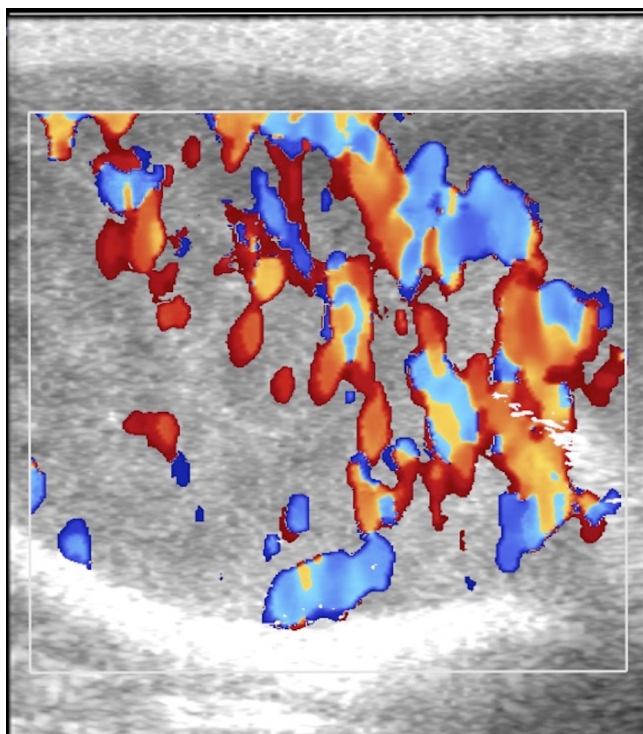
### Case report

A 50-year-old male presented to the urology department with complaints of scrotal swelling and abdominal discomfort. The patient's symptoms started 6 months ago when he noticed swelling in the scrotal region (left side greater than right side). The swelling was slowly progressive and not associated with

pain. The patient developed abdominal discomfort and difficulty in walking because of the testicular swelling around 1 month ago. There was no significant Past or Family history.

On examination, there was an enlargement of bilateral testis which were firm in consistency. There was no tenderness or skin erythema. Mild abdominal distension was present. Rest of the physical examination was within normal limits.

The patient was referred to Radiology department for ultrasonography (USG) of abdomen and scrotum. USG of scrotum revealed diffuse bilateral testicular enlargement with a heterogeneously hypoechoic echotexture (Fig. 1a and b). Few ill-defined anechoic areas were seen in the right testis. Bilateral



**Fig. 2 – Raised vascularity in the right testis and epididymis on Doppler examination.**

epididymis also appeared bulky and heterogenous in echotexture (Fig. 1c). On the left side, the spermatic cord appeared hypoechoic and thickened in its entire extent and showed raised vascularity (Fig. 1d). A mild bilateral hydrocele was seen.

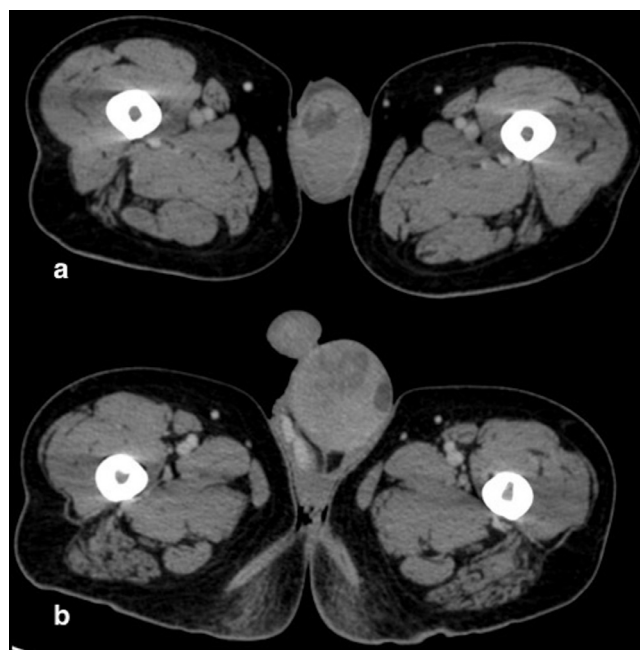
On color Doppler, there was raised vascularity in bilateral testes and epididymis (Fig. 2).

On ultrasound abdomen, bilateral kidneys appeared enlarged and hypoechoic with mild hydronephrosis on the left side. There was a retroperitoneal lymph nodal mass on left anterolateral aspect of aorta with encasement of the latter. Given the clinical and ultrasonographic findings, a provisional diagnosis of NHL was made and the patient was planned for contrast-enhanced computed tomography of chest, abdomen, and pelvis.

Contrast-enhanced computed tomography scan revealed heterogeneously enhancing diffusely enlarged bilateral testes and epididymis with bilateral hydrocele (Fig. 3). Right testis measured 5.9 cm (anteroposterior [AP]) × 3.5 cm (transverse [TR]) × 4.4 cm (length) and left testis measured 6.1 cm (AP) × 5.4 cm (TR) × 8.8 cm (length) (normal testis size - 3 cm [AP] × 2-4 cm [TR] × 3-5 cm [length]).

Enhancing soft tissue mass was seen to extend from the left scrotal region contiguously along the spermatic cord and gonadal vein on the left side till the retroperitoneal region where it was seen to merge with a large heterogeneously enhancing retroperitoneal nodal mass measuring 7.7 cm (AP) × 6 cm (TR) × 10 cm (length), encasing the major vessels and left ureter (Fig. 4).

Both kidneys appeared heterogenous in attenuation and showed a striated nephrographic pattern. Right kidney mea-



**Fig. 3 – CECT images show (a) Enlarged right testis with non-enhancing hypodense areas within. (b) Enlarged left testis with heterogeneous appearance and associated mild hydrocele.**

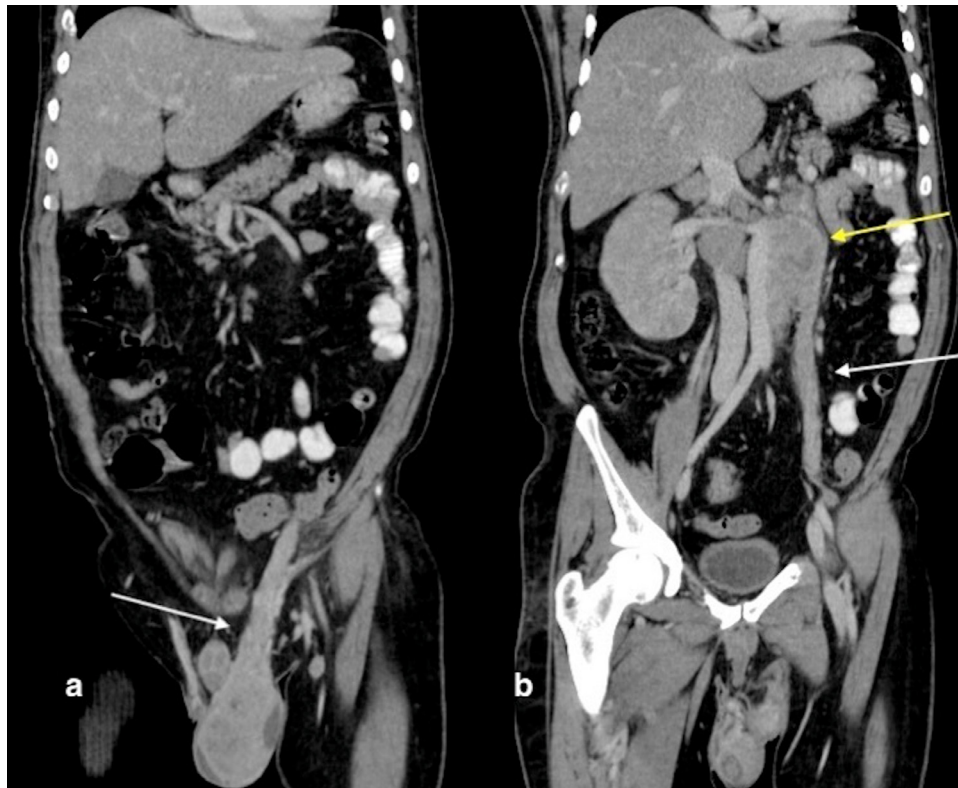
sured 11.2 (length) × 6 cm (TR). Left kidney measured 11.2 (length) × 6.3 cm (TR; normal adult kidney size-  $10.8 \pm 1.2$  cm for the right, and  $11.1 \pm 1.2$  cm for the left kidney). Perinephric stranding was noted bilaterally along with left proximal hydronephrosis (Fig. 5a). Bilateral adrenal glands appeared diffusely enlarged (Fig. 5b). In addition, homogeneously enhancing enlarged mediastinal lymph nodes were seen in the right hilar region and bilateral paratracheal regions (Fig. 5c). Another homogeneously enhancing enlarged left axillary lymph node was seen. Lytic lesions were seen distributed throughout the skeletal system involving pelvic bones, multiple vertebrae, bilateral femur and humerus head, few of which were associated with enhancing soft tissue (Fig. 5d) and pathological fracture.

Laboratory investigations of tumor markers revealed raised Lactate Dehydrogenase (LDH) – 725 U/L (normal 140-280 U/L), normal Alpha-Fetoprotein (AFP) – 4.02 ng/mL (normal 0-40 ng/mL), and Beta Human Chorionic Gonadotropin (HCG) – less than 1.2 mIU/mL (normal is less than 2 mIU/mL) levels.

Based on the above findings, a diagnosis of PTL (NHL) with widespread dissemination was made.

The patient was taken up for left-sided radical inguinal orchidectomy. Histopathology revealed a fleshy tumor replacing the entire testis. The finding of the spread of tumor along the left spermatic cord and gonadal vein was confirmed. Further, it was found that there was microscopic spread of the tumor along the right spermatic cord as well, which was not apparent on imaging. On IHC, cells showed strong and diffuse positivity for CD 20 and Bcl2. The final diagnosis was primary testicular (diffuse large B cell Non-Hodgkin) lymphoma.





**Fig. 4 – (a) Coronal oblique reformatted CECT abdomen shows enhancing soft tissue extending proximally from left scrotum along the left spermatic cord. (b) Coronal oblique reformatted CECT abdomen at a section dorsal to that shown in 4a shows the intra-abdominal extension of soft tissue along the left gonadal vein (white arrow) reaching up to and merging with the retroperitoneal nodal mass (yellow arrow).**

The patient was subsequently started on chemotherapy. However, his condition deteriorated and he expired approximately 1 month after commencement of chemotherapy.

## Discussion

Testicular Non-Hodgkin's Lymphoma (TNHL) is a rare disease, which forms 1% of NHL cases and makes up approximately 5%-10% of all the testicular neoplasms [7]. The age group most affected by TNHL is elderly males between 60 and 80 years. Moreover, TNHL is the most common testicular neoplasm presenting with bilateral involvement [1]. According to previous reports, metachronous involvement of bilateral testes is seen in 35% cases and synchronous involvement of bilateral testis in 3% cases [8]. Secondary involvement of testis is more common than primary extranodal TNHL [1]. Microscopic testicular invasion is seen in post mortem examination in 20% of patients with disseminated NHL [7].

The differential diagnosis of bilateral testicular mass in elderly patient are lymphoma, metastasis and spermatocytic seminoma. In our case, the patient's age was 50 years, which doesn't fall in the reported age group for primary TNHL. However, his age was much more than that expected for the other close differential of seminoma, which usually affects men between 30 and 40 years of age. Our patient presented with bi-

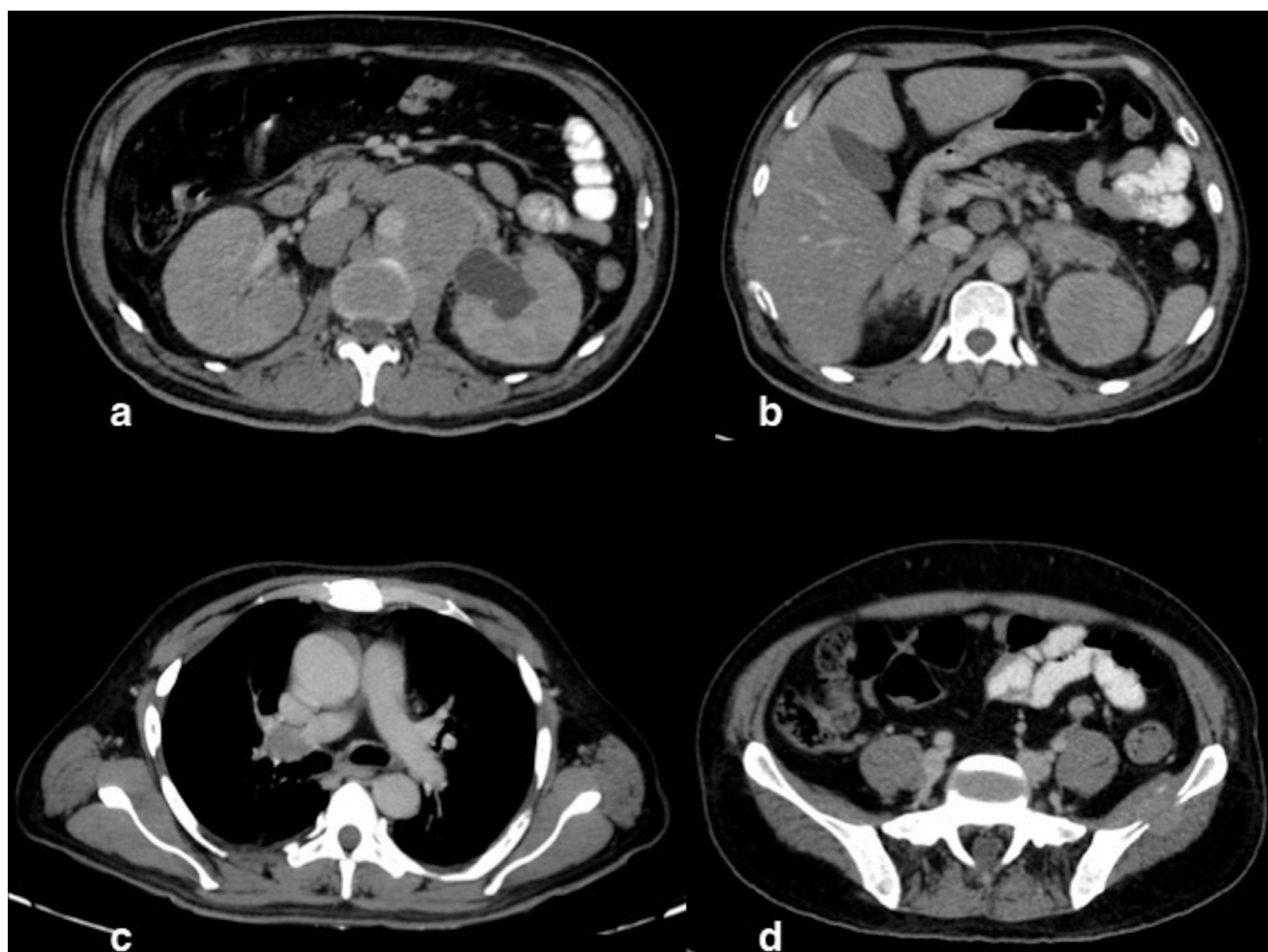
lateral asymmetrical involvement of testis suggestive of synchronous involvement of bilateral testis by the neoplasm.

To date, no well-documented etiological or risk factor for primary TNHL has come forth. Unlike other common testicular neoplasms, no significant association of Primary TNHL has been seen with cryptorchidism, trauma, chronic orchitis, or infertility [7].

On histopathology, the majority of primary TNHL are diffuse large B cell lymphomas with only small percentage being of the T cell type [1,3]. This is consistent with the finding in our case of a diffuse large B cell NHL.

Tumor markers have been described to be less useful for Primary TNHL cases compared to germ cell tumors. Although LDH can be used as a marker of overall burden, AFP and Beta HCG are rarely elevated [3]. Similarly, in our case, LDH was increased and the rest of the markers were within normal limits. The negative markers that is, AFP and Beta HCG are important to rule out germ cell tumors in our case.

USG is generally the first-line imaging modality to be used for the characterization of testicular lesions. Lymphoma appears as hypoechoic lesions, which can be either in the form of a single large mass, or as multiple small lesions involving a major part of testicular parenchyma or replacing it entirely. Hypervascularity is seen on Color Doppler [9]. Due to the infiltrative nature of the pathology, normal testicular vessels have been described to cross the lesions which can serve as a useful guide toward diagnosis [10].



**Fig. 5** – Series of axial CECT chest and abdomen images show (a) Large retroperitoneal nodal mass is seen to encase aorta and inferior vena cava. Bilateral kidneys appear enlarged and diffusely hypodense with subtle striated nephrogram pattern. (b) Bilateral diffuse enlargement of adrenal glands. (c) Enlarged hypo enhancing right hilar lymph node at the level of the carina. (d) Enhancing soft tissue within the left iliac bone with the erosion of both cortex s/o lymphomatous involvement of the bone. Multiple other bones were involved as well.

In our case, USG showed findings consistent with those described in previous studies. However, the finding of contiguous thickening of the spermatic cord is rarely described in previous literature.

On CT, findings are of heterogeneously enhancing hypodense mass lesion either replacing the entire testis or involving a major part of it. Associated involvement of epididymis and hydrocele is also seen. On Magnetic Resonance Imaging, the characteristic features of testicular lymphoma are homogeneous mass lesion, which replaces the entire testis, appearing hyperintense on T1-weighted images, and signal intensity ranging from isointense to hypointense on T2-weighted images. Lymphoma also demonstrates moderate-to-strong diffusion restriction and homogeneous contrast enhancement. Calcifications and hemorrhages are uncommon [4].

In our case, the appearance of the testicular mass with contralateral spread on CT was similar to what has been described previously. However, the additional findings that were

observed such as diffuse lymphomatous spread to retroperitoneum, axillary, and mediastinal lymph nodes, adrenals, kidneys, and bones make our case unique. Primary TNHL has been shown to disseminate to the central nervous system, Waldeyer ring, lungs, or pleura [1]; whereas the sites of tumor dissemination in our case were different from those classically described in Primary TNHL.

The most important finding in our case which sets it apart from those previously described is the contiguous involvement of spermatic cord and gonadal vein in the form of homogeneously enhancing soft tissue extending along these structures on the left side. This finding has been described so far in only a few case reports in the available literature [4–6].

A close differential diagnosis of Primary TNHL is secondary involvement of testis in widespread NHL which is more common [1]. However, these cannot be reliably distinguished on imaging or histopathology. This feature of contiguous spread of tumor along the spermatic cord and gonadal vein described

in our case of Primary TNHL can serve as an important distinction between the two; as this is not a feature of secondary involvement in widespread NHL [4–6]. Only a few case reports exist so far detailing the feature of contiguous tumor spread along the spermatic cord and gonadal vein as a pathognomic feature of Primary TNHL [4–6]. Sabale et al [4] described 2 cases of Primary TNHL that showed extension of soft tissue along epididymis and spermatic cord into inguinal canal with further continuous extension along the gonadal vein up to inferior vena cava. Sabarwal and Ismail [5] described a case of unilateral testicular mass with soft tissue seen to extend along the spermatic cord and infiltrate the gonadal vein. Ellatif et al [6] described 2 cases, both showing cord-like soft tissue extending in a contiguous fashion from the testicular mass onto the spermatic cord and gonadal vessels in the retroperitoneum.

No specific clinical criteria were found on review of literature that serve to define and distinguish PTL from secondary involvement of testis in NHL. PTL are very aggressive malignancies, with a poor outcome. In spite of initial complete remission, most patients with stage I/II disease experience relapse [2]. Thus the prognosis is poor in PTL compared to secondary lymphoma.

The imaging feature of contiguous spread along spermatic cord and gonadal vein can also be used to differentiate Primary TNHL from seminoma, which is a close imaging mimic.

## Conclusion

Primary TNHL is a rare diagnosis in an elderly patient presenting with testicular mass and carries a worse prognosis than its differentials. It is important to differentiate it from secondary testicular involvement in NHL and the more common testicular neoplasm seminoma. The imaging feature of contiguous involvement of the spermatic cord and gonadal vein can serve as an important clue towards the preoperative diagnosis of primary TNHL.

## Consent statement

Written, informed consent for publication of their case was obtained from the patient's family member.

## REFERENCES

- [1] Shahab N, Doll DC. Testicular lymphoma. *Semin Oncol* 1999;26:259–69.
- [2] Vitolo U, Ferreri AJM, Zucca E. Primary testicular lymphoma. *Crit Rev Oncol Hematol* 2008;65:183–9.
- [3] Møller MB, d'Amore F, Christensen BE. The Danish Lymphoma Study Group, LYFO. Testicular lymphoma: a population-based study of incidence, clinicopathological correlations and prognosis. *Eur J Cancer* 1994;30A:1760–4.
- [4] Sabale A, Prahladan A, Kalidos K, Koshy SM, Ramachandran K. Unusual continuous intra-abdominal spread of primary testicular lymphoma along the spermatic cord and gonadal vessels: Report of 2 cases. *Radiol Case Rep* 2015;10:76–80.
- [5] Sabarwal KS, Ismail EHM. A case of primary testicular lymphoma with continuous spread along the gonadal vein and spermatic cord. *BJR Case Rep* [Internet] 2018;5:20180063. [cited 2020 May 12] Available from: <https://www.ncbi.nlm.nih.gov/pmc/articles/PMC6519503>.
- [6] Ellatif M, Kumar R, Weller A, Katz D, Vrentzou E. Two cases of primary testicular lymphoma presenting with direct spread along the spermatic cord and gonadal vessels. *Case Rep Radiol* [Internet] 2019;2019:5953618. [cited 2020 May 12] Available from: <https://www.ncbi.nlm.nih.gov/pmc/articles/PMC6604472>.
- [7] Bhatia K, Vaid AK, Gupta S, Doval DC, Talwar V. Primary testicular non-Hodgkin's lymphoma—a review article. *Sao Paulo Med J* 2007;125:286–8.
- [8] Sussman EB, Hajdu SI, Lieberman PH, Whitmore WF. Malignant lymphoma of the testis: a clinicopathologic study of 37 cases. *J Urol* 1977;118:1004–7.
- [9] Mazzu D, Jeffrey RB, Ralls PW. Lymphoma and leukemia involving the testicles: findings on gray-scale and color Doppler sonography. *AJR Am J Roentgenol* 1995;164:645–7.
- [10] Bertolotto M, Derchi LE, Secil M, Dogra V, Sidhu PS, Clements R, et al. Grayscale and color Doppler features of testicular lymphoma. *J Ultrasound Med* 2015;34:1139–45.