

THE ORTHOPAEDIC FORUM

Original and Modified Lapidus Procedures

Proposals for a New Terminology

Panagiotis D. Symeonidis, MD, PhD, and John G. Anderson, MD

Investigation performed at St Luke's Hospital, Thessaloniki, Greece

In 1934, Paul W. Lapidus submitted a short report that he would later describe as “personal communication” and “preliminary communication.” It referred to a method of first tarsometatarsal (TMT) arthrodesis for the treatment of a congenital predisposition toward hallux valgus due to metatarsus primus varus¹. Although the procedure was first advocated by Albrecht in 1911², it was Lapidus who popularized the method in the following years. Therefore, the technique righteously bears his name, without Lapidus himself claiming its originality. In his 1960 paper that reviewed the prior 3 decades of having performed the procedure, the author stated that his operative technique “remains essentially the same as described originally.”³

It is interesting to see how the Lapidus procedure currently is presented in 2 leading orthopaedic journals: *The Journal of Bone & Joint Surgery* and *Foot & Ankle International* (Table I). A content search for the terms “Lapidus” and “tarsometatarsal” that included all publication dates revealed a total of 339 papers with either term listed in the title, in the abstract, as a keyword, and/or in the full text. For the term “Lapidus” alone, the relevant number was 65 studies, which include 20 clinical studies of case series, 1 survey, 1 technique description, and 1 case report. The remaining studies were either cadaveric, biomechanical, or radiographic. Additionally, there were 7 review papers that did not have an original patient

population. Modifications of the Lapidus procedure, as described in each clinical paper, are impressively broad (Table II). Indeed, it is hard to find 2 studies in which the exact same technique was used. Even within a single study, some authors reported that they modified their own technique during the study period.

A valid question is: What exactly did Lapidus describe in his original papers? Below is a step-by-step description of the technique in his own words³:

- Anesthesia: general anesthesia.

TABLE I Search Results for the Terms Lapidus and Tarsometatarsal in JBJS and FAI*

Search Term	Title		Abstract		Keyword		Full Text	
	Lapidus	TMT	Lapidus	TMT	Lapidus	TMT	Lapidus	TMT
JBJS	3	14	0	3	NA	NA	124	215
FAI	15	27	31	101	16	29	NA	NA
Combined	18	41	31	104	16	29	124	215

*JBJS = *The Journal of Bone & Joint Surgery*, FAI = *Foot & Ankle International*, TMT = tarsometatarsal, and NA = not applicable.

Disclosure: The authors indicated that no external funding was received for any aspect of this work. The **Disclosure of Potential Conflicts of Interest** forms are provided with the online version of the article (<http://links.lww.com/JBJS/G221>).

Copyright © 2020 The Authors. Published by The Journal of Bone and Joint Surgery, Incorporated. All rights reserved. This is an open-access article distributed under the terms of the [Creative Commons Attribution-Non Commercial-No Derivatives License 4.0](https://creativecommons.org/licenses/by-nc-nd/4.0/) (CCBY-NC-ND), where it is permissible to download and share the work provided it is properly cited. The work cannot be changed in any way or used commercially without permission from the journal.

TABLE II Published Papers on Lapidus Procedures and Modifications*

Study	Level of Evidence	No. of Patients with Follow-up	No. of Surgeons	Joints Stabilized or Fused	Approach
Aiyer et al. (2016) ⁵	III: retrospective comparative series	NR	4	TMT1 + IntCunMT1	NR
Bednarz and Manoli (2000) ⁶	IV: case series	26	1	TMT1, MT1-2 (temporary)	Dorsal (between 1st and 2nd rays) + stab medial incision
Coetzee and Wickum (2004) ⁷	IV: retrospective case series	91	NR	TMT1, MT1-2 (temporary)	Dorsal (between 1st and 2nd rays) + stab medial incision
Coetzee et al. (2004) ⁸	IV: retrospective case series	24	NR	TMT1, MT1-2	Dorsal (between the EHL and EHB) + distal incision in the first web space + medial incision
Conti et al. (2020) ^{9,10}	IV: case series	31	2	TMT1	Dorsal (1st TMT)
DeVries et al. (2011) ¹¹	III: retrospective comparative analysis	134	1	TMT1 ± IntCunMT1	NR
Faber et al. (2004) ¹²	I: therapeutic randomized controlled trial	51	1	TMT1	Dorsal, lateral to EHL + distal incision in the first web space + medial incision
Ellington et al. (2011) ¹³	IV: retrospective case series	23	2	TMT1 ± MT1 to MT2	Dorsal (1st TMT)
Habbu et al. (2011) ¹⁴	IV: retrospective case series	268	2	TMT1 ± MT1-2 (temporary)	NR
Jung et al. (2007) ¹⁵	IV: retrospective case series	12	NR	TMT1	Dorsolateral/medial
Kazzaz and Singh (2009) ¹⁶	IV: retrospective case series	19	1	TMT1	Medial
Klemola et al. (2017) ¹⁷	III: case-control study	58	NR	TMT1	NR
Kopp et al. (2005) ¹⁸	IV: retrospective case series	29	2	TMT1	Dorsal (1st TMT)
Langan et al. (2020) ¹⁹	IV: retrospective case series	62	1	TMT1 + IntCunMT1	Dorsomedial, medial to the EHL
Lee and Manoli (2001) ²⁰	V: Case report	1	1	TMT1 + MT1MT2	NR
MacMahon et al. (2016) ²¹	IV: retrospective case series	48	6	NR	NR
Ray et al. (2019) ²²	IV: retrospective case series	57	4	TMT1	Dorsomedial, medial to the EHL
Rippstein et al. (2012) ²³	IV: retrospective case series	10	1	TMT1	Dorsomedial
Sangeorzan and Hansen (1989) ²⁴	IV: retrospective case series	23	1	TMT1 ± MT1MT2 or MT1IntCun	Dorsal, from the first web space to the TMT1
Thompson et al. (2005) ²⁵	IV: retrospective case series	182	NR	TMT1	Dorsal, from the first web space to the TMT1 ± medial MTP
Toolan (2007) ²⁶	V: expert opinion surgical strategies	NA	NA	TMT1 ± MT1MT2	Dorsal (1st TMT)

*NR = not reported, MT = metatarsal, TMT = tarsometatarsal, IntCun = intermediate cuneiform, MedCun = medial cuneiform, PRP = platelet-rich plasma, ± = with or without, AHL = abductor hallucis longus, EHL = extensor hallucis longus, EHB = extensor hallucis brevis, HV = hallux valgus, DBM = demineralized bone matrix, BMA = bone marrow aspirate, OA = osteoarthritis, MTP = metatarsophalangeal, and NA = not applicable.

TABLE II (continued)

Fixation (in Sequence)	Bone Graft	Orthobiologics	Distal Procedures	Comments
Plates (dorsal-medial) and screws	NR	NR	NR	Comparative study of different methods; fixation technique derived from images/figures (not described in detail in the text)
Two 3.5-mm screws: 1. MT1 base to MedCun 2. MT1 to MT2 base	Local cancellous	No	Bunionectomy	Technique attributed to ST Hansen Jr. 2nd screw removed at 13 weeks
A. Two 3.5-mm screws: 1. MedCun to MT1 base 2. MT1 to MT2 B. Modification with 4.0-mm screws	Medial eminence + local cancellous	±PRP	Bunionectomy, release of AHL, ± Akin procedure	
A. Two 3.5-mm screws: 1. MedCun to MT1 base 2. MT1 to MT2	Local cancellous	No	Soft-tissue release ±bunionectomy	Revision surgery for failed HV correction
2 crossed screws: 1. 4.0-mm MT1 to MedCun 2. 3.5-mm MedCun to MT1	Cancellous autograft ±	±DBM	Bunionectomy, ± Akin and/or modified McBride procedure	The authors have reported on the same study population and technique in 2 separate publications
A. 2 crossed TMT screws ± 3rd screw from MT1 to IntCun B. Dorsomedial locking plate ±crossed TMT screw	No	±DBM or BMA	Various, not standard	
Two 3.5-mm crossed screws: 1. MedCun to MT1 2. MT1 to MedCun	NR	No	Bunionectomy + AHL release	Number of feet reported, some of which are bilateral cases
2 crossed screws: 1. MedCun to MT1 2. MT1 to MedCun ± 3rd screw MT1 to MT2	Occasionally allograft/autograft	No	Bunionectomy, soft-tissue release	Revision surgery for failed HV correction
Two 3.5-mm crossed screws: 1. MedCun to MT1 2. MT1 to MedCun ± 3rd screw MT1 to MT2	NR	NR	Soft-tissue release	
Two 3.5-mm crossed screws: 1. MedCun to MT1 2. MT1 to MedCun	NR	NR	NR	Primary diagnosis: TMT OA; fixation technique derived from images/figures (not described in detail in the text)
Two 3.5-mm or 4.0-mm crossed screws: 1. MedCun to MT1 2. MT1 to MedCun	NR	NR	Soft-tissue release + Akin	
Single, headless, variable-pitch compression screw	NR	NR	No distal procedure	
Two 3.5-mm crossed screws: 1. MedCun to MT1 2. MT1 to MedCun ± supplementary temporary Kirschner wire	Local bone graft	NR	Soft-tissue release ±Akin	
Dorsomedial locking plate + 4.0-mm cannulated screw from base of MT1 to IntCun ± 4.0-mm cannulated screw from MT1 to MT2	NR	NR	Soft-tissue release ± bunionectomy ± Akin	
Two 3.5-mm screws: 1. MT1 to MedCun 2. MT1 to MT2	NR	NR	Akin	Method of fixation is derived from images/figures (not described in detail in the text)
NR	NR	NR	NR	
2 small-profile, 4-hole titanium locking plates applied in biplanar 90°-90° fashion	NR	NR	Soft-tissue release	
2 crossed 3.5-mm screws: 1. MedCun to MT1 2. MT1 to MedCun	NR	NR	1st MTP fusion	
2 crossed 3.5-mm screws: 1. MedCun to MT1 2. MT1 to IntCun or MT2	Tricortical bone graft from iliac crest ±	NR	NR	Authors state that their technique has changed during the study period
2 crossed 3.5-mm screws: 1. MT1 to MedCun 2. MedCun to MT1	Local bone graft	NR	Soft-tissue release ± Akin	Some of the procedures were part of a flatfoot reconstruction
Two 3.5-mm screws: 1. MT1 to MedCun 2. MedCun to MT1 or MT1 to MT2	Local bone graft	NR	Bunionectomy + AHL release	

- Tourniquet use: an Esmarch bandage from the toes to the lower quarter of the leg, where it is bandaged tightly and used as a tourniquet.
- Distal soft-tissue procedures: medial approach at the level of the first metatarsophalangeal (MTP) joint. Identification and separation of the muscle bellies and tendons of the abductor hallucis and flexor hallucis brevis plantarly. A U-shaped capsulotomy made with its base at the proximal phalanx. Subcutaneous tenotomy of the adductor hallucis and capsulotomy through a dorsal approach. Suturing of the U-shaped flap to the abductor hallucis longus with no. 0 chromic catgut with considerable tension, but not too tightly.
- Bunionectomy: With the use of small wood-carving chisels at the level of the medial sagittal groove. Aiming at the metatarsal neck, with an effort to preserve the round shape of the head, with or without a dorsal cheilectomy.
- TMT arthrodesis approach: Dorsal, between the extensor hallucis longus (EHL) medially and extensor hallucis brevis (EHB) laterally.
- Joint preparation: Shaving of the articular surfaces of the base of the first metatarsal (MT) and medial cuneiform without wedge resection. Removal of cortex of the base of the first and second MTs, leaving the bone chips in situ after denuding them from soft tissues and cartilage.
- Fixation: A bone tunnel is created at the dorsolateral part of the base of the first MT. A no. 0 chromic catgut is passed through it and sutured to the dorsal ligaments between the medial and intermediate cuneiforms.
- Postoperative immobilization: A 12-cm-long and 7-mm-wide steel corset is used at the medial aspect of the first metatarsal over well-padded dressing for 3 to 4 weeks. Weight-bearing as pain allows, with or without crutches. Special canvas shoes or wool socks are worn in the first month postoperatively.

An easily drawn conclusion is that nowadays practically no one performs the “original” Lapidus procedure. Moreover, a number of authors have probably misquoted the original technique because, with the exception of the 1960 review, the original papers are hard to purchase. Additionally, a number of studies have provided reports on patients who underwent “Lapidus arthrodesis” without clarifying details about the modifications that the authors used in their series. In fact, in many circles, the term “Lapidus procedure” has become synonymous with a number of first TMT arthrodesis constructs, when in fact the original description was in reference to a hallux valgus correction.

The implications of this vague terminology and its endless modifications are many. From a scientific point of view, this wide variety practically renders any effort to conduct a valid meta-analysis on the subject obsolete. Multicenter studies also need to be interpreted with some caution. In a well-quoted survey by

Pinney et al., 24% of 128 academic foot and ankle surgeons stated that they would perform a Lapidus arthrodesis for a hypothetical case of a patient with severe hallux valgus⁴. One can only wonder which of the numerous modifications of the Lapidus procedure each surgeon meant with his or her response.

Coding and billing for the procedure can be equally challenging. The range of operative costs, from 2 crossed 3.5-mm screws to dual-locking titanium plating plus an allograft or the use of orthobiologics, is staggering. Additionally, the term “Lapidoplasty,” which has recently been introduced, only seems to add to the confusion.

A better terminology is needed. The primary objective would be to improve the scientific quality of studies that report, combine, and compare groups of patients who undergo a first TMT arthrodesis procedure. Moreover, an improved terminology may aid in more precise coding and billing of the various modifications of the technique, which would benefit patients, health-care providers, and insurance companies. Finally, while eponyms are common in the orthopaedic lexicon, they can often lead to confusion and, therefore, an effort should be

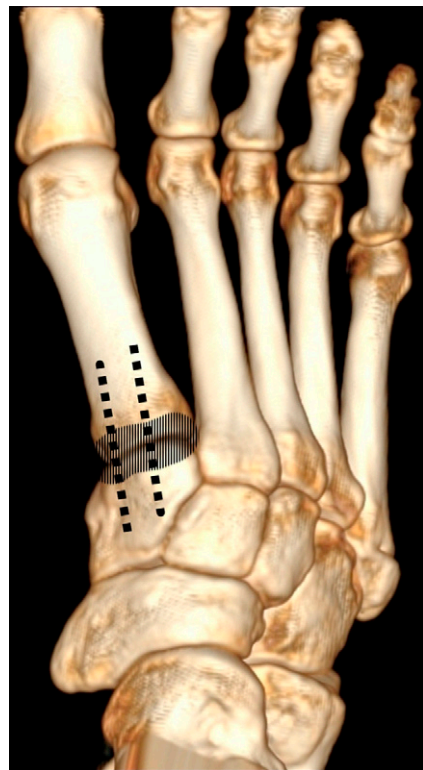


Fig. 1

Figs. 1 through 5 The new terminology for the arthrodesis of the first TMT joint. The solid parallel lines represent the joints that have been prepared for fusion; the dotted lines represent the usual direction that is used for fixation material. The dotted lines do not represent any suggestion on behalf of the authors with regard to the type, the volume, and the number of the fixation devices to be used (e.g., plates, screws, etc.). **Fig. 1** Single first TMT arthrodesis.

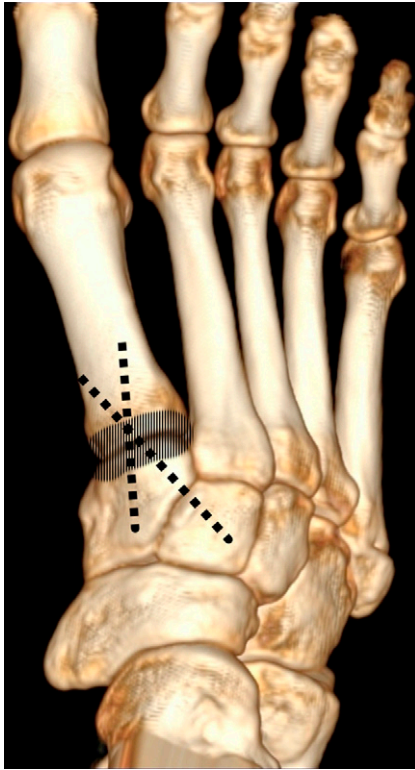


Fig. 2-A

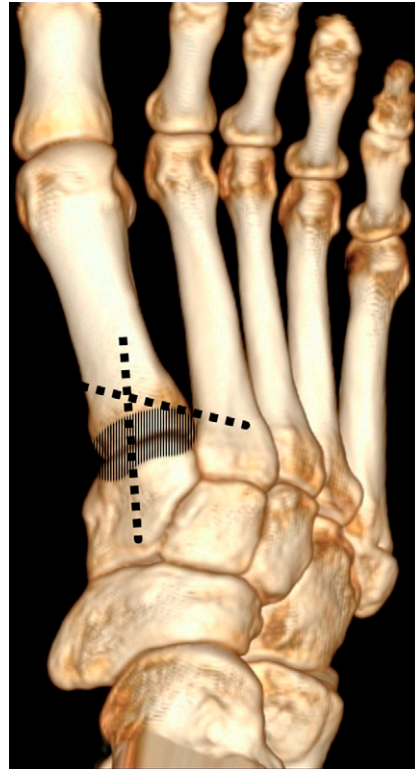


Fig. 2-B

Figs. 2-A and 2-B Arthrodesis. **Fig. 2-A** First TMT arthrodesis with additional fixation to the intermediate cuneiform. **Fig. 2-B** First TMT arthrodesis with additional fixation to the second MT.

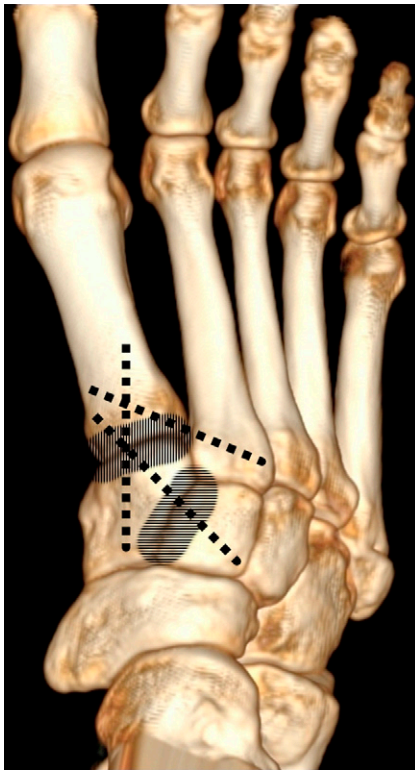


Fig. 3-A

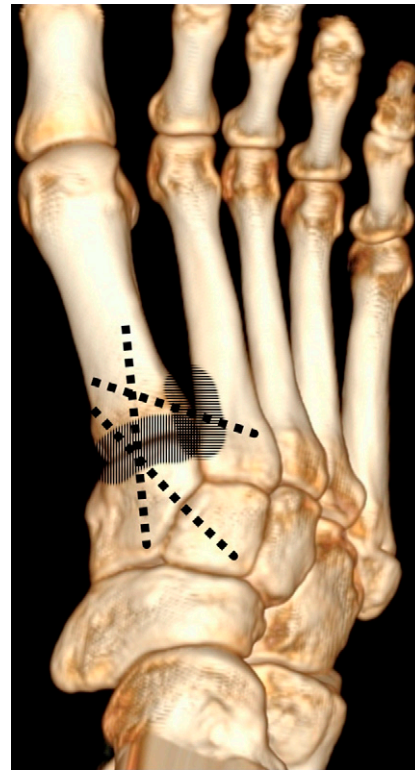


Fig. 3-B

Figs. 3-A and 3-B Arthrodesis. **Fig. 3-A** Three-corner TMT arthrodesis with inclusion of the intermediate cuneiform. **Fig. 3-B** Three-corner TMT arthrodesis with inclusion of the base of the second MT.

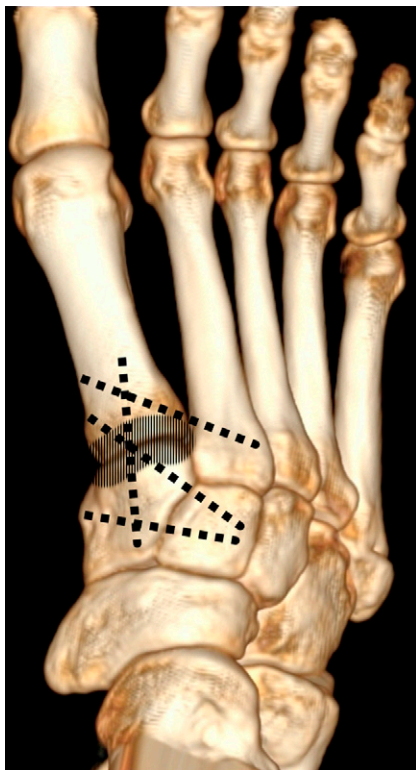


Fig. 4

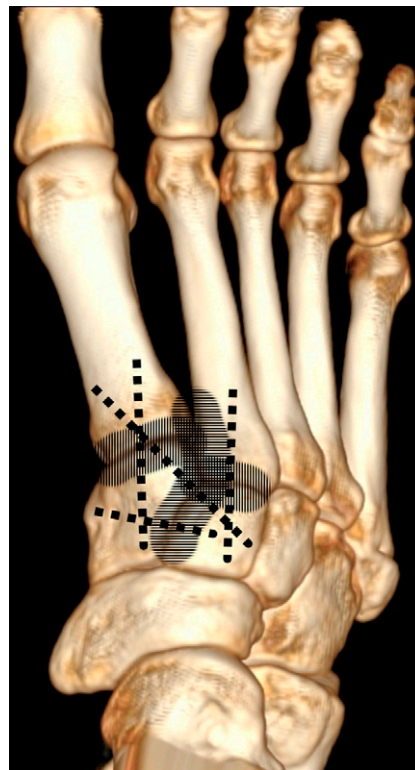


Fig. 5

Fig. 4 First TMT arthrodesis with 4-corner fixation to the intermediate cuneiform and the second MT. **Fig. 5** Four-corner TMT arthrodesis with inclusion of the first and second TMT joints and the intercuneiform joint.

considered to avoid fostering eponyms at the expense of anatomic clarity.

This initiative can only succeed with the support of a leading scientific journal that will follow through with use of the amended terminology in its future publications. Our proposal is to use 5 main descriptive terms when referring to the modifications of the Lapidus procedure, assuming that the procedures are part of hallux valgus correction. These same 5 descriptive terms should be applied when using any combination of first TMT arthrodesis as part of an arch reconstruction or flatfoot correction (Figs. 1 through 5):

1. First TMT arthrodesis: This would include all procedures where a single arthrodesis of the base of the first MT to the medial cuneiform is performed with any means of fixation, without including the intermediate cuneiform or the base of the second MT in the fixation (Fig. 1).
2. First TMT arthrodesis with 3-corner fixation: This term would refer to all procedures where an arthrodesis of the first TMT is combined with fixation of the intermediate cuneiform (Fig. 2-A) or the base of the second metatarsal (Fig. 2-B) without preparation of the joints for fusion.
3. Three-corner TMT arthrodesis: The same as number 2 above, but, in addition, either the intermediate cuneiform or the base of the second MT also is fused (Figs. 3-A and 3-B, respectively).

iform or the base of the second MT also is fused (Figs. 3-A and 3-B, respectively).

4. First TMT arthrodesis with 4-corner fixation: This would refer to all of the procedures that combine arthrodesis of the first TMT and fixation of the bases of the second MT and the intermediate cuneiform without preparation of the joints for fusion (Fig. 4).
5. Four-corner TMT arthrodesis: This would include all techniques where all of the joints between the base of the first and second MTs and the medial and intermediate cuneiforms are prepared for fusion (Fig. 5).

With regard to the concomitant distal soft-tissue release procedure, a number of authors in recent studies do not include it as part of the described procedure. Therefore, we propose the addition of a capital “S” following each number for the type of procedure in order to clarify that the procedure is the combination of the arthrodesis and the distal soft-tissue release.

In 2021, we will celebrate the ninetieth anniversary of the first truly original Lapidus operation that was performed on April 8, 1931. *The Journal of Bone & Joint Surgery*, as the official journal of the American Orthopaedic Association (AOA) and a leading journal in the field for research and teaching purposes, can be a pioneer in redefining the terminology around this

widely used technique and its modifications. We would ask readers of this Orthopaedic Forum article to express their views on the topic and the proposed new terminology of the various modifications of the Lapidus procedure. ■

Panagiotis D. Symeonidis, MD, PhD¹
John G. Anderson, MD^{2,3,4}

¹St Luke's Hospital, Thessaloniki, Greece

²Orthopaedic Associates of Michigan, PC, Grand Rapids, Michigan

³College of Human Medicine and College of Osteopathic Medicine, Michigan State University, East Lansing, Michigan

⁴Grand Rapids Orthopedic Foot and Ankle Fellowship Program, Grand Rapids, Michigan

Email address for P.D. Symeonidis: p.symeonidis@gmail.com

ORCID iD for P.D. Symeonidis: [0000-0002-5762-7627](https://orcid.org/0000-0002-5762-7627)

ORCID iD for J.G. Anderson: [0000-0001-7877-9972](https://orcid.org/0000-0001-7877-9972)

References

- Lapidus PW. The operative correction of the metatarsus varus primus in hallux valgus. *Surg Gynecol Obstet.* 1934;58:183-91.
- Albrecht GH. [The pathology and treatment of hallux valgus.] *Russ Vrach.* 1911; 10:14. Russian.
- Lapidus PW. The author's bunion operation from 1931 to 1959. *Clin Orthop.* 1960;16(12):119-35.
- Pinney SJ, Song KR, Chou LB. Surgical treatment of severe hallux valgus: the state of practice among academic foot and ankle surgeons. *Foot Ankle Int.* 2006 Dec;27(12):1024-9.
- Aiyer A, Shub J, Shariff R, Ying L, Myerson M. Radiographic recurrence of deformity after hallux valgus surgery in patients with metatarsus adductus. *Foot Ankle Int.* 2016 Feb;37(2):165-71. Epub 2015 Nov 13.
- Bednarz PA, Manoli A 2nd. Modified Lapidus procedure for the treatment of hypermobile hallux valgus. *Foot Ankle Int.* 2000 Oct;21(10):816-21.
- Coetzee JC, Wickum D. The Lapidus procedure: a prospective cohort outcome study. *Foot Ankle Int.* 2004 Aug;25(8):526-31.
- Coetzee JC, Resig SG, Kuskowski M, Saleh KJ. The Lapidus procedure as salvage after failed surgical treatment of hallux valgus. *Surgical technique. J Bone Joint Surg Am.* 2004 Mar;86(Suppl 1):30-6.
- Conti MS, MacMahon A, Ellis SJ, Cody EA. Effect of the modified Lapidus procedure for hallux valgus on foot width. *Foot Ankle Int.* 2020 Feb;41(2):154-9. Epub 2019 Oct 30.
- Conti MS, Willett JF, Garfinkel JH, Miller MC, Costigliola SV, Elliott AJ, Conti SF, Ellis SJ. Effect of the modified Lapidus procedure on pronation of the first ray in hallux valgus. *Foot Ankle Int.* 2020 Feb;41(2):125-32. Epub 2019 Oct 16.
- DeVries JG, Granata JD, Hyer CF. Fixation of first tarsometatarsal arthrodesis: a retrospective comparative cohort of two techniques. *Foot Ankle Int.* 2011 Feb;32(2):158-62.
- Faber FW, Mulder PG, Verhaar JA. Role of first ray hypermobility in the outcome of the Hohmann and the Lapidus procedure. A prospective, randomized trial involving one hundred and one feet. *J Bone Joint Surg Am.* 2004 Mar;86(3):486-95.
- Ellington JK, Myerson MS, Coetzee JC, Stone RM. The use of the Lapidus procedure for recurrent hallux valgus. *Foot Ankle Int.* 2011 Jul;32(7):674-80.
- Habbu R, Holthausen SM, Anderson JG, Bohay DR. Operative correction of arch collapse with forefoot deformity: a retrospective analysis of outcomes. *Foot Ankle Int.* 2011 Aug;32(8):764-73.
- Jung HG, Myerson MS, Schon LC. Spectrum of operative treatments and clinical outcomes for atraumatic osteoarthritis of the tarsometatarsal joints. *Foot Ankle Int.* 2007 Apr;28(4):482-9.
- Kazzaz S, Singh D. Postoperative cast necessity after a Lapidus arthrodesis. *Foot Ankle Int.* 2009 Aug;30(8):746-51.
- Klemola T, Leppilahti J, Laine V, Pentikäinen I, Ojala R, Ohtonen P, Savola O. Effect of first tarsometatarsal joint derotational arthrodesis on first ray dynamic stability compared to distal chevron osteotomy. *Foot Ankle Int.* 2017 Aug;38(8):847-54. Epub 2017 Jul 7.
- Kopp FJ, Patel MM, Levine DS, Deland JT. The modified Lapidus procedure for hallux valgus: a clinical and radiographic analysis. *Foot Ankle Int.* 2005 Nov;26(11):913-7.
- Langan TM, Greschner JM, Brandão RA, Goss DA Jr, Smith CN, Hyer CF. Maintenance of correction of the modified Lapidus procedure with a first metatarsal to intermediate cuneiform cross-screw technique. *Foot Ankle Int.* 2020 Apr;41(4):428-36. Epub 2019 Dec 26.
- Lee S, Manoli A 2nd. Where there's hope. *Foot Ankle Int.* 2001 Feb;22(2):161-3.
- MacMahon A, Karbassi J, Burket JC, Elliott AJ, Levine DS, Roberts MM, Deland JT, O'Malley MJ, Yu J, Mancuso CA, Ellis SJ. Return to sports and physical activities after the modified Lapidus procedure for hallux valgus in young patients. *Foot Ankle Int.* 2016 Apr;37(4):378-85. Epub 2015 Nov 17.
- Ray JJ, Koay J, Dayton PD, Hatch DJ, Smith B, Santrock RD. Multicenter early radiographic outcomes of triplanar tarsometatarsal arthrodesis with early weightbearing. *Foot Ankle Int.* 2019 Aug;40(8):955-60. Epub 2019 May 5.
- Rippstein PF, Park YU, Naal FD. Combination of first metatarsophalangeal joint arthrodesis and proximal correction for severe hallux valgus deformity. *Foot Ankle Int.* 2012 May;33(5):400-5.
- Sangeorzan BJ, Hansen ST Jr. Modified Lapidus procedure for hallux valgus. *Foot Ankle.* 1989 Jun;9(6):262-6.
- Thompson IM, Bohay DR, Anderson JG. Fusion rate of first tarsometatarsal arthrodesis in the modified Lapidus procedure and flatfoot reconstruction. *Foot Ankle Int.* 2005 Sep;26(9):698-703.
- Toolan BC. Surgical strategies: the Lapidus procedure. *Foot Ankle Int.* 2007 Oct;28(10):1108-14.