



Innovative use of a Montgomery cannula in the bronchoscopic management of tracheal stenosis and failed tracheostomy decannulation



Haidong Huang ^{a,1}, Changming Chen ^{a,1}, Harmeet Bedi ^{b,1}, Chong Bai ^{a,**}, Qiang Li ^c, Wolfgang Hohenforst-Schmidt ^d, Paul Zarogoulidis ^{e,*}

^a Department of Respiratory and Critical Care Medicine, Changhai Hospital, Second Military Medical University, Shanghai, China

^b Division of Pulmonary & Critical Care Medicine, Stanford University School of Medicine, Stanford, CA, USA

^c Department of Respiratory Medicine, Shanghai General Hospital, Shanghai Jiaotong University, Shanghai, China

^d Sana Clinic Group Franken, Department of Cardiology/Pulmonology/Intensive Care/Nephrology, "Hof" Clinics, University of Erlangen, Hof, Germany

^e Pulmonary Department, "G. Papanikolaou" General Hospital, Aristotle University of Thessaloniki, Thessaloniki, Greece

ARTICLE INFO

Article history:

Received 24 July 2017

Received in revised form

27 July 2017

Accepted 30 July 2017

Keywords:

Montgomery cannula

Silicone stent

Therapeutic bronchoscopy

Tracheal stenosis

Interventional pulmonology

Tracheotomy

Difficult decannulation

ABSTRACT

Background: Endoprosthesis are being used in the everyday clinical practice either as a permanent solution or transient. They can be used in both benign and malignant situations.

Case presentation: We report a case in which a temporary Montgomery cannula is used in conjunction with therapeutic bronchoscopy to manage a patient with failed tracheostomy decannulation secondary to a distal complex tracheal stenosis.

Conclusions: This innovative use of the Montgomery cannula allowed for successful management of the patient's tracheal stenosis and subsequent tracheostomy tube decannulation.

© 2017 The Authors. Published by Elsevier Ltd. This is an open access article under the CC BY-NC-ND license (<http://creativecommons.org/licenses/by-nc-nd/4.0/>).

1. Introduction

Tracheotomy plays an integral role in the long-term management and success of patients with cerebrovascular disease, traumatic brain injury (TBI), and neurologic sequelae of critical care illness. However, long-term tracheostomies are well known to be associated with varying degrees of tracheal stenosis and tracheomalacia [1]. Furthermore, patients suffering from TBI tend to have decreased cognitive ability, difficulty with expectoration, and increased retention of pulmonary secretions which poses challenges with recurrent pulmonary

infections and decannulation [2]. Herein, we describe a unique management strategy for a patient with failed tracheostomy decannulation secondary to complex tracheal stenosis with utilization of therapeutic bronchoscopy and Montgomery cannula placement, with subsequent successful decannulation.

2. Case presentation

A 56 year-old male with a history of intracranial aneurysm rupture, chronic respiratory failure, and mechanical ventilation dependency with tracheostomy presented to the emergency department (ED) from a skilled nursing facility with severe dyspnea, productive cough, and cyanosis of the lips. Patient's tracheostomy (cuffed, #8 tube) was placed 2 months earlier at the time of his aneurysm rupture. Prior to his presentation, despite recovering from his neurologic deficits, he could not tolerate mechanical ventilation weaning trials and suffered from recurrent pulmonary infections. Computed tomography (CT) of the chest on arrival to the ED demonstrated a tracheal stenosis at the distal end of the tracheostomy tube and bilateral lower lobe air space

* Corresponding author.

** Corresponding author. Department of Respiratory and Critical Care Medicine, Changhai Hospital, Second Military Medical University, No. 168, Changhai Road, Shanghai, 200433, China.

E-mail addresses: bc7878@sohu.com (C. Bai), pzarog@hotmail.com (P. Zarogoulidis).

¹ Haidong Huang, Changming Chen, Harmeet Bedi, equally contributed to this work.

opacities. The patient was emergently taken to the bronchoscopy unit for therapeutic bronchoscopy. Bronchoscopic examination revealed a severe complex tracheal stenosis just distal to the tracheostomy tube (Fig. 1A) with an approximate tracheal diameter of 5 millimeters (mm). Given patient's instability, decision was made to emergently relieve his stenosis. The stenosis was incised at the 3, 6, and 9 o'clock positions with a high frequency electrocautery knife. This was immediately followed by sequential balloon dilation to 12 mm. After dilation, the stenosis was further explored and found to be 25 mm in length, with an abundance of retained purulent secretions distally. A new #8 cuffed, extended tracheostomy tube was chosen and exchanged to allow for bypassing and "stenting" of the stenosis (Fig. 1B). The patient subsequently improved and was discharged. One month later, the patient's tracheostomy tube was decannulated and bronchoscopic examination revealed that the previous tracheal stenosis appeared patent. Decision was made to maintain patient's tracheal stoma with the placement of a temporary Montgomery cannula (Fig. 1C) to allow for tracheal suctioning and for possible reinsertion of tracheostomy tube, given patient's complex tracheal issue. The external aperture of the Montgomery cannula was capped with the included button (Fig. 1D). One week later, the patient returned with dyspnea and productive cough. Patient's Montgomery cannula was uncapped and pulmonary secretions cleared with suction catheter. Because of concern for recurrent stenosis, patient was taken again for therapeutic bronchoscopy. Rigid bronchoscopy was performed and demonstrated recurrence of tracheal stenosis at the original site (previously treated). Decision was made to repeat balloon dilation and proceed with tracheal stenting. A silicone stent (Novatech, hourglass shape) was chosen and successfully deployed (Fig. 1E). The patient's symptoms completely resolved, and he was subsequently discharged home. Two weeks later, the patient remained asymptomatic and his Montgomery

cannula was removed. His stoma healed without any complications. Follow-up bronchoscopies continued to show excellent stent position and patent trachea over the next 24 months (Fig. 1F).

3. Discussion

Approximately 20% of ICU patients requiring mechanical ventilation require a tracheostomy [3]. While tracheostomies play a valuable role in maintenance of respiratory function and protection of the airway, its long term use is well associated with many complications such as tracheal granulomas, tracheal stenosis, tracheomalacia, and tracheoesophageal fistulas [4]. While successful tracheostomy decannulation is routinely sought after, up to 5% of patients experience difficulty with decannulation. The most important factors leading to difficult decannulation are uncontrolled pulmonary infections, retained pulmonary secretions, and severe tracheal stenosis [5]. Particularly, tracheal stenosis poses difficult challenges in decannulation and management of such patients. Ideally this population would be treated with tracheal resection, however these patients tend to have many comorbidities and are deemed non-surgical candidates for tracheal resection. Furthermore, these stenosis tend to be distal to the tracheostomy tube which are in the mid and distal tracheas, which are not always technically amenable to surgical resection as well as Montgomery T tube placement. Alternatively, patients are treated with a tracheostomy tube exchange to an extended tube to allow for bypassing the stenosis. This does eliminate the harmful effects of the stenosis, however it usually results in prolonged or lifelong tracheostomy requirement. Drug eluting stents might provide a solution in the future in order to avoid fibrinous tissue formation around both ends of the stent [6,7]. Fibrinous tissue formation can be observed

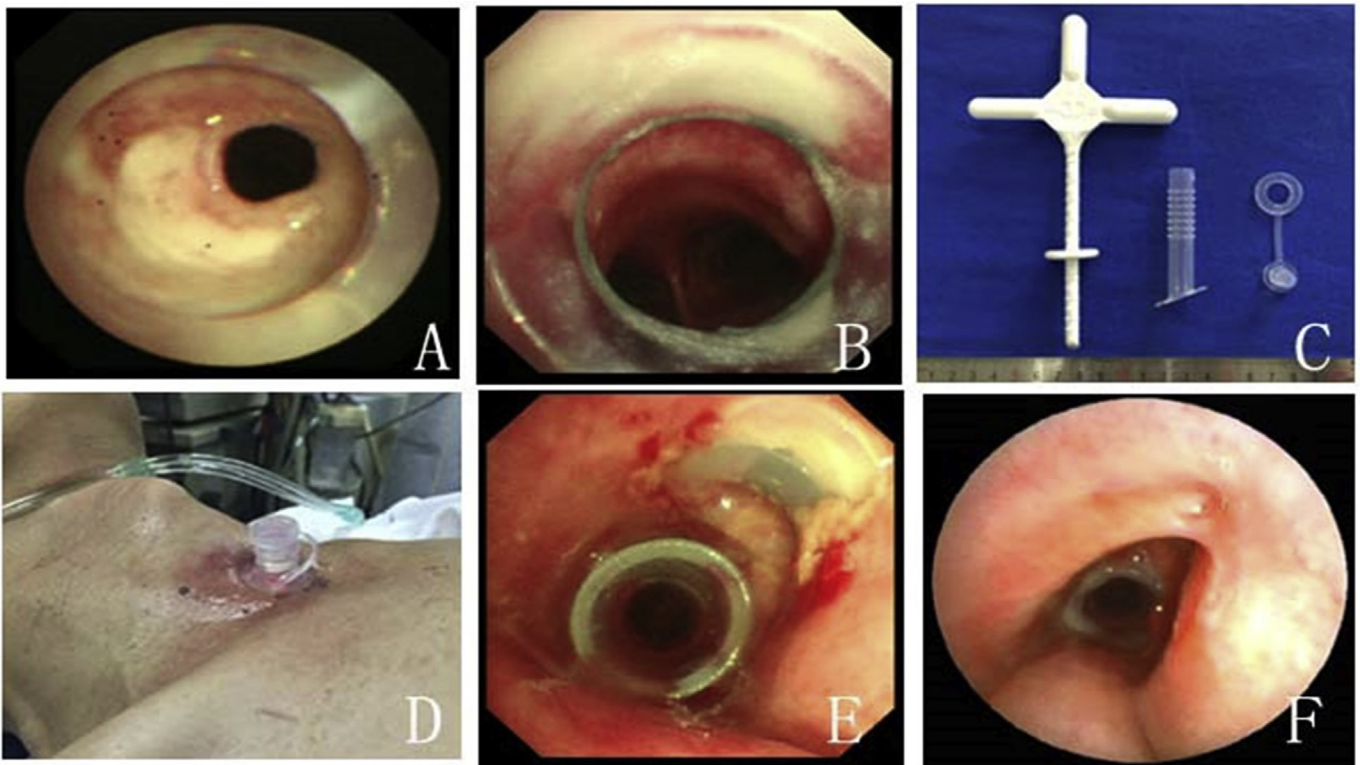


Fig. 1. A: Complex tracheal stenosis seen distal to tracheostomy tube at time of patient presentation. B: Status post therapeutic bronchoscopy and placement of extended tracheostomy tube with relief of tracheal stenosis. C: Temporary Montgomery cannula with deploying device. D: External appearance of the Montgomery cannula exiting patient's tracheal stoma. E: Montgomery cannula seen in stoma just proximal to tracheal silicone stent. F: Status post Montgomery cannula removal with stable position of tracheal silicone stent.

in both silicon based and metallic self-expandable stents. In the future a combination of drug eluting stents might help to avoid this or even treat other medical situations [6,7].

In our patient's case, we successfully achieved tracheostomy decannulation through an innovative combined approach with therapeutic bronchoscopy and the placement of a short-term Montgomery cannula. Therapeutic bronchoscopic treatment of benign complex tracheal stenosis related to intubation and tracheostomies is a well-known entity in the realm of interventional pulmonology [8–10]. However, the use of Montgomery cannulas in conjunction with therapeutic bronchoscopy for the purpose of decannulation is unreported to our knowledge. Montgomery cannulas are available in two varieties: short-term and long-term. The difference between the two types is that the long-term cannulas are designed to promote epithelialization of the tracheal stoma. Montgomery cannulas were introduced in 1978 and were initially indicated for obstructive sleep apnea, bilateral vocal cord paralysis, laryngeal carcinoma with glottis insufficiency, and chronic lung disease with need for frequent suctioning. While these cannulas have been available for decades, they're used much less frequently than tracheostomy tubes. Montgomery cannulas have many benefits over tracheostomy tubes such as they allow for maintained patency of the tracheal stoma without the need to occupy the tracheal lumen, are easier to maintain, and have a more concealable design [11]. And similar to tracheostomy tubes, they allow for tracheal suctioning of pulmonary secretions. These cannulas can also be exchanged for a tracheostomy tubes in case of ventilatory emergencies. Usually stents are inserted through a rigid bronchoscope with the jet-ventilation respiratory model. However; the method of insertion might vary based on the stent and medical situation that the medic has to treat [6].

Prior to presenting to our institution, the patient in this case was unable to successfully wean off of mechanical ventilation as a result of tracheal stenosis (secondary to tracheostomy) and retained pulmonary secretions. With utilization of electrocautery knife incisions, balloon bronchoplasty, and placement of an extended tracheostomy tube, we were able to manage patient's stenosis. However, after planned removal of his tracheostomy tube, he did re-develop the tracheal stenosis. In this situation, in our experience, many institutions would reinsert an extended tracheostomy tube as definitive management. While this may offer an immediate relief, it does commit the patient to many long-term disadvantages such as indefinite trach care, local discomfort, aesthetic concerns, and a nidus for additional long-term tracheostomy complications. Moreover, in our experience, these patients tend to be labelled as too "high-risk" for subsequent decannulation trials, and as a consequence, are never decannulated again [6,11–13]. With our approach, the Montgomery cannula was able to act as a bridge for the patient during the management of his tracheal stenosis. The cannula provided us all the advantages of a tracheostomy tube without any of its disadvantages. As a result, his tracheal stenosis was managed in accordance with traditional interventional pulmonary practices, and he was able to achieve successful decannulation of his tracheostomy tube and subsequently his Montgomery cannula.

While further trials are needed to evaluate the use of Montgomery cannulas and its role in patients with tracheostomies and

tracheal stenosis, it appears that it may have a useful role in a select patient population. Additionally, it may have a useful role in bridging patients from tracheostomy tube removal to successful decannulation in patients deemed to be marginal candidates for decannulation.

Conflict of interest

None to declare.

Acknowledgements

This study was supported by Project of Shanghai Municipal Health Bureau (Grant number: 20124166), Project of Wujiaping Medical Foundation (Grant number: 320.6750.11112), Project of New Clinical Technology Development of Changhai Hospital (Grant number: NT201506).

References

- [1] P.H. Bagley, M. O'Shea, Increased frequency of obstructive airway abnormalities with long-term tracheostomy, *Chest* 104 (1) (1993) 136–138.
- [2] I.D.L. Zanata, R.S. Santos, G.C. Hirata, Tracheal decannulation protocol in patients affected by traumatic brain injury, *Int. Arch. Otorhinolaryngol.* 18 (02) (2014) 108–114.
- [3] A. Esteban, A. Anzueto, I. Alía, F. Gordo, C. Apezteguía, F. Páizas, D. Cide, R. Goldwasser, L. Soto, G. Bugedo, How is mechanical ventilation employed in the intensive care unit? An international utilization review, *Am. J. Respir. Crit. Care Med.* 161 (5) (2000) 1450–1458.
- [4] S.K. Epstein, Late complications of tracheostomy, *Respir. Care* 50 (4) (2005) 542–549.
- [5] H.H. O'Connor, A.C. White, Tracheostomy decannulation, *Respir. Care* 55 (8) (2010) 1076–1081.
- [6] W. Hohenforst-Schmidt, P. Zarogoulidis, G. Pitsiou, B. Linsmeier, D. Tsavlis, I. Kioumis, E. Papadaki, L. Freitag, T. Tsiouda, J.F. Turner, R. Browning, M. Simoff, N. Sachpekidis, K. Tsakiridis, B. Zaric, L. Yarmus, S. Baka, G. Stratakos, H. Rittger, Drug eluting stents for malignant airway obstruction: a critical review of the literature, *J. Cancer* 7 (4) (2016) 377–390.
- [7] R.F. Walter, P. Zarogoulidis, F.D. Mairinger, R. Werner, K. Darwiche, K. Zarogoulidis, L. Freitag, Cell viability of fibroblasts to pifenidone and sirolimus: a future concept for drug eluting stents, *Int. J. Pharm.* 466 (1–2) (2014) 38–43.
- [8] V. Abdullah, A.P. Yim, P.J. Wormald, C.A. van Hasselt, Dumon silicone stents in obstructive tracheobronchial lesions: the Hong Kong experience, *Otolaryngol. Head Neck Surg.* 118 (2) (1998) 256–260.
- [9] J.I. Martinez-Ballarín, J.P. Diaz-Jimenez, M.J. Castro, J.A. Moya, Silicone stents in the management of benign tracheobronchial stenoses. Tolerance and early results in 63 patients, *CHEST J.* 109 (3) (1996) 626–629.
- [10] G. Galluccio, G. Lucantoni, P. Battistoni, G. Paone, S. Batzella, V. Lucifora, R. Dello Iacono, Interventional endoscopy in the management of benign tracheal stenoses: definitive treatment at long-term follow-up, *Eur. J. Cardiothorac. Surg.* 35 (3) (2009) 429–433 discussion 933–934.
- [11] W. Hohenforst-Schmidt, B. Linsmeier, P. Zarogoulidis, L. Freitag, K. Darwiche, R. Browning, J.F. Turner, H. Huang, Q. Li, T. Vogl, K. Zarogoulidis, J. Brachmann, H. Rittger, Transtracheal single-point stent fixation in posttracheotomy tracheomalacia under cone-beam computer tomography guidance by transmural suturing with the Berci needle - a perspective on a new tool to avoid stent migration of Dumon stents, *Ther. Clin. Risk Manag.* 11 (2015) 837–850.
- [12] I. Karapantzos, P. Zarogoulidis, M. Karanikas, V. Thomaidis, C. Charalampidis, C. Karapantzou, Obstruction of the right stem bronchus due to ovarian local metastasis: a 5-year follow-up, *Ann. Transl. Med.* 4 (22) (2016) 445.
- [13] G. Stratakos, V. Gerovasili, C. Dimitropoulos, I. Giozos, F.T. Filippidis, S. Gennimata, P. Zarogoulidis, A. Zissimopoulos, A. Pataka, N. Koufos, S. Zakyntinos, K. Syrigos, N. Koulouris, Survival and quality of life benefit after endoscopic management of malignant central airway obstruction, *J. Cancer* 7 (7) (2016) 794–802.