

Heterotopic Ossification in Primary Total Hip Arthroplasty: which is the role of drainage?

Paolo Di Benedetto, Andrea Zangari, Stefano Magnanelli, Vanni Cainero, Alessandro Beltrame, Renato Gisonni, Araldo Causero

Department of Orthopaedic Surgery, University Hospital of Udine, Udine, Italy

Summary. *Background and aim of the work:* The Heterotopic Ossification (HO) is a common complication following Total Hip Arthroplasty (THA). Although there is no concordance in Literature regarding the etiopathogenic mechanism, various HO risk factors have been recognized, both related to the patient and associated with the surgical procedure. Literature does not consider the use of intra-articular drainage as a possible risk factor. Our hypothesis is that this item can contribute to the development of HO. *Materials and Methods:* 425 implants of hip arthroplasty performed between 2014 and 2017 at the Ortopedic Clinic of Udine were included in the study. No patient performed pre-operative or post-operative anti-HO prophylaxis during follow-up. Radiographs of preoperative and postoperative at 1 year were analyzed according to the Brooker Classification. *Results:* The incidence of HO in patients with intra-articular drainage is 24.6%, while the incidence of HO in patients without intra-articular drainage is 15.3%, with a statistically significant difference. *Conclusions:* The data obtained suggest to consider the use of intra-articular drainage as a possible intra-operative risk factor for HO. This is a retrospective cohort study, so we need more studies and more robust experimental designs to confirm these results. (www.actabiomedica.it)

Key words: Heterotopic Ossification, Total Hip Arthroplasty, drainage

Introduction

The Heterotopic Ossification (HO) is defined as the formation of mature and lamellar bone infiltrated at the soft tissue level, then out of the physiological skeletal structure (1, 2). These HO represent a common complication for orthopedic and traumatological surgery, but in particular it is frequently associated with hip prosthetics. The most probable incidence of HO varies from 28% to 61% (3-10). Generally HO is asymptomatic. In a small percentage of cases local pain and limitation of joint excursion may occur (11, 12). The most used classification to describe is the Classification of Brooker (13). The etiology and pathogenesis of HO have not yet been established with certainty. Literature recognizes risk factors related to the patient (male, age, obesity, arthrosis, etc.) and to the surgical

procedure (surgical access, type of anesthesia, intraoperative blood loss, duration of the procedure, etc.). In any case, it has not yet been established with precision if and which risk factors may have a greater influence on the location and quantity of HO (14,15). The use of intra-articular drainage is an element not considered in literature as a risk factor. Our study consider the presence or absence of drainage in a heterogeneous group of hip arthroplasty implants, to detect any difference in the incidence of HO.

Materials and Methods

The present study regards all the arthroplasty hip implants performed at the Ortopedic Clinic of Udine from 1st of January 2014 to 31th of December 2017.

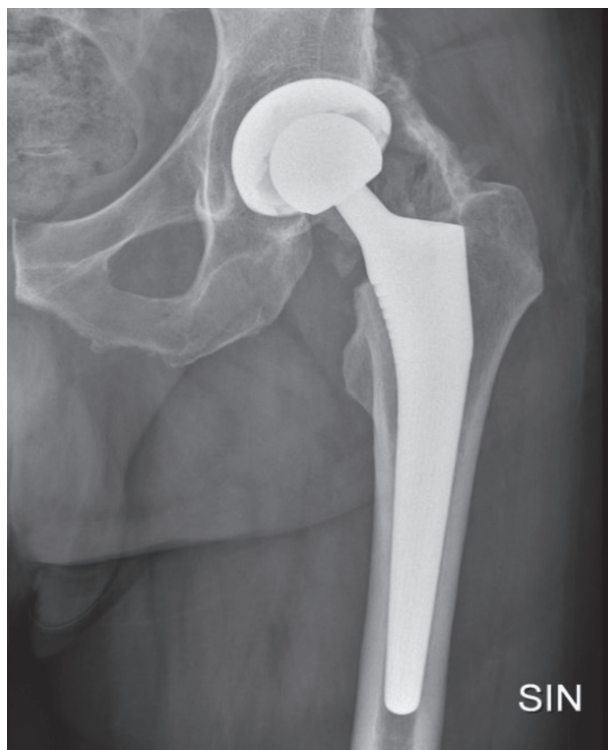

Figure 1. One year post-operative xray showing HO Class IV Brooker's

Surgical operations were performed by five surgeons of the Orthopedic Clinic, all with high rate of experience for this type of surgery. Patients diagnosed with infection, patients who performed prophylactic therapy for HO and patients undergoing prolonged immobilization, were excluded from the study. The proposed diagnoses included primary coxarthrosis, aseptic necrosis of the femoral head, outcomes of congenital hip dysplasia, outcomes of trauma and fracture of the coxo-femoral joint. All THA were followed up to 1 year post-intervention with a frequency of 45 days, 3 months, 6 months and a year. At each clinical control, in addition to the clinical examination, an X-ray of the pelvis in AP and 2 projection (AP and LL) of the operated hip were examined and archived. With a follow-up of at least one year it was therefore possible to recognize the presence and evolution of any HO. The HO were classified according to the Brooker Classification.

For each patient were considered age, gender, admission diagnosis, the surgical procedure performed, the type of implant used and the presence or absence

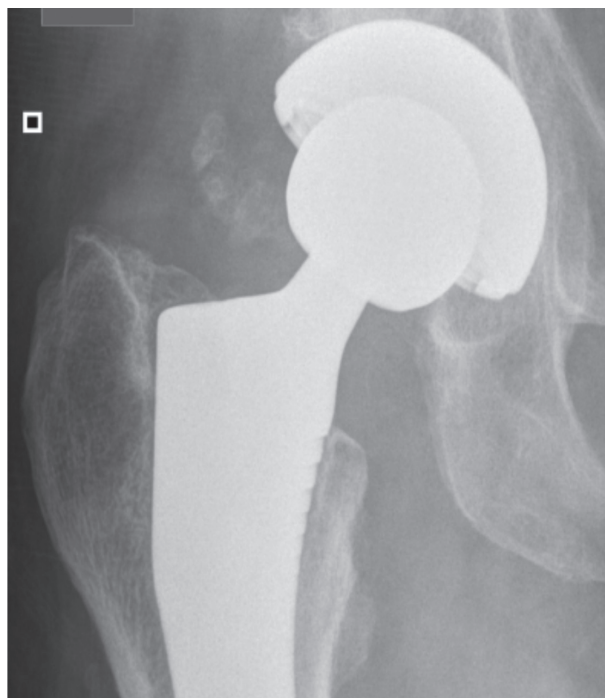


Figure 2. One year post-operative xray showing HO Class I Brooker's

of intra-articular drainage (drainage is always removed in the first day post-operative). The probable higher incidence of HO in patients with drainage was then calculated.

Results

The total number of THA performed is 425. Of these 408 by Direct Anterior Approach (DAA) and the remaining 17 by Direct Lateral or Anterior-Lateral Approach. Of the total 425 hip arthroplasty at 1 year, 90 patients had radiological evidence of HO (21.2%) (Table 1).

In details, following the Classification of Brooker, 33 Class I, 32 Class II, 19 Class III, 6 Class IV. Of the 90 patients in the group with HO, 62 were male (68.9%) (Table 2).

On the 425 implanted hip arthroplasty 265 had intra-articular drainage (62.3%). Of the 90 patients in the group with HO, 66 also had intra-articular drainage (73.3%). The percentage of patients with ossification and drainage is 24.6%. The percentage of patients

with ossifications but without drainage is 15.3% (Table 3). The difference of HO incidence in the two patience groups is statistically significant (p-value 0,0229).

For only 3 patients (all Class IV) a new surgical approach was needed to remove periarticular HO with good benefits.

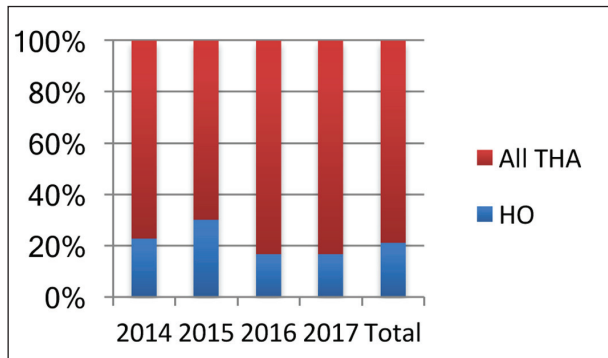


Table 1. HO rate in our study

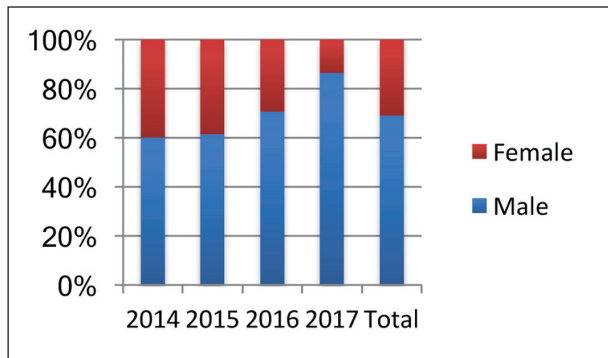


Table 2. Distribution of HO according to gender

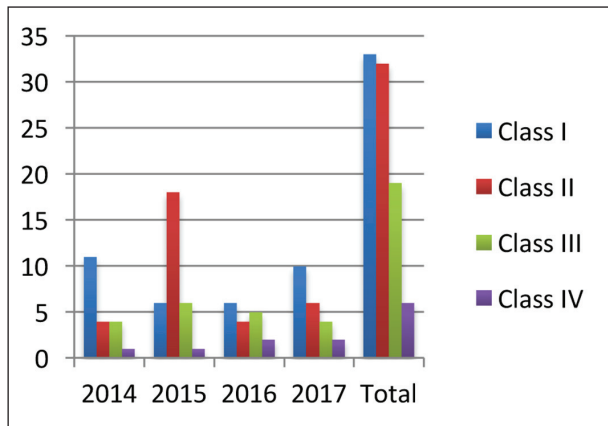


Table 3. HO according to the Brooker Classification

Discussions

Among the orthopedic surgical procedures, the hip arthroplasty is the most affected by the onset of HO. The knee is affected less by this complication. The incidence of HO post-THA varies from 28% to 61% (3-10). According to some Authors the spectrum is between 5% and 90% (16). The result is probably so uncertain and not precise because the HO is often random, and in most cases have no clinical relevance. Only in a small percentage of patients ranging from 3% to 10% a symptomatology can be manifested, which may be local erythema and swelling, pain and limitation of the ROM (17,18). The most famous and most used classification is the Brooker one; through the study of a simple radiography of the antero-posterior pelvis, four classes can be differentiated: Class I (HO islands within periprosthetic soft tissues), Class II (bone proliferations from the apex of the great trochanter or from the acetabulum with space greater than 1 cm between the two extremities), Class III (bone proliferation from the apex of the great trochanter or from the acetabulum with space less than 1 cm between the two extremities), Class IV (apparent hip bone anchor) (13).

Generally HO starts to manifest in the first 6 weeks and is mature and recognizable no later than 6 months post-intervention (11,13). Several studies have recognized the benefits of treatment with NSAIDs, Indomethacin and radiation therapy against the development of HO. These therapies can perform a beneficial action both as preoperative prophylaxis and as postoperative therapy (19-21). The etiology of this calcific phenomenon is unknown. Genetic exposure has not yet been established (22). The first description of HO dates back to 1692 performed by Patin in a child

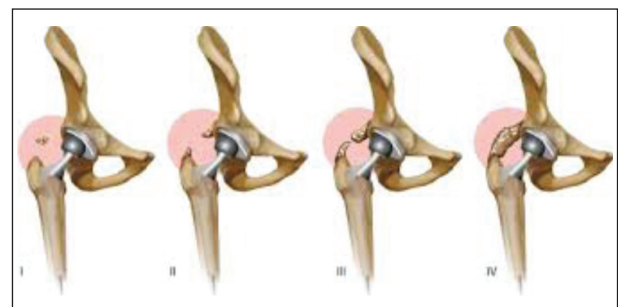


Figure 3. Brooker Stages

affected by myositis ossificans progressiva (23). Since then, several authors have proposed specific pathogenic mechanisms, but there is still no agreement. During the Great War the HO was manifested more in paraplegic soldiers with injuries to the vertebral column from explosion. This phenomenon suggests that the probable responsible for the development of HO are soft tissues, bone tissue and the nervous system. Literature therefore considers these structures to be probable guilts of HO (24-26). As for the ossifications in general, even the HO post-THA was not a shared etiology. The most accredited etiopathogenetic mechanism provides that it is the result of the release of some osteogenic factors released following the injury of the soft tissues located around the coxo-femoral articulation (27). The specific and agreed risk factors for HO are male sex, hypertrophic arthrosis, obesity, ankylosing spondylitis, rheumatoid arthritis, post-traumatic arthritis, Paget's disease and idiopathic skeletal hyperostosis. . Other risk factors, although not yet agreed in Literature, may be related to surgery, such as the type of anesthesia, the duration of the operation, the possible blood transfusion, and especially the surgical approach performed (28, 29). Several authors have tried to deepen this aspect, unfortunately with poor results. The theory according to which a lower trauma of the soft tissues decrease the HO has positively influenced the choice of the Anterior surgical approach. The Direct Anterior Approach is finding more and more space in recent years. It is also our path of choice, because it is an intermuscular and internervous pathway that has shown a lower traumatism of the peri-articular tissues, an early mobilization of the patient, an adequate ROM in shorter times and a lower index of dislocation (30-34). In any case, the Literature has not yet agreed on establishing the influence of the access pathway on the incidence of HO (36). Probably it is necessary to elaborate on and research other risk factors.

An element not so considered in Literature is the use of drainage. The level of dissection and trauma of the soft tissue during surgery can affect the incidence of HO. Elements such as bone debris, the fixation technique of prosthetic components and the development of a hematoma under the fascia, have been taken into account as further factors affecting the HO (28, 29). The most accredited etiopathogenetic mechanism pre-

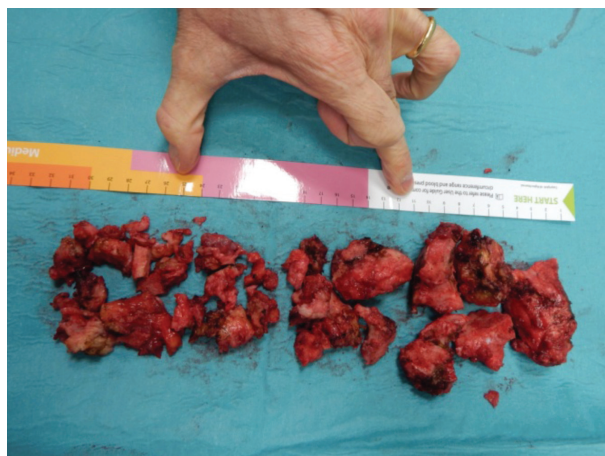


Figure 4. HO removed after surgery

dicts that these factors favor release of bone-inductive factors. Furthermore, the trauma of the surrounding soft tissues creates an environment favorable to the local proliferation of fibroblasts and the accumulation of extracellular matrix, which will evolve in HO through endochondral ossification (37-40). It has not yet been established whether the osteogenic mediators are released from stimulated bone tissue or soft tissue directly (41). Giving credit to this pathogenetic mechanism, the use of drainage is an important factor to consider. Peri-articular drainage performs the draining action preventing the accumulation of local serum-hematic fluid. In relation to the genesis of HO, the positioning of the drainage determines an additional source of trauma to the soft tissues. The presence of drainage also allows an additional way of spreading osteogenic mediators through soft tissues. Furthermore, the presence of a foreign body such as drainage can favor a locally recall of inflammatory factors that can stimulate the start of the forming process of HO.

Conclusions

According to the data obtained, the presence of drainage could favor the development of HO. Our study has several limitations, including the fact of being a retrospective study, the number of patients, not having considered further variables and risk factors in the selection and classification of patients. Nevertheless, the data obtained are statistically significant, so it

could be a first step to deepen the subject. In any case further studies and analyzes are necessary with more data to obtain an adequate result.

References

1. Thomas BJ. Heterotopic bone formation after total hip arthroplasty. *Orthop Clin North Am* 1992;23(2):347.
2. Pakos EE, Pitouli EJ, Tsekeris PG, et al. Prevention of heterotopic ossification in high-risk patients with total hip arthroplasty: the experience of a combined therapeutic protocol. *Int Orthop* 2006;30(2):79
3. Bal BS, Lowe JA, Gietler AE, et al. Heterotopic ossification after 2-incision total hip arthroplasty. *J Arthroplasty* 2010;25(4):538.
4. Goel A, Sharp DJ. Heterotopic bone formation after hip replacement: the influence of the type of arthritis. *J Bone Joint Surg (Br)* 1991;73-B(2):255.
5. Higo T, Mawatari M, Shigematsu M, et al. The incidence of heterotopic ossification after cementless total hip arthroplasty. *J Arthroplasty* 2006;21(6):852.
6. Pai VS. Heterotopic ossification in total hip arthroplasty: the influence of approach. *J Arthroplasty* 1994;9:199.
7. Sneath RJ, Bindi FD, Davies J, et al. The effect of pulsed irrigation on the incidence of heterotopic ossification after total hip arthroplasty. *J Arthroplasty* 2001;16 (5):547.
8. Spinarelli A, Patella V, Petnera M, et al. Heterotopic ossification after total hip arthroplasty: our experience. *Musculoskelet Surg* 2011;95:1.
9. Toom A, Haviko T, Rips L. Heterotopic ossification after total hip arthroplasty. *Int Orthop* 2001;24:323.
10. Vastel L, Kerboul L, Anract P, et al. Heterotopic ossification after total hip arthroplasty: risk factors and prevention. *Rev Rhum Engl Ed* 1998;65(4):238.
11. Ritter MA, Vaughan RB. Ectopic ossification after total hip arthroplasty. *J Bone Joint Surg* 1977;59-A(3):345.
12. Kocic M, Lazovic M, Mitkovic M, et al. Clinical significance of heterotopic ossification after total hip arthroplasty. *Orthopedics* 2010;33(1):16.
13. Brooker AF, Bowerman JW, Robinson RA, et al. Ectopic ossification following total hip replacement. *J Bone Joint Surg Am* 1973;55-A:1629.
14. Iorio R, Healy WL. Heterotopic ossification after hip and knee arthroplasty: risk factors, prevention, and treatment. *J Am Acad Orthop Surg* 2002;10(6):409.
15. Eggli S, Woo A. Risk factors for heterotopic ossification in total hip arthroplasty. *Arch Orthop Trauma Surg* 2001;121(9):531.
16. D. L. Back, J. D. Smith, R. E. Dalziel, D. A. Young, and A. Shimmin, "Incidence of heterotopic ossification after hip resurfacing," *ANZ Journal of Surgery*, vol. 77, no. 8, pp. 642–647, 2007.
17. Hierton C, Blomgren G, Lindgren U. Factors associated with heterotopic bone formation in cemented total hip prostheses. *Acta Orthop Scand* 1983;54(5):698.
18. DeLee J, Ferrari A, Charnley J. Ectopic bone formation following low friction arthroplasty of the hip. *Clin Orthop Relat Res* 1976;(121):53.
19. M. Fransen and B. Neal, "Non-steroidal anti-inflammatory drugs for preventing heterotopic bone formation after hip arthroplasty," *Cochrane Database of Systematic Reviews*, no. 3, Article ID CD001160, 2004.
20. M. A. Ritter and T. J. Gioe, "Theeffect of indomethacin on paraarticular ectopic ossification following total hip arthroplasty," *Clinical Orthopaedics and Related Research*, vol. 167, pp. 113–117, 1982.
21. J. S. McMahan, J. P. Waddell, and J. Morton, "Effect of shortcourse indomethacin on heterotopic bone formation after uncemented total hip arthroplasty," *Journal of Arthroplasty*, vol. 6, no. 3, pp. 259–264, 1991.
22. Vande et al, Heterotopic ossification: a review. *J. rehabil. Med.* 37,129-136 (2005)
23. Geschickter CF, Maseritz I. Myositis ossificans. *J Bone Joint Surg Am* 1938; 20: 661–674.
24. Riedel B. Demonstration line durch ach Hagiges Umhergehen total destruirten knieelenkes von einem patienten mit stichverletzung des ruckans. *Verh Dtsch Gesellschaft Chirurg* 1883; 12: 93.
25. Dejerine A, Ceillier A. Para-osteo-arthropathies des paraplegiques par lesion medullarie; etude clinique et radiographique. *Ann Med* 1918; 5: 497.
26. Damanski M. Heterotopic ossification in paraplegia, a clinical study. *J Bone Joint Surg Am* 1961; 43: 286.
27. Alijanipour P et al., Heterotopic ossification in primary total hip arthroplasty using the direct anterior vs direct anterior lateral approach. *Journal of Arthroplasty*, vol 32, no. 4, pp 1323-1327, 2017
28. Board TN, Karva A, Board RE, et al. The prophylaxis and treatment of heterotopic ossification following lower limb arthroplasty. *J Bone Joint Surg Br* 2007;89(4):434.
29. Cohn RM, Schwarzkopf R, Jaffe F. Heterotopic ossification after total hip arthroplasty. *Am J Orthop (Belle Mead NJ)* 2011;40(11):E232.
30. Matta JM, Shahrdar C, Ferguson T. Single-incision anterior approach for total hip arthroplasty on an orthopaedic table. *Clin Orthop Relat Res* 2005;441:115.
31. Rachbauer F, Kain MS, Leunig M. The history of the anterior approach to the hip. *Orthop Clin N Am* 2009; 40: 311.
32. Bergin PF, Doppelt JD, Kephart CJ, et al. Comparison of minimally invasive direct anterior versus posterior total hip arthroplasty based on inflammation and muscle damage markers. *J Bone Joint Surg Am* 2011:1392.
33. Lugade V, Wu A, Jewett B, et al. Gait asymmetry following an anterior and anterolateral approach to total hip arthroplasty. *Clin Biomech* 2010;25:625.
34. Vail TP, Mariani EM, Boune MH, et al. Approaches in total hip arthroplasty. *J Bone Joint Surg Am* 2009;91:10.
35. Pogliacomì F, Paraskevopoulos A, Costantino C, Marengni P, Ceccarelli F. Influence of surgical experience in the learning curve of a new approach in hip replacement: anterior

- mini-invasive vs standard lateral. *Hip International* 2012; 22(5): 555-61
36. Tippets D et al, Incidence of heterotopic ossification in direct anterior total hip arthroplasty: a retrospective radiographic review. *Journal of Arthroplasty*, vol 29, pp 1835-1838, 2014
37. Baird EO, Kang QK. Prophylaxis of heterotopic ossification - an updated review. *J Orthop Surg* 2009;4:12.
38. Wilkinson JM, Stockley I, Hamer AJ, et al. Biochemical markers of bone turnover and development of heterotopic ossification after total hip arthroplasty. *J Orthop Res* 2003;21(3):529.
39. Nauth A, Giles E, Potter BK, et al. Heterotopic ossification in orthopaedic trauma. *J Orthop Trauma* 2012;26(12):684.
40. Pape HC, Marsh S, Morley JR, et al. Current concepts in the development of heterotopic ossification. *J Bone Joint Surg Br* 2004;86(6):783.
41. Nilsson OS, Persson P. Heterotopic bone formation after joint replacement. *Curr Opin Rheumatol* 1999;11:12

Received: 26 October 2018

Accepted: 10 December 2018

Correspondence:

Paolo di Benedetto, MD, PhD,

Department of Orthopaedic Surgery,

University Hospital of Udine,

P.le S.Maria della Misericordia 15 - 33100 Udine, Italy

Tel. +39 0432 559464 - Fax +39 0432 559298

E-mail: paolo.dibenedetto@asuud.sanita.fvg.it