

Anemia secondary to the use of sodium valproate for preventing postoperative seizures in a 79-year-old man

A case report

Chen Li, MD^a, Lei Su, MD, PhD^a, Minxi Lao, MD, PhD^a, Shaofang Zhu, MD^b, Meilin Ding, MD^{a,*}

Abstract

Rationale: Sodium valproate is a widely used antiepileptic drug and also used to prevent postoperative seizures in neurosurgery. Anemia caused by sodium valproate is occasionally reported and most are from pediatric patients.

Patient concerns: We present the case of a 79-year-old man who developed anemia in the setting of a short-term sodium valproate therapy for the prevention of postoperative seizures.

Diagnosis: By testing complete blood count we found anemia and hepatic enzyme elevations arising after 3-week standard dose sodium valproate therapy for preventing postoperative seizures. Our investigations ruled out most of the known causes of anemia including infection, uncontrolled bleeding, underlying systemic disease, malnutrition, immune hemolytic anemia, and neoplasia. On the drug's discontinuation as diagnostic therapy the patient's hemoglobin began to rise spontaneously and liver function returned to normal. Thus anemia secondary to sodium valproate was considered as the most likely diagnosis.

Interventions: Sodium valproate was suspended and the patient was transfused with concentrated red blood cells.

Outcomes: The hemoglobin recovered obviously on the drug's discontinuation.

Lessons: Hematologic toxicity of sodium valproate can occur quickly. Regular complete blood count test helps to make prompt diagnosis and drug discontinuation leads to the recovery.

Abbreviations: AIHA = autoimmune hemolytic anemia, CT = computed tomography, EPO = erythropoietin, MCH = mean corpuscular hemoglobin, MCHC = mean corpuscular hemoglobin concentration, MCV = mean corpuscular volume, MDS = myelodysplastic syndrome, MR = magnetic resonance, PRCA = pure red cell aplasia, TSH = thyroid-stimulating hormone, WBCs = white blood cells.

Keywords: anemia, old man, sodium valproate

1. Introduction

Sodium valproate has been used as the most common antiepileptic drug to treat the patients with epilepsy and as a mood stabilizer for bipolar disorder. Although more trials are needed to evaluate the drug's effectiveness on reducing postcraniotomy seizures sodium valproate is also widely used

in neurosurgery.^[1,2] The side-effects of sodium valproate include dyspepsia, hepatic enzyme elevations, neurological disorders, hair loss, weight gain, pancreatitis, thrombocytopenia, and kidney damage.^[3] Thrombocytopenia is the most common hematologic toxicity while aplastic anemia, pure red cell aplasia (PRCA), macrocytosis, neutropenia, and bleeding disorders are some of the other hematological adverse reactions to sodium valproate therapy cited in the literature. Anemia caused by sodium valproate are rarely reported and most from the pediatric population. This report concerns an elderly patient who developed anemia and hepatic enzyme elevations on 3-week sodium valproate therapy for preventing postcraniotomy seizures. The hemoglobin recovered spontaneously after the therapy was discontinued. Informed consent was obtained from the patient for publication of this manuscript.

2. Case presentation

A 79-year-old man was admitted to the Geriatric department of our hospital for investigation of body stiffness for 3 years. He also had hypertension, chronic renal failure, and coronary heart disease. On admission, his complete blood count showed the hemoglobin was 112 g/L, the white blood cell count was $7.95 \times 10^9/L$ and the platelet count was $186 \times 10^9/L$. The magnetic resonance (MR) indicated enlargement of the ventricle and the pressure of cerebrospinal fluid increased significantly. Then the

Editor: N/A.

CL and LS contributed equally to this work.

Funding: This project was supported by grants from the Medical Research Foundation of Guangdong Province (No. C2015047).

The authors have no conflicts of interest to disclose.

^a Department of Geriatrics, ^b Department of Neurology, The First Affiliated Hospital, Sun Yat-sen University, Guangzhou, China.

* Correspondence: Meilin Ding, Department of Geriatrics, The First Affiliated Hospital, Sun Yat-sen University, No. 58 Zhongshan Road 2, Guangdong 510080, China (e-mail: dmlin08@sina.com).

Copyright © 2018 the Author(s). Published by Wolters Kluwer Health, Inc. This is an open access article distributed under the terms of the Creative Commons Attribution-Non Commercial-No Derivatives License 4.0 (CCBY-NC-ND), where it is permissible to download and share the work provided it is properly cited. The work cannot be changed in any way or used commercially without permission from the journal.

Medicine (2018) 97:50(e13626)

Received: 31 July 2018 / Accepted: 19 November 2018

<http://dx.doi.org/10.1097/MD.000000000013626>

old man was diagnosed with communicating hydrocephalus. He underwent a ventriculo peritoneal shunt and the intraoperative blood loss was 50 mL. On the day after surgery, the hemoglobin was 82 g/L which may be related to the postoperative minor blood loss and blood dilution after fluid replacement. After 5 hours of the operation the old man was treated with intravenous infusion of 1200 mg of valproate sodium continued for 24 hours to prevent postoperative seizures. The dose was reduced to 500 mg twice a day on the 4th day after operation and then changed to 500 mg once a day on the 11th day. The patient sustained mental malaise and the elevated liver enzyme levels were found on the 13th day after the initiation of sodium valproate therapy (the alanine aminotransferase was 170 U/L). Liver protection drugs were introduced but worked little. At about the same time his hemoglobin drop to 77 g/L and continued to decline to 68 g/L gradually. The patient was getting paler and weaker. After the operation the patient was fed by nasogastric tube and the urine and stool occult blood were negative. No further bleeding was found in the head CT examination reviewed. Excluding malnutrition and bleeding, we suspected that sodium valproate could have induced anemia and liver injury. Sodium valproate which had been used for 3 weeks was suspended and the patient was transfused with two units of concentrated red blood cells on day 21 and day 33 after the surgery separately because of pallor and fatigue. After two weeks his hemoglobin began to rise spontaneously and liver function returned to normal. The patient was well and his hemoglobin was 119 g/L a month after the discontinuance of sodium valproate (Fig. 1). During the observation period his other laboratory parameters

including mean corpuscular volume (MCV), mean corpuscular hemoglobin (MCH), mean corpuscular hemoglobin concentration (MCHC), platelets, white blood cells (WBCs), ferritin, vitamin B12, folic acid, erythropoietin (EPO), bilirubin, blood ammonia level, thyroid-stimulating hormone (TSH), reticulocyte count were all within the normal range (Table 1). Hepatitis A and B antigen were negative.

3. Discussion

This study is of a case of an anemia arising in the setting of a short-term sodium valproate therapy for the prevention of postoperative seizures. Sodium valproate is a widely used antiepileptic drug for seizure and mood disorders. In addition, the prophylactic use has been advocated for patient under-going cranial surgery with no history of epilepsy.^[2] Hematological side-effects of sodium valproate therapy have been occasionally reported and most are from pediatric patients, including thrombocytopenia, neutropenia, macrocytic anemia, bone marrow suppression, and pure red cell aplasia.^[4-6] Our investigations ruled out most of the known causes of anemia in old patients who had received a surgery including infection (the tests for infections were negative), uncontrolled bleeding, underlying systemic disease, malnutrition (the patient was fed by nasogastric tube after operation and his body mass index, serum folate and vitamin B12 levels were normal, suggesting adequate nutrient supply), immune hemolytic anemia (he was not jaundiced) and neoplasia, making the sodium valproate the most likely etiologic factor.

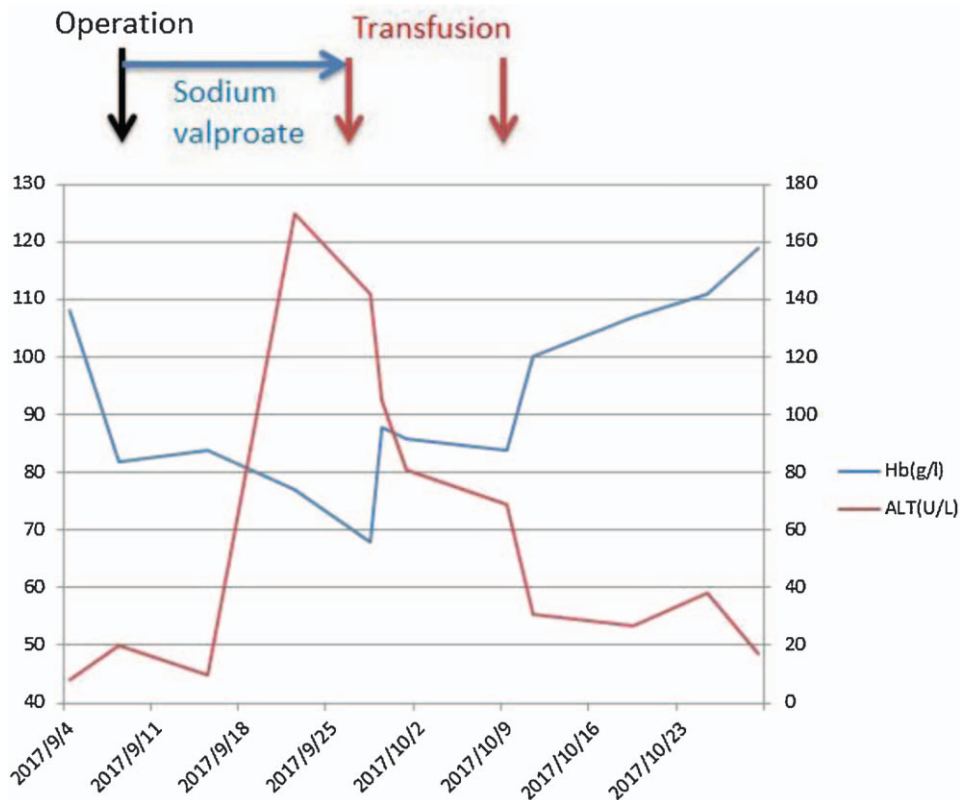


Figure 1. Changes of the patient's hemoglobin and alanine aminotransferase. The date of the operation (black arrow). The date of transfusion of red blood cells (red arrow). The duration of using sodium valproate (blue arrow).

Table 1**Laboratory findings before and after sodium valproate therapy.**

Parameter	Value before therapy	Value after therapy	Normal range
Hemoglobin	112 g/L	68 g/L	120–160 g/L
Red blood cells	$3.66 \times 10^{12}/L$	$2.21 \times 10^{12}/L$	$4.00\text{--}5.50 \times 10^{12}/L$
Mean corpuscular volume	92.45 fl	97.30 fl	82.00–95.00 fl
Mean corpuscular hemoglobin concentration	331.9 g/L	316.0 g/L	320.0–360.0 g/l
Mean corpuscular hemoglobin	30.69 pg	30.8 pg	27.00–31.00 pg
White blood cells	$7.95 \times 10^9/L$	$7.88 \times 10^9/L$	$4.00\text{--}10.00 \times 10^9/L$
platelets	$186 \times 10^9/L$	$168 \times 10^9/L$	$100\text{--}300 \times 10^9/L$
Ferritin	84.69 $\mu\text{g}/L$	178.58 $\mu\text{g}/L$	16.40–323.00 $\mu\text{g}/L$
Vitamin B12	364.59 ng/L	822.57 ng/L	187.00–1059.00 ng/L
Folic acid	5.25 $\mu\text{g}/L$	>23.2 $\mu\text{g}/L$	4.82–18.70 $\mu\text{g}/L$
erythropoietin	10.48 IU/L	49.37 IU/L	3.70–31.50 IU/L
Alanine aminotransferase	12 U/L	170 U/L	1–40 U/L
Aspartate aminotransferase	13 U/L	170 U/L	1–37 U/L

The prompt red cell regeneration and the brisk return of his liver enzyme upon discontinuing the drug, led to the conclusion that sodium valproate had probably been responsible. Hepatic enzyme elevations are well documented as one of side-effects of sodium valproate. According to the previous report of hepatotoxicity induced by sodium valproate, the frequency of hepatotoxic reactions is greatest during the first three months of therapy.^[7] Our patient exhibited severe anemia together with liver injury about two weeks after sodium valproate therapy. Thus we considered the possibility of drug-induced anemia and hepatic enzyme elevation.

Anemia secondary to sodium valproate has been noted in several literatures. The etiological diagnosis includes pure red cell aplasia (PRCA), myelodysplastic syndrome (MDS), and autoimmune hemolytic anemia (AIHA) secondary to sodium valproate.^[8–14] The pathogenesis is still unclear and drug-induced immunological dysfunction or DNA damage is thought to be the possible cause.^[12,13] Most reports are from pediatric patients.^[8,10,13,14] In all cases, the sodium valproate is prescribed for therapy of seizure disorder. The serum concentrations of valproate are almost within the reference range. There are five case reports of PRCA after initiation of sodium valproate and the interval between the initiation of the therapy and the onset of aplasia were from 3 months to 13 years. In these cases, some patients had previously received a long-term treatment of sodium valproate, and some had taken several kinds of anticonvulsants^[11] or had taken medicine after viral infections.^[10] Sodium-valproate-induced PRCA has been resolved upon its discontinuation in most cases, while a case report of a 67-year-old man shows that the discontinuation of sodium valproate failed to increase the number of reticulocytes and cyclosporine therapy led to a rapid and remarkable recovery of red blood cells.^[9] Myelodysplastic syndrome reported by Robert occurred in a 63-year-old female^[12] and autoimmune hemolytic anemia reported by Watanabe et al^[13] occurred in a 2-year-old girl, both of which were arising in the setting of chronic sodium valproate therapy.

Comparing with these cases, our report is unique in that the old patient without a history of seizures disorder developed anemia besides hepatic enzyme elevations after just 3-week standard dose sodium valproate therapy for preventing postoperative seizures. The hemoglobin recovered obviously on the drug's discontinuation. We had suggested a bone marrow biopsy but the patient refused this invasive test. Thus the pathologic mechanism is unclear. The score of Naranjo Adverse Reaction Probability Scale

is 6. We did not monitor the serum concentrations of valproate, which is a limitation of our work. If we had monitored valproic acid levels 3 to 4 days after the drug's administration, the diagnosis of adverse drug reaction would be more convincing.

On the other hand, the review by Weston et al^[2] show that there is not enough evidence of sufficient quality available to suggest that antiepileptic drugs can or cannot be recommended to reduce postcraniotomy seizures. In this case, the usage of sodium valproate is routine in the neurosurgery department of our hospital. The dosage was 1200 mg continuous intravenous drip for 24 hours in the first 3 days, then reduced to 500 mg orally once or twice daily. A significant negative correlation between valproate serum level and platelet count had been reported,^[5] but as far as we know there is no specific literature reported yet about the relationship between the occurrence of anemia and the dose of valproate. The dosage of valproate causing anemia used in the literature is about 10 to 20 mg/kg/day and the serum concentrations of valproate are almost within the reference range. We agree that due to a decrease in unbound clearance of valproate and possibly a greater sensitivity to adverse reactions in the elderly, the starting dose should be reduced in these patients. Meanwhile, we suggest neurologists and neurosurgeon to be aware of the hematological adverse effects of sodium valproate even in a short-term therapy and regular testing of hematological parameters is necessary for patients on such treatment.

4. Conclusion

Hematologic toxicity of sodium valproate can occur quickly and the mechanism is unclear. When unexplained anemia occurs clinicians should pay attention to the hematological side-effects of sodium valproate and test complete blood count regularly.

Author contributions

Conceptualization: Chen Li, Minxi Lao, Meilin Ding.

Data curation: Lei Su, Shaofang Zhu.

Formal analysis: Shaofang Zhu.

Investigation: Shaofang Zhu.

Methodology: Chen Li, Lei Su, Shaofang Zhu, Meilin Ding.

Project administration: Chen Li, Lei Su.

Software: Lei Su, Shaofang Zhu.

Supervision: Chen Li, Lei Su, Minxi Lao, Meilin Ding.

Visualization: Minxi Lao.

Writing – review & editing: Chen Li, Lei Su.

References

- [1] Manaka S, Ishijima B, Mayanagi Y. Postoperative seizures: epidemiology, pathology, and prophylaxis. *Neurol Med Chir* 2003;43:589–600. discussion 600.
- [2] Weston J, Greenhalgh J, Marson AG. Antiepileptic drugs as prophylaxis for post-craniotomy seizures. *Cochrane Database Syst Rev* 2015;3: CD007286.
- [3] Dreifuss FE, Langer DH. Side effects of valproate. *Am J Med* 1988;84:34–41.
- [4] Acharya S, Bussel JB. Hematologic toxicity of sodium valproate. *J Pediatr Hematol Oncol* 2000;22:62–5.
- [5] Vasudev K, Keown P, Gibb I, et al. Hematological effects of valproate in psychiatric patients: what are the risk factors? *J Clin Psychopharmacol* 2010;30:282–5.
- [6] Ozkara C, Dreifuss FE, Apperson Hansen C. Changes in red blood cells with valproate therapy. *Acta Neurol Scand* 1993;88:210–2.
- [7] Powell-Jackson PR, Tredger JM, Williams R. Hepatotoxicity to sodium valproate: a review. *Gut* 1984;25:673–81.
- [8] Bartakke S, Abdelhaleem M, Carcao M. Valproate-induced pure red cell aplasia and megakaryocyte dysplasia. *Br J Haematol* 2008;141:133.
- [9] Kanda J, Chonabayashi K, Watanabe M, et al. Successful treatment with cyclosporine of sodium valproate-induced pure red cell aplasia. [Rinsho Ketsueki] *Jap J Clin Hematol* 2005;46:1114–7.
- [10] MacDougall LG. Pure red cell aplasia associated with sodium valproate therapy. *JAMA* 1982;247:53–4.
- [11] The T, Kolla R, Dawkins F, et al. Pure red cell aplasia after 13 years of sodium valproate, and bone marrow suppression after 17 years of carbamazepine. *PLoS Med* 2004;1:e51.
- [12] Allan RW. Myelodysplastic syndrome associated with chronic valproic acid therapy: a case report and review of the literature. *Hematology* 2007;12:493–6.
- [13] Watanabe T, Nakayasu K, Nagayama Y. Autoimmune haemolytic anaemia and renal Fanconi syndrome caused by valproate therapy. *Eur J Pediatr* 2005;164:186–7.
- [14] Kaczorowska-Hac B, Matheisel A, Maciejka-Kapuscinska L, et al. Anemia secondary to valproic acid therapy in a 13-year-old boy: a case report. *J Med Case Rep* 2012;6:239.