



## Case report

# Vitamin D deficiency in the pathogenesis of leiomyoma and intravascular leiomyomatosis: A case report and review of the literature

Ian Judson<sup>a,\*</sup>, Christina Messiou<sup>b</sup>

<sup>a</sup> The Institute of Cancer Research, Fulham Rd, London SW3 6JB, UK

<sup>b</sup> The Royal Marsden NHS Foundation Trust, Fulham Rd, London SW3 6JJ, UK

## ABSTRACT

This is a case of recurrent intravascular leiomyomatosis in a pre-menopausal woman of African-Caribbean heritage. She presented in 2006 with multiple uterine leiomyomata, tumour invading the inferior vena cava (IVC) extending into the right atrium, and pulmonary metastases. Her initial presentation was treated surgically. On recurrence she was treated by oestrogen suppression using a combination of goserelin and letrozole, with a substantial response. She subsequently reported further regression of disease following exposure to strong sunlight enabling her to discontinue oestrogen suppression without relapse. The hypothesis is that the benefit was due to vitamin D. The role of hypovitaminosis D in the pathogenesis of uterine leiomyomata is discussed, including epidemiology data demonstrating a link between ethnicity and risk and the proven mechanisms by which vitamin D controls oestrogen and progesterone receptor expression and influences other signalling pathways involved in the pathogenesis of leiomyomas. Data indicating the intermediate malignancy nature of intravascular leiomyomatosis, are discussed. We are not aware of other reports indicating a link between intravascular leiomyomatosis and a lack of vitamin D.

## 1. Case report

Herein we report a case of strong sunlight, supplemented with oral vitamin D3, causing stabilisation of uterine leiomyomas permitting withdrawal of oestrogen suppression therapy in a patient with uterine leiomyomas and intravascular leiomyomatosis.

A pre-menopausal woman of African-Caribbean heritage presented in 2006, at the age of 36, with pulmonary embolus, an intracardiac mass tumour thrombus extending from the pelvis up the inferior vena cava (IVC) to the right ventricle. She also had uterine leiomyomas. The intravascular tumour was resected on cardio-pulmonary bypass by a cardiothoracic surgeon and an abdominal surgeon with special expertise in renal surgery. The majority of the tumour was pulled out from the right ventricle as it was quite mobile. However an incision was also made in the IVC from the level of the left renal vein to remove the mass from the left renal vein and an incision was also made in the left renal vein itself. There was a small amount of tumour in the left ovarian vein and therefore the left ovarian vein was removed. The uterus, fallopian tubes and ovaries were not resected because the patient was unwilling to be rendered infertile. The histology of the mass removed from the right ventricle was reported as benign leiomyoma. Fig. 1 shows haematoxylin and eosin (H&E) a stained section of the resected specimen at two different magnifications. It was reported as follows: "Sections show an

encapsulated, elongated spindle cell tumour with large areas of infarction. The tumour is composed of bland spindle cells arranged in loose fascicles, and admixed with thick-walled blood vessels, few of which show hyalinization. Myxoid change is noted focally, mitoses and nuclear pleomorphism is not seen. The tumours cells stain for ER, PgR, desmin, SMA, Bcl-2 and caldesmon and are negative for S100, CD34, CD117, calretinin, AE1/3 and HMB45." We also note the presence of clear cells and both this and hyalinisation have been reported in intravascular leiomyomatosis together with the suggestion that the appearances of intravascular leiomyomatosis differ somewhat from benign leiomyoma (Han et al., 1998; Yaguchi et al., 2010).

No prophylaxis was offered following surgery and the patient was lost to follow-up. She re-presented in 2009 with large pelvic and abdominal masses (Fig. 2a), lung nodules (Fig. 2b) and a suspicion of recurrence in the IVC indicating a diagnosis of intravascular leiomyomatosis. The following year in 2010 a cardiac MRI scan confirmed the presence of tumour in the IVC and right atrium. Treatment with a combination of goserelin and letrozole was commenced in August 2010 resulting in a rapid reduction in the size of pelvic and abdominal leiomyomas (Fig. 3A and B), a slight reduction in the size of pulmonary metastases was also seen together with regression of disease in the IVC on cardiac MRI.

There was a further slight reduction in the volume of intra-

Abbreviations: ER, oestrogen receptor; PgR, progesterone receptor; SMA, smooth muscle actin.

\* Corresponding author.

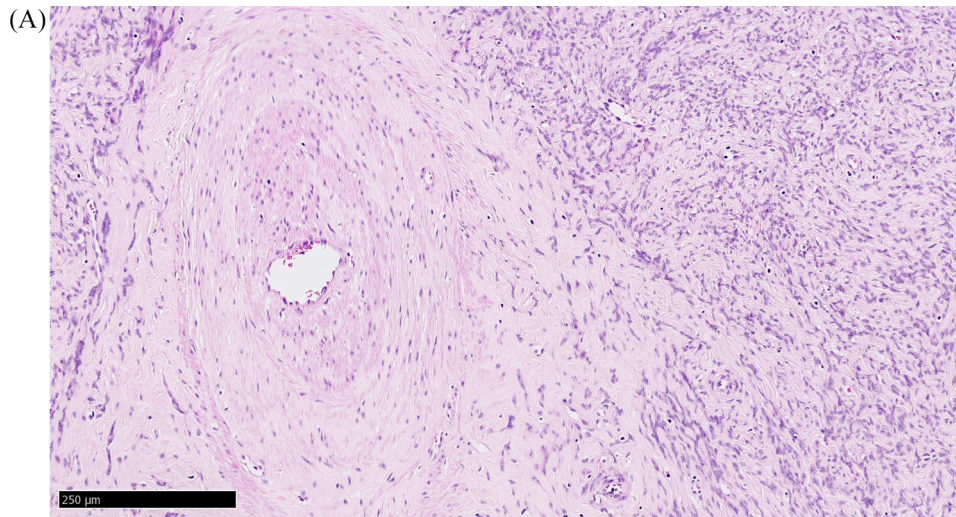
E-mail address: [Ian.Judson@icr.ac.uk](mailto:Ian.Judson@icr.ac.uk) (I. Judson).

<https://doi.org/10.1016/j.gore.2020.100681>

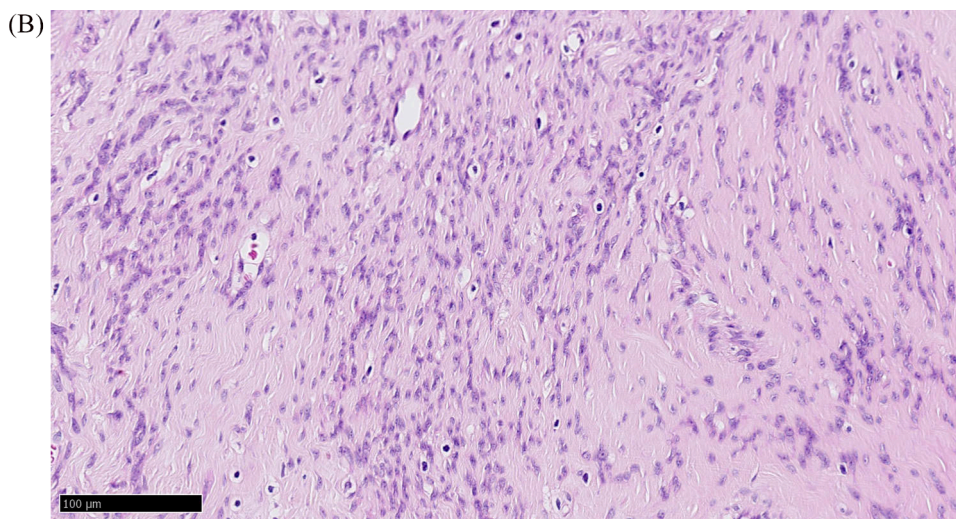
Received 5 August 2020; Received in revised form 1 December 2020; Accepted 6 December 2020

Available online 13 December 2020

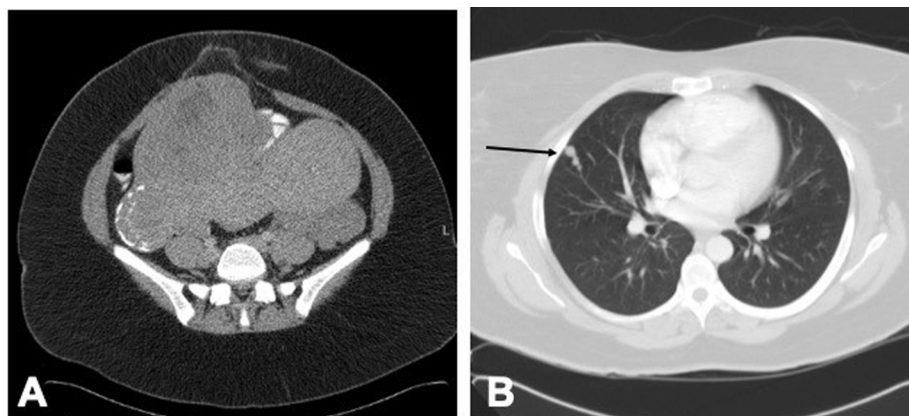
2352-5789/© 2020 Published by Elsevier Inc. This is an open access article under the CC BY-NC-ND license (<http://creativecommons.org/licenses/by-nc-nd/4.0/>).



**Fig. 1A.** H&E stained section of resected tumour from the right ventricle at 10X magnification showing a large thick-walled blood vessel, spindle cells loosely packed in a myxoid stroma. No mitoses are seen.



**Fig. 1B.** Part of the same section is shown at 20x magnification.



**Fig. 2.** Axial contrast enhanced CT abdomen & pelvis performed in 2009 demonstrates large uterine leiomyomata (A) and pulmonary nodules (arrow B).

abdominal disease (Fig. 3C) in 2011. However, the patient was increasingly distressed by the side effects of oestrogen suppression, particularly by insomnia and reduced libido and discontinued treatment

to relieve these symptoms in 2012. A CT in March 2013 showed slight progression in both the pelvic and abdominal disease and lung metastases. In June 2013 a repeat CT showed a further increase in the size of

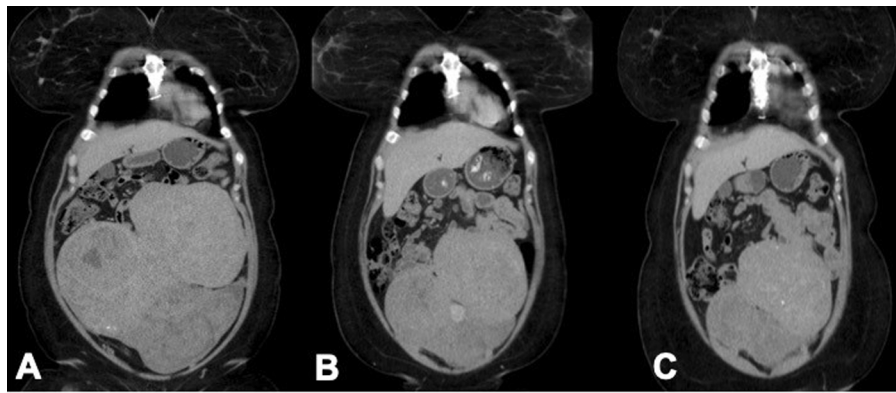


Fig. 3. Coronal CT reformat from a contrast enhanced CT performed in July 2010 (A), September 2010 (B) and 2012 (C) shows shrinkage of the masses.

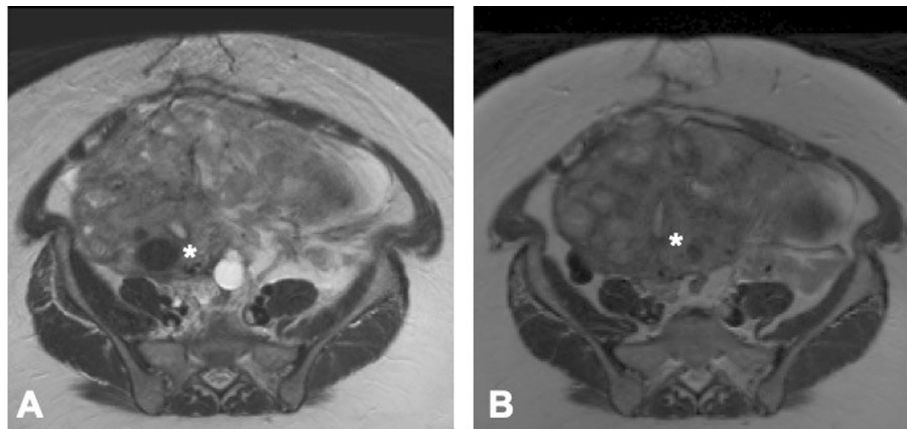


Fig. 4. Axial T2W MRI in 2013 (A) and 2015 (B) showing a large soft tissue mass centred on the uterus (\*). Maximum axial dimension in 2013 was  $24.2 \times 13.9$  cm compared with  $22.4 \times 12.2$  cm in 2015.

the pelvic disease and a cardiac MRI and echocardiogram showed possible recurrent disease in the IVC. Ulipristal acetate was commenced in March 2013 but has since been discontinued. Letrozole and goserelin treatment was recommenced in October 2013 and continued until 2015.

At an out-patient visit in August 2015 she reported that during a trip to the Southern USA in February 2013 to visit a relative, during which she had much more exposure to sunlight than in the UK, she experienced a significant reduction in the size of the abdominal masses and the associated abdominal bloating and discomfort. She was also taking oral vitamin D3 supplements in the form of cod liver oil and vitamin D3. Following this experience, noting that her tumours were smaller in the Summer, during the year 2015 she started regularly using a sunbed twice a week, when access to strong sunshine was not possible. She continued to take cod liver oil and vitamin D3. This combined strategy proved successful and she was able to stop the letrozole and goserelin in 2015 without suffering a relapse. Vitamin D blood levels were not examined following this new information, because we had no baseline prior to the start of self-medicated vitamin D supplementation. Fig. 4 shows a comparison between a representative tumour in 2013 and the same tumour in 2015 showing a small reduction in tumour volume. The patient remains well to this day with stable disease by RECIST, although a more recent scan may show slight progression, and has not needed to recommence treatment with letrozole and goserelin in the last 5 years.

## 2. Discussion

Uterine leiomyomas (fibroids) are extremely common. It is estimated that by the age of 50, nearly 70% of white women and >80% of African-American women will have ultrasound evidence of uterine fibroids. A

recent study demonstrated a link between low blood levels of 25-hydroxyvitamin D (<20 ng/ml) and an increased risk of leiomyomata (Han et al., 1998). A study in Italy reported similar findings, demonstrating that women with at least one uterine leiomyoma had a significantly lower blood level of 25-hydroxyvitamin D3. In this study 25-hydroxyvitamin D3 deficiency was defined as <10 ng/ml and this was associated with an odds ratio for leiomyoma of 2.4 (95% confidence interval 1.2–4.9, P=0.16) compared with controls (Yaguchi et al., 2010). An American nutrition survey African-American women were 10 times more likely to have low vitamin D levels than white women (Baird et al., 2013). The increased incidence of uterine leiomyomas in African-American women has been identified as a public health issue (Eltoukhi et al., 2014; Paffoni et al., 2013). It has been shown that 1–25-dihydroxyvitamin D3 (1,25(OH)2D3) regulates the expression of oestrogen and progesterone receptors in uterine leiomyoma cells (Al-Hendy et al., 2015; Nesby-O'Dell et al., 2002). Treating these cells with 1,25(OH)2D3 reduced the expression of oestrogen receptor- $\alpha$ , progesterone receptor-A and B and members of the steroid receptor coactivator (SRC) family. In addition, 1,25(OH)2D3 also reduces TGF $\beta$ 3- induced fibrosis-related gene expression, e.g. collagen and fibronectin genes, in uterine leiomyoma cells (Halder et al., 2011; Sharan et al., 2011). Vitamin D3 has also been shown to inhibit the proliferation of uterine leiomyoma cells via inhibition of catechol-o-methyltransferase (Al-Hendy et al., 2016) and to inhibit WNT/ $\beta$ -catenin and mTOR signalling pathways in uterine leiomyoma cells (Ciavattini et al., 2016). There is a strong case for considering vitamin D supplementation in women of reproductive age and hypovitaminosis D as a preventive measure and some evidence that this can prevent the progression of pre-existing uterine leiomyomas (Ordulu et al., 2016).

### 3. Conclusions

The role of vitamin D in the pathogenesis of leiomyomas is still not universally recognised by gynecologists. Hypovitaminosis D is a significant problem in women of darker skin ethnicity living in Northern climates, since they require greater sun exposure to generate sufficient vitamin D in the skin, sometimes compounded by cultural factors. This case highlights the potential value of sunlight and vitamin D supplementation in controlling leiomyomas. What is particularly unusual is the fact that this woman was diagnosed with the potentially life-threatening situation of intravascular leiomyomatosis with tumour extending up the IVC into the right atrium prior to successful treatment with combined oestrogen deprivation. This is now recognised to be a disease of intermediate grade malignancy as reported by [Ordulu et al. \(2016\)](#), with a gene expression profile similar to that of leiomyosarcoma, rather than leiomyoma or normal myometrium and the frequent finding of a translocation der[14]t[12;14](q14.3;q24) as shown by co-localization of probes for *HMGA2* (12q14.3) and 14q24 by FISH. In contrast, this study also showed no evidence in the intravenous leiomyomatosis cases of loss of 7q22, frequently deleted in uterine leiomyomata. This case is by no means proof, but it seems likely that this condition is also influenced by the same hormonal factors as common leiomyomas and hence its growth is potentially enhanced by lack of vitamin D and impeded by repletion.

### Consent

Written informed consent was obtained from the patient for publication of this case report and accompanying images.

### Authorship

Both authors contributed to the manuscript, IJ was mainly responsible for the case report and discussion and was the physician who initially cared for the patient. CM was responsible for the choice and presentation of the images. Both authors reviewed the final manuscript.

### Declaration of Competing Interest

The authors declare that they have no known competing financial interests or personal relationships that could have appeared to influence the work reported in this paper.

### Funding acknowledgements

We wish to acknowledge National Health Service funding to the

National Institute for Health Research Biomedical Research Centre, Clinical Research Facility in Imaging and the Cancer Research Network. The views expressed in this publication are those of the author(s) and not necessarily those of the National Health Service, the National Institute for Health Research or the Department of Health.

### References

- Al-Hendy, A., Diamond, M.P., El-Sohemy, A., Halder, S.K., 2015. 1,25-Dihydroxyvitamin D3 regulates expression of sex steroid receptors in human uterine fibroid cells. *J. Clin. Endocrinol. Metab.* 100 (4), E572–E582. <https://doi.org/10.1210/jc.2014-4011>.
- Al-Hendy, A., Diamond, M.P., Boyer, T.G., Halder, S.K., 2016. Vitamin D3 inhibits Wnt/ $\beta$ -catenin and mTOR signaling pathways in human uterine fibroid cells. *J. Clin. Endocrinol. Metab.* 101 (4), 1542–1551.
- Baird, D.D., Hill, M.C., Schectman, J.M., Hollis, B.W., 2013. Vitamin D and the risk of uterine fibroids. *Epidemiology* 24 (3), 447–453. <https://doi.org/10.1097/EDE.0b013e31828acca0>.
- Ciavattini, A., Delli Carpini, G., Serri, M., Vignini, A., Sabbatinelli, J., Tozzi, A., Aggiusti, A., Clemente, N., 2016. Hypovitaminosis D and “small burden” uterine fibroids: Opportunity for a vitamin D supplementation. *Medicine* 95 (52), e5698. <https://doi.org/10.1097/MD.0000000000005698>.
- Eltoukhi, H.M., Modi, M.N., Weston, M., Armstrong, A.Y., Stewart, E.A., 2014. The health disparities of uterine fibroid tumors for African American women: a public health issue. *Am. J. Obstet. Gynecol.* 210 (3), 194–199. <https://doi.org/10.1016/j.ajog.2013.08.008>.
- Halder, S.K., Goodwin, J.S., Al-Hendy, A., 2011. 1,25-Dihydroxyvitamin D3 reduces TGF-beta3-induced fibrosis-related gene expression in human uterine leiomyoma cells. *J. Clin. Endocrinol. Metab.* 96 (4), E754–E762.
- Han, H.S., Park, I.A., Kim, S.H., Lee, H.P., 1998. The clear cell variant of epithelioid intravenous leiomyomatosis of the uterus: report of a case. *Pathol. Int.* 48 (11), 892–896.
- Nesby-O'Dell, S., Scanlon, K.S., Cogswell, M.E., Gillespie, C., Hollis, B.W., Looker, A.C., Allen, C., Dougherty, C., Gunter, E.W., Bowman, B.A., 2002. Hypovitaminosis D prevalence and determinants among African American and white women of reproductive age: third National Health and Nutrition Examination Survey, 1988–1994. *Am. J. Clin. Nutr.* 76 (1), 187–192.
- Ordulu, Z., Nucci, M.R., Dal Cin, P., Hollowell, M.L., Otis, C.N., Hornick, J.L., Park, P.J., Kim, T.-M., Quade, B.J., Morton, C.C., 2016. Intravenous leiomyomatosis: an unusual intermediate between benign and malignant uterine smooth muscle tumors. *Mod. Pathol.* 29 (5), 500–510. <https://doi.org/10.1038/modpathol.2016.36>.
- Paffoni, A., Somigliana, E., Viganò, P., Benaglia, L., Cardellicchio, L., Pagliardini, L., Papaleo, E., Candiani, M., Fedele, L., 2013. Vitamin D status in women with uterine leiomyomas. *J. Clin. Endocrinol. Metab.* 98 (8), E1374–E1378. <https://doi.org/10.1210/jc.2013-1777>.
- Sharan, C., Halder, S.K., Thota, C., Jaleel, T., Nair, S., Al-Hendy, A., 2011. Vitamin D inhibits proliferation of human uterine leiomyoma cells via catechol-O-methyltransferase. *Fertility Sterility* 95 (1), 247–253. <https://doi.org/10.1016/j.fertnstert.2010.07.1041>.
- Yaguchi, C., Oi, H., Kobayashi, H., Miura, K., Kanayama, N., 2010. A case of intravenous leiomyomatosis with high levels of hyaluronan. *J. Obstet. Gynaecol. Res.* 36 (2), 454–458.