



Lateral Meniscus Allograft Transplantation in Combination with BMAC (Bone Marrow Aspirate Concentrate) Injection: Biologic Augmentation of the Allograft

Murat Bozkurt, M.D., Ph.D.

Abstract: Meniscal allograft transplantation (MAT) has proven successful in relieving joint pain and providing functional improvement in patients who have undergone subtotal or total meniscectomy. Bone marrow aspirate concentrate (BMAC) is a biological adjuvant that was shown in the literature to be effective in treating cartilage damage and muscle-tendon tissue problems. The aim of the study is the concomitant use of MAT and BMAC, which are both considered biological treatments and would be beneficial in clinical practice.

Introduction

In the literature, meniscal allograft transplantation (MAT) has been proven successful in serving two purposes: relieving joint pain and providing functional improvement. It has been almost 30 years since successful clinical results of MAT were first reported in the literature, which comprised studies of the short-term, medium-term, and long-term follow-up of patients.¹⁻⁴ Studies have evaluated allograft survival, and it was reported that short-term and medium-term success was achieved; however, such success was seen to decrease in the long term.⁵⁻⁹ A hypothesis has been put forth in the literature that the combination of lateral MAT (LMAT) with an intra-articular and in situ injection of bone marrow aspiration concentrate (BMAC) would result in improved functional and radiological results in the short term, which would, thereby, extend

the life of the allograft. In the literature, BMAC, which is a biological aid, has been reported to be an effective method that can be used when treating cartilage injuries and problems with muscle-tendon tissue.¹⁰⁻¹¹ Additionally, the use of BMAC in combination with meniscus implants and cell-free cartilage scaffolds has been reported to provide very successful results.¹²⁻¹⁴ The current study was conducted with the aim of presenting the technique, involving LMAT in combination with intra-articular and in situ BMAC injections. We think that the application of biological therapies that use stem cells, such as the use of BMAC during MAT, will become a widespread practice, and reports on the use of BMAC in MAT will contribute greatly to the literature.

Patient Evaluation, Imaging, and Indications

The technique can be employed in patients with total or close to total meniscectomy for increasing the viability of the meniscus allograft and accelerating healing by ensuring the compatibility of the meniscus allograft with the patient's capsule and the soft tissue. MRI should be performed both to check the cartilage, ligaments, and other parts of the knee joint and to observe the volume and tissue characteristics of meniscus tissue loss. A long-leg weight-bearing radiograph is necessary for alignment evaluation of the patient. CT is important in determining the suitability of the meniscal allograft for the patient's meniscus size and selecting the appropriate morphological features from the tissue bank.

Ankara Yıldırım Beyazıt University, School of Medicine, Department of Orthopaedics and Traumatology and Department of Musculoskeletal System and Regenerative Medicine, Ankara, Turkey.

Full ICMJE author disclosure forms are available for this article online, as supplementary material.

Received October 2, 2021; accepted December 18, 2021.

Address correspondence to Dr. Murat Bozkurt, M.D., Ph.D., Ankara Acıbadem Hospital, Department of Orthopaedics, 06450, Cankaya-Ankara, Turkey. E-mail: nmbozkurt@gmail.com

© 2022 THE AUTHORS. Published by Elsevier Inc. on behalf of the Arthroscopy Association of North America. This is an open access article under the CC BY-NC-ND license (<http://creativecommons.org/licenses/by-nc-nd/4.0/>).

2212-6287/211401

<https://doi.org/10.1016/j.eats.2021.12.035>

Surgical Technique

Graft Preparation

Prior to the operation, the allograft is first thawed at room temperature in a normal saline solution. Preparation of the allograft is conducted by an assistant on a table at the back of the room, while the diagnostic arthroscopy and debridement are being performed. First, it is necessary to create a bone bridge 7-mm wide and 10-mm deep that connects the anterior and posterior horn attachments. To do this, a cutting block, sagittal saw, and guide are used. Next, a no. 2 nonabsorbable suture is passed through the meniscal allograft at the junction where the body intersects, and the anterior and posterior of the bone in the graft, which assisted with passage of the graft and anatomic reduction, while the allograft is being inserted into the knee (Fig 1).

Lateral Meniscus Allograft Transplantation

An examination of the range of motion and stability of the knee is performed, while the patient is under anesthesia. Next, arthroscopy is performed, and it is observed that small remnants of both the anterior and posterior horns of the lateral meniscus deficiency remain. In the next step, the standard protocol is followed to thaw and reconstitute the meniscal allograft. Trimming of the remnants of the meniscus is performed, as well as that of the body of the native meniscus remnants, to supply a fresh bleeding surface, which is located within 1–2 mm of the peripheral rim where the meniscal allograft is to be placed (Fig 2). For the graft passage a minilateral parapatellar arthrotomy is used to facilitate the graft passage and open the suture fixation of the anterior aspect of the meniscal allograft. Next, trimming of the anterior horn of the

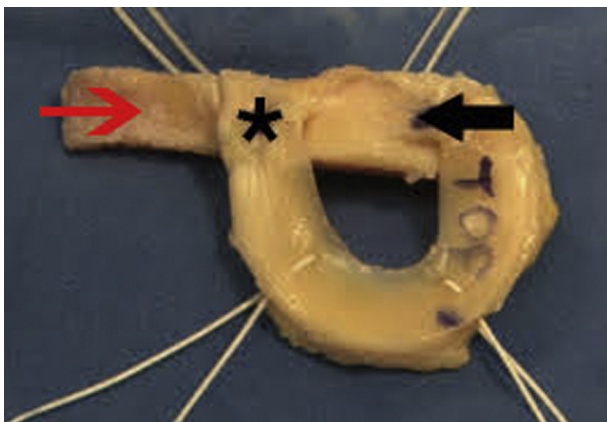


Fig 1. Final graft preparation for bone block meniscal transplantation with sutures. Red arrow denotes the anterior part of the bone block, while the asterisk (*) denotes the anterior root of the lateral meniscus, and the black arrow denotes the posterior root of the lateral meniscus.

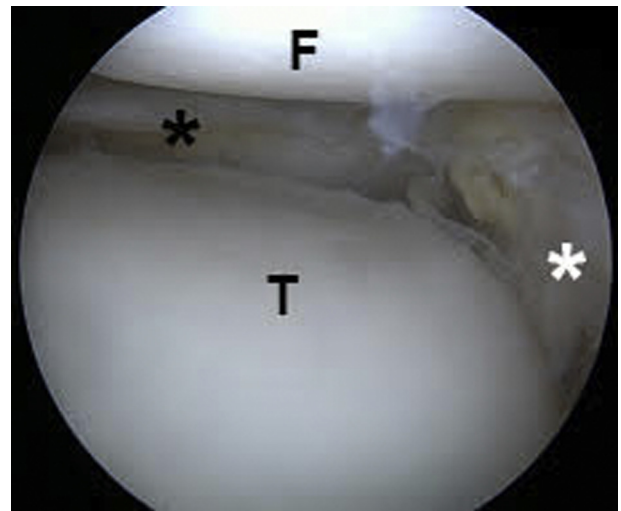


Fig 2. Meniscal remnant debridement for donor site preparation. F, femur; T, Tibia. Black asterisk (*) denotes the posterior horn of the lateral meniscus, while the white asterisk denotes the anterior horn of the lateral meniscus.

native meniscus remnant is performed to provide a fresh, bleeding rim. Spinal needle localization is performed, and then the inferior anterolateral accessory portal is constructed, in accordance with both the anterior and posterior root insertions of the lateral meniscus. Following that, the portal is expanded into an arthrotomy so as to enable insertion of the graft. A vertical oscillating saw is placed into the joint via the anterolateral accessory portal (Fig 3). A reference slot is created superficially by means of connecting the anterior and posterior horns of the meniscus. The line is then marked on the anterior border of the lateral tibial plateau at a distance of 7 mm, and then the borders of the bone slot are formed via the use of a second vertical oscillating saw, which is done at a depth of 10 mm. A bone bridge 7-mm wide and 10-mm deep connecting the anterior and posterior horn attachments is created using a cutting block guide and sagittal saw. These lines are maintained in a position parallel to the slope of the tibial plateau, and the tip is attached around the posterior tibial cortex. A box chisel is carefully tapped using a mallet along the path of the reamed tunnel to make the tunnel rectangular and eliminate any remaining residual bone or cartilage. The slot created using the box chisel is 8 mm wide and 10 mm deep. To make sure that the bone tunnel is able to accommodate the bone bridge on the graft, rasps measuring 7 and 8 mm are used in series until the point that the rasp measuring 8 mm is flush with the tibial plateau and is able to glide in and out of the bone slot with ease. After the pre-fixation preparation of the lateral meniscus allograft is completed, BMAC is injected into the entire periphery of the meniscus allograft. Afterward, the meniscus allograft is soaked in a container filled with BMAC. At

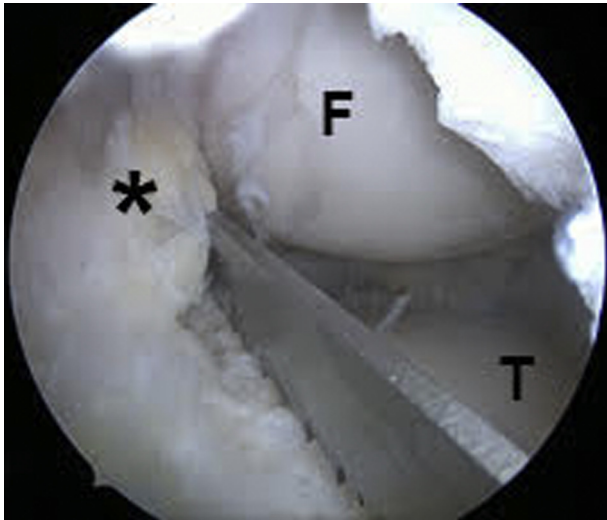


Fig 3. A vertical oscillating saw was placed into the joint via the anterolateral accessory portal. F, femur; T, tibia. The black asterisk denotes the anterior cruciate ligament.

this point, varus stress is applied to the knee, and then tension is steadily maintained on the graft passage sutures while the bone bridge is introduced into the slot under direct visualization. To expose the slot more clearly, two army-navy retractors are used. Inserting the bone bridge into the trough should not require more than very gentle finger pressure. Combining this gentle tension on the sutures in the graft passage, in addition to the varus stress on the knee, as well as the finger pressure applied by the surgeon via the arthrotomy will all aid in reducing the lateral meniscus allograft into the lateral compartment. Once the meniscus allograft is securely in position, it is then peripherally fixed using multiple inside-out vertical mattress sutures, via 2-0 nonabsorbable sutures, wherein the needles are captured using the posterolateral approach. Suturing is performed on the inferior and superior surfaces of the allograft in order to ensure balanced repair while the meniscus is in the anatomic position (Fig 4). Knotless suture is used to fix the anterior horn to the bone. The surgeon must be careful at this point to prevent the sutures from becoming entangled prior to their being finally tied down.

Preparation of the Bone Marrow Aspiration Concentrate

On the surgical side, the anterior iliac crest is selected to be the donor site for harvesting of the BMAC. Following surgical cleaning of the selected surgical area in addition to sterile draping, the aspiration of 60 mL of bone marrow is performed, using a bone marrow aspiration needle, from the position of the anterior iliac bone. Next, it is concentrated using the BMAC. This system usually produces 7 to 10 mL of mesenchymal stem cells. In the first step of the procedure, 2 mL of

BMAC is injected into the periphery of the meniscus allograft, allowing it to reach the inside of the tissue. In the second step, any remaining fluids in the joint as a result of the arthroscopic procedure are aspirated prior to the intra-articular injection, thus creating a dry area. The injection of the BMAC is then performed using a syringe and needle, under arthroscopic control, into the roots, anterior, middle, and posterior areas of the meniscus allograft and capsulo-meniscal junction, as well as under the bone block where the allograft has been placed in the tibial groove. The BMAC that is remaining is then injected into the joint so as to improve the healing response. At this point, the procedure is terminated (Video 1, Fig 5, A-D).

Step by Step Technique Summary

1. Arthroscopic examination of the patient is performed
2. Arthroscopic debridement of lateral meniscus remnants
3. A mini-lateral parapatellar arthrotomy is performed for graft passage and anterior lateral meniscus fixation
4. Lateral meniscus allograft prepared with the bone bridge technique
5. Harvesting of BMAC and its preparation
6. Injection into the periphery of the meniscus allograft, allowing it to reach the inside of the tissue
7. Lateral meniscus allograft reduction and fixation
8. The injection of the BMAC is then performed using a syringe and needle, under arthroscopic control, into the roots, anterior, middle, and posterior areas of the

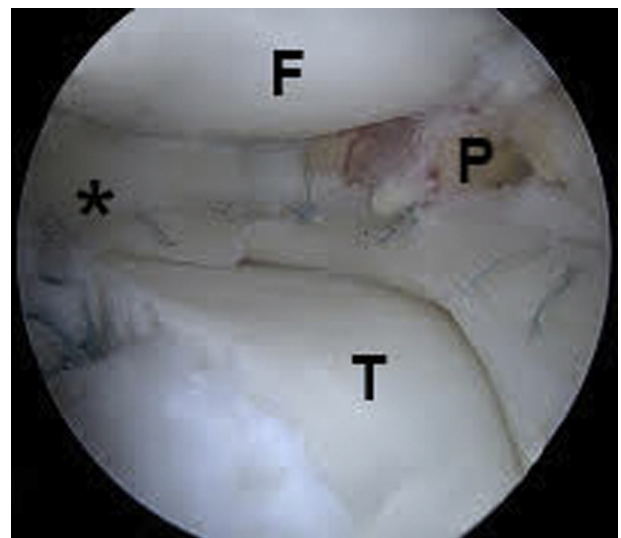


Fig 4. Final anatomic position of the lateral meniscus allograft transplantation after fixation. F, femur; P, popliteus tendon; T, tibia. The black asterisk denotes the posterior horn of the lateral meniscus.

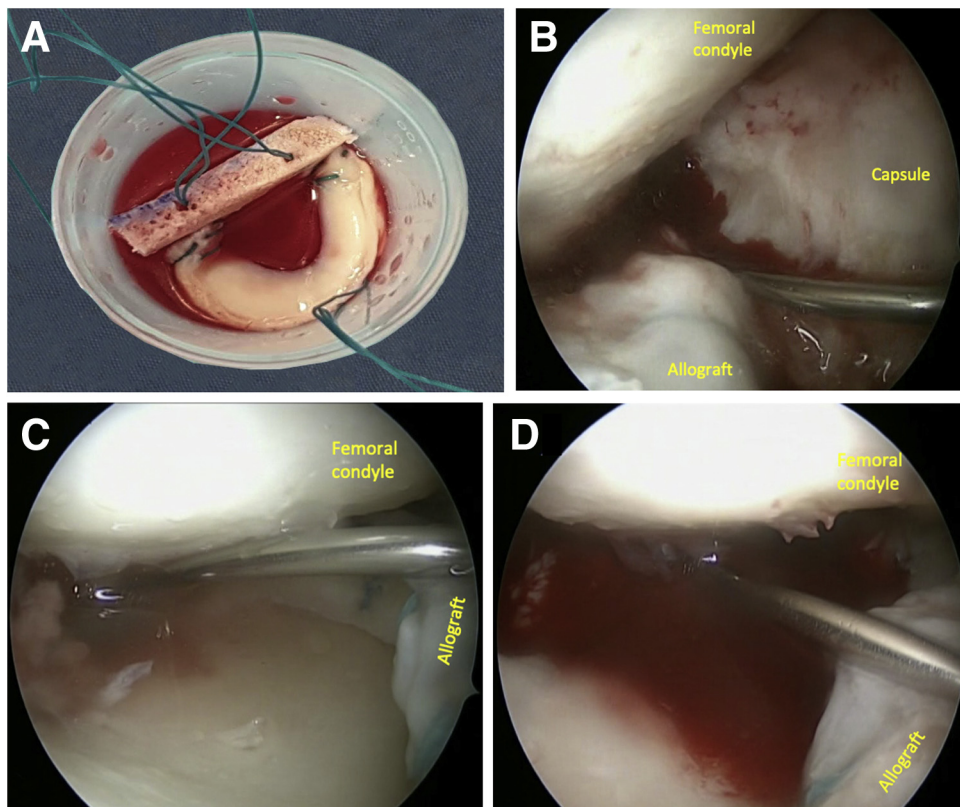


Fig 5. (A) Bone marrow aspirate concentrate (BMAC) soaking of the lateral meniscus allograft. (B) BMAC injection to the capsule and periphery of the lateral meniscus allograft. (C) BMAC injection of the posterior root of the lateral meniscus allograft. (D) BMAC injection of the body of the meniscus allograft.

meniscus allograft and capsulo-meniscal junction, as well as under the bone block of the allograft.

Rehabilitation

During the rehabilitation process, focus is placed on increasing the joint movements of the patients quickly, without jeopardizing the graft healing. Patients receive anticoagulant treatment with low molecular weight heparin for 3 weeks. They are followed up with the use of an angle-adjusted knee brace for 6 weeks postoperatively. Immediately following surgery, the patients are all encouraged to do as many calf pumping and quadriceps sets as they can, and straight leg raises are started 1 day postoperatively. Two days postoperatively, the patients begin to use a continuous passive motion machine to perform passive knee range-of-motion exercises while wearing a hinged knee brace. The purpose of performing these exercises is for the patients to be able to achieve full extension in 1 week, 90° flexion in 3 weeks, and 120° flexion in 6–8 weeks. Isometric muscle strengthening and cocontraction exercises are started from the first postoperative day. Proprioception training is started after the third week. Weight-bearing toe touching using a crutch is permitted for up to 3 weeks and then increased gradually to 50% of the body weight of the patient until 6 weeks postoperatively. At this point, the patients are permitted to

perform full weight-bearing one-leg squatting exercises, when possible, without the use of crutches or a hinged knee brace. The patients are allowed to swim and cycle at the end of 4 months, go running at the end of 6 months, and play contact sports at the end of 8 months.

Discussion

There are many studies in the literature in which a BMAC injection was used for the treatment of meniscus tears in the knee joint. In an animal experiment model conducted by Duygulu et al.,¹⁵ it was shown that after autologous bone marrow aspiration was applied to full-thickness meniscal tears, healing was accelerated on the macroscopic and microscopic level. In a study conducted by James et al.,¹⁶ BMAC injection was combined with meniscus repair techniques in complete radial meniscal tears, and the healing of the torn meniscus tissue was supported and accelerated. In a study conducted by Pierce et al.,¹⁷ satisfactory results were obtained in terms of clinical scores and functional results in the 6-month follow-up results after BMAC injection had been applied to the lateral capsular meniscus tear in a cross-country runner.

Complex surgical planning and additional biological solutions to accelerate healing are required in the presence of intra-articular problems in MAT.¹⁸⁻¹⁹ In the

Table 1. Steps and Pearls

Steps	Pearls
Preparation of the donor area	Trimming of the posterior horn is performed, as well as that of the body of the native meniscus remnants, to supply a fresh bleeding surface located within 1–2 mm of the peripheral rim where the meniscal allograft will be placed. For the graft passage a mini-lateral parapatellar arthrotomy is used to facilitate the graft passage and open the suture fixation of the anterior aspect of the meniscal allograft.
Meniscus transplantation	A bone bridge that is 7 mm wide and 10 mm deep and connected the anterior and posterior horn attachments is created using a cutting block guide and sagittal saw. Combining this gentle tension on the sutures in the graft passage, in addition to the varus stress on the knee, as well as the digital pressure applied by the surgeon via the arthrotomy will all aid in reducing the lateral meniscus allograft into the lateral compartment. Once the meniscus allograft is securely in position, it is then peripherally fixed using multiple inside-out vertical mattress sutures, via 2-0 nonabsorbable sutures, wherein the needles are captured using the posterolateral approach. Suturing is performed on the inferior and superior surfaces of the allograft in order to ensure balanced repair while the meniscus is in the anatomic position.
BMAC application	2 mL of BMAC is injected into the periphery of the meniscus allograft, allowing it to reach the inside of the tissue Any remaining fluids remaining in the joint as a result of the arthroscopic procedure are aspirated prior to the intra-articular injection, thus creating a dry area. The injection of the BMAC is then performed using a syringe and needle, under arthroscopic control, into the anterior, middle, and posterior areas of the meniscus allograft and capsulo-meniscal junction, as well as under the bone block where the allograft has been placed in the tibial groove. The remaining BMAC is then injected into the joint so as to improve the healing response.

BMAC, bone marrow aspirate concentrate.

technique presented in the current study, BMAC injection was combined with LMAT in patients who underwent meniscectomy and significant improvement was achieved in the early period in the clinical scores and pain levels of the patients, which supported the literature. In addition, it should be kept in mind that the histological improvement in the allograft will be accelerated by a BMAC injection, as was reported in the literature.²⁰⁻²¹

Extrusion is one of the main problems experienced after MAT applications. Current studies have shown that extrusions of 3 mm or more cause degradation in the intra-articular load distribution and then prearthritic pathological consequences develop. However, although the reasons for the meniscus extrusion after

MAT remain unclear, there has been no consensus in the literature on what values will be considered normal.²²⁻²⁴

Even though it has been indicated in the literature that graft extrusion may be the result of the surgical technique, especially in a situation in which the anterior and posterior horn positions in the transplanted meniscus were determined incorrectly, the obvious surgical technique errors have not always been determined in the event that extrusion occurs following MAT.²⁵ In their study of 23 patients with repetitive MRI, Lee et al. emphasized that the first 6 weeks after MAT were very important, and they showed that extrusions during this period did not regress during the 1-year follow-up.²⁶

Table 2. Advantages and Limitations of Lateral Meniscus Allograft Transplantation in Combination with Bone Marrow Aspirate Concentrate Injection

Advantages	Limitations
Technically easy to perform	Centrifugation of bone marrow aspirate causes decreased cellular activity with operation time
One-stage operation without any culture expansion	Erythrocytes may have adverse effects when used intra-articularly
Cellularization of the allograft	Variations in stem cell quality and number with age
Accelerated healing and decreased risk for extrusion	No significant clinical studies on effectiveness
Low infection risk	

In another study, Lee et al. followed up with 43 patients in whom they performed MAT for an average of 5 years and found an extrusion of more than 3 mm in 40% of the patients.²⁷ However, at the end of 5 years of follow-up, they concluded that although there was a moderate narrowing in the joint spaces of the patients, extrusion did not have a significant effect on clinical and radiological results.²⁷ In a literature review conducted in 2018, 21 studies investigating extrusion in MAT cases with bone block fixation were evaluated, and it was reported that the average extrusion was 3.2 mm and more than half of the patients had >3 mm extrusion.²⁵

In lateral MAT, it is thought that better meniscocapsular healing and lower extrusion rates can be obtained with BMAC injection in addition to the surgical technique. In addition, it can be inferred that the low extrusion rates support the functional clinical outcomes of the patients. By comparing cases performed with and without BMAC injection, in future clinical studies using this technique, the existence of the advantages mentioned earlier can be better evaluated (Table 1).

Recently, loss of meniscal tissue due to previous meniscectomy surgery in young/middle-aged patients has caused cartilage damage and chronic pain complaints in the knee joints in the mid–long term.²⁸ Successful results with MAT in these patient groups have been frequently obtained, according to the literature.²⁹⁻³⁰ However, these methods should be combined with additional procedures that support healing in order to reduce the problems experienced by patients during long recovery periods and while returning to sports. It is thought that with BMAC injection combined with LMAT in this technique, recovery times will be accelerated, significant improvement will be achieved in clinical functions, and a rapid decrease in pain levels will occur in the short and medium term. The concomitant use of meniscus transplantation and BMAC, which are both considered biological treatments, would be beneficial in clinical practices (Table 2). In this respect, MAT combined with BMAC injection can be regarded as a promising treatment method.

References

- Packer JD, Rodeo SA. Meniscal allograft transplantation. *Clin Sports Med* 2009;28:259-283.
- Peters G, Wirth CJ. The current state of meniscal allograft transplantation and replacement. *Knee* 2003;10:19-31.
- Hutchinson ID, Moran CJ, Potter HG, Warren RF, Rodeo SA. Restoration of the meniscus: Form and function. *Am J Sports Med* 2014;42:987-998.
- Vundelinckx B, Vanlauwe J, Bellemans J. Long-term subjective, clinical, and radiographic outcome evaluation of meniscal allograft transplantation in the knee. *Am J Sports Med* 2014;42:1592-1599.
- Smith NA, MacKay N, Costa M, Spalding T. Meniscal allograft transplantation in a symptomatic meniscal deficient knee: a systematic review. *Knee Surg Sports Traumatol Arthrosc* 2015;23:270-279.
- Bin SI, Nha KW, Cheong JY, Shin YS. Midterm and long-term results of medial versus lateral meniscal allograft transplantation: A meta-analysis. *Am J Sports Med* 2018;46:1243-1250.
- Hommen JP, Applegate GR, Del Pizzo W. Meniscus allograft transplantation: Ten-year results of cryopreserved allografts. *Arthroscopy* 2007;23:388-393.
- Noyes FR, Barber-Westin SD. Long-term survivorship and function of meniscus transplantation. *Am J Sports Med* 2016;44:2330-2338.
- Novaretti JV, Patel NK, Lian J, et al. Long-term survival analysis and outcomes of meniscal allograft transplantation with minimum 10-year follow-up: A systematic review. *Arthroscopy* 2019;35:659-667.
- McCormick F, Harris JD, Abrams GD, et al. Survival and reoperation rates after meniscal allograft transplantation: Analysis of failures for 172 consecutive transplants at a minimum 2-year follow-up. *Am J Sports Med* 2014;42:892-897.
- Salamanna F, Contartese D, Nicoli Aldini N, et al. Bone marrow aspirate clot: A technical complication or a smart approach for musculoskeletal tissue regeneration? *J Cell Physiol* 2018;233:2723-2732.
- Gianakos AL, Sun L, Patel JN, Adams DM, Liporace FA. Clinical application of concentrated bone marrow aspirate in orthopaedics: A systematic review. *World J Orthop* 2017;8:491-506.
- Benthien JP, Behrens P. Reviewing subchondral cartilage surgery: considerations for standardised and outcome predictable cartilage remodelling: A technical note. *Int Orthop* 2013;37:2139-2145.
- Gobbi A, Whyte GP. One-stage cartilage repair using a hyaluronic acid-based scaffold with activated bone marrow-derived mesenchymal stem cells compared with microfracture: Five-year follow-up. *Am J Sports Med* 2016;44:2846-2854.
- Duygulu F, Demirel M, Atalan G, et al. Effects of intra-articular administration of autologous bone marrow aspirate on healing of full-thickness meniscal tear: An experimental study on sheep. *Acta Orthop Traumatol Turc* 2012;46:61-67.
- James EW, LaPrade CM, Feagin JA, LaPrade RF. Repair of a complete radial tear in the midbody of the medial meniscus using a novel crisscross suture transtibial tunnel surgical technique: A case report. *Knee Surg Sports Traumatol Arthrosc* 2015;23:2750-2755.
- Pierce TP, Wagner C, McInerney VK, Festa A, Scillia AJ. Lateral capsular meniscal tear in a cross-country runner. *Orthopedics* 2016;39:e1201-e1204.
- Bozkurt M, Tahta M, Akkaya M, Isik C, Gursoy S. Good clinical results can be obtained along with reduced risk of tunnel communication with a new technique in concomitant meniscus transplantation and ACL reconstruction. *Knee Surg Sports Traumatol Arthrosc* 2018;26:622-627.
- Samitier G, Alentorn-Geli E, Taylor DC, et al. Meniscal allograft transplantation. Part 2: Systematic review of

- transplant timing, outcomes, return to competition, associated procedures, and prevention of osteoarthritis. *Knee Surg Sports Traumatol Arthrosc* 2015;23:323-333.
20. Koch M, Hammer S, Fuellerer J, et al. Bone marrow aspirate concentrate for the treatment of avascular meniscus tears in a one-step procedure-evaluation of an in vivo model. *Int J Mol Sci* 2019;20:1120.
 21. Yu H, Adesida AB, Jomha NM. Meniscus repair using mesenchymal stem cells—A comprehensive review. *Stem Cell Res Ther* 2015;6:86.
 22. Costa CR, Morrison WB, Carrino JA. Medial meniscus extrusion on knee MRI: Is extent associated with severity of degeneration or type of tear? *Am J Roentgenol* 2004;183:17-23.
 23. Choi CJ, Choi YJ, Lee JJ, Choi CH. Magnetic resonance imaging evidence of meniscal extrusion in medial meniscus posterior root tear. *Arthroscopy* 2010;26:1602-1606.
 24. Gale DR, Chaisson CE, Totterman SM, Schwartz RK, Gale ME, Felson D. Meniscal subluxation: Association with osteoarthritis and joint space narrowing. *Osteoarthritis Cartilage* 1999;7:526-532.
 25. Lee DH. Incidence and extent of graft extrusion following meniscus allograft transplantation. *Biomed Res Int* 2018;25:5251910.
 26. Lee DH, Kim TH, Lee SH, Kim CW, Kim JM, Bin SI. Evaluation of meniscus allograft transplantation with serial magnetic resonance imaging during the first postoperative year: Focus on graft extrusion. *Arthroscopy* 2008;24:1115-1121.
 27. Lee DH, Kim SB, Kim TH, Cha EJ, Bin SI. Midterm outcomes after meniscal allograft transplantation: Comparison of cases with extrusion versus without extrusion. *Am J Sports Med* 2010;38:247-254.
 28. Koukoulas N, Papastergiou S, Kazakos K, Poullos G, Parisis K. Mid-term clinical results of medial meniscus repair with the meniscus arrow in the unstable knee. *Knee Surg Sports Traumatol Arthrosc* 2007;15:138-143.
 29. Kim JM, Bin SI, Lee BS, et al. Long-term survival analysis of meniscus allograft transplantation with bone fixation. *Arthroscopy* 2017;33:387-393.
 30. Cavendish PA, DiBartola AC, Everhart JS, Kuzma S, Kim WJ, Flanigan DC. Meniscal allograft transplantation: A review of indications, techniques, and outcomes. *Knee Surg Sports Traumatol Arthrosc* 2020;28:3539-3550.