CASE REPORT – OPEN ACCESS

International Journal of Surgery Case Reports 41 (2017) 26–29

Contents lists available at ScienceDirect

International Journal of Surgery Case Reports

journal homepage: www.casereports.com

An unusual case of transpelvic impalement injury: A case-report

Mushrek Alani[a], Saeed Mahmood[a], Ayman El-Menyar[b,c,*], Sajid Atique[a], Hassan Al-Thani[a], Ruben Peralta[a]

[a] Department of Surgery, Trauma Surgery, Hamad General Hospital, Doha, Qatar
[b] Clinical Medicine, Weill Cornell Medical College, Doha, Qatar
[c] Clinical Research, Trauma Section, Hamad General Hospital, Doha, Qatar

ARTICLE INFO

Article history:
Received 6 August 2017
Received in revised form 16 August 2017
Accepted 16 August 2017
Available online 5 October 2017

Keywords:
Impalement injuries
Transpelvic
Trauma
Surgery

ABSTRACT

INTRODUCTION: Impalement injury is a rare type of mechanical injury following forceful insertion of projecting object into the body. Careful planning for removal of the impaling object is essential to decrease the blood loss and preserve the function of the injured organ.
PRESENTATION OF CASE: A 27 year-old male fell from 4 m height over a U shaped projecting up metallic bar. The bar penetrated the left side of the pelvis and traversed through the left iliac bone causing a comminuted fracture in the supra-acetabular region extending to the left psoas muscle, injuring the viscera and causing fracture of the right femur. Exploratory laparotomy was performed and the metallic bar was pulled out from the sigmoid colon through the inlet of the injury. Intramedullary nailing was performed for femur fracture. The patient developed infection (Methicillin-sensitive Staphylococcus aureus and Escherichia coli) during the post-operative course that was successfully managed with antibiotic therapy. Finally the patient was sent home after a week in a good health condition.
DISCUSSION: Two surgical teams worked in sequence to fix the injuries starting with the trauma team followed by the orthopedic surgeons.
CONCLUSION: Impalement injury is a serious injury that needs a multidisciplinary team with a coordinated approach to achieve a favorable outcome.

1. Introduction

Impalement injury is a rare type of mechanical injury following forceful insertion of a projecting object into the body [1]. This injury is typically accidental but few are homicidal [1]. Management of Impalement injury poses a major challenge [2]. It is widely agreed that the impaling object should be left in situ until the initiation of management at a tertiary trauma center [3]. Careful planning for removal of the impaling object is crucial to minimize blood loss and preserve the involved organ function. However, time is important when evaluating and resuscitating such patients [4]. Herein, we present a case of transpelvic impalement injury. This work has been reported in line with the SCARE criteria [5].

2. Presentation of case

A 27 year-old male fell from 4 m height over a U shaped projecting up metallic bar. The bar penetrated the left side of the pelvis with trajectory toward the right femur through the pelvic cavity (Fig. 1). The bystanders lifted the patient from the site of injury with the impaling metallic bar in place. When the EMS arrived the scene, the patient was hemodynamically stable but in severe pain. Evaluation and stabilization of the deformed right lower extremity was done by the EMS staff. The patient was transported to the tertiary hospital within 75 min. On arrival, the patient airway was patent with bilateral good air entry, blood pressure (BP) 110/70, pulse rate (PR) 98, respiratory rate (RR) 12, temperature 36.9 °C, oxygen saturation 99% on room air, and Glasgow coma scale (GCS) of 15.

The impaling U shape metallic bar was found penetrating the left side of the pelvis without active external bleeding. Initial evaluation and management was provided to the patient upon arrival to the Trauma Resuscitation Unit (TRU) as per Advanced Trauma Life Support (ATLS) protocol. A Focused Assessment Sonography for trauma (FAST) was inconclusive. Deformity of the right thigh was appreciated and distal pulses were intact. Rectal examination was negative for blood, masses or foreign body. Prophylactic antibiotic and tetanus toxoid were given. Pelvic and abdominal X-ray assessment showed fracture of the right femur (Fig. 2A & B). The protruded metal bar was cut using heavy metal cutter.

* Corresponding author at: Clinical Research, Trauma and Vascular Surgery, Hamad General Hospital, PO Box 3050, Doha, Qatar.
E-mail address: aymanco65@yahoo.com (A. El-Menyar).

https://doi.org/10.1016/j.ijscr.2017.08.068

Fig. 1. The impaling U shape metallic bar penetrated the left side of the pelvis.

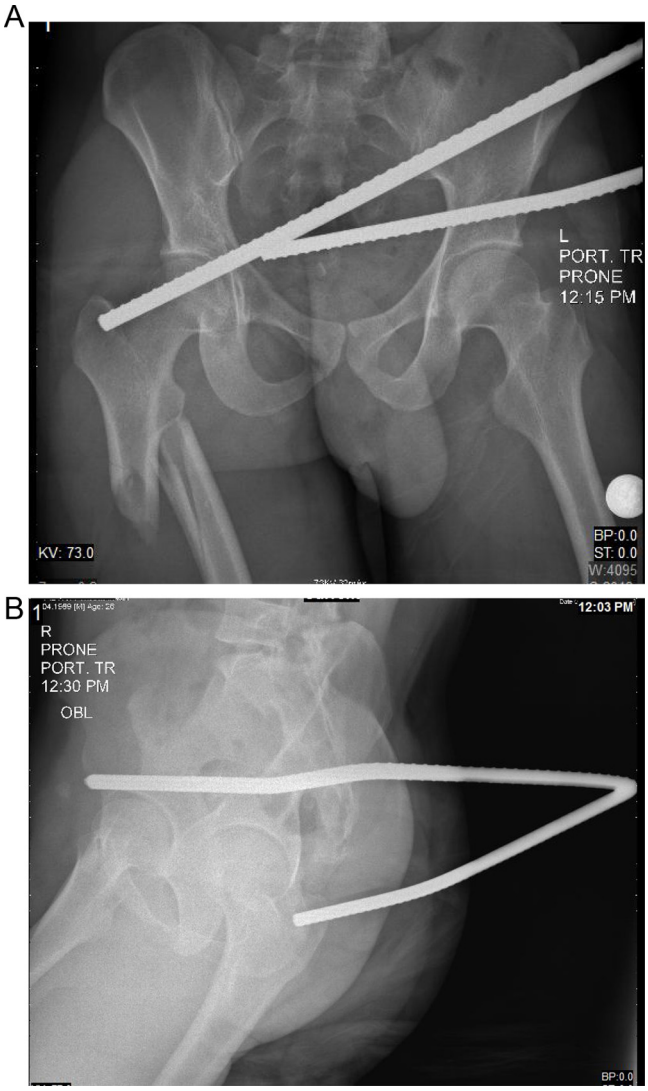

Fig. 2. (A) Anteroposterior view X-ray in the Trauma Resuscitation unit showing the U shape metallic bar with the right femur fracture. (B) Lateral view X-ray in the Trauma resuscitation unit showing the relation of the metallic bar to the pelvic cavity.

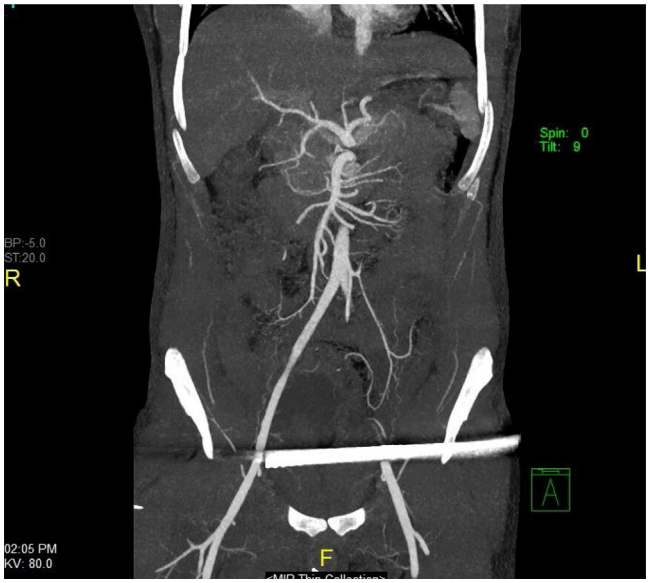

Fig. 3. The computerized tomography (CT) scan of abdomen and pelvis demonstrating the anatomy and the injuries related to the impalement.

Fig. 4. The impaling metallic bar passing through the sigmoid colon.

Computerized tomography (CT) scan of abdomen and pelvis showed that the metallic bar entered from the left side of the pelvis but no exit site was appreciated (Fig. 3). The bar passed through the left iliac bone causing a comminuted fracture in the supra-acetabular region with overlying hematoma and surgical emphysema in the soft tissue extending to the left psoas muscle. It passed through the junction between the descending and the sigmoid colon with extravasation of the rectally administered contrast. Large amount of free air was found in the upper part of the abdomen.

The bar traversed the soft tissue behind the rectus muscle with an evidence of soft tissue contusions. Small metal density fragment was noted anterior to the lower part of the right rectus muscle measuring 4×9 mm. The patient was transferred to the operating room for an exploratory laparotomy and removal of the metallic bar. The metallic bar was pulled out under vision, through injury of the sigmoid colon with minimal contamination (Fig. 4). Repair of the sigmoid colon was performed in two layers with 3–0 Vicryl (absorbable) sutures (Fig. 5). Thorough irrigation was performed after a systematic exploration of the abdomen.

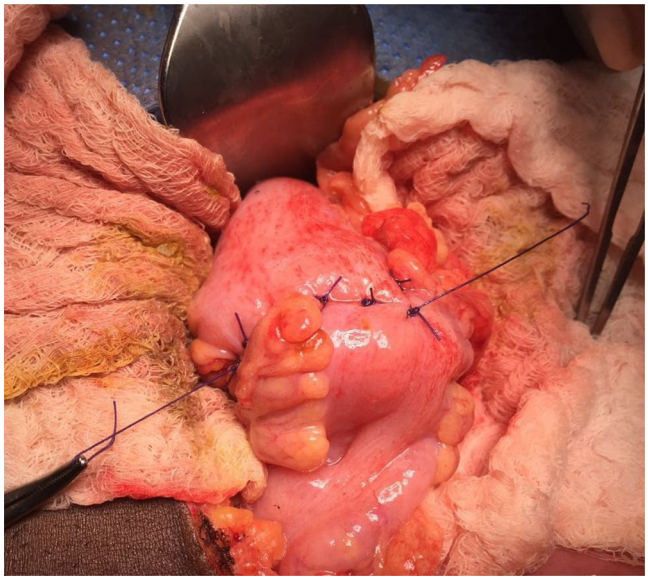

Fig. 5. Suturing of the perforation sites in the sigmoid colon.

Abdomen was closed and the orthopedic team started intramedullary nailing for the fractured femur. On day 4, the patient developed fever, tachycardia, tachypnea, desaturation and low white blood cells (WBC) count. The patient was intubated and admitted to the Intensive care unit (ICU). Broad spectrum antibiotic was started and chest and abdominal CT scan was done to rule out pulmonary embolism, intra-abdominal collection or anastomosis leak. The CT scan result was unremarkable. The blood culture proved methicillin sensitive staphylococcus aureus bacteremia. The patient condition improved and he was extubated after two days; and transferred back to the ward after three days. Four days later in the ward, the patient developed abdominal wound infection with pus collection that was drained and sent to bacteriology testing. Culture result was positive for Escherichia Coli. Antibiotic was changed according to the sensitivity result. The wound was managed and closed within a week. The patient was discharged home in a good health condition.

3. Discussion

Impalement injuries commonly occur as a result of impact between the human body and an immobile object. The typical mechanisms of these injuries are accidental falls, or motor vehicle collisions in which a protruding object involved, or ejection from automobiles and falling on a protruding object [6]. In our case, the patient fell from 4 m height on a U shaped protruding metallic bar in a construction site. The bar penetrated the left side of the pelvis of the patient.

Impalement pelvic injury traversing the pelvic cavity from one side to the other is rare. The impaling object in our case traversed from the left side of the pelvis through the left iliac bone causing a comminuted fracture in the supra-acetabular region with overlying hematoma and surgical emphysema in the soft tissue extending to the left psoas muscle. There was a significant soft tissue injury added to the large bowel and bone injuries accompanied with severe inevitable contamination of the crushed tissues by the impaling dirty and rusty metallic bar. The bystanders and EMS kept the impaling object in place which is the best practice for any impalement injury as this will continuously compress the bleeding source, or leaking bowel. The hemodynamically stable condition of the patient gave us an opportunity to perform the imaging studies on a reasonable time which facilitated the surgical approach for such complicated type of injury.

Two surgical teams worked in sequence to fix the injuries starting with the trauma team followed by the orthopedic surgeons in addition to the radiology and intensive care teams. The patient received the appropriate surgical management. However, septicemia developed on the fourth post-operative day due to soft tissue infection. Neither anastomosis leak nor abdominal collection was discovered by the follow up CT scan. The crushed soft tissue by the contaminated impaling object is a serious source of infection which should be considered in any type of impalement injury and suitable measures should be taken accordingly. In our patient, bacteremia was caused by methicillin sensitive staphylococcus aureus which proved not to be from the bowel leak or from injury as post-operative CT abdomen did not show any lesions inside the peritoneal cavity.

4. Conclusion

Impalement injury is a serious complicated injury that needs a multidisciplinary team with coordinated approach and early imaging studies to facilitate the appropriate management and achieve a favorable outcome.

Conflicts of interest

None.

Funding

None.

Ethical approval

This case report was approved with a waiver of informed consent by the ethical committee at Medical Research Center (IRB#17062/17) at Hamad Medical Corporation, Doha, Qatar.

Consent

As data were collected retrospectively and anonymously, this case report was granted a waiver of informed consent by the ethical committee.

Author contribution

Mushrek Alani, Saeed Mahmood, Sajid Atique, Ruben Peralta and Hassan Al-Thani : study concept or design, data collection, data analysis or interpretation, writing the paper.

Ayman El-Menyar: study concept or design, data interpretation, writing the paper.

Guarantor

Mushrek Alani.

Acknowledgements

The authors thank all the trauma surgery staff for their cooperation. All authors read and approved the case report.

References

[1] J. Yadav, D.S. Badkur, An unusual case of impalement injury, Med. Sci. Law 56 (3) (2016) 213–216.

[2] R. Mohan, D.U. Ram, Y.S. Baba, A. Shetty, S. Bhandary, Transabdominal impalement: absence of visceral or vascular injury a rare possibility, J. Emerg. Med. 41 (5) (2011) 495–498.
[3] S. Angelopoulos, I. Mantzoros, D. Kyziridis, A. Fontalis, S. Parpoudi, D. Konstandaras, C. Tsalis, A rare case of a transabdominal impalement after a fall from a ladder, Int. J. Surg. Case Rep. 22 (2016) 40–43.
[4] T. Kanemura, T. Hifumi, I. Okada, N. Kiriu, T. Ogasawara, E. Hasegawa, H. Kato, Y. Koido, J. Inoue, Management of a gluteal region impalement injury caused by three reinforced aluminum bars: a case report, J. Med. Case Rep. 7 (2013) 295.
[5] R.A. Agha, A.J. Fowler, A. Saetta, I. Barai, S. Rajmohan, D.P. Orgill, The SCARE Group, The SCARE Statement: consensus-based surgical case report guidelines, Int. J. Surg. 34 (2016) 180–186.
[6] F. Edwin, M. Tettey, L. Sereboe, E. Aniteye, D. Kotei, M. Tamatey, K. Entsuamensah, I. Delia, K. Frimpong-Boateng, Impalement injuries of the chest, Ghana Med. J. 43 (2) (2009) 86–89.