

# Videolaryngoscopic versus direct laryngoscopic paraglossal intubation for cleft lip/palate reconstructive surgeries: A randomised controlled trial

## Address for correspondence:

Dr. Indu Mohini Sen,  
Department of Anaesthesia  
and Intensive Care,  
Postgraduate Institute of  
Medical Education and  
Research, Chandigarh, India.  
E-mail: indumohini@gmail.com

**Ananya Ray, Indu Mohini Sen, Neerja Bhardwaj, Sandhya Yaddanapudi, Preethy Mathews**

Department of Anaesthesia and Intensive care, Postgraduate Institute of Medical Education and Research, Chandigarh, India

## ABSTRACT

**Submitted:** 27-May-2021  
**Revised:** 09-Aug-2021  
**Accepted:** 11-Aug-2021  
**Published:** 25-Aug-2021

**Background and Aims:** In the cleft lip and palate, the laryngoscope blade often tends to lodge inside midline clefts, causing reduced manoeuvrability and tissue trauma. The paraglossal technique avoids the midline and offers better Cormack Lehane (CL) grades. We aimed to assess the first-pass intubation rate in performing the left paraglossal laryngoscopy with a curved-blade videolaryngoscope (VLS) versus direct laryngoscope (DLS) in children with cleft palate and evaluate the time taken for successful endotracheal intubation (TTI) and Intubation Difficulty Score (IDS) with both devices. **Methods:** This randomised controlled trial included 60 patients with cleft palate, between 3 months and 6 years. Patients were randomised into group V (VLS) (n = 30) and group D (DLS) (n = 30). Left paraglossal laryngoscopy was done with VLS or DLS, and the first-pass intubation, TTI, CL grade and IDS were recorded. **Results:** First-pass intubation (primary outcome) was successful in all cases in group V and in 29 (96%) cases in group D ( $P = 0.923$ ). Amongst the secondary outcomes, the IDS of the majority in both groups was 1–4 (slight difficulty) ( $P = 0.98$ ) and the mean TTI in group D was 34.6 s (SD = 19.0) (95% CI: 27.5–41.7) versus 39.8 s (SD = 5.2) (95% CI: 37.8–41.7) in group V ( $P = 0.151$ ). **Conclusions:** There was no significant difference in the use of a VLS over a DLS in performing the left paraglossal laryngoscopy in terms of first-pass intubation rate, CL Grade, IDS and TTI. Further studies with different VLS may be done to improve the ease of this technique.

**Key words:** Airway management, cleft lip, cleft palate, intubation, laryngoscope, laryngoscopy

## Access this article online

Website: [www.ijaweb.org](http://www.ijaweb.org)

DOI: 10.4103/ija.ija\_463\_21

Quick response code



## INTRODUCTION

Cleft lip and cleft palate (CP) are congenital anomalies that result from the failure of fusion of the frontonasal and palatine processes of the maxillae. In India, the burden of non-syndromic CP is estimated at 9.1 per 10,000 live births.<sup>[1]</sup> The abnormal airway anatomy resulting from the defect and associated retrognathia and micrognathia can lead to difficult laryngoscopy and intubation. Particularly in bilateral CP, the laryngoscope blade has a tendency to lodge inside the cleft which may lead to tissue trauma.<sup>[2]</sup>

The paraglossal (or molar) approach to laryngoscopy has been reported to be of benefit in improving glottic views and in cases where the midline is to be avoided.<sup>[3-6]</sup> However, this technique entails a

learning curve. In recent years, videolaryngoscopes (VLSs) have been used to improve the visualisation of glottic structures. Studies have concluded that the VLS decreases the number of intubation attempts and leads to higher success rates.<sup>[7]</sup> These have also been used successfully in CP cases using the standard midline laryngoscopy technique.<sup>[8]</sup> We, therefore, put

This is an open access journal, and articles are distributed under the terms of the Creative Commons Attribution-NonCommercial-ShareAlike 4.0 License, which allows others to remix, tweak, and build upon the work non-commercially, as long as appropriate credit is given and the new creations are licensed under the identical terms.

**For reprints contact:** WKHLRPMedknow\_reprints@wolterskluwer.com

**How to cite this article:** Ray A, Sen IM, Bhardwaj N, Yaddanapudi S, Mathews P. Videolaryngoscopic versus direct laryngoscopic paraglossal intubation for cleft lip/palate reconstructive surgeries: A randomised controlled trial. *Indian J Anaesth* 2021;65:593-9.

forward the research question of whether performing the left paraglossal intubation using a VLS makes this technique easier to perform. To the best of our knowledge, no literature describes such a study in this setting. Hence, this study was undertaken to evaluate the ease of performing endotracheal intubation by the left paraglossal technique using a VLS over a direct laryngoscope (DLS), in CP cases.

The primary aim was to assess the first-pass intubation rate while performing the left paraglossal laryngoscopy using the VLS versus the DLS in paediatric patients undergoing corrective surgeries for CP. The secondary objectives were to evaluate the time taken for successful endotracheal intubation (TTI) and Intubation Difficulty Score<sup>[9]</sup> (IDS) obtained with the two devices.

## METHODS

This study was a randomised controlled trial undertaken in the plastic surgery operating room of a tertiary care centre between July 2017 and October 2018. With institutional ethics committee approval and registration with Clinical Trials Registry – India (CTRI/2018/01/011321), 60 paediatric in-patients with uncorrected CP in the age of 3 months to 6 years, posted for elective reconstruction surgery were included. The exclusion criteria were as follows: parents/guardians who did not give consent, patients in whom bag and mask ventilation was difficult post-induction, patients with supraglottic mass lesions, haemodynamic instability pre-operatively, recent upper respiratory tract infections and coagulation disorders.

Pre-anaesthetic evaluation was done for all patients enrolled. Informed consent was obtained from the parents/guardians. Standard fasting guidelines were followed. Patients were orally premedicated with midazolam 0.5 mg/kg mixed with honey, 30 min prior to surgery.

Block randomisation was done in a 1:1 ratio in blocks of four patients each by using a random number sequence. Allocation concealment was done using serially numbered, opaque, sealed envelopes into group V (n = 30) (VLS group) and group D (n = 30) (direct laryngoscope/DLS group).

Standard American Society of Anesthesiologists monitors were attached—pulse-oximeter, electrocardiogram and non-invasive blood pressure cuff. The temperature probe, capnometer and gas

sampling line were connected after induction and intubation. Induction of anaesthesia was done with sevoflurane and oxygen or intravenous propofol, at the discretion of the primary anaesthesiologist. Analgesia was provided with intravenous fentanyl 1 µg/kg. Muscle relaxation was achieved with atracurium 0.5 mg/kg. Bag and mask ventilation during apnoea was then performed for 3 min. The patient was maintained in sniffing position (external auditory meatus aligned with the sternal notch). After ensuring oxygen saturation of >95%, intubation was performed by the left paraglossal technique with either the VLS (VBM Macintosh I-Scope VLS, VBM India Co.) or the Macintosh DLS, as per randomisation, with blade size 1 or 2, as appropriate. Left paraglossal laryngoscopy was performed by introducing the laryngoscope blade from the left angle of mouth and directing it towards the epiglottis, between the tongue and the tonsillar fossa. After lodging the tip of the blade at the base of the epiglottis, an anterolateral force was applied to lift the epiglottis and bring the glottis into view. The primary investigator performed all the intubations. When required, optimum external laryngeal manipulation (OELM) was applied by a trained assistant at the instruction of the intubator. Confirmation of successful intubation was done by auscultation of breath sounds and capnography. The first-pass intubation (successful intubation on the first attempt), TTI (calculated as the time taken from removal of the facemask to confirmation of correct tube placement), Cormack Lehane (CL) grade and Intubation Difficulty Score (IDS)<sup>[9]</sup> were recorded. The CL grade is based on the glottic view obtained during laryngoscopy. The laryngoscopy was further classified as 'easy' if CL grade was 1 or 2a and as 'difficult' for CL grades 2b and 3. The IDS is a numerical scoring system based on parameters that predict difficult intubation and techniques used to ease intubation.

In the event of failure to intubate in the first attempt, either due to inability to negotiate the ETT or accidental oesophageal intubation, a second attempt was taken with the same approach with modifications in position (such as lifting the child's shoulders) or blade size (as appropriate) by using the same laryngoscope. The intervention was stopped, and conventional intubation was performed with the same laryngoscope if the number of attempts exceeded two. Intra-operative complications such as airway trauma during intubation, desaturation (SpO<sub>2</sub> < 92%), tube displacement, accidental extubation and haemodynamic instability were recorded. Extubation

was performed after thorough but gentle oral suctioning, in a light plane of anaesthesia after return of airway reflexes. Post-extubation laryngospasm and bronchospasm were also noted.

The patients were continuously monitored in the post-operative period and post-operative complications such as laryngospasm, desaturation ( $SpO_2 < 92\%$ ), bradycardia (heart rate  $\leq 60/\text{min}$ ), bleeding and aspiration were documented.

The sample size was estimated using a previous study by Yamamoto *et al.*<sup>[10]</sup> in which the authors showed a 65% reduction in difficult laryngoscopy using the left paraglossal approach. We hypothesised a further 30% reduction in the incidence of difficult laryngoscopy by performing the same with a VLS, thereby obtaining a sample size of 54 for an alpha error of 0.05 and power of 80%. Assuming possible dropouts or protocol violations, we planned to take 60 patients who were further block randomised into 15 groups of 4 each.

International Business Machines Statistical Package for the Social Sciences (SPSS Statistics) version 24 was used for statistical analysis. The demographics and TTI were summarised as frequencies and percentages. The first-pass intubation rate, CL grade and the IDS were compared by Chi-square test or Fisher's Exact test wherever appropriate.  $P < 0.05$  was considered statistically significant.

## RESULTS

A total of 69 patients were assessed for eligibility of whom nine were excluded before randomisation. There were no exclusions after randomisation. Finally, 60 patients were randomised [Figure 1]. The demographic characteristics of the groups were similar [Table 1].

The primary outcome, i.e., first-pass intubation was successful in 59 of 60 cases. This included all cases in group V and 29 (96%) cases in group D ( $P = 0.923$ ).

Overall, most patients had CL grade 2a (48.3%). The younger age groups had higher CL grades (Grade 2b and 3). CL grade 3 was obtained in only one patient, one year of age. The CL grades between both groups of CP were comparable ( $P = 0.599$ ).

In group D, 29 patients had an easy laryngoscopy. In group V, 25 patients had an easy laryngoscopy ( $P = 0.097$ ) [Table 2].

In group D, difficult laryngoscopy [Table 2] was encountered in only one patient (3.3%) who had CL grade 3, while in group V, difficult laryngoscopy was present in 5 patients (16.7%), all with CL grade 2b.

The patient having CL grade 3 was a one-year-old male child with micrognathia. On attempting the left paraglossal approach with a DLS, the CL grade obtained was 3 even after OELM as the tongue could not be displaced well within the oral cavity, leaving little space to obtain an adequate view and manoeuvre the ETT. The passage of the ETT was not attempted. Hence, following a second attempt that yielded similar results, a change of technique to conventional midline approach was employed with the same scope and a CL grade 2b was obtained after OELM and the patient was intubated.

Among the secondary outcomes, the IDS in both groups were comparable ( $P = 0.98$ ). In the DLS group, only one patient had an IDS of  $\geq 5$ , i.e., moderate to major difficulty [Table 3].

The IDS parameter most applied was OELM (9 patients in group V and 11 in group D), 1 required extra lifting

**Table 1: Demographic characteristics between the two groups**

	DLS (n=30)	VLS (n=30)	
Males:Females	20:10	16:14	
Age (months)	17.8±12.6	23.9±20.8	$P=0.174^{\#}$
Age Groups			
3 mo–1 yr	17	18	$P=0.002^*$
1 yr–3 yr	12	3	
3 yr–6yr	1	9	
Weight (kg)	8.1±2.3	8.2±2.5	$P=0.974^{\#}$
Type of Cleft <sup>§</sup>			
Palate Group 2	17	16	$P=1.00^{\#}$
Lip + palate Group 3	13	14	

DLS: Direct Laryngoscope, VLS: Videolaryngoscope \*Fisher's Exact test, <sup>#</sup>Student's t-test, <sup>§</sup>Chi-square test <sup>§</sup>Indian classification proposed by Balakrishnan<sup>[11]</sup> Categorical values expressed as frequencies, continuous variables expressed as mean±SD

**Table 2: CL grades observed between the DLS and VLS groups**

	CL Grade 1	CL Grade 2a	CL Grade 2b	CL Grade 3
DLS	12	17	0	1
VLS	13	12	5	0
	<b>Easy Laryngoscopy (Grade 1 and 2a)</b>		<b>Difficult Laryngoscopy (Grade 2b)</b>	
DLS	29 (96.6%)		1 (3.3%)	
VLS	25 (83.3%)		5 (16.7%)	

CL Grade: Cormack Lehane Grade, DLS: Direct Laryngoscope, VLS: Videolaryngoscope No significant difference in the CL grades observed in the two groups ( $P=0.097$  by Fisher's Exact test). Values are expressed as frequencies and percentages

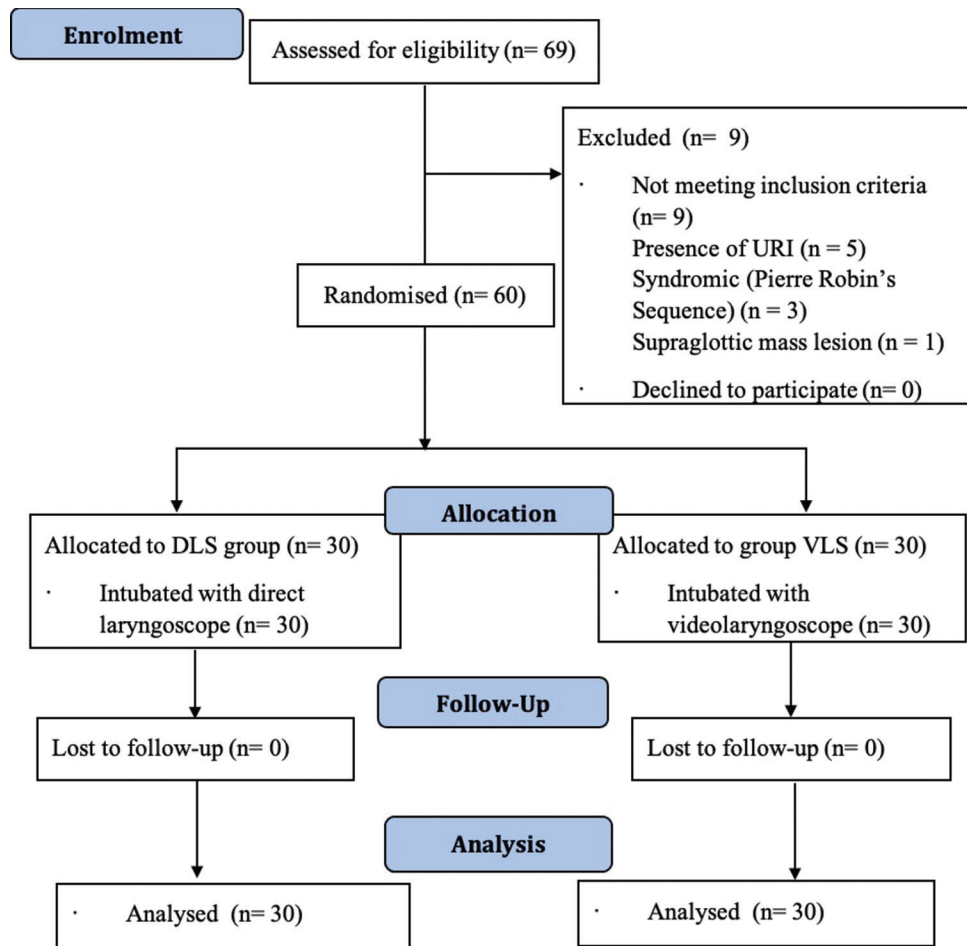


Figure 1: CONSORT flow diagram showing phases of the RCT.

**Table 3: IDS in the DLS and VLS groups**

IDS	DLS	VLS	P=0.98*
0 (easy)	12	12	
1-4 (slightly difficult)	17	18	
≥5 (moderate to major difficulty)	1	0	

IDS: Intubation Difficulty Score, DLS: Direct Laryngoscope, VLS: Videolaryngoscope. The IDS scores comparable between the DLS and VLS groups (P=0.98). \*Fisher's Exact test Values are expressed as frequencies

force and another required change of technique and had a high CL grade [Figure 2].

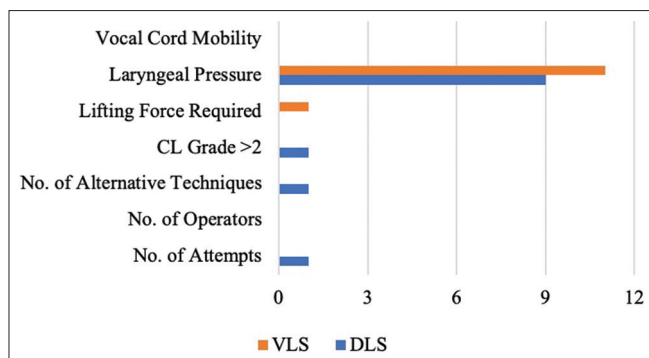
Overall, the mean time taken to intubate was 37.2 s [standard deviation (SD) =14.072] [95% confidence interval (CI): 33.4–40.8]. In group D, the mean TTI was 34.6 s (SD = 19.0) (95% CI: 27.5–41.7) and in group V was 39.8 s (SD = 5.2) (95% CI: 37.8–41.7) (P = 0.151) [Figure 3].

There were no major complications encountered during the study. One patient required a change of the ETT to a larger size due to a significant leak.

Thirteen patients had laryngospasm at the time of extubation, all of which resolved with a continuous positive airway pressure of 10 cmH<sub>2</sub>O provided with 100% oxygen at a flow of 10 L/min. Of them, 8 belonged to group D and 5 to group V.

## DISCUSSION

Cleft lip/palate corrective surgeries often involve the challenges of securing a paediatric airway with the added disadvantage of associated micrognathia, retrognathia and deficient tissue support.<sup>[12]</sup> The present study was undertaken to evaluate the ease of performing left paraglossal intubation in these patients with a curved-blade VLS over a Macintosh DLS to overcome the learning curve required to perform this technique. The primary outcome was first-pass intubation, which was comparable between the groups. There was also no significant difference in the secondary outcomes, i.e. IDS and TTI between the two groups. This highlights that both devices are comparable when performing this technique. This is



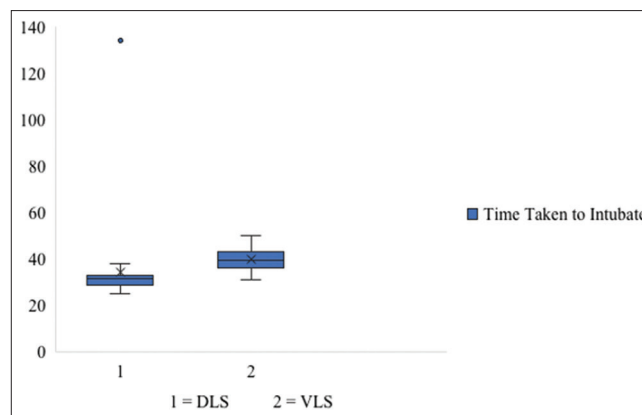
**Figure 2:** Graph showing the IDS parameters used in the two groups. The most commonly used parameter was OELM.

the first randomised study comparing the two devices in performing this technique in CP patients. In our experience, performing this technique in the paediatric population with the VLS required more manipulation of the scope and retraction of the cheek.

Studies on the left paraglossal technique with the curved blade are few and most literature comprise isolated case reports. Our primary outcome was a first-pass attempt, which was successful in all but one patient in DLS group with micrognathia. Similarly, the first-pass attempt has been successful in a majority of patients in previous studies. Sen *et al.*<sup>[4]</sup> reported a second attempt in only two patients, for change of ETT size and not due to failed intubation. Mahmoud *et al.*<sup>[2]</sup> reported the absence of failed intubation but did not mention the requirement of a second attempt. Jindal *et al.*<sup>[13]</sup> succeeded in intubating 86% of patients in the first attempt.

The left paraglossal technique has been shown to provide improved CL grades in patients with CP.<sup>[2,3,4,14]</sup> We found laryngoscopy views of CL grade 1 and 2a in the majority. However, there was no significant difference in the views obtained between the two devices.

The IDS was comparable between the two groups. The majority of the cases had an IDS of 1-2 (slight difficulty). Sen *et al.*<sup>[4]</sup> reported no patient with IDS >1. However, their study sample was small. Mahmoud *et al.*<sup>[2]</sup> used a Likert scale by which 87.5% left paraglossal intubations were graded easy or modest and only 12.5% were graded difficult. This is subjective and varies with the familiarity of the anaesthesiologist with this technique. Jindal *et al.*<sup>[13]</sup> noted that the paraglossal approach significantly reduced the median IDS score, and on the Likert scale, 81.4% right paraglossal intubations were graded easy.



**Figure 3:** Box and whisker plot expressing the time taken to intubate in the two groups.

Of the IDS parameters, the most applied parameter was OELM. This is in agreement with previous studies, which state that OELM improves the glottis CL grade in both right and left molar intubations.<sup>[4,10,15]</sup> However, Jindal *et al.*<sup>[13]</sup> found the IDS parameter most applied was ‘number of attempts’, with 10 of 70 patients requiring two attempts to intubate.

This study found the mean TTI to be 37.18 s, with no significant difference between the two groups. The results provided by Mahmoud *et al.*<sup>[2]</sup> are consistent with this finding—mean intubation time of 37.63 s in the left paraglossal group. However, Sen *et al.*<sup>[4]</sup> reported a mean TTI of 52.4 s while using the Miller DLS. Gupta *et al.*<sup>[15]</sup> reported a mean TTI of 40.4 s while using a Macintosh DLS. Jindal *et al.*<sup>[13]</sup> reported a mean time for intubation of 28 s in their right paraglossal group. This lays the ground for future studies comparing the TTI for different blades.

A note was made of the difficulty in performing the left paraglossal intubation with a DLS in a patient with micrognathia. There was minimal room for negotiating the ETT and manipulating the laryngoscope due to the bulging tongue. We, therefore, feel that in such a case with reduced intra-oral space, this technique with a curved blade may not be the best choice as this technique leaves limited space for manoeuvring the ETT even in normal patients. However, some literature does suggest that the paraglossal technique may improve the glottic view in patients with micrognathia. A case report by Agrawal *et al.*<sup>[16]</sup> states the reason as reduction of soft tissue compression with the use of a straight blade which avoids the problem of the curvature of the blade hindering the line of sight. In the present study, the use of a curved blade may have contributed to the difficulty.

This study holds importance in view of the clinical relevance of the study question. The left paraglossal intubation may be valuable in many cases but requires practice and experience; thus, the notion behind the hypothesis was to reduce its difficulty using a VLS. The prospective and randomised nature of this study reduces selection bias. This study adds evidence to the reliability of using the left molar approach in cases where the midline is to be avoided but shows no benefit of employing the VLS to perform the same.

One limitation of this study may be that the VLS available was designed for insertion over the centre of the tongue without tongue displacement, and the angle required for lifting the epiglottis was more vertical than along the same line of the handle. Therefore, for a technique that requires the displacement of the tongue and an anterolateral lifting force, a VLS like the C-MAC may be better suited.<sup>[17,18]</sup> However, due to non-availability of the C-MAC VLS, the VBM VLS was used for this study. Another limitation may be the more proficient use of the DLS than the VLS by the investigator. One may also contend that a cross-over trial, which can eliminate patient variance, was not conducted. However, considering all our patients were of paediatric age group, it may not be ethical to subject them to two interventions under apnoea.

To the best of our knowledge, there is no large trial comparing the use of the VLS with DLS for this technique. Considering the large variety of VLSs available presently, a similar trial may be undertaken with a larger sample size and various devices and blades to further simplify and improve the paraglossal technique. Further, the reliability of this technique in the setting of difficult airway and midline lesions invites the need for a systematic review in the future.

## CONCLUSION

This randomised controlled trial found no significant difference in the use of a curved-blade VLS over a Macintosh DLS in performing the left paraglossal laryngoscopy in terms of first-pass intubation, CL Grades, IDS and TTI. Further studies with a larger number of patients and different VLSs and blades may be undertaken to evaluate the ease of this technique of intubation.

## Declaration of parental/guardian consent

The authors certify that they have obtained all appropriate patient/guardian consent forms. In the

form, the parent(s)/guardian(s) has/have given his/her/their consent for his/her/their images and other clinical information to be reported in the journal. The patients/guardians understand that their names and initials will not be published and due efforts will be made to conceal their identity, but anonymity cannot be guaranteed.

## Financial support and sponsorship

Nil.

## Conflicts of interest

There are no conflicts of interest.

## REFERENCES

- Banerjee M, Dhakar AS. Epidemiology-clinical profile of cleft lip and palate among children in India and its surgical consideration. *Can J Surg* 2013;2:45-51.
- Mahmoud AA, Fouad AZ, Mansour MA, Kamal AM. A novel intubation technique in bilateral cleft palate pediatric patients: Hard gum shield-aided intubation. *Pediatr Anesth* 2013;23:349-54.
- Xue FS, Zhang GH, Li P, Sun HT, Li CW, Liu KP, et al. The clinical observation of difficult laryngoscopy and difficult intubation in infants with cleft lip and palate. *Pediatr Anaesth* 2006;16:283-9.
- Sen I, Kumar S, Bhardwaj N, Wig J. A left paraglossal approach for oral intubation in children scheduled for bilateral orofacial cleft reconstruction surgery-A prospective observational study. *Pediatr Anaesth* 2009;19:159-63.
- Goel A, Kaur A, Dias R, Shah H. Non-operating room anaesthesia for residual neonatal epignathus: Small pill, big thrill.... *Indian J Anaesth* 2021;65:422-3.
- Archana M, Segaran S, Zachariah M, George SK. Infant with stridor due to vallecular cyst – Anaesthetic management. *Indian J Anaesth* 2021;65:340-2.
- Byhahn C, Iber T, Zacharowski K, Weber CF, Ruesseler M, Schalk R, et al. Tracheal intubation using the mobile C-MAC video laryngoscope or direct laryngoscopy for patients with a simulated difficult airway. *Minerva Anestesiologica* 2010;76:577-83.
- Mutlak H, Unglaube M, Klages M. Videolaryngoscopic intubation conditions in children with orofacial cleft: A comparison between GlideScope® GVL and C-MAC® with Miller blade. *Anesth Intens* 2017;58:132-6.
- Adnet F, Borron SW, Racine SX, Clemessy JL, Fournier JL, Plaisance P, et al. The intubation difficulty scale (IDS) proposal and evaluation of a new score characterizing the complexity of endotracheal intubation. *Anesthesiology* 1997;87:1290-7.
- Yamamoto K, Tsubokawa T, Ohmura S, Itoh H, Kobayashi T. Left-molar approach improves the laryngeal view in patients with difficult laryngoscopy. *Anesthesiology* 2000;92:70-4.
- Balakrishnan C. Indian classification of cleft lip and palate. *Indian J Plast Surg* 1975;7:319-30.
- Somerville N, Fenlon S. Anaesthesia for cleft lip and palate surgery. *Contin Educ Anaesth Crit Care Pain* 2005;5:76-9.
- Jindal P, Khurana G, Gupta D. Can paraglossal approach be an effective alternative to the conventional laryngoscopy in routine anesthesia practice – A comparative study. *J Anesth Clin Res* 2014;5:406. doi: 10.4172/2155-6148.1000406.
- Roychoudhury S, Kundu R, Murmu R, Mistry T, Paul D, Chatterjee AB. Midline versus paraglossal laryngoscopic approach using the Miller blade in small children: A randomised, controlled, cross-over study. *Airway* 2020;3:127-34.
- Gupta A, Thukral S, Lakra A, Kumar S. A comparison between left molar direct laryngoscopy and the use of a Bonfils

- intubation fibrescope for tracheal intubation in a simulated difficult airway. *Can J Anaesth* 2015; 62:609-17.
16. Agrawal S, Asthana V, Sharma J, Sharma U, Meher R. Alternative intubation technique in a case of Treacher Collins Syndrome. *Internet J Anesthesio* 2005;11:1-4.
  17. Aziz MF, Dillman D, Fu R, Ph D, Brambrink AM. Comparative effectiveness of the C-Mac video laryngoscope versus Direct laryngoscopy in the setting of the predicted difficult airway. *Anesthesiology* 2012;116:629-36.
  18. Elattar H, Abdel-Rahman I, Ibrahim M, Kocz R, Raczka M, Kumar A, *et al.* A randomized trial of the glottic views with the classic miller, Wis-Hipple and C-MAC (videolaryngoscope and direct views) straight size 1 blades in young children. *J Clin Anesth* 2020;60:57-61.