

## Case series

# Concurrent hysterectomy and bilateral salpingo-oophorectomy during cytoreductive surgery and hyperthermic intraperitoneal chemotherapy for non-gynecologic cancers

McKayla J. Riggs<sup>a</sup>, Miranda Lin<sup>b</sup>, Joseph Kim<sup>b</sup>, Prakash Pandalai<sup>b</sup>, Charles S. Dietrich III<sup>a,\*</sup>

<sup>a</sup> Division of Gynecologic Oncology, University of Kentucky, 800 Rose Street, Lexington, KY 40536, United States

<sup>b</sup> Division of Surgical Oncology, University of Kentucky, 800 Rose Street, Lexington, KY 40536, United States

## ARTICLE INFO

## Keywords:

HIPEC

Hysterectomy

Bilateral salpingo-oophorectomy

## ABSTRACT

Hyperthermic intraperitoneal chemotherapy (HIPEC) is a key component of treatment in non-gynecologic peritoneal surface malignancies. As many as 10–15% of patients with a gastrointestinal primary malignancy will present with carcinomatosis. Maximal cytoreductive surgery directly affects the prognosis of patients. The routine inclusion of hysterectomy with bilateral salpingo-oophorectomy during these procedures optimizes cytoreduction despite negative pre-operative imaging and findings at the time of surgery. In this case series, we review twenty non-gynecologic cancer patients who underwent cytoreductive surgery with concurrent hysterectomy and bilateral salpingo-oophorectomy and HIPEC at our institution.

## 1. Introduction

Cytoreductive surgery (CRS) and hyperthermic intraperitoneal chemotherapy (HIPEC) are effective treatment modalities for non-gynecologic peritoneal surface malignancies. Peritoneal carcinomatosis is present in 10–30% of patients with gastrointestinal cancer at the time of initial surgery and usually is associated with a poor prognosis (Harmon and Sugarbaker, 2005). The goal of HIPEC is to target remaining microscopic residual tumor following an optimal complete resection. In the last decade, randomized clinical trials have demonstrated significant improved overall survival in patients with gastric cancer who underwent CRS followed by HIPEC compared to cytoreduction or systemic therapy alone (Yang et al., 2011; Rudloff et al., 2014). Although utilizing HIPEC for the treatment of colorectal cancer remains controversial, the highest median overall survival to date was seen in a recent multicenter clinical trial of metastatic colorectal cancer patients after treatment with CRS and HIPEC of 41.7 months (Quenet and Roca, 2018). CRS and HIPEC have also shown clinical benefit for patients with peritoneal carcinomatosis originating from the appendix (El Halabi et al., 2012) and malignant peritoneal mesothelioma (Turaga et al., 2017). It remains as the only potential cure for patients with pseudomyxoma peritonei (Benhaim et al., 2019). CRS improved both overall survival and progression free survival in colon cancers metastatic to the ovaries. Although statistical significance was not reached in breast or gastric cancer with ovarian metastasis, a trend towards

improved benefit was noted (Ayhan et al., 2005).

Both intraoperative and postoperative disease burden predicts overall survival. The Peritoneal Cancer Index (PCI) quantifies disease burden according to amount and location using intraoperative direct visualization. Higher PCI values are associated with decreased survival following CRS and HIPEC (Chu et al., 1989). To evaluate the extent of surgical debulking, Glehen and Gilly created the CC score that defines residual tumor diameter: no visible residual tumor (CC-0), less than 2.5 mm (CC-1), 2.5 mm to 2.5 cm (CC-2), and greater than 2.5 cm (CC-3). Their studies indicated that the benefits of HIPEC diminished as the CC score increased, and CC score was the most significant independent prognostic factor for patient survival (Glehen et al., 2004). As expected, patients undergoing incomplete cytoreduction faced increased morbidity with poorer survival (Lee et al., 2020).

Our institution takes a unique approach to patients with non-gynecologic peritoneal carcinomatosis. Female patients deemed optimal candidates for CRS and HIPEC undergo pre-operative counseling with both surgical oncology and gynecologic oncology. Using a shared decision-making model with the patient, hysterectomy and bilateral salpingo-oophorectomy are recommended as part of the cytoreductive effort regardless of whether gynecologic organ involvement is suspected preoperatively. To date, no literature has examined the role for concurrent hysterectomy and bilateral salpingo-oophorectomy in these non-gynecologic peritoneal carcinomatosis patients undergoing HIPEC. In this case series, we describe the demographics, pre-operative,

\* Corresponding author at: 330 Whitney Hendrickson Building, 800 Rose Street, Lexington, KY 40536, United States.

E-mail address: [charles.dietrich@uky.edu](mailto:charles.dietrich@uky.edu) (C.S. Dietrich).

intraoperative, and final pathology findings, the operative times, and immediate postoperative outcomes at our institution.

## 2. Methods

A retrospective chart review was performed on twenty consecutive patients presenting to the Markey Cancer Center between August 1, 2018, and February 28, 2020, who underwent cytoreductive surgery with concurrent hysterectomy and bilateral salpingo-oophorectomy and HIPEC for a non-gynecologic malignancy at the University of Kentucky. This review was conducted in accordance with the US Common Rule and approved by the Institutional Review Board (IRB). Demographic variables, such as age, race, BMI, preoperative assessment, intraoperative findings, final pathologic diagnosis, and 30-day surgical outcomes were included in the analysis.

Our institution utilizes an open approach to CRS through a midline laparotomy incision. Initial exploration quantifies PCI. All female patients, regardless of gross disease, undergo the following procedures: resection of the greater and lesser omentum, appendectomy, cholecystectomy, hysterectomy, bilateral salpingo-oophorectomy, and tumor debulking with the goal of achieving complete resection of all visible disease. A closed system technique is used for administration of HIPEC with the Genesis Medical System. The abdomen is warmed with hyperthermic saline to 43 °C and chemotherapy is infused and perfused for 30–90 min with simultaneous agitation of the abdomen. We typically administer cisplatin for 60 min for gastric cancer and mitomycin C for 90 min in appendiceal and colorectal primaries. Following administration, the abdomen is rinsed with three liters of saline, the abdomen re-opened and irrigated, and the definitive visceral reconstruction performed (Riggs et al., 2020).

## 3. Results

The cohort was comprised of twenty female patients aged 18–75 years old (mean 52 years). Reflective of Kentucky demographics, race was predominantly Caucasian (15/20, 75%). The most common cancer type was mucinous appendiceal adenocarcinoma (9/20, 45%). Several of the mucinous appendiceal subtypes were considered low-grade appendiceal neoplasms (4/9, 44.4%). BMI ranged from 17.3–49.2 kg/m<sup>2</sup> (mean 30.24 kg/m<sup>2</sup>). Demographic characteristics of all subjects are shown in Table 1.

Nine patients (9/20, 45%) had evidence of gynecologic organ disease on pre-operative assessment, either from imaging studies with positron emission tomography (PET) or computed tomography (CT) scan or from pre-operative assessment via diagnostic laparoscopy to determine eligibility for HIPEC. Thirteen patients (13/20, 65%) had gross involvement of the gynecologic organs at the time of surgery, and sixteen (16/20, 80%) had confirmation of disease on final pathology. Of the eleven patients with negative pre-operative assessment, five had gross visible disease at the time of surgery with positive final pathologic analysis. An additional three had microscopic disease on final pathology that was not visible preoperatively or intraoperatively as shown in Fig. 1.

The average PCI of the cases was 7.9 with seven patients having a PCI  $\geq$  10. At the completion of surgery, eighteen patients (90%) had a CC-0 score, and two patients (10%) had a score of CC-1 at the time of HIPEC. Mean estimated blood loss was 152.5 mL (range 50–500 mL) for the non-gynecologic portion and 106.5 mL (range 25–400 mL) for the gynecologic portion of the cases. These findings are displayed in Table 2. The mean operative time of the cases was 481 min (range 271–790 min). Patients were discharged home after a mean of 7 days (range 4–16 days).

Complications are summarized using the Clavien-Dindo Classification system in Table 3 (Clavien et al., 2009). One intraoperative cystotomy occurred during the completion of the hysterectomy as part of the oncologic resection for her disease burden and is

**Table 1**  
Demographic Characteristics.

Characteristics	No. Patients (%)
<b>Total</b>	20 (100)
Age Group	Range (18–75 years)
< 52 years	8 (40.0)
52+ years	12 (60.0)
Race	
Caucasian	15 (75.0)
African American	2 (10.0)
Other	3 (15.0)
Cancer Type	
Mucinous Appendiceal	9 (45.0)
Colonic Adenocarcinoma	3 (15.0)
Gastric Adenocarcinoma	3 (15.0)
Urachal Mucinous	1 (5.0)
Mesothelioma	2 (10.0)
Small Bowel Adenocarcinoma	2 (10.0)
Pathologic Grade	
1	5 (25.0)
2	6 (30.0)
3	3 (15.0)
Unknown	6 (30.0)
BMI (kg/m <sup>2</sup> )	
15–25	6 (30.0)
26–35	7 (35.0)
36–45	6 (5.61)
46–55	1 (5.0)

not included in the graded complications. This patient had recurrent pseudomyxoma peritonei that had fistulized into the uterus. No other intraoperative complications were noted.

In the peri- and post-operative course, nine patients (45%) recovered uneventfully. Most of the complications recorded were grade I–II. Five patients had grade III complications, and one had a grade IV complication. One patient who had extensive diaphragmatic resection required a chest tube on postoperative day two for a pneumothorax occurrence. One patient developed pancytopenia felt to be secondary to sequestered chemotherapy perfusate fluid in the pleural cavity that resolved after interventional radiology guided thoracentesis and growth factor support. One patient was noted to have a small pleural effusion postoperatively that was expectantly managed and later developed a right upper quadrant hematoma requiring aspiration but never required a transfusion. The two other grade III complications are described further with their readmissions. The grade IV complication occurred in a patient who developed pneumonia following an aspiration event on postoperative day four requiring ICU care and intubation, resulting in a sixteen-day postoperative hospital stay.

In the subsequent six-week period following discharge from the initial hospitalization, four patients required readmission. One patient was readmitted with dehydration from high colostomy output. Another patient was readmitted three weeks postoperatively with a peri-splenic abscess that resolved with drain placement. A third patient was found to have a strangulated hernia three weeks postoperatively and underwent an exploratory laparotomy with mesh repair. The final patient was readmitted three weeks postoperatively for a paralytic ileus treated expectantly and a pelvic fluid collection managed with antibiotics.

## 4. Discussion

This descriptive case series examines the potential to maximize cytoreductive surgery efforts for non-gynecologic cancers undergoing HIPEC by including a gynecologic oncologist for a planned hysterectomy and bilateral salpingo-oophorectomy, regardless of pre-operative imaging or intraoperative findings at the time of surgery. Overall, eighty percent of patients in our series had metastasis to gynecologic organs. Even in patients with a negative preoperative assessment for gynecologic involvement, 72.7% (8 of 11 patients) were

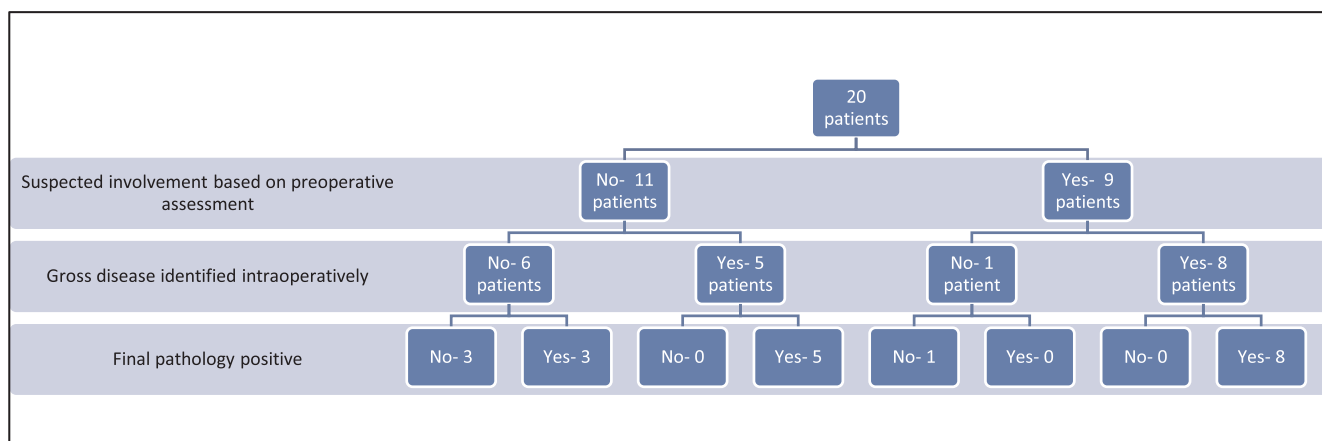


Fig. 1. Pelvic organ involvement by non-gynecologic malignancies flowsheet.

Table 2  
Surgical Demographics.

Characteristics	No. Patients (%)
<b>Total</b>	20 (100)
PCI values	
Range (mean)	0–22 (7.9)
Cytoreduction Score	
CC-0	18 (90)
CC-1	2 (10)
Operative Time	
Range (mean), minutes	318–790 (481.45)
Estimated blood loss, average in cc (range)	
Gynecologic	106.5 (25–400 mL)
Non-gynecologic	152.5 (50–500 mL)
Length of hospital stay	
Range (mean), days	4–16 (7.4)

Table 3  
Morbidity after surgical cytoreduction and HIPEC.

Morbidity	Grade			Total (%)
	I-II	III	IV	
<b>Gastrointestinal tract</b>				3 (15.0)
Paralytic ileus	2	–	–	
Anastomotic leak	–	–	–	
Strangulated hernia	–	1	–	
<b>Hematologic</b>				5 (25.0)
Blood transfusion	2	–	–	
Wound hematoma	–	1	–	
Leukopenia requiring intervention	2	–	–	
<b>Infections</b>				3 (15.0)
Superficial wound infection	1	–	–	
Deep surgical site	1	1	–	
<b>Pulmonary</b>				4 (20.0)
Pleural effusions	1	1	–	
Pneumothorax	–	1	–	
Aspiration pneumonia	–	–	1	
<b>Renal</b>				2 (10.0)
Acute Kidney Injury	2	–	–	
<b>Hospital Readmissions</b>				
Readmission < 30 days				4 (20.0)
Readmission > 30–90 days				0 (0.0)

confirmed to have either gross disease intraoperatively or microscopic disease on final pathology. This suggests that by not including a planned hysterectomy or bilateral salpingo-oophorectomy at the time of surgery, a less optimal debulking may occur. In addition, by involving the gynecologic oncology service in preoperative assessment, patients were counseled about the risks and benefits of a total hysterectomy and bilateral salpingo-oophorectomy before the procedure and were

mentally prepared to undergo that portion of the surgery.

In non-gynecologic cancers, HIPEC and CRS have an estimated morbidity of 30–50%, mortality of 1–5%, with a mean operative time of 388–550 min depending on the extent of peritoneal procedures (Baratti et al., 2010). A positive correlation between duration of surgery, number of peritonectomy procedures and resections, and number of suture lines correlated with combined grade III-IV morbidities. Duration of surgery was the most common predictor of morbidity and was associated with pancreatitis, cardiovascular toxicity, wound sepsis, systemic sepsis, bile leak, and deep vein thrombosis. In a study by Stephens, et al., their average patient had 2.1 prior surgeries and a PCI of 19 with the majority (150/183) having appendiceal primary as the source (Stephens et al., 1999).

In our patients, mean operative time including the hysterectomy and bilateral salpingo-oophorectomy was 481 min, which is similar to that quoted in prior studies. Our perioperative and postoperative complications are also similar to what is quoted in the literature, suggesting that the addition of a planned hysterectomy and bilateral salpingo-oophorectomy with each case may not add to the overall morbidity of the procedure. The inclusion of a hysterectomy added an average of 106 mL of blood loss to the case. The only event directly linked to hysterectomy in our series was a cystotomy created during en bloc resection of the uterus with tumor that was not unexpected given her disease extent and required oncologic resection. A second patient requiring readmission three weeks postoperatively for ileus was found to have a pelvic fluid collection requiring antibiotics that could have been secondary to the hysterectomy portion of the case. Our patients had an average PCI of 7.9 with seven of twenty patients having a PCI ≥ 10. The PCI of the patients in the prior studies mentioned was 19, suggesting a higher surgical complexity, although this does not take into consideration the surgical and medical history of our patients prior to the operation.

The key limitation to this study is its retrospective nature and case series design. Based on our practice approach, a control group that did not have concurrent hysterectomy and bilateral salpingo-oophorectomy is unavailable for comparison of outcomes. However, this is the first study to take a deeper look into concurrent hysterectomy and bilateral salpingo-oophorectomy in non-gynecologic cancer cases. Eighty percent of patients in our series had gynecologic organ involvement including both expected and unexpected final pathologic findings. Prior studies would suggest that maximal cytoreduction leads to improved outcomes, but further prospective trials would be needed to fully understand the survival impact of hysterectomy and bilateral salpingo-oophorectomy in this setting.

## 5. Conclusion

CRS and HIPEC are treatment options for patients with non-gynecologic cancers, and survival outcomes have been correlated with the extent of CRS. Our experience at Markey Cancer Center suggests a benefit to concurrent hysterectomy and bilateral salpingo-oophorectomy as part of the cytoreductive effort in these cases. Twenty-five percent (5/20) of patients had gross involvement of gynecologic organs at the time of surgery that was unanticipated based on preoperative evaluation. An additional fifteen percent (3/20) of our patients had microscopic involvement that was unexpected given both pre- and intraoperative assessment. Involving a gynecologic oncologist in the care of these patients preoperatively allows for additional counseling and patient preparation. Our morbidity and operative times are within the reported range of prior literature, even with our inclusion of a hysterectomy and bilateral salpingo-oophorectomy at the time of CRS. We feel there is benefit in a multidisciplinary approach to these patients and that concurrent hysterectomy and bilateral salpingo-oophorectomy at the time of CRS and HIPEC may maximize the CRS without adding significant surgical morbidity.

## CRedit authorship contribution statement

**McKayla J. Riggs:** Conceptualization, Data curation, Formal analysis, Investigation, Writing - original draft, Writing - review & editing. **Miranda Lin:** Data curation, Writing - original draft, Writing - review & editing. **Joseph Kim:** Resources, Validation, Writing - original draft, Writing - review & editing. **Prakash Pandalai:** Resources, Validation, Writing - original draft, Writing - review & editing. **Charles Dietrich:** Conceptualization, Investigation, Validation, Project administration, Supervision, Writing - original draft, Writing - review & editing.

## Declaration of Competing Interest

The authors declare that they have no known competing financial interests or personal relationships that could have appeared to influence the work reported in this paper.

## References

- Ayhan, A., Guvenal, T., Salman, M.C., Ozyuncu, O., Sakinci, M., Basaran, M., 2005. The role of cytoreductive surgery in nongenital cancers metastatic to the ovaries. *Gynecol. Oncol.* 98 (2), 235–241.
- Baratti, D., Scivales, A., Balestra, M.R., Ponzi, P., Di Stasi, F., Kusamura, S., et al., 2010. Cost analysis of the combined procedure of cytoreductive surgery and hyperthermic intraperitoneal chemotherapy (HIPEC). *Eur. J. Surg. Oncol.* 36 (5), 463–469.
- Benhaim, L., Faron, M., Gelli, M., Sourrouille, I., Honore, C., Delhorme, J.B., et al., 2019. Survival after complete cytoreductive surgery and HIPEC for extensive pseudomyxoma peritonei. *Surg. Oncol.* 29, 78–83.
- Chu, D.Z., Lang, N.P., Thompson, C., Osteen, P.K., Westbrook, K.C., 1989. Peritoneal carcinomatosis in nongynecologic malignancy. A prospective study of prognostic factors. *Cancer* 63 (2), 364–367.
- Clavien, P.A., Barkun, J., de Oliveira, M.L., Vauthey, J.N., Dindo, D., Schulick, R.D., et al., 2009. The Clavien-Dindo classification of surgical complications: five-year experience. *Ann. Surg.* 250 (2), 187–196.
- El Halabi, H., Gushchin, V., Francis, J., Athas, N., Macdonald, R., Nieroda, C., et al., 2012. The role of cytoreductive surgery and heated intraperitoneal chemotherapy (CRS/HIPEC) in patients with high-grade appendiceal carcinoma and extensive peritoneal carcinomatosis. *Ann. Surg. Oncol.* 19 (1), 110–114.
- Glehen, O., Mohamed, F., Sugarbaker, P.H., 2004. Incomplete cytoreduction in 174 patients with peritoneal carcinomatosis from appendiceal malignancy. *Ann. Surg.* 240 (2), 278–285.
- Harmon, R.L., Sugarbaker, P.H., 2005. Prognostic indicators in peritoneal carcinomatosis from gastrointestinal cancer. *Int. Semin. Surg. Oncol.* 2 (1), 3.
- Lee, R.M., Zaidi, M.Y., Gamboa, A.D., Speegle, S., Kimbrough, C.W., Cloyd, J.M., et al., 2020. What is the optimal preoperative imaging modality for assessing peritoneal cancer index? An analysis from the United States HIPEC collaborative. *Clin. Colorectal Cancer* 19 (1), e1–e7. <https://doi.org/10.1016/j.clcc.2019.12.002>.
- Quenet, F.E.D., Roca, L., et al., 2018. A UNICANCER phase III trial of hyperthermic intraperitoneal chemotherapy (HIPEC) for colorectal peritoneal carcinomatosis (PC): PRODIGE 7. *J. Clin. Oncol.* 36 (18, supp).
- Riggs, M., Pandalai, P., Kim, J., Dietrich, C., 2020. Hyperthermic intraperitoneal chemotherapy in ovarian cancer. *Diagnostics* 10 (1), 43. <https://doi.org/10.3390/diagnostics10010043>.
- Rudloff, U., Langan, R.C., Mullinax, J.E., Beane, J.D., Steinberg, S.M., Beresnev, T., et al., 2014. Impact of maximal cytoreductive surgery plus regional heated intraperitoneal chemotherapy (HIPEC) on outcome of patients with peritoneal carcinomatosis of gastric origin: results of the GYMSSA trial. *J. Surg. Oncol.* 110 (3), 275–284.
- Stephens, A.D., Alderman, R., Chang, D., et al., 1999. Morbidity and mortality analysis of 200 treatments with cytoreductive surgery and hyperthermic intraoperative intraperitoneal chemotherapy using the coliseum technique. *Ann. Surg. Oncol.* 6 (8), 790–796.
- Turaga, K.K., Deraco, M., Alexander, H.R., 2017. Current management strategies for peritoneal mesothelioma. *Int. J. Hyperthermia* 33 (5), 579–581.
- Yang, X.J., Huang, C.Q., Suo, T., Mei, L.J., Yang, G.L., Cheng, F.L., et al., 2011. Cytoreductive surgery and hyperthermic intraperitoneal chemotherapy improves survival of patients with peritoneal carcinomatosis from gastric cancer: final results of a phase III randomized clinical trial. *Ann. Surg. Oncol.* 18 (6), 1575–1581.