

Received: 2018.08.25
 Accepted: 2018.12.28
 Published: 2019.06.03

Comparison of Wrist Arthroscopy, Small Incision Surgery, and Conventional Surgery for the Treatment of Carpal Tunnel Syndrome: A Retrospective Study at a Single Center

Department of Hand Surgery, Ningbo No. 6 Hospital, Ningbo, Zhejiang, P.R. China

Authors' Contribution:
 Study Design A
 Data Collection B
 Statistical Analysis C
 Data Interpretation D
 Manuscript Preparation E
 Literature Search F
 Funds Collection G

B Xiaofeng Teng
 D Jihai Xu
 F Huizong Yuan
 G Xinkun He
 ACE Hong Chen

Corresponding Author: Hong Chen, e-mail: hongchen2qm@163.com
 Source of support: Departmental sources

Background: This study aimed to compare the efficacy and safety of wrist arthroscopy, small incision surgery, and conventional open carpal tunnel release surgery for the treatment of carpal tunnel syndrome.





Material/Methods: Patients with carpal tunnel syndrome (n=111) were treated with wrist arthroscopy (n=33), small incision surgery (n=40), and conventional open carpal tunnel release surgery (n=38). Incision length, duration of surgery, degree of intraoperative bleeding, recovery time, and findings at postoperative follow-up at one month, three months, and six months after surgery were recorded. Assessment included the two-point discrimination test, the grip and pinch strength test, the visual analog scale (VAS) score for pain, the Levine questionnaire, and Kelly's therapeutic evaluation.

Results: Incision length, duration of surgery, intraoperative bleeding, and recovery time were significantly reduced in the wrist arthroscopy group and the small incision surgery group compared with the conventional surgery group (p<0.05). There were no significant differences in the two-point discrimination or grip and pinch strength test (p>0.05). Postoperatively, at one month, the VAS score, Levine score, and Kelly's therapeutic evaluation in the wrist arthroscopy group and the small incision surgery group were significantly lower compared with the conventional surgery group (p<0.05). Scar length and scar tenderness in the conventional surgery group were significantly increased compared with the wrist arthroscopy group and the small incision surgery group (p<0.05).

Conclusions: Wrist arthroscopy, small incision surgery, and conventional open carpal tunnel release surgery were effective for the treatment of carpal tunnel syndrome, but conventional surgery resulted in more postoperative complications.

MeSH Keywords: Arthroscopy • Carpal Tunnel Syndrome • Tissue Adhesions

Full-text PDF: <https://www.medscimonit.com/abstract/index/idArt/912912>

 2817  5  5  20



Background

Carpal tunnel syndrome is due to compression of the median nerve within the carpal tunnel and is treated surgically. Carpal tunnel syndrome is a common condition that includes the symptoms of pain and numbness in the fingers, and signs of muscle atrophy [1,2]. The symptom of pain associated with carpal tunnel syndrome can cause sleep disturbance. If the condition is not treated early, it can lead to thenar muscle atrophy and weakness that can affect the quality of life of patients.

Treatment of carpal tunnel syndrome includes conservative treatment for mild symptoms, but open carpal tunnel release surgery is most commonly used for patients with symptoms or thenar muscle atrophy and weakness or when conservative treatments have failed [3]. Wrist arthroscopy and small incision surgery are also used in the surgical treatment of carpal tunnel syndrome in addition to conventional carpal tunnel release surgery, and each surgical approach has advantages and disadvantages. However, the choice of surgical method for the treatment of carpal tunnel syndrome can vary between each center and each orthopedic surgeon.

This retrospective observational study was conducted at a single center and aimed to compare the efficacy and safety of wrist arthroscopy, small incision surgery, and conventional open carpal tunnel release surgery for the treatment of carpal tunnel syndrome.

Material and Methods

Patients studied

A total of 111 patients with carpal tunnel syndrome who underwent surgical treatment from February 2017 to December 2017 were retrospectively reviewed, using the medical and surgical records. There were 33 patients who underwent wrist arthroscopy (the wrist arthroscopy group), 40 patients who underwent small incision surgery (the small incision surgery group), and 38 patients who underwent conventional open carpal tunnel release surgery (the conventional surgery group). The clinical characteristics of the patients in the three study groups are shown in Table 1. In the wrist arthroscopy group, there were

18 men and 15 women, with a mean age of 41.22 ± 3.28 years, and a mean pre-operative history of 8.71 ± 1.22 months. In the small incision surgery group, there were 23 men and 17 women, with a mean age of 43.23 ± 2.11 years, and a mean pre-operative history of 8.67 ± 1.98 months. In the conventional surgery group, there were 20 men and 18 women, with a mean age of 42.68 ± 2.98 years, and a mean pre-operative history of 9.11 ± 1.18 months. Comparisons between the group showed that there were no significant differences in gender, age, and length of the pre-operative clinical history of carpal tunnel syndrome between the groups ($p>0.05$). All subjects signed informed consent to participate in the study. The study was approved by the Ethics Committee of Ningbo No. 6 Hospital.

Diagnostic criteria for carpal tunnel syndrome

The diagnostic criteria for carpal tunnel syndrome included: patients with symptoms of numbness of three-and-a-half fingers on the radial side, waking with nocturnal pain, and thenar muscle atrophy and asthenia; >6 mm two-point discrimination on testing the index finger; a positive Tinel's sign; a positive Phalen's test; and patients who had electromyography (EMG) testing that showed reduced or absent sensory conduction velocity of the median nerve or a prolonged or absent latent period, and the appearance of an waveform of the abductor pollicis brevis muscle.

Study inclusion criteria

Patients who were included in the study met the diagnostic criteria for carpal tunnel syndrome and required surgical treatment, were free from heart disease, diabetes, and other diseases that might increase their risk from anesthesia and surgery. Patients were included who had no response or persistent symptoms following conservative treatment, patients who agreed to participate in this study and signed the informed consent, and patients who complied with medical advice and treatment.

Study exclusion criteria

Patients were excluded from the study who did not meet the above inclusion criteria, female patients who were pregnant or lactating, patients with hypertension, diabetes, heart disease,

Table 1. Characteristics of the patients with carpal tunnel syndrome in the three surgical treatment groups.

Group	Male: Female (n)	Age (years)	Course of disease (months)
Wrist arthroscopy group	18: 15	41.22 ± 3.28	8.71 ± 1.22
Small incision surgery group	23: 17	43.23 ± 2.11	8.67 ± 1.98
Conventional surgery group	20: 18	42.68 ± 2.98	9.11 ± 1.18

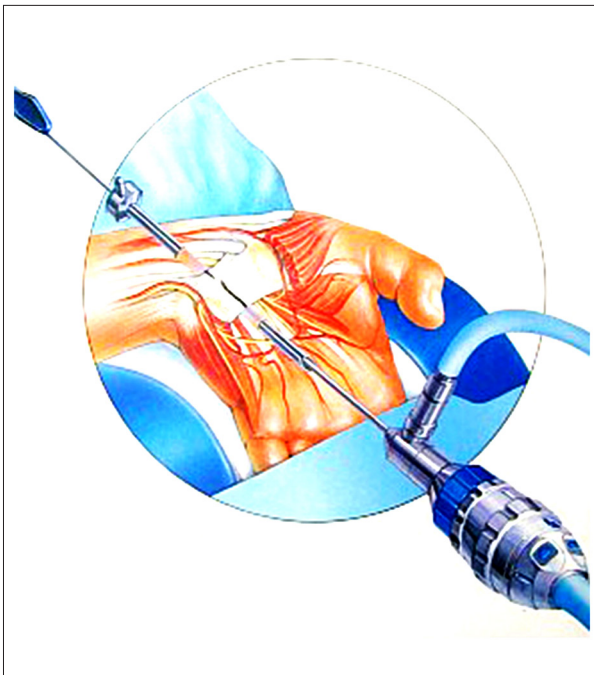


Figure 1. A diagram illustrating the surgical procedure of wrist arthroscopy for the treatment of carpal tunnel syndrome.

or other major diseases and who could not tolerate surgery, patients with mental disease or cognitive impairment, and patients with cervical spondylosis complicated by and hyperosteoarthritis of the cervical vertebrae.

Wrist arthroscopy surgery

Following anesthesia, patients who underwent wrist arthroscopy were maintained in the supine position. Disinfectant was applied to the surgical site, followed by draping. The transverse horizontal palmar longus tendon, at 1 cm from the ulnar side of the wrist, was chosen as the point of the initial surgical excision. The thumb was maintained in radial abduction, parallel to the metacarpophalangeal joint on the ulnar side. The intersection point of the long axis between the ring finger and the ulnar side was 45 degrees. A tunnel was created from the incision site on the ulnar side of the palmaris longus tendon, with the outer sleeve aimed towards the ring finger. The probe entered the wrist adjacent to the observed movement of the flexor tendon. The outer sleeve was inserted from the outlet of the carpal canal by lifting the skin upward and using a sharp knife. The skin incision was 6 mm in length. The subcutaneous tissue underwent blunt dissection and the palmar aponeurosis was exposed by the incision (Figure 1). The junction between the palm and the flexed ring finger was the exit point where an incision about 0.5 cm in length was made. The deep fascia was cut, the transverse carpal ligament was exposed, and the carpal joint was maintained in dorsal

extension. The inferior transverse carpal ligament was punctured via the puncture outfit and the skin was pierced at the exit point. The cannula was placed along the puncture outfit, which was removed and the carpal tunnel endoscope was inserted to view and sever the transverse carpal ligament under the direct view of the carpal tunnel endoscope. After any bleeding points and the tendon were examined for any abnormalities, the carpal tunnel endoscope was removed and the wound was sutured (Supplementary Figure 1).

Small incision surgery

Following anesthesia, patients who underwent small incision surgery were maintained in the supine position. Disinfectant was applied to the surgical site, followed by draping. A longitudinal incision of 3 cm in length was made at 3 mm from the ulnar side of the thenar eminence on the extended line of the web of the ring finger. The transverse carpal ligament was exposed and excised from the ulnar side of the tendon palmaris longus. The flexor retinaculum (transverse carpal ligament) was exposed and removed with tissue scissors. The cut end of the transverse carpal ligament was pulled and the median nerve was examined. Patients with severe epineurium hyperplasia underwent epineurium release. Following hemostasis, 2 mL of dexamethasone was injected into the epineurium, and the wound was sutured and bandaged under pressure (Supplementary Figure 1).

Conventional open carpal tunnel release surgery

Following anesthesia, patients who underwent conventional open carpal tunnel release surgery were maintained in the supine position. Disinfectant was applied to the surgical site, followed by draping. An incision was made along the thenar muscles and turned to the ulnar side in an arc shape to the distal superficial palmar arch at the proximal end. The median nerve and its branches were protected, the transverse carpal ligament was severed, the synovium was cleared, the epineurium was released, and the wound was sutured (Supplementary Figure 1).

Surgical evaluation indicators

The incision length, duration of surgery, amount of intraoperative bleeding, and time to return to work for the patients were recorded in the three treatment groups. Patients were followed up at one month, three months, and six months after surgery. The results from the two-point discrimination test, the grip and pinch strength test, the visual analog scale (VAS) score for pain, the Levine Questionnaire, and Kelly's therapeutic evaluation were recorded. Postoperative complications at the last follow-up were recorded for all patients.

Table 2. Comparisons of the surgical data and recovery time of the patients with carpal tunnel syndrome in the three surgical treatment groups.

Group	Length of incision (cm)	Blood loss (mL)	Surgery time (min)	Recovery time (days)
Wrist arthroscopy group	3.38±0.87*	5.56±2.18*#	18.38±5.73*	17.57±5.15**
Small incision surgery group	3.51±0.98*	8.98±2.33*	21.25±3.77*	28.35±4.22*
Conventional surgery group	8.77±1.21	15.38±4.21	38.92±8.77	44.21±3.56

* p<0.05 vs. the conventional surgery group; # p<0.05 vs. the small incision surgery group.

Table 3. Comparison of the findings from the two-point discrimination test (mm) of the patients with carpal tunnel syndrome in the three surgical treatment groups.

Group	1 month after surgery	3 months after surgery	6 months after surgery
Wrist arthroscopy group	3.21±0.53*	3.18±0.47*	2.89±0.57*
Small incision surgery group	3.48±0.73	3.16±0.31*	2.93±0.46*
Conventional surgery group	3.51±0.31	3.37±0.28	3.08±0.77

* p<0.05 vs. the conventional surgery group.

Statistical analysis

SPSS version 20.0 software (IBM, Chicago, IL, USA) was used for statistical analysis. Data were expressed as the mean ± standard deviation (SD). The t-test was used when the data showed a homogeneous normal distribution, the adjusted t-test was used when the data showed a heterogeneous normal distribution, and the nonparametric test was adopted when the normal distribution was not met and the variance was heterogeneous. The rank sum test was used for ranked data and chi-squared (χ^2) test was used for count data. A p-value <0.05 was considered to be statistically significant.

Results

Comparisons of the surgical data in the three surgical treatment groups

As shown in Table 2, the length of the surgical incision in the wrist arthroscopy group and the small incision surgery group were significantly less than that in the conventional surgery group (p<0.05). The amount of intraoperative bleeding in the wrist arthroscopy group was significantly less than in the small incision surgery group and the conventional surgery group (p<0.05), and was also significantly less in the small incision surgery group compared with the conventional surgery group (p<0.05). The duration of surgery in the wrist arthroscopy group and the small incision surgery group was significantly less when compared with the conventional surgery group (p<0.05). Also, the recovery time in the wrist arthroscopy group as significantly

less when compared with the small incision surgery group and the conventional surgery group (p<0.05), and was also significantly less in the small incision surgery group compared with the conventional surgery group (p<0.05).

Comparison of the results of the two-point discrimination test

As shown in Table 3, there were no significant differences in the results of the two-point discrimination test between the three groups at one month, three months, and six months after surgery (p>0.05).

Comparisons of the grip and pinch strength test

As shown in Table 4, there were no significant differences in the results of the grip and pinch strength test between the three groups at one month, three months, and six months after surgery (p>0.05).

Comparisons of visual analog scale (VAS) score for pain, the Levine questionnaire score, and Kelly's therapeutic evaluation

The visual analog scale (VAS) scores in the wrist arthroscopy group and the small incision surgery group were significantly lower when compared with the conventional surgery group at one month after surgery (p<0.05). There were no significant differences in the VAS scores between the three groups at three months and at six months after surgery (p>0.05). The Levine questionnaire score in the conventional surgery group was

Table 4. Comparison of the findings from the grip and pinch strength test (kg) of the patients with carpal tunnel syndrome in the three surgical treatment groups.

Group	1 month after surgery		3 months after surgery		6 months after surgery	
	Grip strength	Pinch strength	Grip strength	Pinch strength	Grip strength	Pinch strength
Wrist arthroscopy group	26.21±4.32	5.18±1.21	28.78±5.11	6.82±1.56*	28.67±4.71	7.13±1.21
Small incision surgery group	25.78±5.22	5.22±1.79	28.19±4.45	6.78±1.77	28.72±5.25	7.09±1.19
Conventional surgery group	26.19±4.47	4.99±1.33	28.79±6.26	6.11±1.33	28.17±4.32	7.11±1.21

* p<0.05 vs. the conventional surgery group.

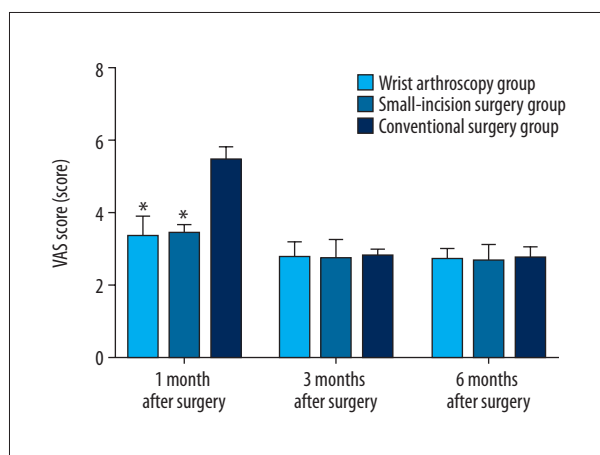


Figure 2. Bar graphs of the visual analog scale (VAS) scores in the three surgical treatment groups at 1 month, 3 months, and 6 months after surgery. * p<0.05 vs. the conventional surgery group.

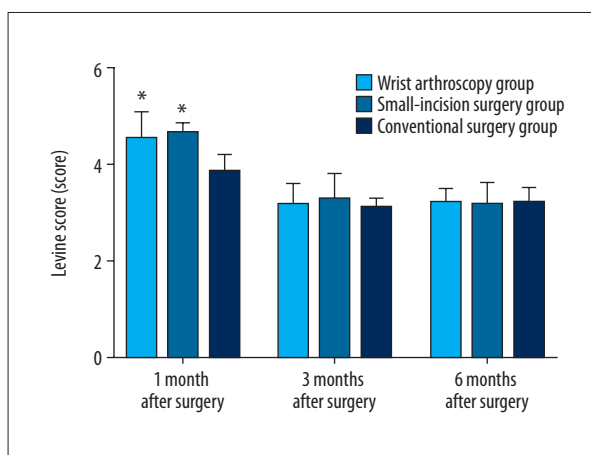


Figure 3. Bar graphs of the Levine questionnaire scores in the three surgical treatment groups at 1 month, 3 months, and 6 months after surgery. * p<0.05 vs. the conventional surgery group.

significantly lower compared with that in the wrist arthroscopy group and the small incision surgery group at one month after surgery (p<0.05). No significant differences were found in the Levine questionnaire score between the three groups at three months and six months after surgery (p>0.05). The good to excellent scores of Kelly's therapeutic evaluation in the conventional surgery group was significantly greater when compared with the wrist arthroscopy group and the small incision surgery group at one month after surgery (p<0.05). The good to excellent rate of Kelly's therapeutic evaluation was not significantly different between the three groups at three months and six months after surgery (p>0.05) (Figures 2–4).

Comparisons of postoperative complications in the three surgical groups

The scar length in the conventional surgery group was significantly longer compared with that in the wrist arthroscopy group and the small incision surgery group (p<0.05), and was

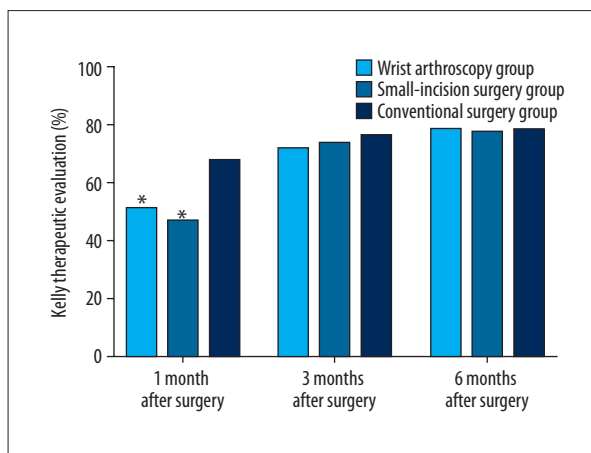


Figure 4. Bar graphs of Kelly's therapeutic evaluation scores in the three surgical treatment groups at 1 month, 3 months, and 6 months after surgery. * p<0.05 vs. the conventional surgery group

Table 5. Comparison of the findings of the postoperative scar length (cm) and scar tenderness (%) of the patients with carpal tunnel syndrome in the three surgical treatment groups.

Group	Scar length (cm)	Incidence rate of scar tenderness (%)
Wrist arthroscopy group	1.12±0.97*#	31*#
Small incision surgery group	2.67±1.21*	43*
Conventional surgery group	5.21±1.31	57

* p<0.05 vs. the conventional surgery group. # p<0.05 vs. the small incision surgery group.

significantly shorter in the wrist arthroscopy group compared with that in the small incision surgery group (p<0.05). The incidence of scar tenderness in the conventional surgery group was significantly greater compared with the wrist arthroscopy group and the small incision surgery group (p<0.05), and was significantly less in the wrist arthroscopy group compared with the small incision surgery group (p<0.05). No nerve injury occurred in the three study groups (Table 5).

Discussion

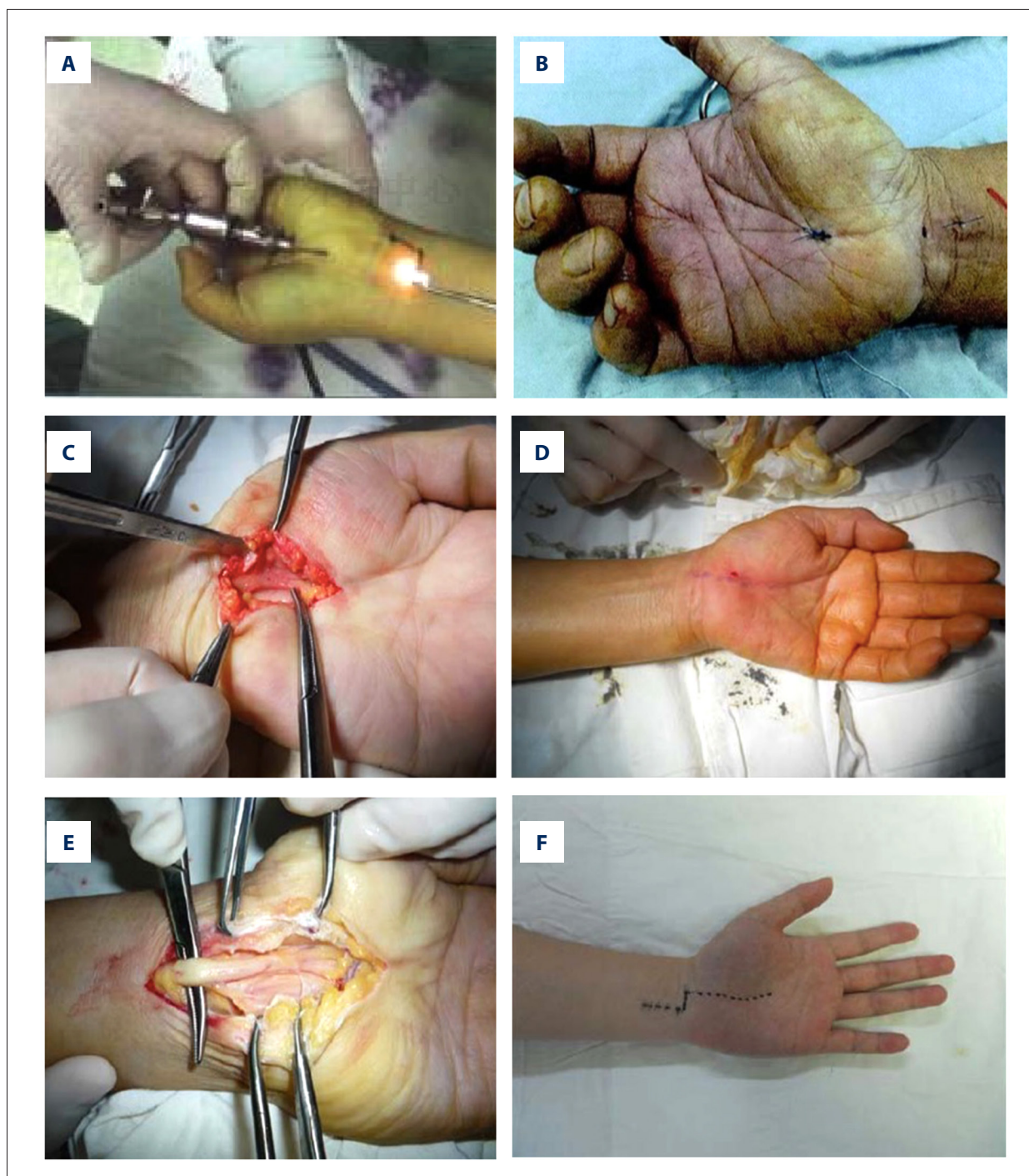
Carpal tunnel syndrome can arise from several causes and is associated with a decreased carpal tunnel volume with compression of the median nerve. Surgical treatment involves excising the transverse carpal ligament to open and increase the volume of the carpal tunnel and completely relieve the compression of the median nerve [4,5]. In conventional open carpal tunnel release surgery, the tissues between the skin and the transverse carpal ligament are completely excised, and the transverse carpal ligament is completely removed to relieve the compression of the median nerve [6]. Conventional release surgery, which is a simple technique that is widely used, involves completely opening the carpal tunnel, with release of the median nerve, and is definitive and reliable treatment with good efficacy [7,8]. However, conventional open carpal tunnel release surgery can be associated with increased surgical trauma that results in longer postoperative recovery times. A further postoperative complication of conventional release surgery is the formation of scar tissue on the palm of the hand and scar tenderness that can be associated with the development of a neuroma in the palmar cutaneous nerve branch, which can affect the postoperative quality of life [9].

Recent developments in the surgical treatment of carpal tunnel syndrome have resulted in improved surgical techniques to reduce

postoperative pain and improve cosmesis. In small incision surgery, the transverse carpal ligament can also be excised to fully decompress the carpal tunnel, which leads to improved efficacy, particularly in terms of functional improvement and reduced scar hyperplasia [10–12]. Also, in small incision surgery, the requirements for surgical instruments and equipment are low, the surgical approach is simpler, tissue damage is smaller, and the medical costs are lower [13]. However, the disadvantage of small incision surgery is that during surgery, it is not possible to fully explore the structure and condition of carpal tunnel or to excise the flexor retinaculum under direct vision, which can lead to incomplete release and the accidental damage to tissues and nerves [14,15].

However, not all cases of carpal tunnel syndromes can be treated with small incision surgery. Minimally invasive surgery, including small incision surgery, is not applicable for carpal tunnel syndrome caused by secondary diseases, carpal tunnel tumor, and abnormalities in the muscles of the hand or wrist. With the rapid development of endoscopic techniques for minimally invasive surgery, carpal tunnel surgery using wrist arthroscopy has become increasingly used. The results of the present study showed that the length of the surgical incision and surgery time in wrist arthroscopy and small incision surgery were significantly shorter when compared with conventional release surgery. Also, the amount of intraoperative bleeding in wrist arthroscopy and small incision surgery was significantly less than that in conventional release surgery, and was significantly less in wrist arthroscopy compared with small incision surgery, indicating that wrist arthroscopy and small incision surgery, as minimally invasive surgical methods, cause less damage to tissues, improve postoperative recovery, and result in shorter recovery time of patients with carpal tunnel syndrome.

There were no significant differences in the improvement of grip and pinch strength and two-point discrimination of patients with carpal tunnel syndrome between the three treatment groups. The three surgical methods all reduced compression of the median nerve caused by carpal tunnel syndrome. At one month after surgery, wrist arthroscopy and small incision surgery reduced the symptoms of pain significantly more than conventional release surgery. However, the early efficacy of wrist arthroscopy and small incision surgery was not superior to that of conventional release surgery, and no significant differences were found in long-term efficacy between the three surgical methods. The possible reason is that in conventional release surgery, the transverse carpal ligament can be excised to fully decompress the carpal tunnel with improved release the median nerve. However, scar formation after conventional release surgery was significantly greater when compared with scar formation after wrist arthroscopy and small incision surgery, and the incidence rate of scar tenderness after conventional release surgery was significantly greater when compared with wrist arthroscopy and small incision surgery.



Supplementary Figure 1. Operative images demonstrating the three surgical procedures used in the treatment of carpal tunnel syndrome. (A, B) Wrist arthroscopy surgery for the treatment of carpal tunnel syndrome. (C, D) Small incision surgery for the treatment of carpal tunnel syndrome. (E, F) Conventional open carpal tunnel release surgery for the treatment of carpal tunnel syndrome.

Previously published studies have reported that in the surgical management of patients with carpal tunnel syndrome, wrist arthroscopy is associated with less tissue damage and more rapid recovery [16,17]. In minimally invasive wrist arthroscopy,

the transverse carpal ligament can be excised under direct vision with the help of the endoscope, which avoids accidental damage to other tissues, so that surgical trauma is reduced, there are few postoperative complications, and patients can

recover quickly [18,19]. However, specialized surgical instruments and equipment are required to perform wrist arthroscopy, surgeons require training in the arthroscopic technique, and the costs of surgery may be higher, although inpatient costs are reduced due to a shorter postoperative hospital stay [20].

Conclusions

This retrospective clinical study on the surgical management of patients with carpal tunnel syndrome was conducted at a single center. The findings showed that wrist arthroscopy and small incision surgery significantly reduced the damage to the skin, palmar aponeurosis, muscles of the hand, cutaneous nerves,

and blood vessels, when compared with conventional open carpal tunnel release surgery. Arthroscopic wrist surgery resulted in significantly less postoperative pain, leading to a reduced length of hospital stay and improved functional recovery when compared with conventional surgery. From the findings from the experience of this center, selection of the surgical procedure should be individualized for each patient with carpal tunnel syndrome to obtain the optimal therapeutic effect with the least risk of surgical complications.

Conflict of interest

None.

References:

1. Thatté MR, Mansukhani KA: Compressive neuropathy in the upper limb. *Indian J Plast Surg*, 2011; 44(2): 283–97
2. Raducha JE, Gil JA, Defroda SF: An evidence-based approach to the differentiation of compressive neuropathy from polysensory neuropathy in the upper extremity. *JBJS Rev*, 2017; 5(16): e9
3. Tapadia M, Mozaffar T, Gupta R: Compressive neuropathies of the upper extremity: Pathophysiology, classification, electrodiagnostic findings. *J Hand Surg Am*, 2010; 35(4): 668–77
4. Mcdowell D: Endoscopic carpal tunnel release in Jamaica-seven years experience. *West Indian Med J*, 2012; 61(2): 158–62
5. Kim H S, Joo S H, Han ZA: The nerve/tunnel index: A new diagnostic standard for carpal tunnel syndrome using sonography: A pilot study. *J Ultrasound Med*, 2012; 31(1): 23–29
6. Beck JD, Deegan JH, Rhoades D et al: Results of endoscopic carpal tunnel release relative to surgeon experience with the Agee technique. *J Hand Surg Am*, 2011; 36(1): 61–64
7. Sayegh ET, Strauch RJ: Open versus endoscopic carpal tunnel release: A meta-analysis of randomized controlled trials. *Clin Orthop Relat Res*, 2015; 473(3): 1120–32
8. Chen L, Duan X, Huang X et al: Effectiveness and safety of endoscopic versus open carpal tunnel decompression. *Arch Orthop Trauma Surg*, 2014; 134(4): 585–93
9. Ayeni O, Thoma A, Haines T et al: Analysis of reporting return to work in studies comparing open with endoscopic carpal tunnel release: A review of randomized controlled trials. *Can J Plast Surg*, 2005; 13(4): 181–87
10. Żyłuk A, Puchalski P, Walaszek I: A Comparison of the efficacy of a local vs. brachial plexus block anaesthesia in the carpal tunnel release: The results of a prospective and randomised trial. *Polish J Surg*, 2008; 80(11): 615–20
11. Nabhan A, Steudel WI, Dedeman L: Subcutaneous local anesthesia versus intravenous regional anesthesia for endoscopic carpal tunnel release: A randomized controlled trial. *J Neurosurg*, 2011; 114(1): 240–44
12. Madbouly K, Alshahrani S, Al-Omair T: Efficacy of local subcutaneous anesthesia versus intramuscular opioid sedation in extracorporeal shockwave lithotripsy: A randomized study. *J Endourol*, 2011; 25(5): 845–49
13. Atroshi I, Hofer M, Larsson GU: Extended follow-up of a randomized clinical trial of open vs. endoscopic release surgery for carpal tunnel syndrome. *JAMA*, 2015; 314(13): 1399–401
14. Shahrokh HD, Kashipazha D, Rahim F et al: Diagnostic accuracy of ultrasound findings in patients with carpal tunnel syndrome. *J Med Sci*, 2015; 15(2): 94–99
15. Kang HJ, Koh IH, Lee TJ et al: Endoscopic carpal tunnel release is preferred over mini-open despite similar outcome: A randomized trial. *Clin Orthop Relat Res*, 2013; 471(5): 1548–54
16. Silverstein BA, Fine LJ, Armstrong TJ: Occupational factors and carpal tunnel syndrome. *Am J Ind Med*, 2010; 11(3): 343–58
17. Michelotti B, Romanowsky D, Hauck RM: Prospective, randomized evaluation of endoscopic versus open carpal tunnel release in bilateral carpal tunnel syndrome: An interim analysis. *Ann Plast Surg*, 2014; 73(Suppl. 2): S157
18. Saw NL, Jones S, Shepstone L: Early outcome and cost-effectiveness of endoscopic versus open carpal tunnel release: A randomized prospective trial. *J Hand Surg Br*, 2003; 28(5): 444–49
19. Li M, Qiu J, Qi H: Endoscopic enucleation versus open prostatectomy for treating large benign prostatic hyperplasia: A meta-analysis of randomized controlled trials. *PLoS One*, 2014; 10(3): e0121265
20. Vasiliadis HS, Xenakis TA, Mitsionis G et al: Endoscopic versus open carpal tunnel release. *Arthroscopy*, 2010; 26(1): 26–33