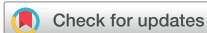



Since January 2020 Elsevier has created a COVID-19 resource centre with free information in English and Mandarin on the novel coronavirus COVID-19. The COVID-19 resource centre is hosted on Elsevier Connect, the company's public news and information website.

Elsevier hereby grants permission to make all its COVID-19-related research that is available on the COVID-19 resource centre - including this research content - immediately available in PubMed Central and other publicly funded repositories, such as the WHO COVID database with rights for unrestricted research re-use and analyses in any form or by any means with acknowledgement of the original source. These permissions are granted for free by Elsevier for as long as the COVID-19 resource centre remains active.



# Traumatic Nonmissile Penetrating Transnasal Anterior Skull Base Fracture and Brain Injury with Cerebrospinal Fluid Leak: Intraoperative Leak Detection and an Effective Reconstruction Procedure for a Localized Skull Base Defect Especially After Coronavirus Disease 2019 Outbreak

Yuichiro Yoneoka<sup>1</sup>, Naotaka Aizawa<sup>2</sup>, Yoriko Nonomura<sup>2</sup>, Manabu Ogi<sup>2</sup>, Yasuhiro Seki<sup>1</sup>, Katsuhiko Akiyama<sup>1</sup>

## Key words

- Cerebrospinal fluid leakage
- COVID-19 era
- Endonasal endoscopic repair
- Fat-on-fascia graft
- Fluorescein
- Skull base defect
- Traumatic nonmissile penetrating transnasal skull base fracture

## Abbreviations and Acronyms

**COVID-19:** Coronavirus disease 2019

**CSF:** Cerebrospinal fluid

**FFG:** Fat-on-fascia graft

From the Departments of <sup>1</sup>Neurosurgery and <sup>2</sup>Otorhinolaryngology, Uonuma Institute of Community Medicine, Niigata University Medical and Dental Hospital, Niigata, Japan

To whom correspondence should be addressed:

Yuichiro Yoneoka, M.D., Ph.D.

[E-mail: [yone@bri.niigata-u.ac.jp](mailto:yone@bri.niigata-u.ac.jp)]

Citation: *World Neurosurg.* (2020) 140:166–172.

<https://doi.org/10.1016/j.wneu.2020.05.236>

Journal homepage: [www.journals.elsevier.com/world-neurosurgery](http://www.journals.elsevier.com/world-neurosurgery)

Available online: [www.sciencedirect.com](http://www.sciencedirect.com)

1878-8750/\$ - see front matter © 2020 Elsevier Inc. All rights reserved.

## INTRODUCTION

Intracranial penetrating injury through the nose is uncommon.<sup>1</sup> Among these types of injuries, transnasal penetration by a nonmissile foreign body is rare.<sup>2</sup> Cerebrospinal fluid (CSF) leakage after a penetrating skull injury is also relatively rare compared with the incidence after a closed head injury involving a skull base fracture.<sup>3</sup> Transnasal penetrating brain injuries, albeit rare, are a medical emergency and should be treated promptly,<sup>4</sup> whether or not CSF leak is present.

In the present report, we have described a case of traumatic nonmissile penetrating transnasal anterior skull base fracture and

■ **BACKGROUND:** Cerebrospinal fluid (CSF) leakage after penetrating skull base injury is relatively rare compared with close head injuries involving skull base fractures.

■ **CASE DESCRIPTION:** We report the case of a 65-year-old man who had presented with epistaxis and serous rhinorrhea. When he had fallen to the ground near his bee boxes, a garden pole had poked into his right nostril. He had instantly removed the pole from his nostril himself. However, immediately after removal of the pole, he had developed nasal bleeding and serous rhinorrhea. He then drove to our emergency room. Computed tomography showed pneumocephalus with a minor cerebral contusion in the left frontal lobe and a penetrating injury in the left anterior skull base. His CSF leakage had not resolve spontaneously within 1 week after the injury with strict bed rest. We repaired the CSF leakage using a fat (adipose tissue)-on-fascia autograft plug and caulked the defect in the anterior skull base with the fat-on-fascia graft (FFG) plug through the left nostril with endoscopic guidance. The CSF rhinorrhea was successfully controlled. Intranasal local application of fluorescein aided in the detection of the direction of flow of the CSF leakage.

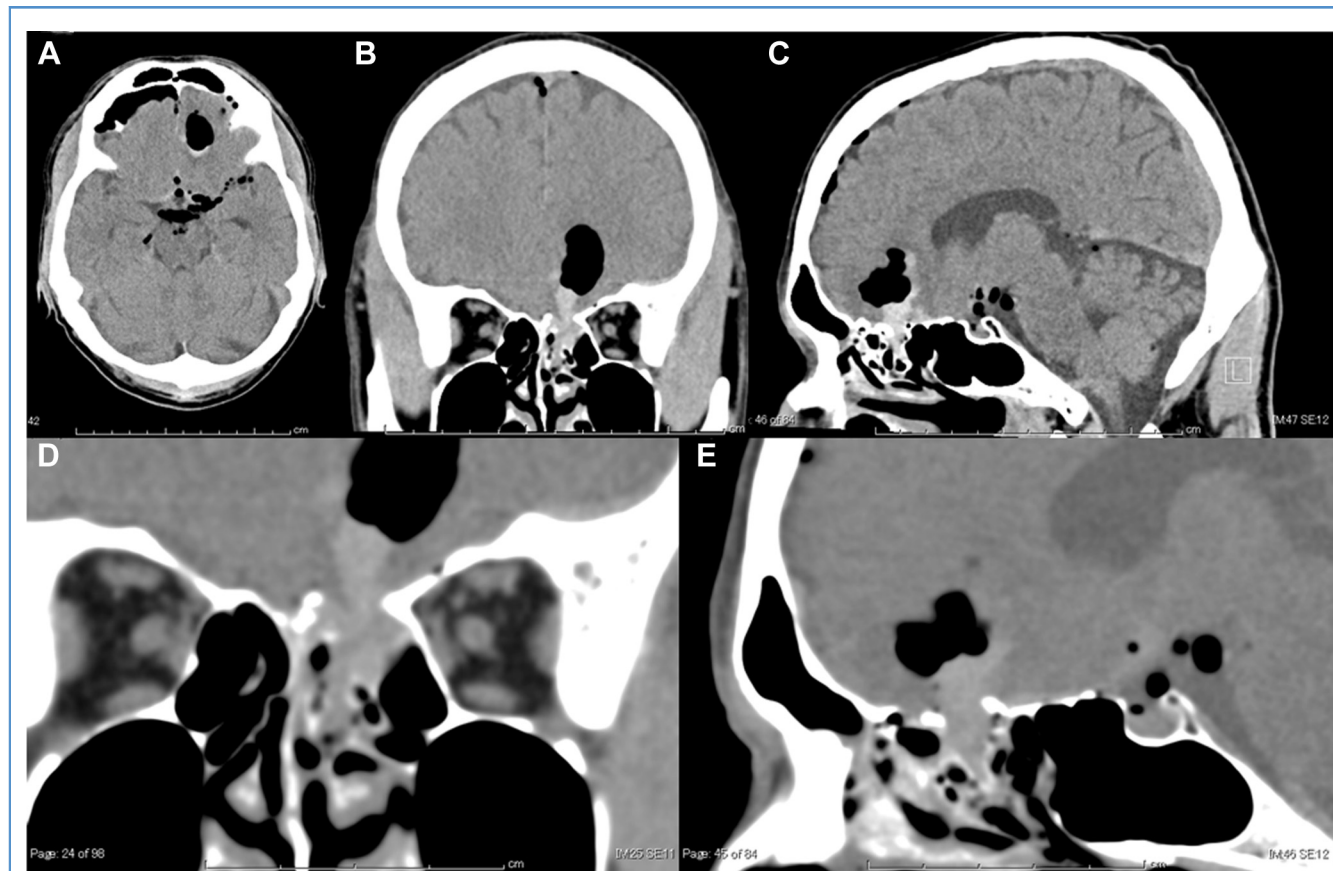
■ **CONCLUSIONS:** Endonasal endoscopic caulking of a skull base defect using an FFG plug can be useful to treat CSF leakage due to the localized skull base defect, especially in the coronavirus disease 2019 pandemic. It is simple, inexpensive, and timesaving. It requires no special skills nor sophisticated instruments that can cause aerosolization, reducing the risk of infection during the surgery.

brain injury with CSF leakage. We have demonstrated a simple method for intraoperative CSF leak detection and an effective reconstruction procedure for a localized skull base defect using a fat-on-fascia graft (FFG). Both methods are available without any special equipment required to improve the efficiency of reconstructive procedures. Specifically, we have introduced a practical closure method using an FFG plug for a localized skull base defect based on our experience,<sup>5–9</sup> especially in the coronavirus disease 2019 (COVID-19) era. The method is simple, inexpensive, and timesaving. It requires no special skills nor sophisticated instruments that can cause aerosolization,

reducing the risk of infection during the surgery.

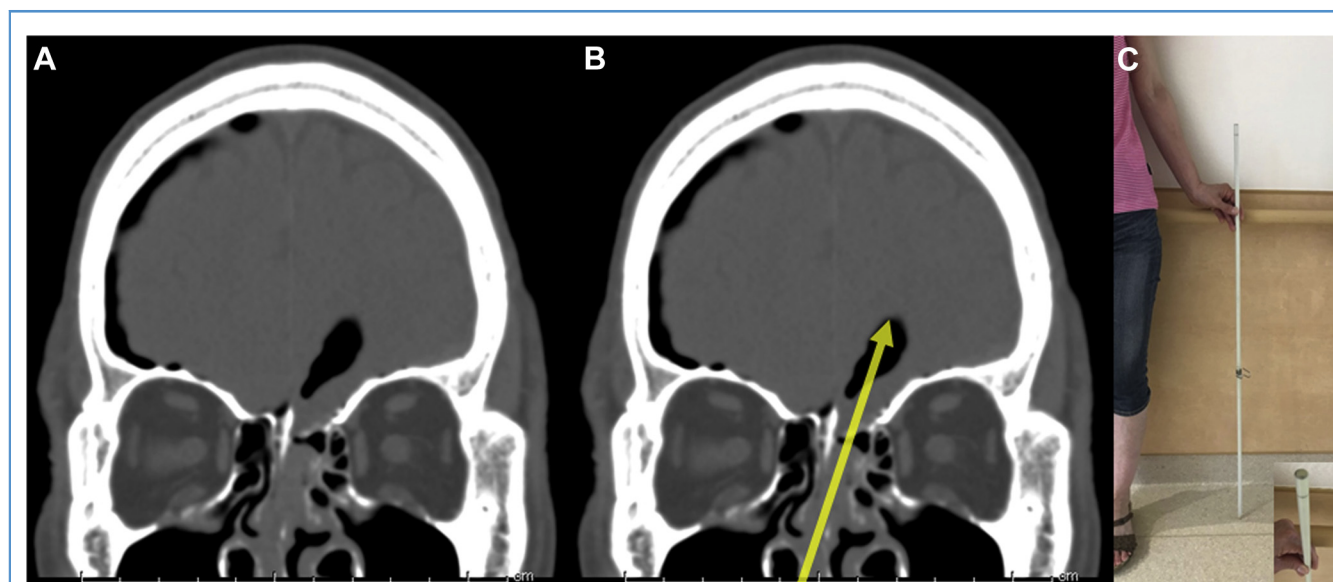
## CASE DESCRIPTION

A 65-year-old man had presented to the emergency department with a 30-minute history of epistaxis and serous rhinorrhea. He had fallen to the ground near his bee boxes. At that time, a garden pole had poked into his right nostril. He had instantly removed the pole from his nostril by himself. Immediately after removal of the pole, he had developed some nasal bleeding and serous rhinorrhea. He had driven to our emergency department by



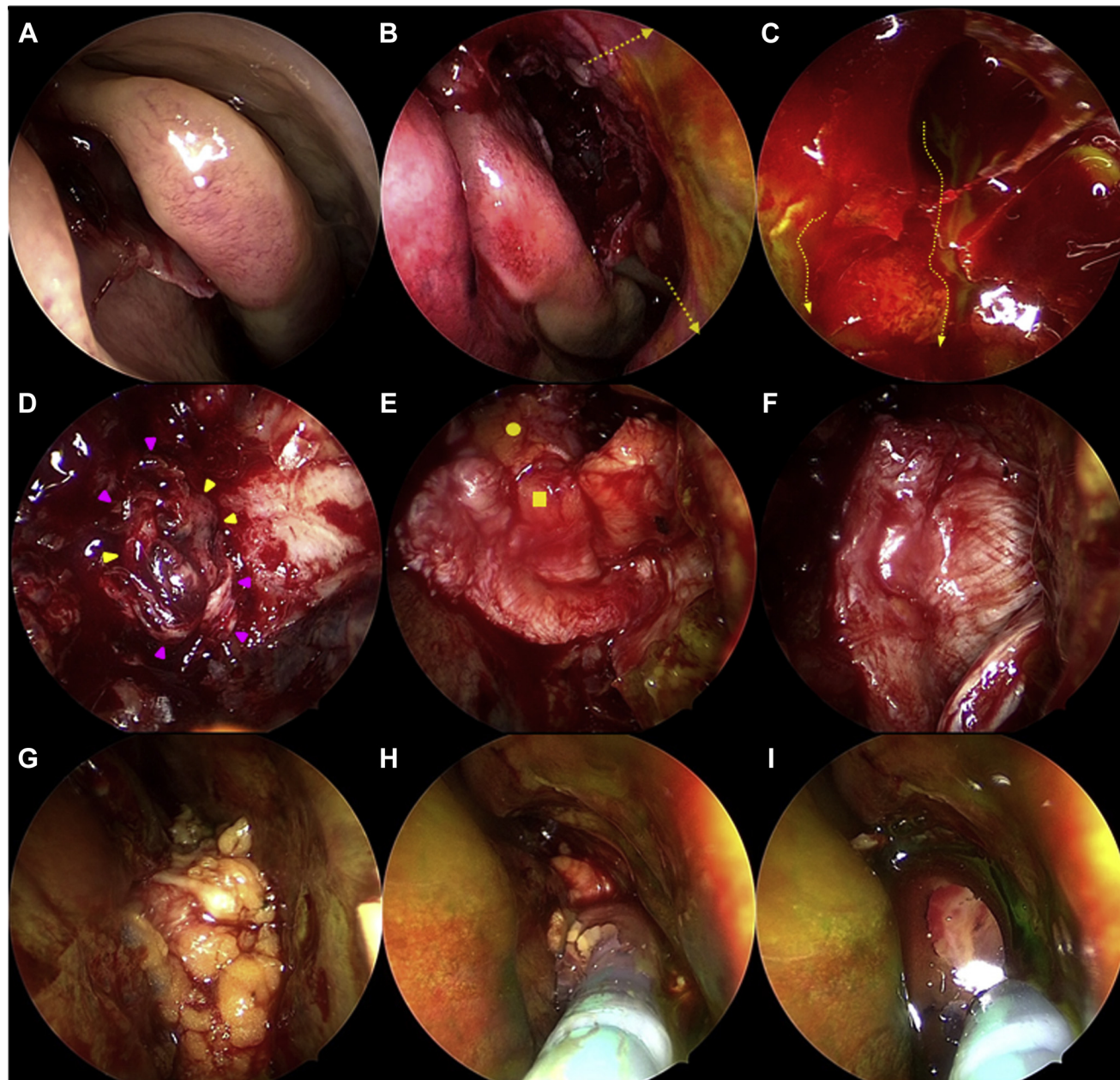
**Figure 1.** Multiplanar reconstruction images of cranial computed tomography scan showing (A) pneumocephalus and intracerebral air retention in the left frontal lobe and (B, C) intracerebral air retention in the left frontal lobe adjoining the cerebral contusion with some hemorrhage

present. (D, E) The left cribriform was pierced. The pole had penetrated through the left cribriform plate from the left ethmoid sinus to the left frontal lobe.



**Figure 2.** The intraoperative findings showed that the pole had (A) traveled through the nasal septum from the right to the left and (B) pierced the left cribriform place from the left ethmoid sinus to the left frontal lobe (yellow

arrow). (C) The patient's wife had brought us the pole that had penetrated the left anterior skull base.



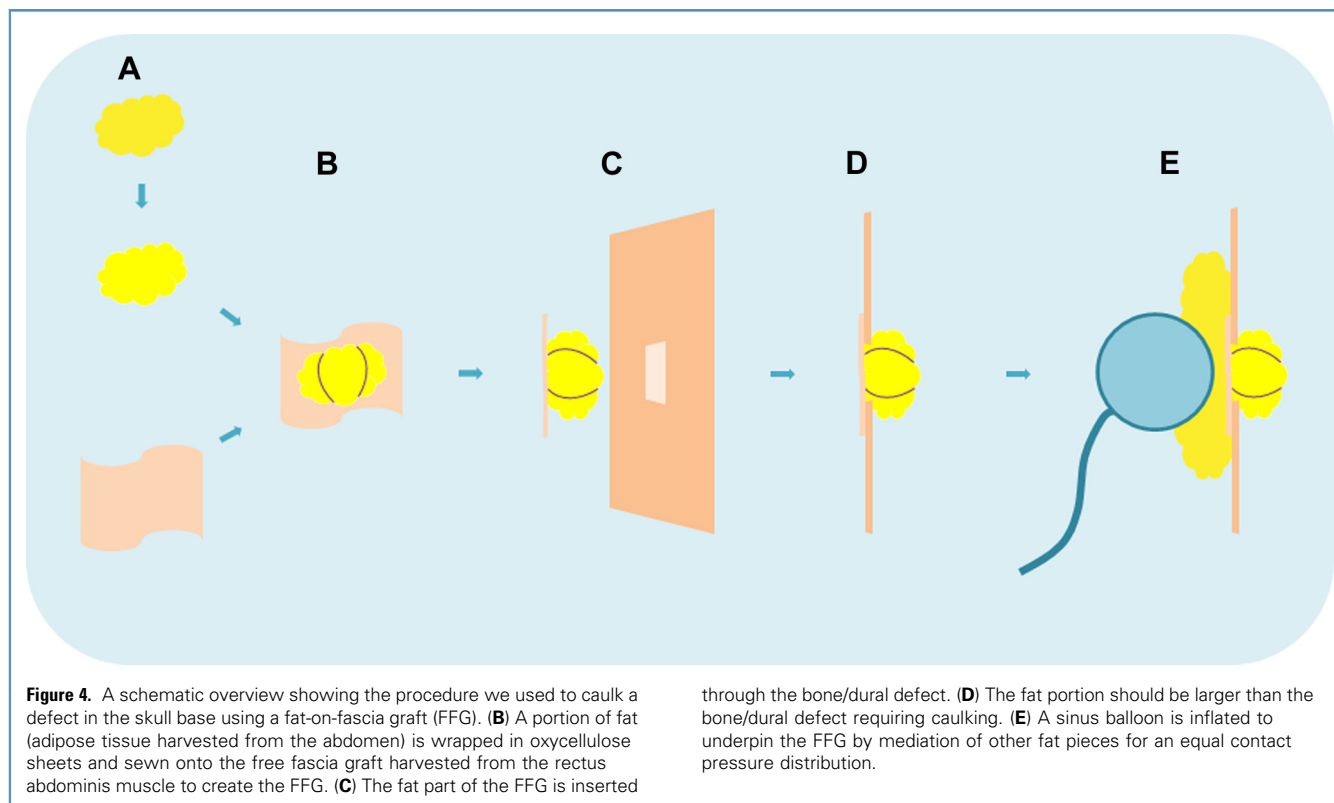
**Figure 3.** Intraoperative endoscopic views of (A) the left nasal cavity showing perforation of the nasal septum from the right to left; and (B) local intranasal application of fluorescein to detect the flow direction of the cerebrospinal fluid (CSF) leakage (broken straight arrows). (C) The yellowish streams clearly demonstrated the CSF leakage (broken tortuous arrows). (D) Tracing these yellowish streams determined the origin of the CSF leakage. At the origin of CSF leakage, the damaged brain tissue (yellow triangles) and torn dura (magenta triangles) had protruded through

the perforated cribriform plate. (E) A fat-on-fascia graft (FFG) was brought to the skull defect. The fat (adipose tissue) part (circle), which had been sewn onto the free fascia graft (square), was inserted to the intradural space through the skull defect. The fascia graft (square) was constrained by the inserted fat portion (circle) and caulked the CSF leak well. (F) Another fascia graft was placed to cover the caulked FFG. (G) A portion of fat (adipose tissue) was placed on the fascia. (H, I) A sinus balloon was inserted and inflated to support the placed FFG through the fat portion.

himself because the nasal bleeding and serous rhinorrhea had continued. The patient's medical history was unremarkable. He had been in his usual state of

good health until the occurrence of this injury. In the emergency department of our hospital, the patient reported no vision changes, diplopia, dysarthria,

numbness, tingling, weakness, cough, dyspnea, abdominal pain, vomiting, diarrhea, or dysuria. He had not experienced fatigue, pharyngitis, joint stiffness, joint



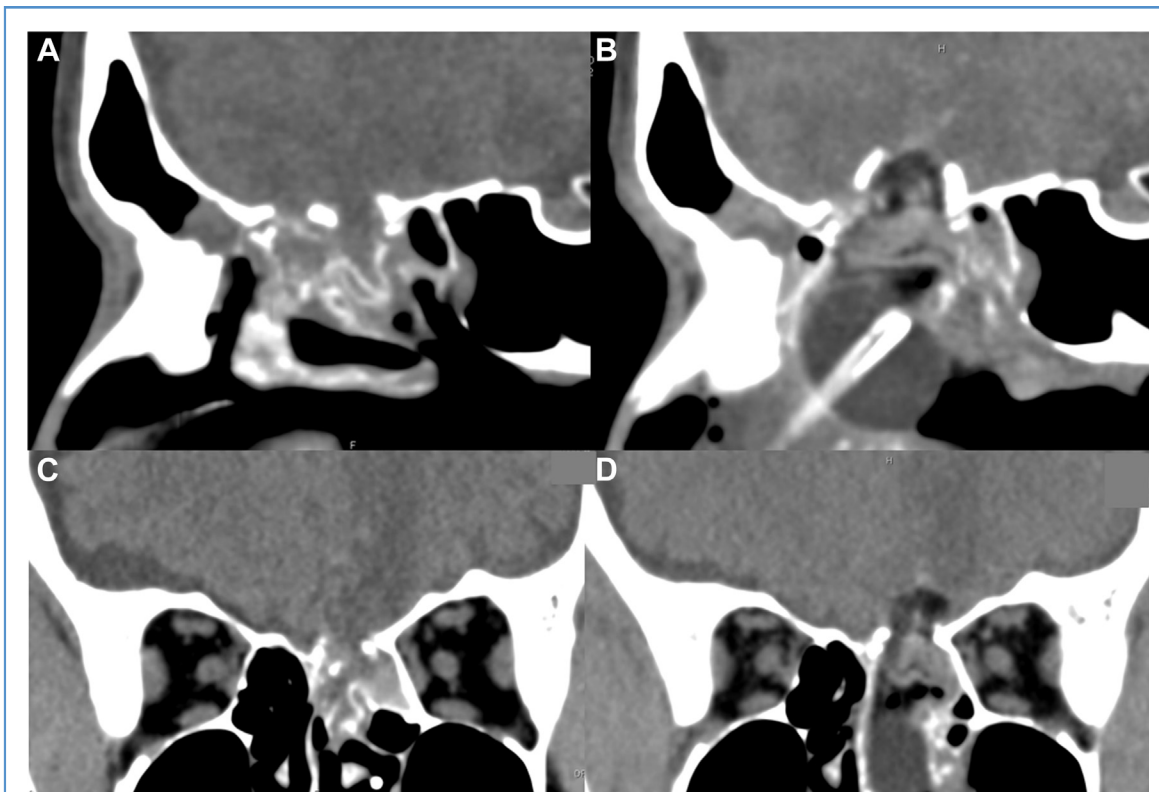
swelling, or myalgia. On examination in the emergency department, the patient was alert, cooperative, and oriented. His vital signs were normal. His weight was 68.4 kg, his height was 170.2 cm, and his body mass index was 23.6 kg/m<sup>2</sup>. The nasal bleeding and serous rhinorrhea appeared intermittently on exertion. Computed tomography showed pneumocephalus with a minor cerebral contusion in the left frontal lobe and a penetrating injury in the left anterior skull base (Figure 1). Symptoms of infection, such as pyrexia, nuchal stiffness, purulent rhinorrhea, or purulent otorrhea, were not observed. As the first step in the treatment of the skull base injury with CSF leak, the patient expressed a desire for conservative treatment.<sup>5</sup> Thus, he was prescribed 1 week of complete bed rest, and piperacillin (2 g 3 times daily) was administered prophylactically. He declined placement of a lumbar subarachnoid CSF drainage tube at the start of the conservative treatment. However, his CSF leakage had not resolved spontaneously within 1 week after the injury with strict bed rest.

During the conservative rest therapy, the patient selected endonasal and endoscopic repair as the less-invasive procedure. We presumed that the pole had entered into the right nostril, crossed the nasal septum obliquely, and penetrated the left cribriform plate into the right frontal lobe (Figure 2A, B). The direction of the pole penetrating his anterior skull base was identified, which enhanced the surgical reconstruction of the skull base (Figure 2C). We repaired the CSF leakage using a fat (adipose tissue)-on-fascia autograft plug and caulked the defect in the anterior skull base with the fat-on-fascia graft (FFG) plug through the left nostril with endoscopic guidance (Figure 3). The fat and fascia grafts were both harvested from the subumbilical abdominal region. We assembled the FFG plug outside the nostril just before performing the endoscopic-guided caulking (Figure 4). Intranasal local application of fluorescein aided in the detection of the flow direction of the CSF leakage (Figure 3B, C). The CSF rhinorrhea was successfully controlled (Figure 5B, D). A lumbar CSF

drainage tube was not inserted. The patient could walk to the bathroom the day after surgery after an overnight of rest. His activity of daily living had increased enough that he could leave the hospital within 2 days. The sinus balloon was removed at 14 days postoperatively. He left the hospital without sequelae, except for mild sinusitis, which had improved within 3 months after discharge. A follow-up computed tomography scan showed complete reconstruction of the anterior skull base defect even after 6 months (Figure 6). The patient had not experienced any relapse of the CSF leak at 16 months after reconstruction using the FFG plug and had completely returned to his responsibilities of beekeeping.

## DISCUSSION

Transnasal intracranial penetrating injury is rare.<sup>6</sup> Transnasal and transorbital penetrating foreign body injuries are relatively uncommon. However, when they do occur, they require rapid workup and interdisciplinary management to

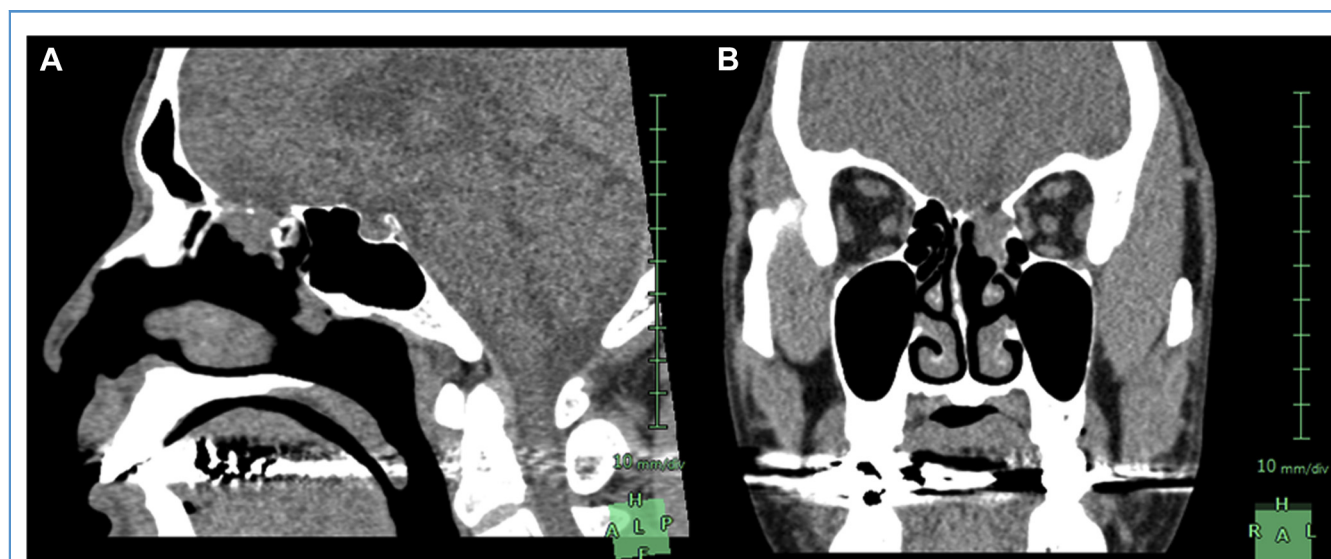


**Figure 5.** (A) The bone/dural defect in the anterior skull base was (B) caulked using the fat-on-fascia graft (FFG). The inflated sinus balloon supports the FFG from below. (C) The bone/dural defect in the left cribriform plate was (D) filled by the FFG.

prevent acute and delayed complications.<sup>7</sup> We used a FFG plug to repair a localized anterior skull base defect caused by a

traumatic nonmissile penetrating injury, which performed well, with long-term stability. Our previous experience<sup>8-12</sup> and

the results from the present report have shown that FFG plugs are effective, inexpensive, safe, and usable for any surgeon



**Figure 6.** (A,B) Follow-up computed tomography scans showing persistence of the closure using the fat-on-fascia graft 6 months after treatment.

without requiring special skills or instrumentation.

In 2020, the novel coronavirus, severe acute respiratory coronavirus 2, and its infection, COVID-19, quickly became a worldwide threat to health, travel, and commerce.<sup>13</sup> International experience with COVID-19 has suggested that it poses a significant risk of infectious transmission to skull base surgeons owing to the high nasal viral titers and the unknown potential for aerosol generation during endonasal instrumentation. Endonasal endoscopic caulking of a skull base defect using an FFG plug is useful for CSF leakage resulting from a localized skull base perforation or penetration defect, especially during the COVID-19 era. The FFG plug is simple, inexpensive, and timesaving and does not require special skills or instrumentation. Although several reconstruction procedures have been reported,<sup>14-19</sup> the use of an FFG plug shortens the operation time, reducing the risk of infection and the risk of aerosolization during the surgery.<sup>20</sup> Specifically, the minimal intranasal submucosal dissection reduces the operative time and the risk of virus “aerosolization.” In addition, the described FFG plug method does not require the placement of a mucosal pedicle flap, which also reduces the operative time and the risk of virus aerosolization.

An FFG plug is created as a free autograft. The fat (adipose tissue) and fascia can both be harvested from the abdomen. A piece of fat is wrapped with a seat of oxycellulose cotton, placed, and sewn on a free fascia graft using absorbable sutures. The piece of fat should be somewhat larger than the dural/bone defect that will be caulked with the FFG. The method of making an FFG is summarized in **Figure 4**. No special skills nor sophisticated instruments are required to perform the FFG plug method (**Figure 4**). This FFG plug method does not require the availability of sophisticated instruments to perform the surgical procedure, reducing the cost. Also, lumbar CSF drainage tube is required, which will shorten the hospitalization period and associated medical costs. Appropriate discharge guidance has enabled us to remove the sinus balloon on an outpatient basis.

The key to successful management of CSF leakage is to precisely identify the site of the dural tear.<sup>21,22</sup> To help localize the site and extent of the leaks better, some investigators have advocated the use of intraoperative fluorescein.<sup>23,24</sup> In our patient, we applied intraoperative fluorescein near the site of the dural tear and defect and identified the CSF current or flow on the mucosa in the nasal cavity. Local application of fluorescein helped to better localize the site and the extent of the CSF leakage, although it was not administered intrathecally (**Figure 3B, C**).

## CONCLUSIONS

Endonasal endoscopic caulking of a skull base defect using an FFG plug is useful for controlling CSF leakage resulting from a localized skull base defect, especially during the COVID-19 outbreak because of its simplicity, with no requirements for special skills or sophisticated instruments. Intranasal local application of fluorescein aided in the detection of the direction of flow of the CSF leakage.

## REFERENCES

- Cetinkaya EA, Okan C, Pelin K. Transnasal, intracranial penetrating injury treated endoscopically. *J Laryngol Otol*. 2006;120:325-326.
- Nguyen HS, Oni-Orisan A, Doan N, Mueller W. Transnasal penetration of a ballpoint pen: case report and review of literature. *World Neurosurg*. 2016;96:611.e1-611.e10.
- Teng TS, Ishak NL, Subha ST, Bakar SA. Traumatic transnasal penetrating injury with cerebral spinal fluid leak. *EXCLI J*. 2019;18:223-228.
- Yücel A, Yücel H, Güllüev M, Alataş N. Transnasal endoscopic removal of a knife causing penetrating brain injury in a child. *J Craniofac Surg*. 2018;29:e694-e695.
- Bai W, Shao C, Sun W, Ha PK, Califano JA, Cao Z. Conservative management of transnasal intracranial injury. *Am J Otolaryngol*. 2011;32:165-167.
- Lee DH, Seo BR, Lim SC. Endoscopic treatment of transnasal intracranial penetrating foreign body. *J Craniofac Surg*. 2011;22:1800-1801.
- Ghadersohi S, Ference EH, Detwiller K, Kern RC. Presentation, workup, and management of penetrating transorbital and transnasal injuries: a case report and systematic review. *Am J Rhinol Allergy*. 2017;31:29-34.
- Jinguji S, Nishiyama K, Yoshimura J, et al. Endoscopic biopsies of lesions associated with a thickened pituitary stalk. *Acta Neurochir (Wien)*. 2013;155:119-124.
- Yoneoka Y, Watanabe N, Okada M, Fujii Y. Observation of the neurohypophysis, pituitary stalk, and adenohypophysis during endoscopic pituitary surgery: demonstrative findings as clues to pituitary-conserving surgery. *Acta Neurochir*. 2013;155:1049-1055.
- Yoneoka Y, Watanabe N, Kohno M, Satoh D, Takahashi H, Fujii Y. Endoscopic resection of a dermoid cyst anchored to the anterior optic chiasm. *Interdiscipl Neurosurg*. 2014;1:21-25.
- Yoneoka Y, Okada M, Watanabe N, Aoki S, Kakita A, Fujii Y. Ectopic pituitary null cell adenoma arising from the infundibulum in the third ventricle: a successful endonasal transsphenoidal resection after long-term follow-up MR imaging—a technical note. *Interdiscipl Neurosurg*. 2017;10:122-125.
- Yoneoka Y, Yoshimura J, Sano M, Okada M, Kakita A, Fujii Y. Third ventricle germ cell tumor originating from the infundibulum with rapidly expansive enlargement. *Pediatr Neurosurg*. 2018;53:49-54.
- Giwa AL, Desai A, Duca A. Novel 2019 coronavirus SARS-CoV-2 (COVID-19): an overview for emergency clinicians. *Pediatr Emerg Med Pract*. 2020;17:1-24.
- Kassam A, Carrau RL, Snyderman CH, Gardner P, Mintz A. Evolution of reconstructive techniques following endoscopic expanded endonasal approaches. *Neurosurg Focus*. 2005;19:E8.
- Gardner P, Kassam A, Snyderman C, Mintz A, Carrau R, Moossy JJ. Endoscopic endonasal suturing of dural reconstruction grafts: a novel application of the U-Clip technology. Technical note. *J Neurosurg*. 2008;108:395-400.
- Virgin F, Barañano CF, Riley K, Woodworth BA. Frontal sinus skull base defect repair using the pedicled nasoseptal flap. *Otolaryngol Head Neck Surg*. 2011;145:338-340.
- Saafan ME, Albirmawy OA, Tomoum MO. Sandwich grafting technique for endoscopic endonasal repair of cerebrospinal fluid rhinorrhoea. *Eur Arch Otorhinolaryngol*. 2014;271:1073-1079.
- Patron V, Roger V, Moreau S, Babin E, Hitier M. State of the art of endoscopic frontal sinus cerebrospinal fluid leak repair. *Eur Ann Otorhinolaryngol Head Neck Dis*. 2015;132:347-352.
- Jahanshahi J, Zeinalizadeh M, Reza Mohammadi H, Sadrehosseini SM. Endonasal endoscopic management of frontal sinus cerebrospinal fluid leak. *Am J Rhinol Allergy*. 2017;31:406-411.
- Workman AD, Welling DB, Carter BS, et al. Endonasal instrumentation and aerosolization risk in the era of COVID-19: simulation, literature review, and proposed mitigation strategies [e-pub ahead of print]. *Int Forum Allergy Rhinol* <https://doi.org/10.1002/alr.22577>. Accessed April 3, 2020.
- Oakley GM, Alt JA, Schlosser RJ, Harvey RJ, Orlandi RR. Diagnosis of cerebrospinal fluid rhinorrhea: an evidence-based review with recommendations. *Int Forum Allergy Rhinol*. 2016;6:8-16.

22. Oh JW, Kim SH, Whang K. Traumatic cerebrospinal fluid leak: diagnosis and management. *Korean J Neurotrauma*. 2017;13:63-67.
23. Locatelli D, Rampa F, Acchiardi I, Bignami M, De Bernardi F, Castelnuovo P. Endoscopic endonasal approaches for repair of cerebrospinal fluid leaks: nine-year experience. *Neurosurgery*. 2006;58(suppl 2):ONS246-ONS256.

24. Le C, Strong EB, Luu Q. Anterior skull base cerebrospinal fluid leaks. *J Neurol Surg B Skull Base*. 2016;77:404-411.

*Conflict of interest statement: The authors declare that the article content was composed in the absence of any commercial or financial relationships that could be construed as a potential conflict of interest.*

*Received 9 May 2020; accepted 25 May 2020*

*Citation: World Neurosurg. (2020) 140:166-172.*

*<https://doi.org/10.1016/j.wneu.2020.05.236>*

*Journal homepage: [www.journals.elsevier.com/world-neurosurgery](http://www.journals.elsevier.com/world-neurosurgery)*

*Available online: [www.sciencedirect.com](http://www.sciencedirect.com)*

*1878-8750/\$ - see front matter © 2020 Elsevier Inc. All rights reserved.*