Clinical and genetic characteristics of pyridoxine-dependent epilepsy: Case series report of three Chinese patients with phenotypic variability

SANMEI WANG, JING SUN, YAO TU, LINA ZHU and ZHICHUN FENG

National Engineering Laboratory for Birth Defects Prevention and Control of Key Technology, Beijing Key Laboratory of Pediatric Organ Failure, Affiliated Bayi Children's Hospital, General Military Hospital of Beijing PLA, Beijing 100700, P.R. China

Received July 8, 2016; Accepted April 28, 2017

DOI: 10.3892/etm.2017.4735

Abstract. Pyridoxine-dependent epilepsy (PDE) is a rare disorder caused by aldehyde dehydrogenase 7 family member A1 (ALDH7A1) deficiency. The present study reported on three Chinese cases of PDE with phenotypic variability for providing further insight into this disease. All three patients presented with recurrent seizures and readily responded to treatment with pyridoxine, in line with the typical symptomology of PDE. The three cases varied in their clinical manifestations with regard to the time of onset, seizure type, EEG findings and mental development. Four ALDH7A1 mutations were identified in Case 1 (c.1008+1G>A and c.871+5G>A) and Case 2 (c.977A>G and c.1463A>G). To the best of our knowledge, the present study was the first to report on the mutations c.871+5G>A and c.1463A>G. Early definitive diagnosis and timely treatment with pyridoxine was the cornerstone of management of PDE. Timely treatment was associated with excellent prognosis. A high index of suspicion in cases and early genetic testing may facilitate early diagnosis of this rare disease.

Introduction

Pyridoxine-dependent epilepsy (PDE) is a clinical disorder caused by a deficiency of aldehyde dehydrogenase 7 family member A1 (ALDH7A1), which typically presents in infancy or early childhood (1,2). The disease is characterized by intractable seizures that are non-responsive to conventional anti-epileptic treatments, but respond, clinically as well as electroencephalographically, to large doses of pyridoxine (vitamin B6) (3). Over 200 cases of PDE have been documented since its first description in 1954 (1). Long-term follow-up studies are rare owing to the wide temporal and spatial dispersion of cases. Most reported cases readily responded to pyridoxine and had a good prognosis (4). Only few Chinese cases of PDE have been reported, all of which had a classical presentation of PDE (5). The present case series was on three Chinese cases of PDE with phenotypic variability, and included clinical presentation, genetic characteristics and follow-up information.

Case report

Ethics and consent. All experiments on human subjects were performed in accordance with the ethical standards of the responsible committee at General Military Hospital of Beijing PLA (Beijing, China) on human experimentation, and with the Declaration of Helsinki from 1964 and its later amendments. Written informed consent was obtained from the parents of each patient.

Case 1. A male patient who was full-term neonate with normal delivery, presented with symptoms of pneumonia occurring 12 h after birth, followed by recurrent seizures with a poor response to conventional anti-epileptic treatment with phenobarbital. Brain computed tomography (CT) revealed a global decrease in signal density. The pneumonia was cured after 10 days of anti-infective treatment; however, intermittent seizures continued to persist. At 21 days after birth, the neonate was referred to the affiliated Bayi Children's Hospital (General Military Hospital of Beijing PLA, Beijing, China). The patient had a family history of self-resolving multiple seizures affecting the patient's grandfather and great grandfather; however, the patient's parents were healthy. Digital video electroencephalography (EEG) displayed diffuse slow and sharp waves with medium-high amplitude in the bilateral frontal and parietal regions, dominant in the right side. The seizure did not recur during 5 days of neurotrophic therapy with oral vitamin

Correspondence to: Dr Sanmei Wang, National Engineering Laboratory for Birth Defects Prevention and Control of Key Technology, Beijing Key Laboratory of Pediatric Organ Failure, Affiliated Bayi Children's Hospital, General Military Hospital of Beijing PLA, 5 Nan Men Cang Hu Tong, Dongcheng, Beijing 100700, P.R. China
E-mail: wangsanmei66@163.com

Key words: pyridoxine dependent epilepsy, aldehyde dehydrogenase 7 family member A1, seizures, pyridoxine

B6 (20 mg/day) and mecobalamin (250 μg/day) and the patient was discharged. When discharged, the patient stopped taking vitamin B6. He was re-hospitalized due to recurrent seizures 12 days after discontinuation of oral vitamin B6. Two days of intravenous administration of vitamin B6 (250 mg/day) appeared to have resolved the seizures. However, EEG still displayed a slow background rhythm and sporadic sharp waves with high amplitude in the left middle temporal region. Considering the poor response to vitamin B6 treatment, levetiracetam (LEV) treatment was started along with vitamin B6 maintenance therapy (100 mg/day). Due to resolution of seizures within 7 days of modified treatment, the patient was discharged, with continuation of oral LEV treatment, but not vitamin B6. Similar seizures reoccurred 11 days after discharge, which poorly responded to several trials of various anti-convulsant drugs, including benzodiazepine, pentobarbital, chloral hydrate and mannitol. The seizure was aborted by nasogastric administration of topiramate (TPM) at a high dose of 8 mg/kg. TPM was gradually decreased to a maintenance level (5 mg/kg/day) and the seizure did not reoccur for 19 days. After discharge, the patient was treated using a combination of anti-epileptic drugs, including LEV, VPA, TPM and vitamin B6, until the age of one year, without seizure re-occurrence. However, at 15 days after withdrawal of vitamin B6, seizures recurred but readily resolved with vitamin B6 (200 mg/day). On clinical suspicion of PDE, genetic testing for ALDH1A1 gene mutations was performed to confirm the diagnosis of PDE.

For genetic testing, genomic DNA was isolated from peripheral white blood cells as described previously (6). Analysis of ALDH1A1 gene mutations was performed as per the methodology described by Scharer *et al* (7). Two heterozygous mutations of shear position variation (c.1008+1G>A and c.871+5G>A) were identified. The c.1008+1G>A mutation has been reported to be associated with the pathogenesis of PDE (5). The other identified mutation has not been documented to date.

After confirmation of PDE diagnosis, the patient was prescribed oral vitamin B6 (15 mg/kg/day) treatment for six months, during which the seizure did not recur. This infant was exclusively sustained by breastfeeding for the first six months with complementary feeding after 6 months. He suffered from mental motor and intelligence retardation.

Case 2. A male full-term neonate with normal delivery developed recurrent seizures from the third day after birth. The severity of seizures increased over time. EEG displayed a slow background rhythm and paroxysmal multifocal sharp or spike-shaped slow waves with high amplitude. The seizures had a poor response to treatment with six different types of anti-epileptic drug (LEV, VPA, TPM, oxcarbazepine, phenobarbital and clonazepam). Seizure episodes continued to recur intermittently and the longest seizure-free period was 5 months on one occasion. The patient did not have any family history of seizures. His gross motor functions developed normally, but the fine motor functions were poorly developed. His language development was retarded, characterized by slow speed and limited vocabulary. At 6 years of age, he scored 60 points on the Wechsler Intelligence Scale for Children-IV (WISC-IV), which indicated mild mental retardation.

The patient was referred to the affiliated Bayi Children's Hospital (General Military Hospital of Beijing PLA, Beijing, China) on April 19, 2014 with a history of recurrent seizures for 7 years and status epilepticus for 2 h. Genetic testing revealed two heterozygous missense mutations (c.977A>G and c.1463A>G) in the ALDH1A1 gene. The c.977A>G mutation has been described previously (8). The seizures resolved and EEG findings were significantly improved after treatment with vitamin B6 (300 mg/day; Fig. 1). The patient was prescribed long-term oral vitamin B6 treatment (10 mg/kg/day) at discharge. He showed significant improvement in exercise capacity and mental status on follow-up assessment at 1 year and the EEG returned to normal. His active language communication also improved and his WISC-IV score improved to 75 points.

Case 3. A male patient was a full-term baby with normal delivery. At the age of 6 months, he suffered from clusters of seizures with a frequency of 3-6 per day. EEG showed hypsarrhythmic waves, which readily responded to intravenous administration of vitamin B6 (100 mg), with concomitant cessation of seizures. Brain magnetic resonance imaging revealed right periventricular leucomalacia involving subcortical white matter, accompanied with signs of gliosis, and observations on CT were in line with this (Fig. 2). The patient was discharged 4 days after admission and maintained on vitamin B6 treatment, with no seizure episode for 3 months. One week after discontinuation of vitamin B6 treatment on behalf of the patient's parents, he was hospitalized with a left limb tic followed by movement disorder for 2 h. After treatment with vitamin B6 (30 mg/kg/day), the seizures resolved. He continued long-term oral vitamin B6 and did not experience any recurrence during follow-up for 2 years. EEG displayed a slow background rhythm and paroxysmal spikes as well as slow waves in the right hemisphere with high amplitude (Fig. 1). His gross movements developed normally, with a slightly clumsy left upper limb. His Gesell Developmental Schedules rating at the age of 2.5 years demonstrated that his language function lagged behind that of healthy children of his age by one year.

Discussion

In the present case series, all three cases had onset of PDE in the neonatal or early infantile period, and presented with recurrent seizures without any obvious cause. In all three cases, seizures were readily ameliorated with vitamin B6, and tended to relapse on withdrawal of vitamin B6, which is consistent with the typical clinical presentation of PDE (9-12). However, all three cases had differences in terms of clinical manifestations including time of onset, seizure type, EEG findings and mental development. Cases 1 and 2 presented with symptoms in the early neonatal period, while Case 3 presented at the age of 6 months. In cases 1 and 2, PDE manifested as recurrent complex partial seizures, with the occurrence of status epilepticus. In Case 3, the onset was characterized by spasm and tended to recur as partial seizures, which were brought on by cessation of vitamin B6 treatment. In addition, case 3 rarely showed hypsarrhythmia on EEG.

Over 60 different gene mutations have been identified in PDE patients (13-15), and missense mutations account

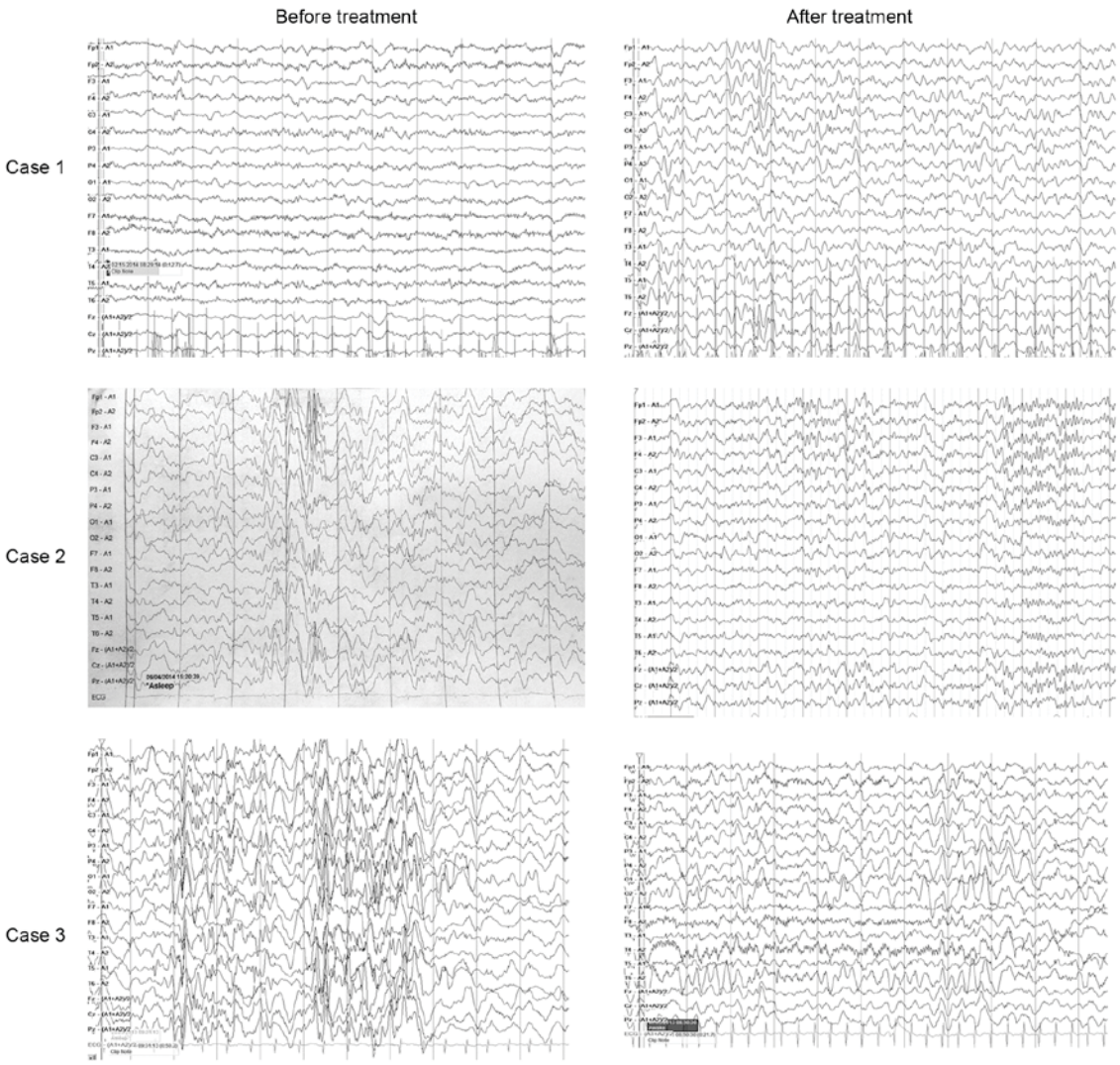

Figure 1. EEGs of the three patients prior to and after pyridoxine treatment. Case 1, slow background rhythm prior to treatment and normal back background rhythm. Case 2, pre-treatment EEG of a varied phenotype manifesting as paroxysmal high-amplitude sharp spikes and multiple-spike slow waves in bilateral temporal region; post-treatment EEG normal. Case 3, poor background rhythm with hypsarrhythmia prior to treatment. Spike and slow waves in the right hemisphere after treatment. EEG, electroencephalogram.

for 50-60% of mutations. The present study reported on two novel mutations of c.871+5G>A and c.1463A>G in the ALDH1A1 gene, which calls for further investigation of their association with the pathogenesis of PDE. Mutations of the pyridoxine-5'-phosphateoxidase (PNPO) gene have previously been identified in certain PDE patients with no mutation of the ALDH7A1 gene (16,17). Therefore, it remains elusive whether case 3 had mutations in the PNPO gene, which may have been accountable for PDE. Although this is a limitation, Case 3 presented with recurrent seizures, which readily responded to pyridoxine treatment, in line with the typical symptomatology of PDE. PDE cases are liable to misdiagnosis or delayed diagnosis. In Cases 1 and 2, the definitive diagnosis was delayed. In Case 1, seizures were resolved only partially after a diagnostic treatment trial with high-dose vitamin B6 for 2 days, which led to a delayed diagnosis. The delayed response to vitamin B6 treatment is probably attributable to frequent seizures, which may have caused brain edema leading to only partial recovery in the short period. The present findings suggested that a minimum of a three-day treatment with vitamin B6 may contribute to the prevention of misdiagnosis. In Case 2, no diagnostic trial of vitamin B6 was performed, which contributed to the delay in diagnosis; consequently, the patient was treated with multiple anti-epileptic drugs. Phenotype variability

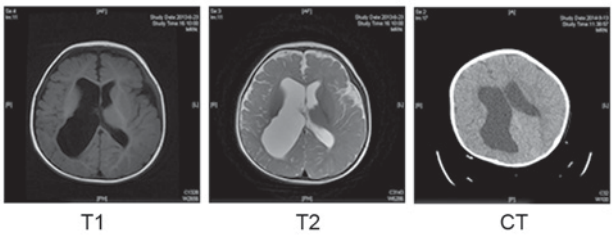

Figure 2. Brain MRI and CT radiograph of Case 3 with pyridoxine-dependent epilepsy. Brain MRI (T1- and T2-weighted imaging) indicated right periventricular leucomalacia involving subcortical white matter, accompanied by gliosis. Brain CT revealed similar results. MRI, magnetic resonance imaging; CT, computed tomography.

is another reason for delayed diagnosis or misdiagnosis of PDE. Approximately one third of all PDE cases are known to present as variable phenotypes, such as late onset of seizures, autism, variability in the initial response to anti-convulsants or response to extremely low doses of pyridoxine (10,18,19). A high index of suspicion and genetic testing in such cases will facilitate early diagnosis.

References

1. Stockler S, Plecko B, Gospe SM Jr, Coulter-Mackie M, Connolly M, van Karnebeek C, Mercimek-Mahmutoglu S, Hartmann H, Scharer G, Struijs E, *et al*: Pyridoxine dependent epilepsy and antiquitin deficiency: Clinical and molecular characteristics and recommendations for diagnosis, treatment and follow-up. Mol Genet Metab 104: 48-60, 2011.
2. Mills PB, Struys E, Jakobs C, Plecko B, Baxter P, Baumgartner M, Willemsen MA, Omran H, Tacke U, Uhlenberg B, *et al*: Mutations in antiquitin in individuals with pyridoxine-dependent seizures. Nat Med 12: 307-309, 2006.
3. Pérez B, Gutiérrez-Solana LG, Verdú A, Merinero B, Yuste-Checa P, Ruiz-Sala P, Calvo R, Jalan A, Marín LL, Campos O, *et al*: Clinical, biochemical, and molecular studies in pyridoxine-dependent epilepsy. Antisense therapy as possible new therapeutic option. Epilepsia 54: 239-248, 2013.
4. Yeghiazaryan NS, Striano P, Spaccini L, Pezzella M, Cassandrini D, Zara F and Mastrangelo M: Long-term follow-up in two siblings with pyridoxine-dependent seizures associated with a novel ALDH7A1 mutation. Eur J Paediatr Neurol 15: 547-550, 2011.
5. Yang Z, Yang X, Wu Y, Wang J, Zhang Y, Xiong H, Jiang Y and Qin J: Clinical diagnosis, treatment, and ALDH7A1 mutations in pyridoxine-dependent epilepsy in three Chinese infants. PLoS One 9: e92803, 2014.
6. Miller SA, Dykes DD and Polesky HF: A simple salting out procedure for extracting DNA from human nucleated cells. Nucleic Acids Res 16: 1215, 1988.
7. Scharer G, Brocker C, Vasiliou V, Creadon-Swindell G, Gallagher RC, Spector E and Van Hove JL: The genotypic and phenotypic spectrum of pyridoxine-dependent epilepsy due to mutations in ALDH7A1. J Inherit Metab Dis 33: 571-581, 2010.
8. Nam SH, Kwon MJ, Lee J, Lee CG, Yu HJ, Ki CS and Lee M: Clinical and genetic analysis of three Korean children with pyridoxine-dependent epilepsy. Ann Clin Lab Sci 42: 65-72, 2012.
9. Yeghiazaryan NS, Zara F, Capovilla G, Brigati G, Falsaperla R and Striano P: Pyridoxine-dependent epilepsy: An under-recognised cause of intractable seizures. J Paediatr Child Health 48: E113-E115, 2012.
10. Grillo E, da Silva RJ and Barbato JH Jr: Pyridoxine-dependent seizures responding to extremely low-dose pyridoxine. Dev Med Child Neurol 43: 413-415, 2001.
11. Baxter P: Epidemiology of pyridoxine dependent and pyridoxine responsive seizures in the UK. Arch Dis Child 81: 431-433, 1999.
12. Bass NE, Wyllie E, Cohen B and Joseph SA: Pyridoxine-dependent epilepsy: The need for repeated pyridoxine trials and the risk of severe electrocerebral suppression with intravenous pyridoxine infusion. J Child Neurol 11: 422-424, 1996.
13. Millet A, Salomons GS, Cneude F, Corne C, Debillon T, Jakobs C, Struys E and Hamelin S: Novel mutations in pyridoxine-dependent epilepsy. Eur J Paediatr Neurol 15: 74-77, 2011.
14. Mills PB, Footitt EJ, Mills KA, Tuschl K, Aylett S, Varadkar S, Hemingway C, Marlow N, Rennie J, Baxter P, *et al*: Genotypic and phenotypic spectrum of pyridoxine-dependent epilepsy (ALDH7A1 deficiency). Brain 133: 2148-2159, 2010.
15. Striano P, Battaglia S, Giordano L, Capovilla G, Beccaria F, Struys EA, Salomons GS and Jakobs C: Two novel ALDH7A1 (antiquitin) splicing mutations associated with pyridoxine-dependent seizures. Epilepsia 50: 933-936, 2009.
16. Mills PB, Surtees RA, Champion MP, Beesley CE, Dalton N, Scambler PJ, Heales SJ, Briddon A, Scheimberg I, Hoffmann GF, *et al*: Neonatal epileptic encephalopathy caused by mutations in the PNPO gene encoding pyridox(am)ine 5'-phosphate oxidase. Hum Mol Genet 14: 1077-1086, 2005.
17. Plecko B, Hoeger H, Jakobs C, Struys E, Stromberger C, Leschnik M, Muehl A and Stoeckler-Ipsiroglu S: Pipecolic acid concentrations in brain tissue of nutritionally pyridoxine-deficient rats. J Inherit Metab Dis 28: 689-693, 2005.
18. Basura GJ, Hagland SP, Wiltse AM and Gospe SM Jr: Clinical features and the management of pyridoxine-dependent and pyridoxine-responsive seizures: Review of 63 North American cases submitted to a patient registry. Eur J Pediatr 168: 697-704, 2009.
19. Goutières F and Aicardi J: Atypical presentations of pyridoxine-dependent seizures: A treatable cause of intractable epilepsy in infants. Ann Neurol 17: 117-120, 1985.