

# Clinical value of radionuclide shuntography by qualitative methods in hydrocephalic adult patients with suspected ventriculoperitoneal shunt malfunction

Szu-Ying Tsai, MD<sup>a</sup>, Shan-Ying Wang, MD<sup>a,b</sup>, Yu-Chien Shiau, MD, PhD<sup>a</sup>, Lin-Hsue Yang, MD<sup>c</sup>, Yen-Wen Wu, MD, PhD<sup>a,d,e,\*</sup>

## Abstract

To determine the clinical value of radionuclide shuntography in the evaluation of adult hydrocephalic patients with suspected ventriculoperitoneal (V-P) shunt malfunction. All adult patients who underwent Tc-99m diethylenetriamine pentaacetic acid shuntographic scans at Far Eastern Memorial Hospital between August 2005 and December 2015 were included. Shuntographic results were visually evaluated in a simple qualitative manner: prompt flow that reached the peritoneum on 30-minute early images and diffuse peritoneal tracer distribution on 2-hour delayed images were interpreted as nonobstructive shunt flow. Partial dysfunction was diagnosed as scintigraphic findings between no obstruction and complete obstruction (where complete malfunction indicated no peritoneal distribution on delayed images). The results were correlated with the clinical outcomes and surgical results within 30 days. Diagnostic sensitivity (Se), specificity (Sp), positive predictive value (PPV), negative predictive value (NPV), and overall accuracy were also calculated. A total of 93 scans in 69 patients with suspected V-P shunt malfunction were analyzed. Sixty-two scans were interpreted as abnormal, including complete (n=26, 41.9) distal obstruction, partial (n=35, 56.5) distal dysfunction, and miscellaneous (n=1, 1.6, cerebrospinal fluid leak). The Se and Sp were 83.0% and 55.0%, respectively, and PPV, NPV, and accuracy were all 71.0%. Twenty-five patients (28 scans) underwent surgical revision, and the results were highly concordant with the imaging findings (Se, 92.0%; Sp, 100.0%; PPV, 100.0%; NPV, 60.0%; and accuracy, 92.9%). Radionuclide shuntography provides useful information in adult patients with V-P shunt malfunction and could be used to guide further surgical intervention.

**Abbreviations:** AUC = areas under the curve, CSF = cerebrospinal fluid, NPV = negative predictive value, PPV = positive predictive value, ROC = receiver operating characteristic, Se = sensitivity, Sp = specificity, V-P = ventriculoperitoneal.

**Keywords:** hydrocephalus, radionuclide shuntography, shunt malfunction, Tc-99m diethylenetriamine pentaacetic acid, ventriculoperitoneal shunt

Editor: Saad Zakko.

Registration number and name of registry: Qualitative Radionuclide Shuntography for Adult Patients With Suspected V-P Shunt Malfunction; NCT02894216.

Funding/support: The study was partially supported by grant MOST 104-2314-B-418-008 from the Ministry of Science and Technology of Taiwan.

Note: The data have presented previously at SNMMI annual meeting 2016 as poster.

The authors have no funding and conflicts of interest to disclose.

<sup>a</sup> Department of Nuclear Medicine, Far Eastern Memorial Hospital, New Taipei City, <sup>b</sup> Department of Biomedical Imaging and Radiological Sciences, National Yang-Ming University, Taipei, <sup>c</sup> Department of Neurosurgery, Far Eastern Memorial Hospital, New Taipei City, <sup>d</sup> National Yang-Ming University School of Medicine, Taipei, <sup>e</sup> Department of Nuclear Medicine, National Taiwan University Hospital and National Taiwan University College of Medicine, Taipei, Taiwan.

\* Correspondence: Yen-Wen Wu, Department of Nuclear Medicine, Far Eastern Memorial Hospital, No. 21, Sec. 2, Nanya S. Rd., Banciao Dist., New Taipei City 220, Taiwan (e-mail: wuyw0502@gmail.com).

Copyright © 2017 the Author(s). Published by Wolters Kluwer Health, Inc. This is an open access article distributed under the terms of the Creative Commons Attribution-Non Commercial-No Derivatives License 4.0 (CCBY-NC-ND), where it is permissible to download and share the work provided it is properly cited. The work cannot be changed in any way or used commercially without permission from the journal.

Medicine (2017) 96:17(e6767)

Received: 3 February 2017 / Received in final form: 16 March 2017 / Accepted: 17 March 2017

<http://dx.doi.org/10.1097/MD.00000000000006767>

## 1. Introduction

Hydrocephalus predominantly affects infants and the elderly and produces significant public health burden. Cerebrospinal fluid (CSF) shunt is the mainstay of management for hydrocephalus. Etiologies such as idiopathic normal pressure hydrocephalus are potentially reversible and could greatly benefit from CSF shunting.<sup>[1–6]</sup> Usually there are 3 segments in shunts: proximal/ventricular catheter, shunt valve, and distal catheter.<sup>[7,8]</sup> Among the different types of shunts, ventriculoperitoneal (V-P) shunts are most commonly performed.<sup>[8,9]</sup>

More than 30% of hydrocephalic patients would develop CSF shunt obstruction within the first year of shunt insertion.<sup>[8,10]</sup> Only half of new shunts could survive the second year, and even less than 1/3 are functional by the 10th year without revision.<sup>[8,11]</sup> When shunt malfunction is suspected, clinical symptoms and increased CSF opening pressure might serve as clues. Anatomical imaging studies, including computed tomography and magnetic resonance image, could detect dilated ventricles; although ventricular dilatation is characteristic, it is not a specific sign. If the above information is equivocal, the functional radionuclide shuntography may be of help.<sup>[12–15]</sup>

Radionuclide shuntography was first described in 1966 by Di Chiro and Grove.<sup>[16]</sup> It is a simple, effective, and low-radiation-dose functional method to assess shunt patency in hydrocephalic patients.<sup>[3,17]</sup> However, related literature is scarce and involves

studies with primarily small sample sizes. There is a lack of guidelines regarding this procedure or consensus on image interpretation,<sup>[12,18]</sup> which considerably limits its clinical applications. Furthermore, the etiologies of hydrocephalus are quite different between pediatric and adult population, and the majorities of previous studies included subjects younger than 18 year-old and in relatively small sample size.

This study aimed to analyze the radionuclide shuntography by a simple qualitative method in a relatively large adult population and to evaluate its clinical value for decision making in patients with suspected V-P shunt malfunction.

## 2. Materials and methods

### 2.1. Study population

The study was approved by the institutional review board of Far Eastern Memorial Hospital. Each patient's written informed consent was waived due to the retrospective nature of the study.

Between August 2005 and December 2015, all hydrocephalic patients who underwent radionuclide shuntography for suspected V-P shunt malfunction at our hospital were retrospectively enrolled in the study. Those patients younger than 18 years of age at the time of examination were excluded. Basic information was collected from medical records, including age, gender, clinical symptoms, and follow-up course. Each patient was followed up for at least 30 days after the index radionuclide shuntography.

Clinical shunt malfunction was determined based on the clinical judgment of the physician and the indication for surgery or shunt pressure adjustment. Cardinal events including surgical intervention, shunt pressure adjustment, and other major conditions such as hospitalization or death due to shunt infection, worsening of neurologic symptoms, and/or hydrocephalus were recorded. Surgical findings regarding the condition of the distal catheter, as documented in operative reports, were sorted into 3 groups: complete obstruction, partial dysfunction (e.g., some clots or adhesion, or catheter kinking), and no significant obstruction, and/or merely pressure-related problem.

### 2.2. Radionuclide shuntography scanning procedure

All patients were placed in the supine position, and marked on the left side of the axilla and iliac crest with a syringe containing trace thallium-201 for localization. After careful aseptic preparation of the scalp over the shunt reservoir, a 25-ga butterfly needle was inserted and approximately 1 mL of CSF was aspirated to confirm the injection site. Tc-99m diethylenetriamine pentaacetic acid, 1.5 to 3 mCi (60–100 MBq), in 0.3 to 0.5 mL sterile water was intrathecally injected via another syringe connected by 3-way connector, followed by slow flush with 0.5 to 0.7 mL of CSF to ensure isovolume and proper introduction.

A low-energy general-purpose collimator (with 15% window centered at 140 keV) was used. The gamma camera moved along the tracer distribution on the initial 30-minute dynamic images; images were collected as 4-second frames for the first minute, and 1-minute frames for the second to the 30th minute. Static whole-body images were obtained as early (30 minutes) and delayed (60 and 120 minutes) images. If tracer was not visualized in peritoneum after 2 hours, the reservoir was depressed twice with fingerprint pressure to accelerate the flow rate. On the other hand, if diffuse peritoneal distribution of tracer was seen before 2-hour images, early termination of the examination was implemented.

### 2.3. Imaging interpretation

All images were recorded digitally. Imaging interpretation was performed visually and qualitatively by 2 experienced nuclear medicine physicians, who were unaware of the clinical information and who arrived at a consensus decision regarding the interpretation of the imaging.

The function of the proximal catheter could be assessed by the presence of ventricular reflux on 30-minute early images, whereas no ventricular reflux does not indicate obstruction necessarily.<sup>[12]</sup> Most V-P shunt malfunctions in adults occur due to obstruction of the peritoneal catheter,<sup>[3]</sup> thus the present study focused on the distal catheter patency. Two following criteria were used to classify the functionality of the distal catheter: prompt flow toward the peritoneum within 30 minutes, and/or diffuse peritoneal tracer distribution being evident within 2 hours. A distal catheter with "normal function" was defined if radiotracer could be visualized in the peritoneum within 30 minutes, conjointly with diffuse distribution by the end of 2-hour delayed images. A "complete malfunction" of distal catheter was designated if no tracer uptake was seen in peritoneum on 2-hour delayed images. A "partial dysfunction" of distal catheter was considered as delayed radiotracer flow and/or incomplete peritoneal tracer distribution at 2 hours; findings between "normal function" and "complete malfunction".

The representative images of a "normal" radionuclide shuntogram are shown in Fig. 1, with prompt flow reaching the peritoneum and ventricular reflux on the early images, and diffuse peritoneal distribution and tracer clearance within the shunt on delayed images.

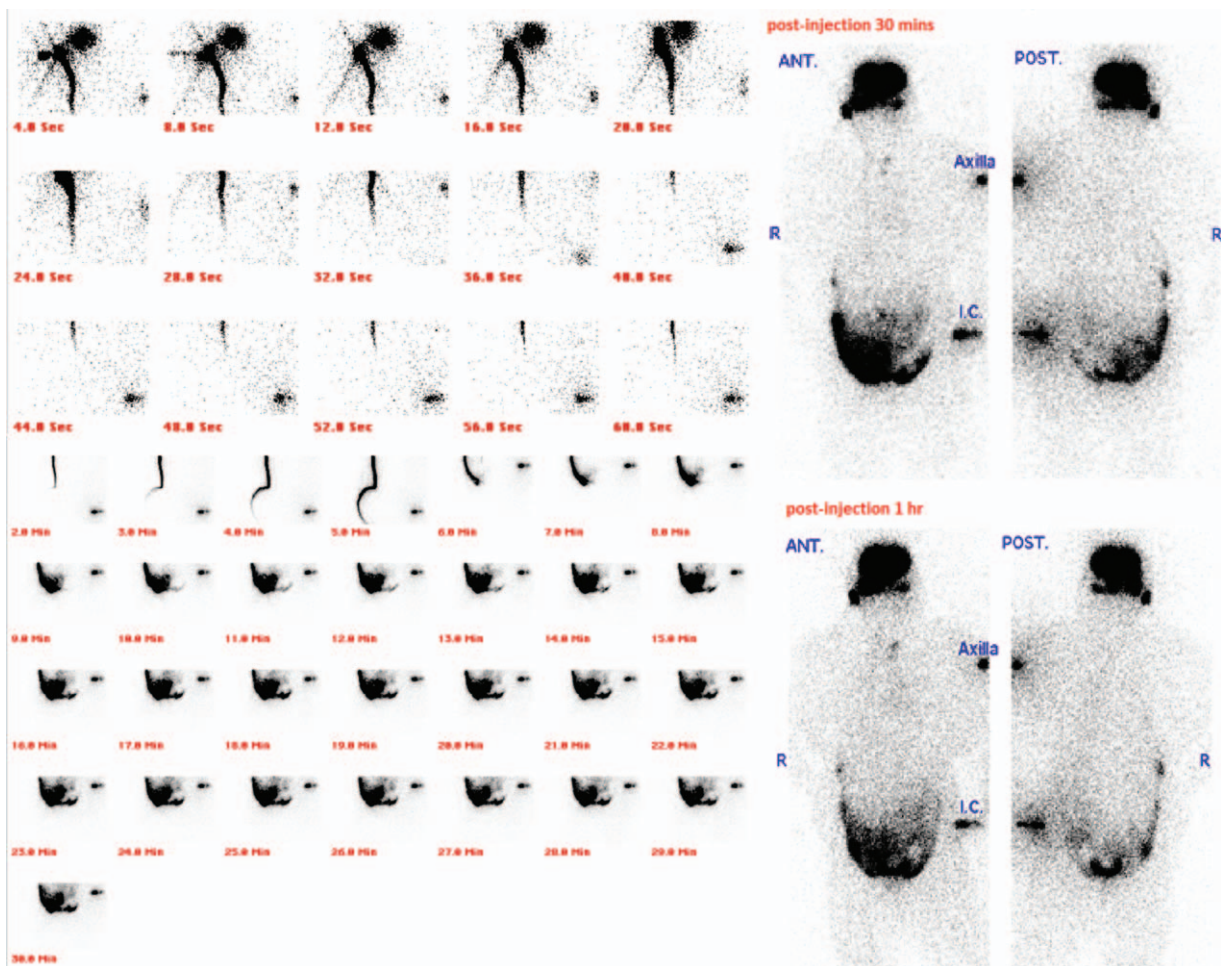
### 2.4. Statistical analysis

Numerical variables were expressed as mean  $\pm$  standard deviation, and categorical variables were expressed as percentages. Differences between numeric variables were compared using the Student *t* test; and differences between categorical variables were compared using Pearson chi-square test or Fisher exact test, as appropriate. With the clinical outcome and surgical findings as the standard, the diagnostic values of radionuclide shuntography were expressed as sensitivity (Se), specificity (Sp), positive predictive value (PPV), negative predictive value (NPV), and overall accuracy. Receiver operating characteristic (ROC) curves were generated, and the areas under the curve (AUC) were calculated. Data were analyzed using SPSS 17.0 software (IBM Corp., Armonk, NY). The *P* values were 2-sided, with a *P* value  $<.05$  considered statistically significant.

## 3. Results

The flow diagram of patient enrollment and analyses is shown in Fig. 2. The remaining 93 studies from 69 subjects represented the study population. Mean age at the time of study was  $66.2 \pm 14.9$  years (median, 68 years; range, 21–102 years). Male gender accounted for 50.7% ( $n=35$ ) of the population. A total of 16 patients (23.3%) had received more than 1 scan (twice in 12 patients, 3 times in 2 patients, 4 times in 1 patient, and 6 times in 1 patient) during the study period.

Surgical intervention was performed after 28 index shuntographic studies in 25 patients (11 men; mean age,  $59.7 \pm 11.0$  years; median age, 60 years; range, 32–78 years; 3 patients had 2 shunt studies). The surgical groups were younger than the whole study population ( $P=.048$ ). The mean interval between shuntography and operation was  $5.1 \pm 5.4$  days (median, 4 days;



**Figure 1.** Representative images of normal shuntography. The dynamic (4-second frame in the first minute, and 1-minute frame in the second to 30th minutes) and whole-body static early images showed prompt flow reaching peritoneum and ventricular reflux; the 1-hour delayed image showed diffuse abdominal distribution and tracer clearance within shunt.

range, 0–23 days). The clinical characteristics were summarized in Table 1. All subjects were followed for at least 30 days without any complications or discomfort.

Of the 93 included studies, 31 (33.3%) scans were classified as patent. The remaining 62 (66.7%) abnormal studies comprised 26 (28.0%) “complete malfunction” scans, 35 (37.6%) “partial dysfunction” scans, and only 1 miscellaneous finding (1.1%) suggestive of CSF leak.

Clinical malfunction was defined after 53 index shuntography, including the need for surgery ( $n=32$ ), and CSF shunt pressure adjustment ( $n=21$ ). Surgical findings regarding the distal catheters ( $n=28$ ) were categorized as: complete obstruction ( $n=22$ ), partial dysfunction ( $n=3$ ), and no significant obstruction ( $n=3$ ). The relationships of the radionuclide shuntography findings to clinical outcome or surgical findings are listed in Table 2.

Using the clinical outcomes as the diagnostic reference, the Se and Sp were 83.0% and 55.0%, respectively; and PPV, NPV, and accuracy were all 71.0%. The interpretation between shuntographic results and surgical findings were highly concordant (Se=92.0%, Sp/PPV=100.0%, NPV=60.0%, overall accuracy=92.9%,  $P=.003$ ) (Table 3). The AUC of the ROC analyses, based on clinical outcomes and surgical findings, were 0.69 (95%

confidence interval [CI] 0.60–0.78) and 0.96 (95% CI 0.90–1.02) respectively, as shown in Fig. 3.

#### 4. Discussion

Shunt obstruction is not uncommon in patients who receive CSF shunt insertion, and the incidence increases with time.<sup>[19,20]</sup> The diagnosis of shunt malfunction is challenging. The absence of subsequent meningitis, infection of the injection site, shunt malfunction or worsening of clinical symptoms following tracer injection could confirmed the safety of radionuclide shuntography. The high concordance of shuntographic interpretation and surgical findings suggests that this simple qualitative method provides clinically useful information of shunt patency and could be used to guide surgical intervention.

CSF shuntography is not familiar to many physicians possibly due to limited access to nuclear medicine facilities and lack of recommended approach. Most clinical studies involve small sample sizes and subjects younger than 18 years.<sup>[10,13–15,18]</sup> The etiology of hydrocephalus, prevalence, and underlying reasons for shunt complications differ between children and adults.<sup>[20–23]</sup> Our study evaluated V-P shunt function in an adult population, and 30.1% (28/93) of patients also underwent surgical intervention.



**Table 1**  
Clinical characteristics of all subjects and subjects who underwent surgical intervention.

Clinical variables	All study subjects (n=69)	Surgical group (n=25)
Age, y	66.2 ± 14.9*	59.7 ± 11.0*
Male	63.9 ± 15.5	58.1 ± 13.4
Female	68.9 ± 14.0	60.9 ± 9.0
Male gender, %	35 (50.7)	11 (44.0)
Received more than 1 shuntography, %	16 (23.2)	3 (12.0)
Twice	12	3
3 times	2	0
4 times	1	0
6 times	1	0
Interval between shuntography and surgery, d	–	5.1 ± 5.4 (95% CI 2.9–7.3)

Mean ± SD or n (%). 95% CI=95% confidence interval.  
\* P=.048 between "all subject group" and "surgical group."

**Table 2**  
Correlations between radionuclide shuntography and clinical outcome or surgical findings.

	Radionuclide shuntography		P
	Normal	Abnormal	
Clinical outcome (n=93)			<.001
Function	22 (23.7%)	18 (19.4%)	
Malfunction	9 (9.7%)	44 (47.3%)	
Surgical findings (n=28)			.003
No obstruction	3 (10.7%)	0 (0.0%)	
Obstruction/dysfunction	2 (7.1%)	23 (82.1%)	

P<.001 by Pearson Chi square test, and .003 by Fisher exact test.

**Table 3**  
Diagnostic value of radionuclide shuntography based on clinical outcome or surgical findings.

	Clinical outcome (95% CI)	Surgical findings (95% CI)
n	93	28
Sensitivity	83.0% (77.8–90.8)	92.0% (75.0–97.8)
Specificity	55.0% (39.8–69.3)	100.0% (43.9–100.0)
Positive predictive value	71.0% (58.1–81.8)	100.0% (85.7–100.0)
Negative predictive value	71.0% (52.0–85.8)	60.0% (23.1–88.2)
Overall accuracy	71.0% (61.1–79.2)	92.9% (77.4–98.0)
AUC of ROC curve	0.69 (0.60–0.78)	0.96 (0.90–1.02)

95% CI = 95% confidence interval, AUC = areas under the curve, ROC = receiver operating characteristic.

when correlated with intraoperative findings in a 74-patient series with a median age of 19 years. They also emphasized that if tracer enters the ventricle (NPV > 90%) and could be used to exclude obstruction; yet no ventricular uptake does not necessarily indicate obstruction.<sup>[12,18]</sup>

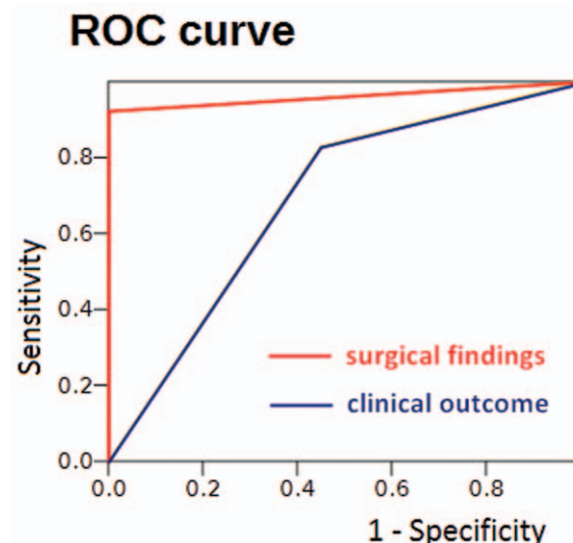
The abovementioned first definition of normal shuntogram was similar to ours, except that we set the threshold at 30 minutes. Although NPV was lower, the Se, Sp, and PPV were higher in our series. This discrepancy in results could be partly explained by different study populations (median age 19 years vs 60 years) and different diagnostic thresholds.

Gok et al<sup>[18]</sup> and Kharkar et al<sup>[3]</sup> series are the only existing studies specifically focused on the adult population; the prior

elaborated the application of ventriculoatrial shunt, while the latter evaluated V-P shunt function. Kharkar et al<sup>[3]</sup> assessed the effectiveness of different "single-variable" shuntography methods in patients with normal pressure hydrocephalus who underwent surgery. The results showed that "T<sub>1/2</sub> ≥ 8.7 minutes" had a diagnostic accuracy of 87% in 32 patients, and "diffuse peritoneal distribution" was correctly identified in 35 patients (71%). Quantitative methods encompass more complicated skills, but our simple method had an even higher overall diagnostic accuracy in the postoperative group (n=28, 92.9%).

**4.1. Limitations**

Our study had several limitations including its retrospective nature. Certain clinical information is not complete in all the included subjects, including etiology of hydrocephalus, valve type, valve settings, onset and duration of symptoms, neurologic status at the examination, and duration between V-P shunt and shuntography.



\* p < 0.001

**Figure 3.** The area under the receiver operating characteristic curve based on the surgical results was significantly higher than clinical outcome, 0.96 (red line, n=28) and 0.69 (blue line, n=93), respectively (P<.001).

This was an observational study, and subsequent treatment strategies were decided by the in-charge neurosurgeons. Most patients received long-term follow-up at our institute, and the majority (84.9%) were cared for by the same physician (Dr Yang). Repeated shuntography, pressure adjustment, and surgical intervention were performed if the neurologic condition deteriorated, even in the setting of a normal shuntogram.

In summary, our study confirmed that radionuclide shuntography was useful in adult patients suspected V-P shunt malfunction and could be used to guide surgical intervention.

## References

- [1] Conn HO. Normal pressure hydrocephalus (NPH): more about NPH by a physician who is the patient. *Clin Med* 2011;11:162–5.
- [2] Bradley WG Jr. CSF flow in the brain in the context of normal pressure hydrocephalus. *AJNR Am J Neuroradiol* 2015;36:831–8.
- [3] Kharkar S, Shuck J, Kapoor S, et al. Radionuclide shunt patency study for evaluation of suspected ventriculoperitoneal shunt malfunction in adults with normal pressure hydrocephalus. *Neurosurgery* 2009;64:909–16.
- [4] Kiefer M, Unterberg A. The differential diagnosis and treatment of normal-pressure hydrocephalus. *Dtsch Arztebl Int* 2012;109:15–25.
- [5] Martín-Láez R, Caballero-Arzapalo H, López-Menéndez LÁ, et al. Epidemiology of idiopathic normal pressure hydrocephalus: a systematic review of the literature. *World Neurosurg* 2015;84:2002–9.
- [6] Torsnes L, Blåfjelldal V, Poulsen FR. Treatment and clinical outcome in patients with idiopathic normal pressure hydrocephalus—a systematic review. *Dan Med J* 2014;61:A4911.
- [7] Lollisa SS, Mamourian AC, Vaccarob TJ, et al. Programmable CSF shunt valves: radiographic identification and interpretation. *AJNR Am J Neuroradiol* 2010;31:1343–6.
- [8] Symms NP, Oi S. Is there an ideal shunt? A panoramic view of 110 years in CSF diversions and shunt systems used for the treatment of hydrocephalus: from historical events to current trends. *Childs Nerv Syst* 2015;31:191–202.
- [9] Pople IK. Hydrocephalus and shunts: what the neurologist should know. *J Neurol Neurosurg Psychiatry* 2002;73:i17–22.
- [10] Thompson EM, Wagner K, Kronfeld K, et al. Using a 2-variable method in radionuclide shuntography to predict shunt patency. *J Neurosurg* 2014;121:1504–7.
- [11] Piatt JH Jr, Carlson CV. A search for determinants of cerebrospinal fluid shunt survival: retrospective analysis of a 14-year institutional experience. *Pediatr Neurosurg* 1993;19:233–41.
- [12] Chiewvit S, Nuntaaree S, Kanchaanapiboon P, et al. Assessment lumboperitoneal or ventriculoperitoneal shunt patency by radionuclide technique: a review experience cases. *World J Nucl Med* 2014;13:75–84.
- [13] May CH, Aurisch R, Kornrumpf D, et al. Evaluation of shunt function in hydrocephalic patients with the radionuclide <sup>99m</sup>Tc-pertechnetate. *Childs Nerv Syst* 1999;15:239–44.
- [14] O'Brien DF, Taylor M, Park TS, et al. A critical analysis of 'normal' radionuclide shuntograms in patients subsequently requiring surgery. *Childs Nerv Syst* 2003;19:337–41.
- [15] Vernet O, Farmer J-P, Lambert R, et al. Radionuclide shuntogram: adjunct to manage hydrocephalic patients. *J Nucl Med* 1996;37:406–10.
- [16] Di Chiro G, Grove AS Jr. Evaluation of surgical and spontaneous cerebrospinal fluid shunts by isotope scanning. *J Neurosurg* 1966;24:743–8.
- [17] Howman-Giles R, McLaughlin A, Johnston I, et al. A radionuclide method of evaluating shunt function and CSF circulation in hydrocephalus technical note. *J Neurosurg* 1984;61:604–5.
- [18] Gok B, Batra S, Eslamy H, et al. Radionuclide shunt patency study for suspected ventriculoatrial shunt malfunction. *Clin Nucl Med* 2013;38:527–33.
- [19] Graham P, Howman-Giles R, Johnston I, et al. Evaluation of CSF shunt patency by means of technetium-99m DTPA. *J Neurosurg* 1982;57:262–6.
- [20] Wu Y, Green NL, Wrench MR, et al. Ventriculoperitoneal shunt complications in California: 1990 to 2000. *Neurosurgery* 2007;61:557–62.
- [21] Oi S, Cinalli G, Sainte-Rose C, Maixner WJ. Classification and definition of hydrocephalus: origin, controversy, and assignment of the terminology. *Pediatric Hydrocephalus Springer-Verlag Italia, Milano*:2005;95–111.
- [22] Oi S. Hydrocephalus research update—controversies in definition and classification of hydrocephalus. *Neurol Med Chir (Tokyo)* 2010;50:859–69.
- [23] Oi S. Classification of hydrocephalus: critical analysis of classification categories and advantages of “Multi-categorical Hydrocephalus Classification” (Mc HC). *Childs Nerv Syst* 2011;27:1523–33.