



Contents lists available at ScienceDirect

International Journal of Surgery Case Reports

journal homepage: www.casereports.com

Endoscopic clipping of spontaneous esophageal rupture: Case reports of three patients



Koji Otsuka*, Masahiko Murakami, Tomotake Ariyoshi, Takeshi Yamashita, Satoru Goto, Makoto Watanabe, Takeshi Aoki

Division of Gastroenterological and General Surgery, Department of Surgery, Showa University School of Medicine, 142-8666 1-5-8 Hatanodai, Shinagawa-ku, Tokyo, Japan

ARTICLE INFO

Article history:

Received 29 March 2017

Received in revised form 27 June 2017

Accepted 3 July 2017

Available online 8 July 2017

ABSTRACT

INTRODUCTION: Spontaneous esophageal rupture is a life-threatening condition which is difficult to diagnose early, and is usually treated surgically. Prolonged hospitalization is common. Non-operative treatment of esophageal rupture localized to the mediastinum has been reported. We report three patients with spontaneous esophageal rupture successfully managed with endoscopic clipping.

CASE PRESENTATIONS: Two patients had ruptures localized to the mediastinum, and were discharged within one week of undergoing closure. The third patient presented with Boerhaave's syndrome with a leak into the pleural space and needed prolonged hospitalization (34 days), but she did not need surgery and began oral intake two days after endoscopic clipping. The patient had an uneventful recovery.

© 2017 The Authors. Published by Elsevier Ltd on behalf of IJS Publishing Group Ltd. This is an open access article under the CC BY-NC-ND license (<http://creativecommons.org/licenses/by-nc-nd/4.0/>).

Discussion Surgery is the treatment of choice for most patients with spontaneous esophageal rupture, but is associated with complications in 14–40% of patients. Although there are many reports of non-operative treatment of spontaneous esophageal rupture localized to the mediastinum, the non-operative management of Boerhaave's syndrome with pleural rupture is rarely reported. We suggest that endoscopic clipping is a reasonable strategy not only for patients with esophageal rupture localized to the mediastinum, but also for those with Boerhaave's syndrome and pleural rupture.

1. Introduction

Spontaneous rupture of the esophagus involves all layers of the esophageal wall due to a sudden increase in intraluminal pressure, first documented by Herman Boerhaave in 1724. In patients with Boerhaave's syndrome with pleural rupture, the resulting mediastinitis can rapidly lead to severe pneumonia and death [1,2]. Surgery is the conventional treatment for patients with esophageal rupture. However, it has been reported recently that esophageal rupture localized to the mediastinum can be successfully treated non-operatively [3–5]. We suggest endoscopic clipping as a less invasive treatment strategy for patients not only with esophageal rupture localized to the mediastinum, but also for select patients with Boerhaave's syndrome and pleural rupture.

2. Presentation of cases

We describe three patients diagnosed with spontaneous esophageal rupture between January 2013 and May 2015, after presenting with chest pain after vomiting (Table 1).

All of the patients were in their late forties, and included two males and one female. The female patient had Boerhaave's syndrome with pleural rupture caused by severe vomiting due to obstruction secondary to duodenal ulcer stenosis. The two male patients had esophageal rupture localized to the mediastinum caused by vomiting after excessive alcohol consumption. This report was approved by the Institutional Review Board of the Showa University School of Medicine. Informed consent was obtained from each patient for the publication of this case report.

The diagnosis of spontaneous esophageal rupture was confirmed by physical examination and by radiography including computed tomography (CT) scan of the chest and abdomen. The female patient was referred with respiratory difficulty. Mediastinal emphysema and a massive pleural effusion were observed on a plain chest CT scan (Fig. 1a, b). Fluoroscopy with gastrografin showed an esophageal perforation approximately 1 cm in diameter (Fig. 2). Adequate drainage was achieved by a drain placed adjacent to the perforation site in the left pleural cavity. Subsequently, her general condition improved by the fifth hospital day, and we performed low-pressure insufflation endoscopy. The site of perforation was visualized, surrounded by 3 cm of lacerated mucosa on the left side of the distal esophagus. (Fig. 3a, b). The surrounding mucosa showed fibrosis due to inflammation. The patient underwent a contrast study using gastrografin to confirm the site of perforation (Fig. 4a), and then underwent endoscopic closure of the perforation

* Corresponding author.

E-mail address: kojiotsuka@med.showa-u.ac.jp (K. Otsuka).

Table 1
Patient characteristics and hospital course.

Patient	Age	Gender	Cause	Type	Endoscopy (days)	Treatment	Oral intake (days)	Hospital Stay (days)
1	46	F	Stenosis of Duodenal Ulcer	fistula with pleural cavity	5	Clipping	4	34
2	45	M	Alcohol, GERD (Grade D)	Mediastinitis	0	Clipping	3	8
3	50	M	Alcohol, GERD (Grade D)	Mediastinitis	0	Clipping	3	7

GERD: Gastroesophageal Reflux Disease, F=Female, M=Male.

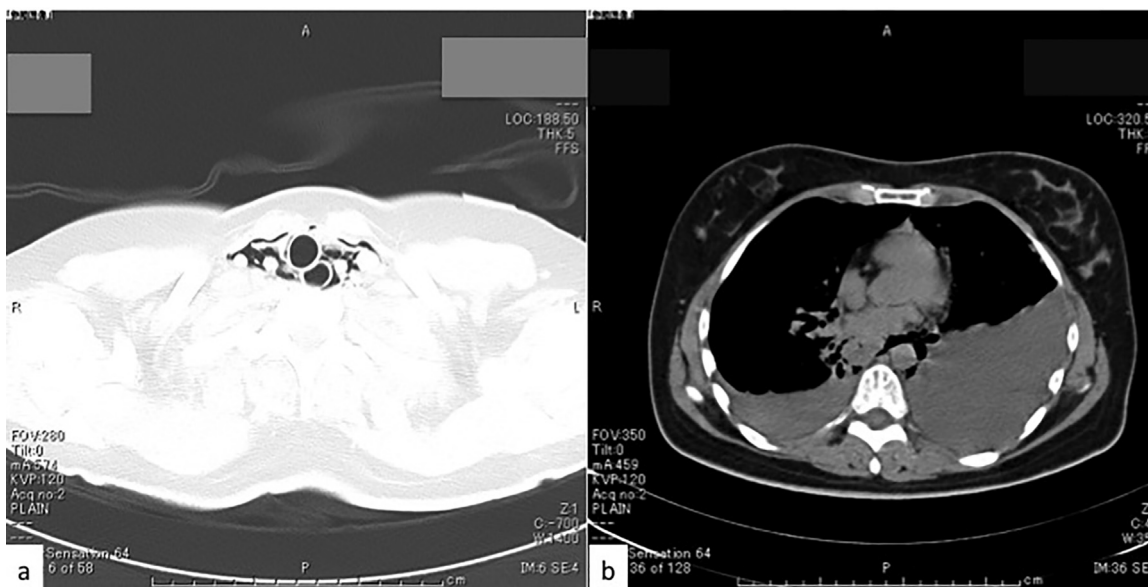


Fig. 1. a. At initial diagnosis, computed tomography scan revealed cervical subcutaneous emphysema. b. A large quantity of pleural fluid on the left side and mediastinal emphysema were detected.

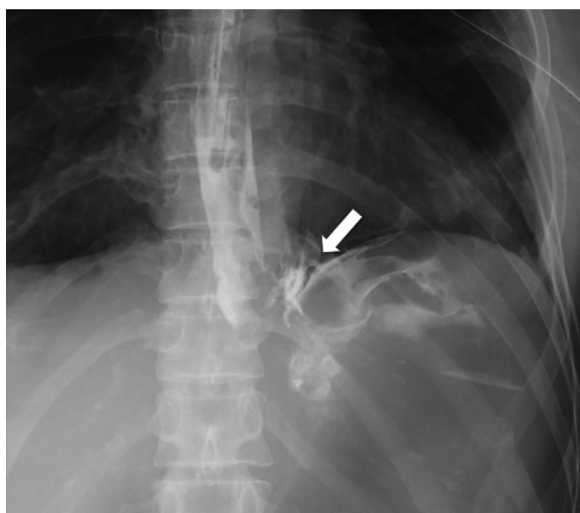


Fig. 2. At initial diagnosis, fluoroscopy indicated a perforation on the left side of the distal esophagus (arrow).

using five long metallic clips (HX-610-090L; Olympus Corporation, Tokyo, Japan) (Fig. 4b). Closure of the perforation was confirmed on a subsequent contrast study using gastrografin, which showed no leak (Fig. 4c). Follow-up endoscopy at six months after discharge showed in Fig. 4d. The patient started drinking water and a liquid diet on the second and third days, respectively, after endoscopic clipping, and had an uneventful recovery. However, because of the rupture, further therapy was needed (e.g., treatment for *Helicobacter pylori*, bacterial culture before drain withdrawal) and the patient was hospitalized for 34 days (Fig. 5).

The other two patients underwent endoscopic clipping immediately after esophageal perforation. Oral intake was initiated for both patients an average of 3.3d after endoscopic clipping.

3. Discussion

Spontaneous esophageal rupture is a life-threatening condition which is difficult to diagnose early. The most common site of perforation is the left side of the distal esophagus, where the wall is weak. Treatment of this condition is difficult and complications occur in 14–40% of patients [6]. Surgery is the treatment of choice for most patients with spontaneous esophageal rupture [7]. Among the various surgical approaches, the transthoracic approach is commonly chosen. However, some patients are treated with the transperitoneal approach because the perforation often occurs in the distal esophagus. Thoracoscopy has recently been reported for the treatment of this condition [8]. There are also several reports of non-operative treatment, by stopping all oral intake and providing intravenous nutrition or using a covered stent in patients with small ruptures localized to the mediastinum [3,5]. However, the use of covered stents is occasionally associated with migration of the stent or perforation of the lower esophagus. Cameron et al. [9] and Shaffer et al. [10] described eligibility criteria for non-operative treatment in patients with esophageal rupture. In two of the patients described here, the perforation was localized to the mediastinum, which is consistent with these criteria. In contrast, surgery was indicated in the female patient described here with a perforation located in the thoracic cavity. Insertion of a drain into the thoracic cavity was effective for this patient, and endoscopic clipping was performed after her general condition improved.

Although there are many reports regarding non-operative treatment of spontaneous esophageal rupture localized to the

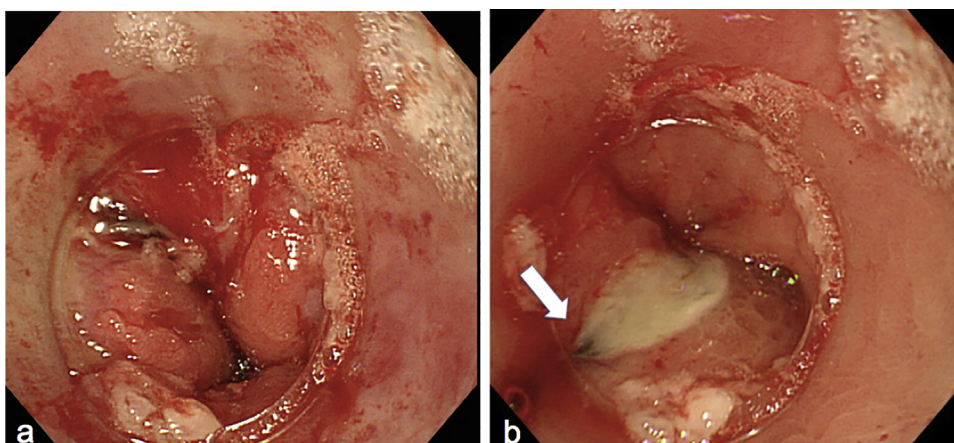


Fig. 3. a. The laceration of the mucosa showed erythema and was accompanied by slight stiffness. b. Arrow shows the perforation site that was not closed.

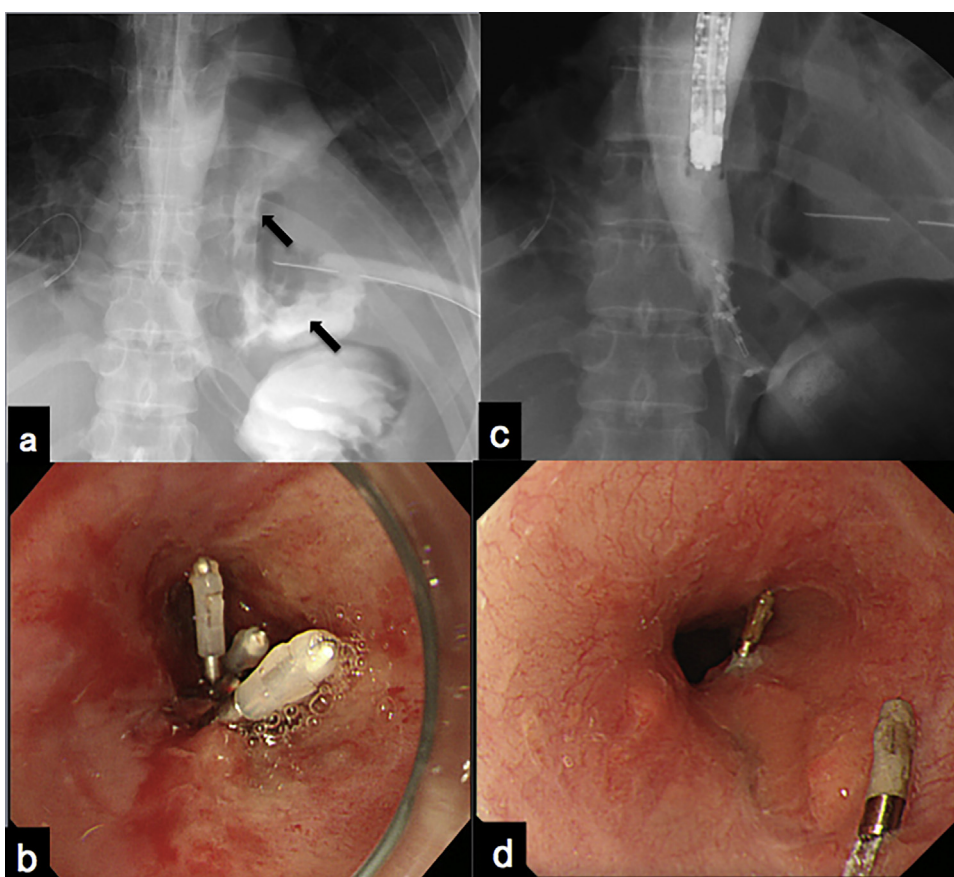


Fig. 4. a. We performed a contrast examination using gastrografin endoscopy and confirmed the perforation site. Arrow shows gastrografin that refluxed into the thoracic cavity. b. Although the mucosa was stiff, clipping could be performed. c. After clipping, there was no leakage of contrast. d. Follow-up endoscopy at six months after discharge shows two residual clips with no esophageal stenosis.

mediastinum [3–5], the non-operative management of Boerhaave's syndrome with pleural rupture is rarely reported. In our experience, perforations may take much longer to heal after conventional surgical closure, and such patients require a longer hospital stay. Even if the site of the perforation, which can be confirmed from the adventitial layer, is closed directly by suturing or omentoplasty, some leakage of contrast often continues, as observed on fluoroscopy. This leakage is probably because the length of the surrounding mucosal laceration is longer than the perforation, and the perforation may expand. Consequently, endoscopic closure of the full length of the lacerated wound is important, from within the

esophageal lumen. This procedure can be considered an appropriate treatment strategy for completely closing the site of leakage under direct vision.

There have recently been reports of closure of perforations using a new clipping technique involving an over-the-scope-clip (OTSC) system (Ovesco Endoscopy GmbH, Tübingen, Germany) [11]. In the patients described here with pleural rupture, we could not use this device because it had not yet been released for clinical use. Since OTSC has the ability to grasp the muscularis mucosa, we believe that OTSC may change the treatment of Boerhaave's syndrome. The optimal timing of endoscopic clipping in patients

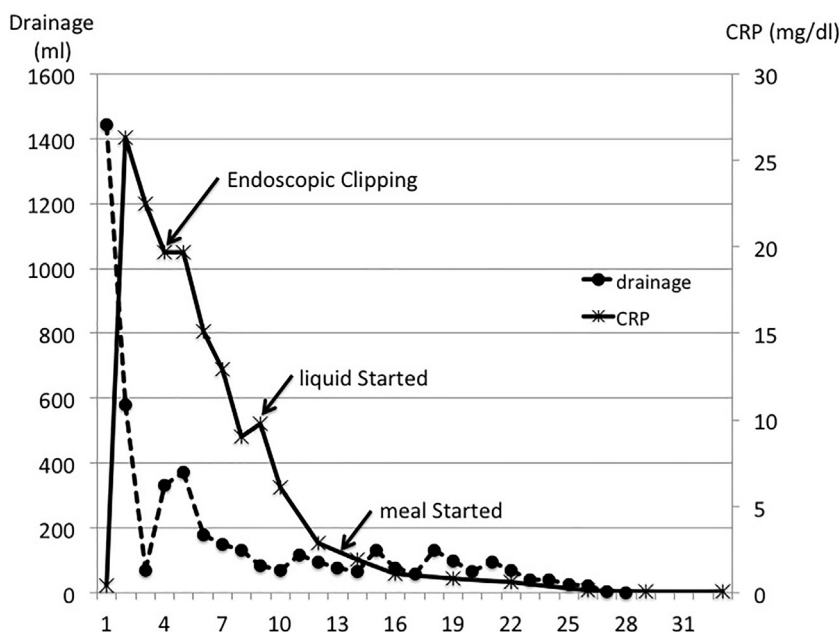


Fig. 5. The patient had an uneventful recovery. However, because of the rupture, further therapy was needed (e.g., treatment for *Helicobacter pylori*, bacterial culture before drain withdrawal) and the patient was hospitalized for 34 days. CRP: C-reactive protein.

with Boerhaave's syndrome with pleural rupture is debatable. In many patients with spontaneous esophageal rupture localized to the mediastinum, endoscopic clipping is performed immediately after admission. Immediate treatment after precisely determining the size and status of the rupture under direct visualization is important.

Endoscopic clipping carries a high risk in patients with poor overall condition due to Boerhaave's syndrome with pleural rupture; hence, careful management is necessary. For patients with spontaneous esophageal ruptures with pleural rupture, endoscopic clipping should be performed after inserting a drain into the thoracic cavity and after the patient's general condition improves. When endoscopy is performed, there is a concern that the general condition of the patient could worsen (e.g., aggravated mediastinal emphysema due to insufflation and tension pneumothorax). Therefore, insufflation with a low volume of carbon dioxide is necessary. However, the closure commonly leads to fibrosis and sclerosis of the tissue surrounding the perforation.

Timing of closure by endoscopy is very important because these tissues are firm and edematous, which can cause extension of the perforation at the time of closure. Fortunately, we could close the site directly on the fifth hospital day. Although it is not possible to compare results with closure on admission and closure on the fifth hospital day, we believe that the time interval may have allowed the perforation site to contract after non-operative treatment. This allowed direct closure with long metallic clips.

We present three patients who underwent endoscopic clipping for spontaneous esophageal rupture. This condition can be fatal and should be treated immediately. However, endoscopic clipping should be performed by or under the guidance of physicians who can perform emergency esophageal surgery. If non-operative treatment and direct closure by endoscopy is not effective, surgical treatment must be undertaken without hesitation. Endoscopic clipping is useful for not only patients with spontaneous esophageal rupture localized to the mediastinum but also for patients with Boerhaave's syndrome and pleural rupture after their general condition has been stabilized. Based on the accumulated data of such patients, further study of endoscopic clipping for the management of these patients is indicated.

4. Conclusion

The management of patients with esophageal rupture is usually operative. In patients with rupture localized to the mediastinum, non-operative management with clipping has been reported. Endoscopic clipping may also be a reasonable treatment option for highly selected patients with Boerhaave's syndrome.

Institutional review board statement

This report was reviewed and approved by the Institutional Review Board of the Showa University School of Medicine.

Informed consent statement

Informed consent was obtained from each patient for the publication of this case report.

Conflict-of-interest statement

The authors declare no conflicts of interest.

Funding source

I do not have any sources of funding for my research.

Ethical approval

This report was reviewed and approved by the Institutional Review Board of the Showa University School of Medicine.

Consent

This report was reviewed and approved by the Institutional Review Board of the Showa University School of Medicine.

Author contributions

Otsuka K and Murakami M participated in the conception and design of the report; Ariyoshi T, Yamashita T, Goto S, Tashiro Y, Watanabe M, and Aoki T performed the literature review; Otsuka K drafted the manuscript; Murakami M critically reviewed the manuscript.

Guarantor

The Guarantor is Koji Otsuka and Masahiko Murakami

Acknowledgement

This case report is in line with the SCARE criteria [14]. <http://www.scareguideline.com>.

References

- [1] V.J. Derbes, R.E. Mitchell Jr., Hermann Boerhaave's Atrocis, nec descripti prius, morbi historia, the first translation of the classic case report of rupture of the esophagus, with annotations, *Bull. Med. Libr. Assoc.* 43 (1955) 217–240, PMID: 14364044.
- [2] J. Davies, D. Spitzer, M. Phylactou, M. Glasser, Cardiac arrest due to a missed diagnosis of Boerhaave's syndrome, *BMJ Case Rep.* 2016 (May (6)) (2016).
- [3] K.F. Ghassemi, H.J. Rodriguez, L. Vesga, L. Stewart, K.R. McQuaid, J.N. Shah, Endoscopic treatment of Boerhaave syndrome using a removable self-expandable plastic stent, *J. Clin. Gastroenterol.* 41 (2007) 863–864, <http://dx.doi.org/10.1097/01.mcg.0000225597.46943.06>, PMID: 17881934.
- [4] R. Tanaka, S. Kosugi, D. Sato, H. Hirukawa, T. Tada, H. Ichikawa, T. Hanyu, T. Ishikawa, T. Kobayashi, T. Wakai, Conservative treatment of esophageal perforation related to a peptic ulcer with pyloric stenosis, *Clin. J. Gastroenterol.* 7 (August (4)) (2014) 295–298.
- [5] F. Biancari, T. Tauriainen, T. Ylikotila, M. Kokkonen, J. Rintala, E. Mäkäräinen-Uhlbäck, V. Koivukangas, J. Saarnio, Outcome of stent grafting for esophageal perforations: single-center experience, *Surg. Endosc.* (January (11)) (2017), <http://dx.doi.org/10.1007/s00464-016-5408->.
- [6] J.D. Richardson, Management of esophageal perforations: the value of aggressive surgical treatment, *Am. J. Surg.* 190 (2005) 161–165, <http://dx.doi.org/10.1016/j.amjsurg.2005.05.004>, PMID: 16023423.
- [7] S. Yamashita, S. Takeno, T. Moroga, M. Kamei, K. Ono, Y. Takahashi, S. Yamamoto, K. Kawahara, Successful treatment of esophageal repair with omentum for the spontaneous rupture of the esophagus (Boerhaave's syndrome), *Hepatogastroenterology* 59 (2012) 745–746, <http://dx.doi.org/10.5754/hge10025>, PMID: 22469718.
- [8] J.W. Haveman, V.B. Nieuwenhuijs, J.P. Kobold, G.M. van Dam, J.T. Plukker, H.S. Hofker, Adequate debridement and drainage of the mediastinum using open thoracotomy or video-assisted thoracoscopic surgery for Boerhaave's syndrome, *Surg. Endosc.* 25 (2011) 2492–2497, <http://dx.doi.org/10.1007/s00464-011-1571-y>, PMID: 21359901.
- [9] J.L. Cameron, R.F. Kieffer, T.R. Hendrix, D.G. Mehigan, R.R. Baker, Selective nonoperative management of contained intrathoracic esophageal disruptions, *Ann. Thorac. Surg.* 27 (1979) 404–408, [http://dx.doi.org/10.1016/S0003-4975\(10\)63335-8](http://dx.doi.org/10.1016/S0003-4975(10)63335-8), PMID: 110275.
- [10] H.A. Shaffer Jr., G. Valenzuela, R.K. Mittal, Esophageal perforation: a reassessment of the criteria for choosing medical or surgical therapy, *Arch. Intern. Med.* 152 (1992) 757–761, <http://dx.doi.org/10.1001/archinte.1992.00400160069013>, PMID: 1558433.
- [11] E. Ramhamadany, S. Mohamed, S. Jaunoo, et al., A delayed presentation of Boerhaave's syndrome with mediastinitis managed using the over-the-scope clip, *J Surg Case Rep* 2013 (2013), <http://dx.doi.org/10.1093/jscr/rjt020>, rjt020 PMID 24964437.
- [14] R.A. Agha, A.J. Fowler, A. Saetta, I. Barai, S. Rajmohan, D.P. Orgill, The SCARE group, The SCARE statement: consensus-based surgical case report guidelines, *Int. J. Surg.* 34 (2016) 180–186.

Open Access

This article is published Open Access at sciedirect.com. It is distributed under the [IJSCR Supplemental terms and conditions](#), which permits unrestricted non commercial use, distribution, and reproduction in any medium, provided the original authors and source are credited.