

Cryptococcal endocarditis of native valves without immunodeficiency or drug abuse: a case report

Journal of International Medical Research

48(12) 1–6

© The Author(s) 2020

Article reuse guidelines:

sagepub.com/journals-permissions

DOI: 10.1177/0300060520970763

journals.sagepub.com/home/imr

Yimin Li^{1,*} , Shenghu He^{2,*}, Zhiping Lu¹,
Chang Ding¹, Qian Wang¹, Quanyi Li¹,
Yang Pan¹ and Jin Huang¹

Abstract

Cryptococcal endocarditis has rarely been reported. Most patients with this condition are associated with risk factors, such as structural heart disease/valve replacement, immunodeficiency/immunosuppression or drug abuse. We report a case of cryptococcal endocarditis of the native valves without any risk factors. A 50-year-old Chinese man was admitted to hospital with fever for 1 month without any underlying heart disease, immunodeficiency, or drug use. He was diagnosed as having *Cryptococcus neoformans* infective endocarditis and was discharged after valve replacement surgery and long-term antifungal therapy.

Keywords

Cryptococcus, endocarditis, native valve, aortic valve replacement, heart failure, fever

Date received: 19 July 2020; accepted: 12 October 2020

Introduction

Infectious endocarditis is a difficult disease to treat. Fungal endocarditis, which is mainly caused by *Candida* species and *Aspergillus* species, accounts for only 2% of all cases of endocarditis.^{1,2} Cryptococcal endocarditis has rarely been reported. Only a few reported cases of this condition were associated with risk factors,

¹Department of Cardiovascular Medicine, Nanjing Chest Hospital, Nanjing, China

²Department of Cardiovascular Medicine, Northern Jiangsu People's Hospital, Yangzhou, China

*These authors contributed equally to this work.

Corresponding author:

Jin Huang, Department of Cardiology, Nanjing Chest Hospital, 215 Guangzhou Road, Nanjing, 210029, China.
Email: huangjin6310@sina.com



Creative Commons Non Commercial CC BY-NC: This article is distributed under the terms of the Creative

Commons Attribution-NonCommercial 4.0 License (<https://creativecommons.org/licenses/by-nc/4.0/>) which permits non-commercial use, reproduction and distribution of the work without further permission provided the original work is attributed as specified on the SAGE and Open Access pages (<https://us.sagepub.com/en-us/nam/open-access-at-sage>).

such as heart valve disease/valve replacement, immunodeficiency/immunosuppression, or drug abuse.³ We present a case of cryptococcal endocarditis of native valves without immunodeficiency or drug abuse.

Case presentation

A 50-year-old Chinese man was admitted with recurrent fever 1 month after removal of internal fixation after fracture of the left clavicle 4 months previously. He had received intravenous infusion of various antibiotics (e.g., cefuroxime, moxifloxacin, cefoperazone and sulbactam) in local hospitals, but still had intermittent fever (peak temperature was nearly 40°C), accompanied by progressive aggravation of chest tightness and shortness of breath. His medical history was lacunar cerebral infarction and chronic hepatitis B. No major social and family history was reported. On admission, his body temperature was 36.4°C, heart rate was 78 beats per minute, respiratory rate was 18 breaths per minute, and blood pressure was 113/55 mmHg. A physical examination was unremarkable, except that conjunctiva of both eyes was obviously congested and there was a sigh-like murmur in the aortic valve area.

A laboratory examination showed the following: white blood cell count of $2.1 \times 10^9/L$, red blood cell count of $2.58 \times 10^{12}/L$, hemoglobin level of 78 g/L, mean corpuscular volume of 93 fL, platelet count of $98 \times 10^9/L$, high-sensitivity C-reactive protein level of 58.72 mg/L, D-dimer level of 2.93 mg/L, N-terminal-pro-brain natriuretic peptide level of 12,072 ng/mL, and fungal D-glucan level of 109.9 pg/mL. Anti-tuberculosis LAM antibody, anti-tuberculosis 38 kD antibody, *Mycoplasma pneumoniae* immunoglobulin (Ig) M, influenza B virus IgM, and anti-Ro-52 antibody were positive, and a human immunodeficiency virus test was negative. A chest computed tomography (CT) scan showed a

small amount of bilateral pleural effusion and pericardial effusion, while a brain CT scan was unremarkable. Transthoracic echocardiography showed additional echo of the aortic valve, aortic valve vegetation (17×15 mm), and moderate aortic valve insufficiency. The left ventricular internal diameter during diastole was 63 mm and the ejection fraction was 50%. There were mild mitral and tricuspid valve insufficiency, mild pulmonary hypertension, and a small amount of pericardial fluid (Figure 1).

After obtaining the patient's consent, we initiated intravenous vancomycin 1 mg once every 12 hours, levofloxacin 500 mg once a day, and fluconazole 400 mg once a day. Intermittent fever was still present, with a thermal peak of 39°C. Blood cultures were performed immediately after admission and at the peak of the fever on the next day. Both results, which were obtained after 5 days, showed *Cryptococcus neoformans* (Figure 2). Because of the poor medical treatment and the high risk of shedding and embolization of valve vegetation, emergency aortic valve replacement was performed (Figure 3). *C. neoformans* was also isolated from extracted cardiac tissue by periodic acid-silver methenamine (Figure 4). Postoperative anti-infection strategy was adjusted to cefminox 2 g once every 12 hours, amphotericin B 50 mg once

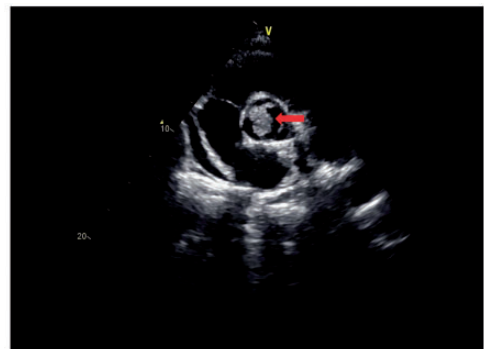


Figure 1. Transthoracic echocardiogram showing large vegetation (red arrow) on the aortic valve.




Figure 2. Cryptococcus in blood culture.

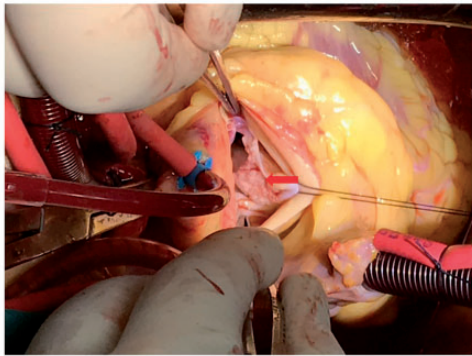


Figure 3. Intraoperative direct vision of vegetation (red arrow) on the aortic valve.

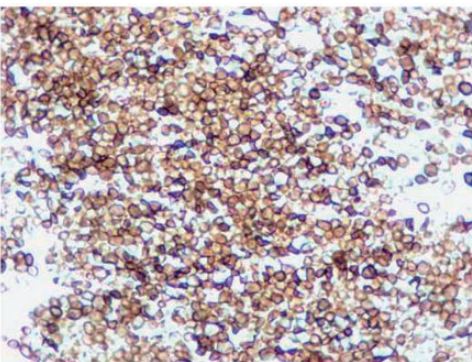


Figure 4. Histological section of Cryptococcus in vegetation stained by periodic acid-silver methenamine.

a day, and fluconazole 0.8 g once a day. The patient's chest tightness and wheezing symptoms greatly improved, but he still had intermittent fever, with a peak temperature of 38.2°C. Four times of postoperative blood cultures were negative. One month later, the antifungal strategy was switched to flucytosine (1.5 g, every 6 hours) + fluconazole (0.8 g, once a day) for approximately 10 weeks. He was discharged after 1 week of a normal body temperature. After discharge, fluconazole (0.4 g, once a day) was orally administered. The patient was followed up for approximately 6 months, with no obvious discomfort, such as fever (the patient's details have been de-identified).

Discussion

C. neoformans belongs to the fungal phylum of Blastomycota with no capsule or only a small capsule *in vitro*. However, *C. neoformans* forms a thick capsule quickly after entering the human body with significantly enhanced pathogenicity. Cryptococcus species can infect any tissue and organ of the human body. The central nervous system is the most commonly affected organ, followed by the lungs and skin. Systemic infections are usually due to lung infections caused by inhalation of spores or dried yeast.⁴ Cryptococcus species are opportunistic pathogens. The infection rate of *C. neoformans* in patients with acquired immune deficiency syndrome can be as high as 30%, while this rate is only approximately 1 in 100,000 in people without immunodeficiency.⁵

Infective endocarditis caused by Cryptococcus species is extremely rare. In retrospect, only 12 cases of cryptococcal endocarditis have been reported worldwide since 1957,^{1,3} mostly in patients with immunocompromised or prosthetic valve replacement. Six cases of cryptococcal endocarditis occurred in native valves (one vegetation occurred on the implantable cardiac

Table 1. Brief review of reported cases of cryptococcal endocarditis from 1957 to 2020.

Authors	Year	Sex	Age (years)	Underlying disease	Vegetation	Surgery	Antifungal strategies	Prognosis*
Lombardo TA et al. ⁶	1957	Male	44	RHD	MV+AV	No	Actidione, sulfadiazine	Died
Colmers RA et al. ⁷	1967	Male	55	Mitral stenosis, DM	MV	No	AMB	Survived (1 year)
Child JS et al. ⁸	1979	Male	56	Hematological disorder (prednisone, azathioprine)	MV	No	AMB	Died
Blanc V et al. ⁹	1996	Male	12	RHD, mitral valve plasty	MV	Yes	AMB + FLCZ	Survived (1 year)
Roy M et al. ³	2018	Male	26	Intravenous drug user	TV	No	L-AMB + FLCZ	Survived (6 months)
Kowatari R et al. ¹⁰	2018	Male	4	Acute leukemia, chemotherapy	MV	Yes	Voriconazole + capsosungin	Survived (3 years)
Nakajima T et al. ¹	2019	Male	72	ICD implantation, DM, interstitial pneumonitis (prednisone)	Lead	No	Micafungin + FLCZ + L-AMB + flucytosine	Died

*The survival time was known at the time of publication.

Abbreviations: RHD, rheumatic heart disease; MV, mitral valve; AV, aortic valve, DM, diabetes mellitus; AMB, amphotericin B; L-AMB, liposomal amphotericin B; FLCZ: fluconazole; TV, tricuspid valve; ICD, implantable cardiac defibrillator.

defibrillator lead) (Table 1).^{1,3,6-10} Unlike previous cases, our case is the first report of cryptococcal endocarditis of native valves without a complex history of valvular disease/valve replacement, immunodeficiency/immunosuppression, or drug use. Although some pathogens, such as bacteria, a virus, and immune indicators were positive after admission, the diagnosis of cryptococcal infection was quickly confirmed by blood culture and vegetative pathology.

Fungemia is usually considered to be an opportunistic disease. Advances in medicine have led to prolonged survival of immunocompromised patients as well as to development of opportunistic fungal infections.¹¹ In recent years, fungal infection has gradually become the principal component of nosocomial infection.¹² Although our patient did not have acquired immune deficiency syndrome, a tumor, or other risk factors of fungal infections, he underwent surgery for removal of internal fixation for the clavicle 4 months previously. He also repeatedly received intravenous infusion treatment before he was admitted to our hospital. Consequently, the invasive operation or intravenous line used might have led to hospital-acquired fungemia.

Previous studies have reported that 71% of cryptococcal infection is associated with meningitis.¹³ Related guidelines also recommend¹⁴ that routine lumbar puncture should be performed, even if there is no evidence of encephalitis in cryptococcal infections. No obvious meningeal signs of irritation were detected in our case and a complete cerebrospinal fluid etiological examination after valve replacement was negative. Fortunately, the pathogen may fail to invade the central nervous system, and this result also provides a basis for the selection of antifungal strategies.

Our patient received aortic valve replacement after 1 week of anti-inflammatory and antifungal treatment, which was in accordance with the recommendations of the

2015 European Society of Cardiology infective endocardial treatment guidelines.¹⁵ Our patient had all of the indications for active surgery, such as heart failure, infection, and vegetation >15 mm, which is an independent risk factor for a new embolism. Surgical methods quickly corrected the gradually worsening heart failure, and prevented embolism and inflammatory spread of the cryptococcal mass, laying a foundation for a good final prognosis.

Cryptococcal endocarditis has a low incidence and lacks standardized antifungal management recommendations. Using the recommendations of lung and central nervous system infections, the antifungal strategy for non-human immunodeficiency virus patients is amphotericin B combined with flucytosine fortification, followed by fluconazole. Because of the lack of experience and considering the side effects, we adopted an amphotericin B + fluconazole regimen for our patient. After the 1-month induction period, the long-term regimen of flucytosine and fluconazole also achieved good results.

In summary, we report a case of cryptococcal infective endocarditis of native valves with no history of immunodeficiency, drug use, or underlying heart disease. Prompt diagnosis, timely surgery, and long-term antifungal strategies may be important for a good prognosis.

Declaration of conflicting interest

The authors declare that there is no conflict of interest.


Ethics statement

No ethical approval was required for this case report. Patient details were de-identified. Therefore, consent for publication by the patient was not required.

Funding

This work was supported by the Nanjing Medical Science and Technique Development Foundation.

ORCID iD

Yimin Li  <https://orcid.org/0000-0001-8157-6906>

References

1. Nakajima T, Oba Y, Takashima J, et al. Cryptococcus endocarditis: A case report and review of the literature. *J Infect Chemother* 2019; 25: 901–905.
2. Murdoch DR, Corey GR, Hoen B, et al. Clinical presentation, etiology, and outcome of infective endocarditis in the 21st century: the International Collaboration on Endocarditis-Pro prospective Cohort Study. *Arch Intern Med* 2009; 169: 463–473.
3. Roy M, Ahmad S and Roy AK. Cryptococcus neoformans infective endocarditis of native valves in an immunocompetent host. *IDCases* 2018; 12: 66–70.
4. Velagapudi R, Hsueh YP, Geunes-Boyer S, et al. Spores as infectious propagules of Cryptococcus neoformans. *Infect Immun* 2009; 77: 4345–4355.
5. Mitchell TG and Perfect JR. Cryptococcosis in the era of AIDS—100 years after the discovery of Cryptococcus neoformans. *Clin Microbiol Rev* 1995; 8: 515–548.
6. Lombardo TA, Rabson AS and Dodge HT. Mycotic endocarditis; report of a case due to Cryptococcus neoformans. *Am J Med* 1957; 22: 664–670.
7. Colmers RA, Irniger W and Steinberg DH. Cryptococcus neoformans endocarditis cured by amphotericin B. *JAMA* 1967; 199: 762–764.
8. Child JS, MacAlpin RN, Moyer GH, et al. Coronary ostial embolus and mitral vegetation simulating a left atrial myxoma: a case of probable cryptococcal valvulitis. *Clin Cardiol* 1979; 2: 43–48.
9. Blanc V, Lavarde V, Thanh NT, et al. Postoperative Cryptococcus neoformans endocarditis. *Clin Microbiol Infect* 1996; 2: 66–69.
10. Kowatari R, Suzuki Y, Daitoku K, et al. Cryptococcal infective endocarditis in a child with acute lymphocytic leukaemia. *Interact Cardiovasc Thorac Surg* 2019; 28: 642–644.
11. Couto FM, Macedo DP and Neves RP. Fungemia in a university hospital: an epidemiological approach. *Rev Soc Bras Med Trop* 2011; 44: 745–748.
12. Colombo AL, Nucci M, Park BJ, et al. Epidemiology of candidemia in Brazil: a nationwide sentinel surveillance of candidemia in eleven medical centers. *J Clin Microbiol* 2006; 44: 2816–2823.
13. Perfect JR, Durack DT and Gallis HA. Cryptococemia. *Medicine (Baltimore)* 1983; 62: 98–109.
14. Perfect JR, Dismukes WE, Dromer F, et al. Clinical practice guidelines for the management of cryptococcal disease: 2010 update by the infectious diseases society of America. *Clin Infect Dis* 2010; 50: 291–322.
15. The 2015 ESC Guidelines for the management of infective endocarditis. *Eur Heart J* 2015; 36: 3036–3037.