

# The Clinical Outcomes of Arthroscopic Tenotomy versus Tenodesis with Medium-to-Massive Rotator Cuff Tear in the Elderly: A Retrospective Study

Kaihang Song\*, Guanghua Lu<sup>✉</sup>\*, Ming Cai, Qi Sun

Department of Orthopedics, Shanghai Tenth People's Hospital, School of Medicine, Tongji University, Shanghai, 200072, People's Republic of China

\*These authors contributed equally to this work

Correspondence: Ming Cai; Qi Sun, Email cmdoctor@163.com; tjdxsq@163.com

**Purpose:** Shoulder arthroscopic repair of rotator cuff tears with simultaneous treatment of lesions of the long head of the biceps tendon has become increasingly accepted. However, the clinical outcomes between tenotomy and tenodesis remain unclear. This study aimed to compare the efficacy of tenotomy and tenodesis combined with rotator cuff repair in elderly patients with medium-to-massive rotator cuff tears.

**Patients and Methods:** We conducted a retrospective trial of patients aged > 60 years with medium-to-massive rotator cuff tears who underwent arthroscopic rotator cuff repair with tenotomy or tenodesis. This study included 96 patients: 47 in the tenotomy group and 49 in the tenodesis group. At 3 and 6 months after surgery and at the last follow-up, the American Shoulder and Elbow Surgeons (ASES) score, Constant-Murley score (CS score), anterior shoulder pain (VAS score), elbow flexion strength and supination strength, and complications were recorded.

**Results:** At 3 months postoperatively, ASES score, CS score and strength of elbow flexion of the tenodesis group were significantly better than those of the tenotomy group. In addition, the VAS score is  $4.4 \pm 1.4$  and  $3.3 \pm 1.3$  in the tenodesis and tenotomy respectively ( $p = 0.039$ ). At the final follow-up, despite no significant statistical differences in ASES scores, CS scores, VAS scores, and flexion strength between the two groups, the variation in the above items in the tenodesis group was statistically lower than that in the tenotomy group. No difference was observed in the rates of complications and revision between the groups.

**Conclusion:** For people over 60 years of age with medium to massive rotator cuff tears, postoperative shoulder function of tenodesis is superior to tenotomy, and functional recovery is relatively more stable after tenodesis than after tenotomy.

**Keywords:** tenodesis, tenotomy, aged population, arthroscopy, rotator cuff tear

## Introduction

Lesions of the long head of the biceps tendon (LHBT) are common causes of shoulder pain and dysfunction in patients with rotator cuff injuries.<sup>1</sup> The anecdotal evidence available illustrates that both tenotomy and tenodesis achieve favorable and comparable results in the treatment of LHBT lesions.<sup>2–4</sup> Generally, tenodesis is clinically suggested for younger and high-demand patients, whereas tenotomy should be performed for an aged population with low-demand. For biceps tenotomy, advocates list ease of rehabilitation, fast return to usual activity, low-demand technical requirements, and low complications.<sup>5</sup> However, proponents of tenodesis suggest that it is beneficial for functional recovery, such as supination and flexion strength, and avoidance of cosmetic deformities.<sup>6</sup> Due to the absence of clear evidence-based indicators indicating the superiority or inferiority of the two surgical methods, the determination usually depends on the surgeon's preferences, experience, and individual patient factors.

Despite its effectiveness in the treatment of LHBT lesions, finding about detailed aspects of biceps tenodesis versus tenotomy varied.<sup>5,7-9</sup> Regarding the effect of both procedures on strength, there exists a discrepancy in the evidence published. Specifically, some studies indicated that the difference in elbow flexion or forearm supination strength between the two surgical methods is not significant,<sup>5,7</sup> whereas others have observed a decrement in strength following tenotomy procedures.<sup>10</sup> A systematic review revealed no significant difference in postoperative biceps pain.<sup>8</sup> In relation to the occurrence of cosmetic deformities, some studies exhibit a notable discrepancy in the manifestation of the Popeye sign,<sup>7,8</sup> whereas other investigations did not reveal any significant variance.<sup>9</sup> Hence, the choice between biceps tenodesis and tenotomy remains unclear.

Generally, the demand for activity and age are critical factors that affect the determination of biceps tenodesis and tenotomy. Mirazayan et al<sup>11</sup> reported that younger age and male sex are high-risk factors for complications such as Popeye deformity, subjective weakness, and cramping. Surgeons tend to favor performing tenodesis on young men or patients with high activity demands.<sup>12-14</sup> LHBT tenotomy is potentially the most suitable surgical procedure for elderly patients with low activity requirements.<sup>11</sup> A recent retrospective study compared the difference in efficacy between tenotomy and tenodesis in aged females, they found that tenodesis only yielded earlier pain relief and better biceps strength than biceps tenotomy without other improvements.<sup>15</sup> The female selection, unselection of rotator cuff tear size, and higher rate of loss of follow-up (25%) limit the adaptation of clinical application.

Clinically, the size of rotator cuff tear is typically correlated with shoulder joint function and pain.<sup>6,16</sup> Especially, medium to massive sized rotator cuff tears might largely affect the effect of treatment of LHBT. Furthermore, the elderly population has different demands for movement and pain. There is currently controversy surrounding the effectiveness of biceps tenotomy and tenodesis in treating LHBT lesions in the elderly population. Therefore, the efficacy of biceps tenodesis and tenotomy may yield complex effects in an elderly population with non-small-sized rotator cuff tears. This study aimed to investigate the efficacy of arthroscopic biceps tenodesis and tenotomy performed concurrently with repair of medium-to-massive rotator cuffs for  $\geq 60$ -year-old patients. We hypothesized that biceps tenotomy would not be inferior to tenodesis in terms of clinical outcome in the elderly population.

## Materials and Methods

The retrospective study was conducted to analyze elderly patients who underwent arthroscopic rotator cuff repair with intraoperative confirmation of a lesion of the LHBT in our hospital between June 2020 and June 2022. The inclusion criteria were as follows: performing tenodesis or tenotomy, age  $> 60$  years, symptomatic rotator cuff tears that did not improve after adequate rehabilitation treatment, performing a complete double-row repair, minimum follow-up of 24 months, and confirmation of medium to massive rotator cuff tear. The exclusion criteria were as follows: no rotator cuff tears, massive irreparable tears, active or previous joint infections, glenohumeral osteoarthritis (Hamada stage  $\geq 2$ ), severe cervical disorders or paralysis of the axillary nerve, previous surgery of the affected shoulder, and revision surgery.

## Procedures

Clinical, radiological, and functional outcomes were assessed preoperatively and 3 months, 6 months and at the last follow-up after surgery. Functionality was evaluated as follows: the American Shoulder and Elbow Surgeons (ASES) score, the Constant score, and the visual analog scale for pain (VAS) preoperatively, 3 and 6 months postoperatively and at the latest out-patient clinic. Elbow flexion strength and supination strength were evaluated using a digital force gauge transducer. Tendon tear size preoperatively was roughly measured with Magnetic Resonance Imaging (MRI). The classification of rotator cuff size was finally determined by probe hook with scale under arthroscopy, based on DeOrio and Cofield classification. Tendon integrity at the last follow-up were measured using MRI. The Sugaya classification were adopted for assessment of re-rupture rate.<sup>17</sup> Moreover, complications and incidence of revision were recorded during the entire follow-up period.

## Surgical Procedures

All patients were placed in the lateral decubitus position for all shoulder arthroscopy, which were performed by the same surgeon (M.C). Diagnostic arthroscopy was conducted using a standard posterior portal. The assessment of biceps tendon

was performed via a standard anterior interval portal. If medium-to-massive rotator cuff tears and inflammation, instability, and tearing of the LHBT or injury of the superior labrum attachment were identified, the patient's eligibility was confirmed.

When performing tenotomy, an arthroscopic electrothermal scalpel is utilized to detach the LHBT from its attachment site on the superior labrum. During tenodesis, the LHBT was fixed using a SiveLock (Arthrex) and a TWINFIX Suture Anchor (Smith & Nephew) with an arthroscopic suprapectoral approach after detachment. Subsequently, subacromial pathology and rotator cuff conditions were assessed. When necessary, utilize the cutting block technique to perform subacromial decompression. The rotator cuff tear was repaired using a Suture Bridge with Mason-Allen sutures via standard anterolateral and posterolateral portals.

## Postoperative Care and Rehabilitation

The postoperative rehabilitation programs for both groups were the same. With sling immobilization for 4–6 weeks, gentle passive motion of the shoulder, including elevation, abduction, and non-resisted elbow flexion, was allowed immediately after surgery. Active movement was not allowed until 4–6 weeks after the surgery. After reaching the maximum range of motion, resistance training is permitted, and exercise can commence 6 months post-surgery.

## Sample Size Calculation

As described by previous literature,<sup>18</sup> the minimal clinical detectable difference of the ASES score were a difference of 9.7 points (standard deviation at 16.5 points). With setting of alpha at 0.05 and power at 0.80, the minimum of sample size per group was set to be 45 patients.

## Ethical Considerations

All procedures and data collection were performed prior to approval by the Ethics Committee of Shanghai Tenth People's Hospital, in accordance with the Declaration of Helsinki. Written informed consent was secured from all participants before their inclusion in the study.

## Statistical Analysis

In this study, the statistical analyses were conducted using the IBM Statistics SPSS version 19.0 software package. The descriptive statistics are presented in the form of mean  $\pm$  standard deviations (SDs) for continuous variables, and frequencies (percentages) for nominal data. For the comparison of demographic and clinical characteristics and outcomes between groups, Student's *t*-tests were employed for normally distributed continuous variables, while Mann–Whitney *U*-tests were used for non-normally distributed continuous variables. Fisher's exact test was utilized to analyze the nominal data. A  $p < 0.05$  was deemed to be statistically significant.

## Results

A total of 96 participants were included in this study (biceps tenodesis group,  $n = 49$ ; biceps tenotomy group,  $n = 47$ ) between June 2020 and June 2022. The demographic characteristics, preoperative subjective scores (Table 1) and intraoperative finding (Table 2) were comparable between the groups. In detail, the differences in sex distribution, age, BMI, surgical side, and previous occupation were not significant between the tenodesis and tenotomy groups. Regarding the length of follow-up, patients in both groups completed a minimum of follow-up of 24 months, which were  $29.3 \pm 4.2$  and  $29.9 \pm 3.8$  months in tenodesis and tenotomy group respectively ( $p = 0.525$ ). The average of operative time was  $79.5 \pm 27.4$  minutes in the tenodesis group, much longer than  $62.2 \pm 23.9$  minutes in the tenotomy group ( $P = 0.045$ ). The time from occurrence of symptom to surgery were  $11.4 \pm 5.8$  and  $13.7 \pm 5.6$  months without statistical difference. The size of rotator cuff tears, including medium size, large size, and massive size, was almost identical between two groups ( $p = 0.678$ ). SLAP tear occurred 25 in the tenodesis group and 23 in the tenodesis and tenotomy group, respectively ( $p = 0.838$ ). Regarding additional arthroscopic treatment, there were 27 cases of acromioplasty, and 34 cases of arthroscopic release in the tenodesis group, and 22 cases of acromioplasty, and 29 cases of arthroscopic release in the tenotomy group; these items were not significantly different (Table 2).

**Table 1** Baseline Characteristics of Patients

Variables	Tenodesis (n=49)	Tenotomy (n=47)	p value
Gender			
Male	30	25	0.536
Female	19	22	
Age	73.7±10.9	71.3 ± 9.7	0.429
BMI (kg/m <sup>2</sup> )	23.3 ± 1.9	23.14 ± 1.8	0.381
Surgical side (dominant)	29	20	0.153
Previous occupation			0.299
Labor	17	22	
Non-labor	32	25	
Follow-up (months)	29.3 ± 4.2	29.9 ± 3.8	0.525

**Table 2** The Intraoperative Findings and Procedures of Both Tenodesis and Tenotomy Group

Variables	Tenodesis Group (n=49)	Tenotomy Group (n=47)	p value
Operative time, min	79.5 ± 27.4	62.2 ± 23.9	0.045
Rotator cuff tear			
Medium sized tear	23	22	0.678
Large sized tear	18	20	
Massive sized tear	8	5	
SLAP tears	25	23	0.838
Additional surgical procedures			
Acromioplasty	27	22	0.416
Arthroscopic release	34	29	0.428
Time to surgery, months	11.4 ± 5.8	13.7±5.6	0.341

**Table 3** Subjective and Functional Outcomes by Group at Each Time Point

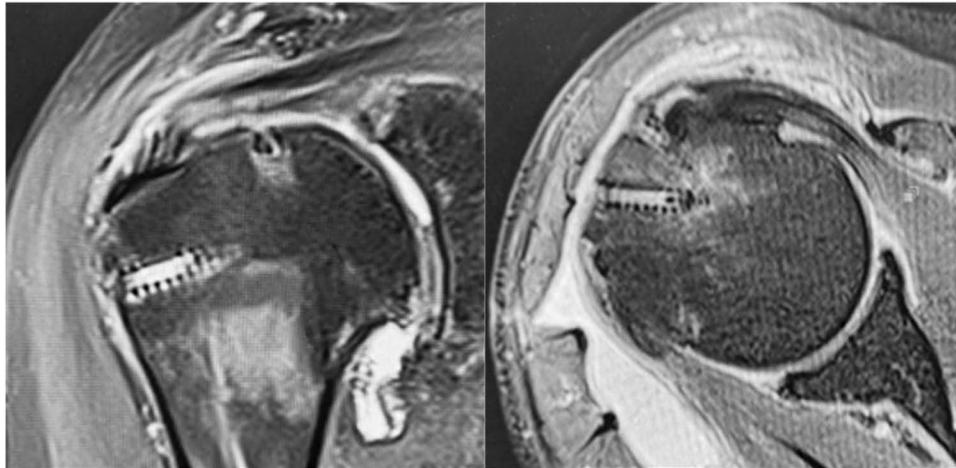
		Preoperative	3 Months Postoperative	6 Months Postoperative	Last Follow-Up
ASES score	Tenodesis	51.3 ± 11.9	68.2 ± 9.1*	77.3 ± 7.2 <sup>#</sup>	82.1 ± 6.8 <sup>#</sup>
	Tenotomy	48.9 ± 10.6	61.2 ± 8.9	75.7 ± 11.2	78.0 ± 11.9
CS score	Tenodesis	49.8 ± 9.7	66.7 ± 8.1*	76.7 ± 7.6 <sup>#</sup>	81.1 ± 6.7 <sup>#</sup>
	Tenotomy	50.2 ± 10.4	60.9 ± 8.7	75.9 ± 10.2	79.0 ± 11.4
VAS pain score	Tenodesis	5.5± 2.4	4.4 ± 1.4*	3.2 ± 1.2	2.6 ± 1.1 <sup>#</sup>
	Tenotomy	5.4± 2.6	3.3 ± 1.3	3.0 ± 1.7	2.5 ± 1.7
Flexion strength, kg	Tenodesis	10.3 ± 5.7	17.4 ± 6.2*	17.9 ± 5.2 <sup>#</sup>	18.1 ± 3.1 <sup>#</sup>
	Tenotomy	10.7 ± 6.2	14.7 ± 6.8	15.7 ± 4.8	16.3 ± 5.3
Supination strength, kg	Tenodesis	2.3 ± 1.2	2.7 ± 1.4	3.0 ± 1.6	3.2 ± 1.4
	Tenotomy	2.1 ± 1.2	2.6 ± 1.6	2.9 ± 1.8	3.1 ± 1.9

**Notes:** \*Indicates statistically significant difference between two groups. <sup>#</sup> indicates statistically significant difference in variation between two groups.

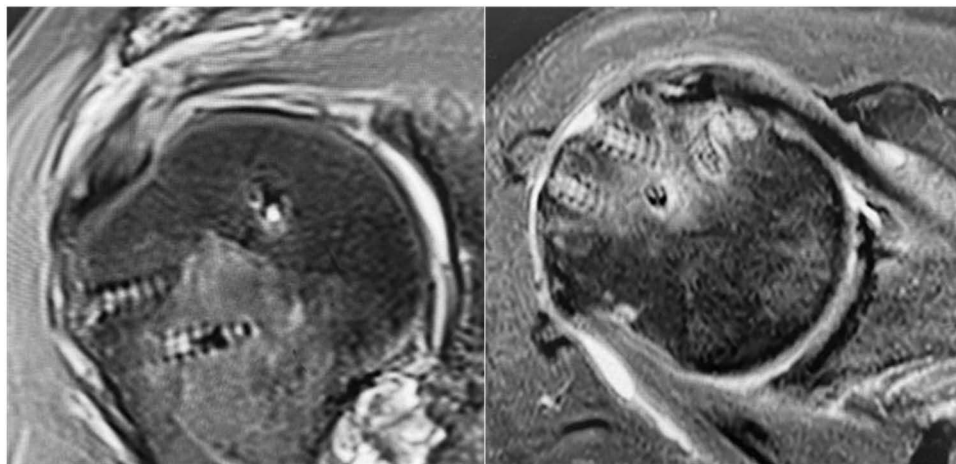
The functional scores and physical assessments according to group and time point is summarized in Table 3. Significant improvements of both ASES and CS scores were observed in both groups from baseline to the last follow-up. The tenodesis group showed a significantly higher ASES scores, from the baseline to the last follow-up. Meanwhile,

statistical difference was observed in ASES scores between two groups ( $68.2 \pm 9.1$  versus  $61.2 \pm 8.9$ ) at 3 months postoperatively. Moreover, the variance in ASES scores was significantly lower in the tenodesis group from 6 months to last follow-up postoperatively, indicating that tenodesis guarantees the anticipated stable shoulder function other than tenotomy. Similarly, the CM scores improved from the baseline to the last follow-up. There were also significantly increased CM scores in the tenodesis group than in the tenotomy group 3 months postoperatively.

From the presurgery to the last follow-up, both groups showed great improvement in both strength of elbow flexion and forearm supination. During the entire follow-up period, shoulder strength was higher in the tenodesis group, but only flexion strength was significantly higher in the tenodesis group at 3 months postoperatively. There was average difference of 1.8 kg in strength of elbow flexion and average difference of 0.1 kg in supination strength between tenodesis group and tenotomy group. In particular, the variance in elbow flexion in the tenodesis group was much lower at six months postoperatively and at the last follow-up. Pain improvement occurred significantly from 3 months to the last follow-up postoperatively with a mean decrease of 2.6, as reflected by the VAS scores. The VAS score was significantly higher at 3 months postoperatively, and the variance in the VAS scores was much lower at the last follow-up in the tenodesis group. Rotator cuff integrity postoperatively was classified into type 1 for 18, type 2 for 20, type 3 for 9, type 4 for 2, and type 5 for 0 patient in the tenodesis group and type 1 for 16, type 2 for 19, type 3 for 9, type 4 for 2, and type 5 for 1 patient in the tenotomy group respectively ( $p=0.894$ ). The representative images of MRI scanning of patients undergoing arthroscopic repair of rotator cuff tear and biceps tenodesis or tenotomy was shown in Figures 1 and 2.

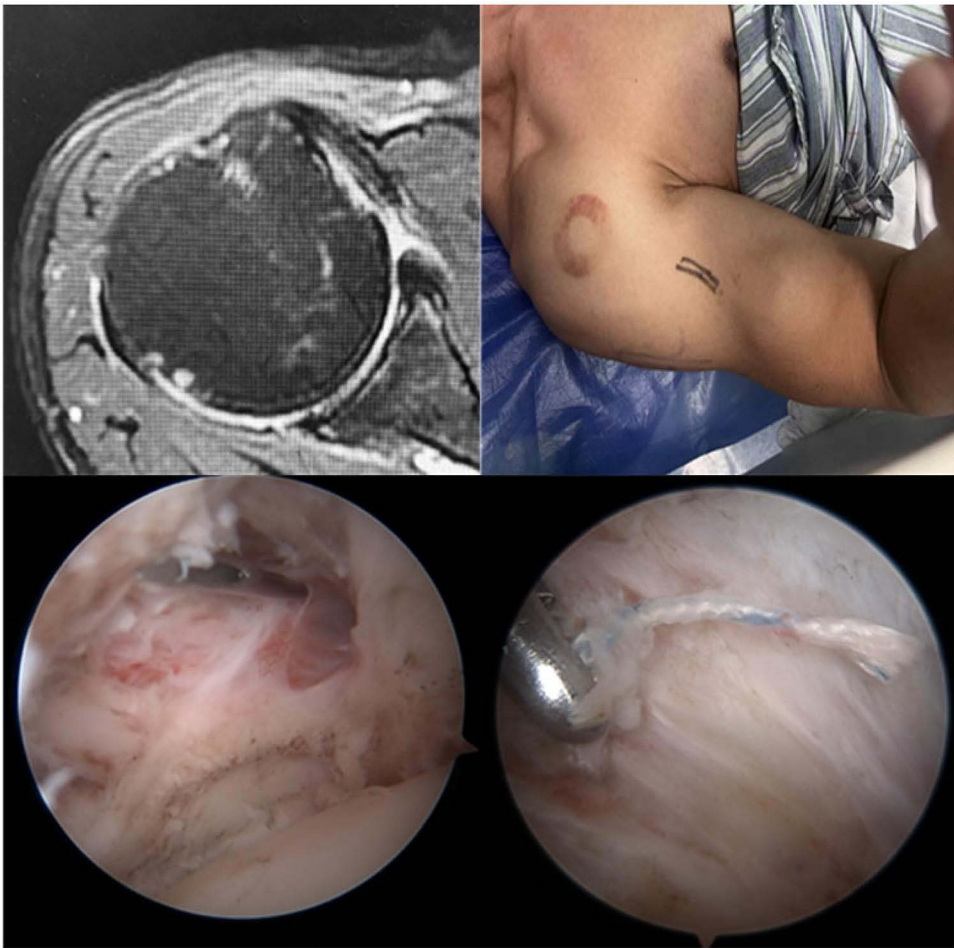


**Figure 1** Representative images of MRI scanning of patients undergoing arthroscopic repair of rotator cuff tear and biceps tenotomy. Left panel: sagittal view. Right panel: coronal view.



**Figure 2** Representative images of MRI scanning of patients undergoing arthroscopic repair of rotator cuff tear and biceps tenodesis. Left panel: sagittal view. Right panel: coronal view.





**Figure 3** Upper left panel: Representative coronal view of MRI scanning of patients with failure of fixation of biceps after arthroscopic repair of rotator cuff tear and biceps tenodesis. Upper right panel: image of “Popeye lump”. Lower left panel: image of empty biceps groove. Lower right panel: image of failed fixation of biceps tendon after tenodesis.

The total rates of postoperative complications in the tenodesis and tenotomy group were comparable ( $p=0.563$ ). Five cases of subjective Popeye deformity were observed after tenotomy, which was significantly higher than that after tenodesis. The representative coronal view of MRI scanning and arthroscopic image of patients with failure of fixation of biceps after arthroscopic repair of rotator cuff tear and biceps tenodesis were shown in [Figure 3](#). In addition, there were no significant differences in weakness or fatigue discomfort between the tenodesis and tenotomy groups ([Table 4](#)). There were five cases of reoperation in the tenotomy group, of which three patients switched to tenodesis, both due to persistent anterior shoulder pain. Another 2 patients developed postoperative limited shoulder function due to rotator cuff retear, as

**Table 4** Frequency and Type of Postoperative Complications

Variables	Tenodesis (n=49)	Tenotomy (n=47)	p value
Popeye deformity	1	5	0.082
Weakness	2	2	0.996
Fatigue discomfort	3	4	0.653
Cramping pain	7	2	0.092
Reoperation	3	5	0.424
Total	16	18	0.563
Total person	12	15	0.419

**Table 5** The Detail of Complication Treatment

Patient Number	Additional Surgery Time, Months	Additional Biceps Surgery	Additional Other Procedures	ASES, %		Pain	
				pre	post	pre	post
Tenodesis Group							
1	8	Tenodesis revision	Rotator cuff exploration	48	68	5	3
2	13	Tenodesis revision	Rotator cuff exploration	56	67	4	3
3	15	/	Distal clavicle excision, rotator cuff examination, debridement and synovectomy	52	70	4	2
Tenotomy Group							
1	13	Tenodesis	Rotator cuff exploration, debridement and excision	45	59	5	3
2	21	/	Revision decompression	57	73	5	2
3	9	/	Distal clavicle excision, rotator cuff examination, debridement and synovectomy	61	84	6	3
4	16	Tenodesis	Rotator cuff exploration and debridement	53	70	7	3
5	17	Tenodesis	Rotator cuff examination, debridement and synovectomy	60	81	6	4

confirmed by MRI. The patients underwent arthroscopic repair of the rotator cuff. There were 3 cases of reoperation in the tenodesis group because of persistent anterior shoulder pain, 2 of which underwent tenodesis revision. The third patient underwent an arthroscopic rotator cuff repair procedure for a rotator cuff retear. (Table 5).

## Discussion

In this study, both tenodesis and tenotomy achieved favorable outcomes in treating LHBT lesions in terms of functional and pain scores in elderly patients with concomitant rotator cuff injuries. Despite no significant difference in functional and pain scores between the two groups at the final follow-up, the tenodesis group exhibited better functional scores at 3 months than the tenotomy group, possibly due to the preservation of biceps tendon function and strength. Several recently published meta-analyses that compared tenodesis and tenotomy have yielded similar results.<sup>19–21</sup> Additionally, we observed that the tenodesis group achieved more stable functional scores postoperatively, as indicated by the lower variance in ASES scores, CS scores, VAS scores, and elbow flexion strength at 6 months and at the last follow-up postoperatively. These results did not align with our hypothesis.

However, no statistically significant difference was observed in CMS and ASES scores between the two groups at the final follow-up. Consistent with most current reports, although with varying levels of evidence, the majority of relevant literature has failed to demonstrate any functional outcome differences between biceps tenodesis and tenotomy.<sup>22–25</sup> Because the LHBT functions more as a shoulder stabilizing structure than an elbow movement structure, functional testing is limited. The strength of elbow flexion and forearm supination may not truly reflect the role of the LHBT. The functional outcomes of these two surgeries are similar, possibly because both tenodesis and tenotomy neutralize the shoulder stabilizing effects of the LHBT.<sup>22</sup> Additionally, since the patients included in this study were elderly individuals aged 60 years or older, the lack of strength after tenotomy may have had a minimal impact on their daily lives. Notably, shoulder function in the tenodesis group was much more stable and predictable, as reflected by lower deviation.

Our findings indicate that the postoperative functional scores were more stable in the tenodesis group, possibly because of the preservation of biceps tendon function and strength. This implies that tendon fixation surgery may be preferable for elderly patients or for those with relatively higher shoulder functional demands. We speculate that in patients with LHBT lesions and rotator cuff injury, when LHBT lesions rather than rotator cuff injury become the main cause of pain and functional impairment, direct tenotomy may benefit the patients more. In contrast, tenotomy may result in a certain degree of functional loss to the LHBT compared with tenodesis.

Biomechanically, the LHBT is critical for shoulder stabilization and is closely associated with shoulder function. Kumar et al<sup>26</sup> reported that tenotomy can cause the upward migration of the humeral head, leading to a decrease in acromiohumeral distance, which is associated with rotator cuff tears, and distances less than 7 millimeters are typically associated with degenerative rotator cuff diseases.<sup>27,28</sup> In our study, double-row arthroscopic rotator cuff repair was used for all patients to preserve more acromiohumeral distance,<sup>29</sup> which may reduce possibility of subacromial impingement. That may explain the lower re-rupture rate in our study. The biceps also facilitate forearm movements, especially forearm supination and elbow flexion. Spontaneous LHBT ruptures have been reported to lead to a 20% decrease in forearm supination strength and an 8%–20% decrease in elbow flexion strength.<sup>13</sup> Besides, Lee et al<sup>14</sup> found a significant decrease in supination strength after tenotomy compared to tenodesis based on isometric testing 12 months postoperatively, with a greater side-to-side difference. Wittstein et al<sup>30</sup> demonstrated limited peak supination torque other than the peak flexion torque or endurance in either motion with tenotomy versus tenodesis. In our study, neither supination nor flexion strength showed statistical differences between tenodesis and tenotomy at six months postoperatively. The similar outcomes of supination and flexion may be attributed to the age and size of the rotator cuff. Elderly patients have a much lower demand for supination and flexion strength in daily activities. Second, despite the recovery of rotator cuff tears, the large size affects shoulder strength; therefore, the effect of treatment of the biceps was covered.

In addition to the improvement in functionality, both surgical procedures have been proven effective in alleviating pain, considering that the LHBT pathology itself contributes to shoulder pain. Tenotomy can significantly alleviate pain during motion and tenderness upon palpation.<sup>31</sup> Walch et al<sup>32</sup> recommended tenotomy as a palliative treatment for patients with irreparable rotator cuff tears. Some studies suggest that the postoperative pain levels are similar for both procedures,<sup>8,13</sup> while others indicate that patients undergoing tenotomy experience milder pain and faster relief compared to the other approach,<sup>33,34</sup> which may be related to the presence of implant in the bicipital groove.<sup>2</sup> In our study, there was no significant difference in VAS scores between the two groups at the last follow-up. This may be partly attributed to the inclusion of elderly patients aged  $\geq 60$  years with reduced shoulder movement. Concomitant rotator cuff injuries may also affect pain assessment.

This study has certain limitations. Firstly, this study shares similar limitations with other retrospective studies, and the selection of surgical approach was not randomized. Second, we compared tenodesis and tenotomy in older patients undergoing rotator cuff repair; however, our findings may not be applicable to isolated LHBT lesions or to younger patients. Third, due to the simultaneous repair of rotator cuff tears, it is difficult to determine the impact of tenodesis and tenotomy alone on the shoulder and elbow function in this study. Fourth, all patients in this study were followed up for at least two years after surgery, which may require longer follow-up times to determine the final prognosis of the two surgical methods.

In the future, further development of clinical evaluation scales for LHBT is needed. At the same time, more high-quality clinical studies are needed to explore the long-term effects of LHBT surgery on the progression of rotator cuff tears and shoulder function.

## Conclusion

For people over 60 years of age with medium-to-massive rotator cuff tears, both arthroscopic tenotomy and tenodesis with rotator cuff repair can achieve good results. Postoperative shoulder function after tenodesis improves prior to tenotomy, and functional recovery is relatively more stable after tenodesis than after tenotomy. Tenotomy and tenodesis are equally effective for improving postoperative pain and preventing Popeye deformities.

## Acknowledgments

This study was supported by the National Natural Science Foundation of China (Grant nos. 82102602, 82272176).

## Disclosure

The authors declare that they have no known competing financial interests or personal relationships that could have appeared to influence the work reported in this paper.



## References

- Descamps J, Kierszbaum E, Protais M, et al. Outcomes of isolated biceps tenodesis/tenotomy or partial rotator cuff repair associated with biceps tenodesis/tenotomy for massive irreparable tears: a systematic review. *J Clin Med*. 2023;12(7):2565. doi:10.3390/jcm12072565
- Zabrzynski J, Huri G, Gryckiewicz S, et al. Biceps tenodesis versus tenotomy with fast rehabilitation protocol-a functional perspective in chronic tendinopathy. *J Clin Med*. 2020;9(12):3938. doi:10.3390/jcm9123938
- Checchia SL, Doneux PS, Miyazaki AN, et al. Biceps tenodesis associated with arthroscopic repair of rotator cuff tears. *J Shoulder Elbow Surg*. 2005;14(2):138–144. doi:10.1016/j.jse.2004.07.013
- Belk JW, Kraeutler MJ, Houck DA, et al. Biceps tenodesis versus tenotomy: a systematic review and meta-analysis of level I randomized controlled trials. *J Shoulder Elbow Surg*. 2021;30(5):951–960. doi:10.1016/j.jse.2020.11.012
- Frost A, Zafar MS, Maffulli N. Tenotomy versus tenodesis in the management of pathologic lesions of the tendon of the long head of the biceps brachii. *Am J Sports Med*. 2009;37(4):828–833. doi:10.1177/0363546508322179
- Werner BC, Brockmeier SF, Gwathmey FW. Trends in long head biceps tenodesis. *Am J Sports Med*. 2015;43(3):570–578. doi:10.1177/0363546514560155
- Koh KH, Ahn JH, Kim SM, et al. Treatment of biceps tendon lesions in the setting of rotator cuff tears: prospective cohort study of tenotomy versus tenodesis. *Am J Sports Med*. 2010;38(8):1584–1590. doi:10.1177/0363546510364053
- Slenker NR, Lawson K, Ciccotti MG, et al. Biceps tenotomy versus tenodesis: clinical outcomes. *Arthroscopy*. 2012;28(4):576–582. doi:10.1016/j.arthro.2011.10.017
- Osbahr DC, Diamond AB, Speer KP. The cosmetic appearance of the biceps muscle after long-head tenotomy versus tenodesis. *Arthroscopy*. 2002;18(5):483–487. doi:10.1053/jars.2002.32233
- Werner BC, Evans CL, Holzgrefe RE, et al. Arthroscopic suprapectoral and open subpectoral biceps tenodesis: a comparison of minimum 2-year clinical outcomes. *Am J Sports Med*. 2014;42(11):2583–2590. doi:10.1177/0363546514547226
- Mirzayan R, McCrum C, Butler RK, et al. Risk factors and complications following arthroscopic tenotomy of the long head of the biceps tendon. *Orthop J Sports Med*. 2020;8(2):2325967120904361. doi:10.1177/2325967120904361
- Hsu AR, Ghodadra NS, Provencher CDRMT, et al. Biceps tenotomy versus tenodesis: a review of clinical outcomes and biomechanical results. *J Shoulder Elbow Surg*. 2011;20(2):326–332. doi:10.1016/j.jse.2010.08.019
- Meraner D, Sternberg C, Vega J, et al. Arthroscopic tenodesis versus tenotomy of the long head of biceps tendon in simultaneous rotator cuff repair. *Arch Orthop Trauma Surg*. 2016;136(1):101–106. doi:10.1007/s00402-015-2343-2
- Lee HJ, Jeong J-Y, Kim C-K, et al. Surgical treatment of lesions of the long head of the biceps brachii tendon with rotator cuff tear: a prospective randomized clinical trial comparing the clinical results of tenotomy and tenodesis. *J Shoulder Elbow Surg*. 2016;25(7):1107–1114. doi:10.1016/j.jse.2016.02.006
- Kawashima I, Sugaya H, Takahashi N, et al. Biceps tenotomy versus soft-tissue tenodesis in females aged 60 years and older with rotator cuff tears. *J Orthop Sci*. 2022;27(4):786–791. doi:10.1016/j.jos.2021.04.012
- Bedi A, Bishop J, Keener J, et al. Rotator cuff tears. *Nat Rev Dis Primers*. 2024;10(1):8. doi:10.1038/s41572-024-00492-3
- Sugaya H, Maeda K, Matsuki K, et al. Functional and structural outcome after arthroscopic full-thickness rotator cuff repair: single-row versus dual-row fixation. *Arthroscopy*. 2005;21(11):1307–1316. doi:10.1016/j.arthro.2005.08.011
- Michener LA, McClure PW, Sennett BJ. American shoulder and elbow surgeons standardized shoulder assessment form, patient self-report section: reliability, validity, and responsiveness. *J Shoulder Elbow Surg*. 2002;11(6):587–594. doi:10.1067/mse.2002.127096
- Zhang C, Yang G, Li T, et al. Biceps tenodesis better improves the shoulder function compared with tenotomy for long head of the biceps tendon lesions: a meta-analysis of randomised controlled trials. *J Clin Med*. 2023;12(5):1754.
- Liu H, Song X, Liu P, et al. Clinical outcomes of arthroscopic tenodesis versus tenotomy for long head of the biceps tendon lesions: a systematic review and meta-analysis of randomized clinical trials and cohort studies. *Orthop J Sports Med*. 2021;9(4):2325967121993805. doi:10.1177/2325967121993805
- Vajda M, Szakó L, Hegyi P, et al. Tenodesis yields better functional results than tenotomy in long head of the biceps tendon operations-A systematic review and meta-analysis. *Int Orthop*. 2022;46(5):1037–1051. doi:10.1007/s00264-022-05338-9
- MacDonald P, Verhulst F, McRae S, et al. Biceps tenodesis versus tenotomy in the treatment of lesions of the long head of the biceps tendon in patients undergoing arthroscopic shoulder surgery: a prospective double-blinded randomized controlled trial. *Am J Sports Med*. 2020;48(6):1439–1449. doi:10.1177/0363546520912212
- Malavolta EA, Sousa ACD, Gracitelli MEC, et al. Biceps tenotomy or tenodesis in association with rotator cuff repair: is there an influence on functional results? A retrospective cohort study. *Sao Paulo Med J*. 2022;140(2):237–243. doi:10.1590/1516-3180.2021.0219.r1.28062021
- Kukkonen J, Rantakokko J, Virolainen P, et al. The effect of biceps procedure on the outcome of rotator cuff reconstruction. *ISRN Orthop*. 2013;2013:840965. doi:10.1155/2013/840965
- Kim J, Nam JH, Kim Y, et al. Long head of the biceps tendon tenotomy versus subpectoral tenodesis in rotator cuff repair. *Clin Orthop Surg*. 2020;12(3):371–378. doi:10.4055/cios19168
- Kumar VP, Satku K, Balasubramaniam P. The role of the long head of biceps brachii in the stabilization of the head of the humerus. *Clin Orthop Relat Res*. 1989;244:172–175.
- McCreesh KM, Crotty JM, Lewis JS. Acromiohumeral distance measurement in rotator cuff tendinopathy: is there a reliable, clinically applicable method? A systematic review. *Br J Sports Med*. 2015;49(5):298–305. doi:10.1136/bjsports-2012-092063
- Chin K, Chowdhury A, Leivadiotou D, et al. The accuracy of plain radiographs in diagnosing degenerate rotator cuff disease. *Shoulder Elbow*. 2019;11(1 Suppl):46–51. doi:10.1177/1758573217743942
- Turan K, Çabuk H, Köroğlu C, et al. Increased acromiohumeral distance in a double-row arthroscopic rotator cuff surgery compared to a single-row surgery after 12 months. *J Orthop Surg Res*. 2021;16(1):385. doi:10.1186/s13018-021-02523-1
- Wittstein JR, Queen R, Abbey A, et al. Isokinetic strength, endurance, and subjective outcomes after biceps tenotomy versus tenodesis: a postoperative study. *Am J Sports Med*. 2011;39(4):857–865. doi:10.1177/0363546510387512
- Kelly AM, Drakos MC, Fealy S, et al. Arthroscopic release of the long head of the biceps tendon: functional outcome and clinical results. *Am J Sports Med*. 2005;33(2):208–213. doi:10.1177/0363546504269555

32. Walch G, Edwards TB, Boulahia A, et al. Arthroscopic tenotomy of the long head of the biceps in the treatment of rotator cuff tears: clinical and radiographic results of 307 cases. *J Shoulder Elbow Surg.* 2005;14(3):238–246. doi:10.1016/j.jse.2004.07.008
33. Friedman JL, FitzPatrick JL, Rylander LS, et al. Biceps tenotomy versus tenodesis in active patients younger than 55 years: is there a difference in strength and outcomes? *Orthop J Sports Med.* 2015;3(2):2325967115570848. doi:10.1177/2325967115570848
34. Belay ES, Wittstein JR, Garrigues GE, et al. Biceps tenotomy has earlier pain relief compared to biceps tenodesis: a randomized prospective study. *Knee Surg Sports Traumatol Arthrosc.* 2019;27(12):4032–4037. doi:10.1007/s00167-019-05682-1

## Clinical Interventions in Aging

### Publish your work in this journal

Clinical Interventions in Aging is an international, peer-reviewed journal focusing on evidence-based reports on the value or lack thereof of treatments intended to prevent or delay the onset of maladaptive correlates of aging in human beings. This journal is indexed on PubMed Central, MedLine, CAS, Scopus and the Elsevier Bibliographic databases. The manuscript management system is completely online and includes a very quick and fair peer-review system, which is all easy to use. Visit <http://www.dovepress.com/testimonials.php> to read real quotes from published authors.

Submit your manuscript here: <https://www.dovepress.com/clinical-interventions-in-aging-journal>

**Dovepress**  
Taylor & Francis Group