

Bronchial Artery-Pulmonary Artery Shunt by *Apiotrichum mycotoxinivorans* Infection in a Recurrent Hemoptysis Case

Yu Pang¹, Diefei Hu¹, Yiwu Dang², Siming Huang³, Lanhui Qin⁴, Meng Li⁵

¹Department of Infectious Disease, First Affiliated Hospital of Guangxi Medical University, Nanning, Guangxi, 530021, People's Republic of China;

²Department of Pathology, First Affiliated Hospital of Guangxi Medical University, Nanning, Guangxi, 530021, People's Republic of China; ³Department of Respiratory Medicine, First Affiliated Hospital of Guangxi Medical University, Nanning, Guangxi, 530021, People's Republic of China; ⁴Department of Radiology, First Affiliated Hospital of Guangxi Medical University, Nanning, Guangxi, 530021, People's Republic of China; ⁵Department of Clinical Laboratory, First Affiliated Hospital of Guangxi Medical University, Nanning, Guangxi, 530021, People's Republic of China

Correspondence: Meng Li, Department of Clinical Laboratory, First Affiliated Hospital of Guangxi Medical University, Nanning, Guangxi, 530021, People's Republic of China, Tel/Fax +8613367809642, Email gxmulinmeng@foxmail.com

Background: *Apiotrichum mycotoxinivorans* is a rare mycotoxinivorans, and its pathogenicity is unknown. Bronchial artery shunt is a pathophysiological state following congenital or acquired chronic infection. We report a rare case of bronchial artery shunt by *A. mycotoxinivorans* infection in a recurrent hemoptysis patient.

Case Presentation: A 45-year-old female presented with recurrent cough and hemoptysis for 4 years. Before admission, she had been treated in several hospitals for pulmonary tuberculosis and bronchiectasis and received standardized anti-tuberculosis treatment for 1 year, but it was ineffective. After admission, CTPA and bronchial arterial angiography showed left bronchial artery–left pulmonary artery shunt and right bronchial artery–right pulmonary artery shunt. Fiber-optic bronchoscopy was performed, which revealed a large amount of purulent secretions, bronchoalveolar lavage fluid fungi (1-3)- β -d glucan: 728.06, and GM test: 3.239. Fungal hyphae and spores were observed by gram staining of BALF smear. Acid-fast bacilli were not found in BALF smear and brush smear. Two consecutive BALF fungal cultures grew *A. mycotoxinivorans*, the identity of which was confirmed by internal-transcribed-spacer (ITS) sequencing. Intravenous amphotericin B liposome (30mg; 0.5mg/kg, QD) was given for 2 weeks, embolization was performed, and itraconazole (voriconazole allergy) was taken orally for 9 months after operation. Hemoptysis and pulmonary lesions gradually improved after treatment.

Conclusion: We report the first case of bronchial artery–pulmonary artery shunt in a patient diagnosed with *A. mycotoxinivorans* infection. Phagocytosis of fungi by leukocytes was observed, and the pathogenicity of the fungus was confirmed in order to heighten the awareness of these infections.

Keywords: *Apiotrichum mycotoxinivorans*, bronchial artery–pulmonary artery shunt, hemoptysis, infection

Introduction

Apiotrichum mycotoxinivorans (formerly *Trichosporon mycotoxinivorans*)¹ is a rare pathogenic *Trichosporon* that can inhabit soil, river, and farm animals. It is a yeast isolated from the hindgut of lower termite *Mastotermes darwiniensis* (Mastotermitidae) in 2004² and represents a new member of the genus *Trichosporon*. Its pathogenicity was unknown until 2009; Hickey et al³ reported the first human case of *A. mycotoxinivorans* infection, who died of histologically documented *Trichosporon* species pneumonia with cystic fibrosis (CF). It was suggested that *A. mycotoxinivorans* was a newly discovered pathogen, which seems to have a certain predisposition to CF patients. *A. mycotoxinivorans* has since been isolated from the sputum and blood samples of cystic fibrosis patients. Searches online has found that only 8 clinical cases of this fungal infection had been reported in PubMed until now, including CF patients (6/8) and non-CF patients (2/8). There was a case with CF died of disseminated infection for *A. mycotoxinivorans* after liver and lung transplantation.⁴ There was another case of disseminated infection for *A. mycotoxinivorans* after dialysis in chronic renal failure.⁵ In addition, there was a pediatric patient

of *A. mycotoxinivorans* isolated in congenital ventricular septal defect complicated with pneumonia, which was found after surgery.⁶ There was another case of *A. mycotoxinivorans* isolated in a 70-year-old female patient with cirrhosis accompanied by chronic bronchial infection (CBI), which was detected with *Cryptococcus*.⁷ In these two cases, only fungi were isolated without sufficient evidence of pathogenicity.

Chronic infection or long-term asymptomatic colonization was more common in CF patients with normal immune function. Shah et al⁸ reported a long-term follow-up of 4 children with CF, and none of their patients had fulminant disease associated with initial isolation of *A. mycotoxinivorans* and 2 of them could be improved without antifungal therapy. Goldenberger et al⁹ reported a case of CF patient with *A. mycotoxinivorans*, who was followed up for 9 years and presented mild pulmonary symptoms, which could be improved after antifungal treatment. Martinez Muniz et al¹⁰ reported a case of 37-year-old CBI patient with *A. mycotoxinivorans*, who showed no signs of clinical, radiological or functional deterioration during a 5-year follow-up.

These cases suggest that *A. mycotoxinivorans* infection is rare, whose host status and clinical manifestation varied in these patients. Few cases progress rapidly and can be severe or even fatal. In some cases, it could also manifest as nonpathogenic colonization or chronic airway infection. The exact host and mechanism are still unknown. Interestingly, bronchial artery–pulmonary artery shunt is also not common. We report the first case of bronchial artery–pulmonary artery shunt in a patient (non-CF patients) diagnosed with *A. mycotoxinivorans* infection. More importantly, the pathogenicity of the fungus was confirmed, and it is very rare and critical to our understanding and increasing our experience of the disease.

Case Presentation

A 45-year-old female patient, a city greening worker and was in good health before onset, was admitted to a local hospital in October 2017 due to cough and hemoptysis. At that time, she was diagnosed with pneumonia and bronchiectasis. She was given cephalosporin anti-infective therapy, but it did not work. Then, between January and March 2018, she visited other hospitals several times and was diagnosed with tuberculosis due to imaging findings (no *Mycobacterium tuberculosis* was found in sputum). Therefore, from April 2018 to April 2019, the patient received conventional (2HRZE/9HE) anti-TB therapy for about 1 year, but it was ineffective; cough and hemoptysis continued to occur repeatedly. Therefore, in November 2019, she came to our hospital for treatment. After admission, tuberculosis bacteria culture in sputum in November 2019 showed no *M. tuberculosis* complex group. Blood tests showed that the WBC was $5.42 \times 10^9/L$, the percentage of neutrophil was 0.77, the erythrocyte sedimentation rate was 58mm, PCT was 0.078ng/mL, and the C-reactive protein was 62mg/L; sputum smear was negative for acid-fast bacilli; and HIV antibodies were negative and antinuclear antibody was positive (1:1000). CTPA showed the following: Filling defect was observed in the main pulmonary artery, bronchial artery diameter was widened, and irregular patchy and nodular density was observed in both lungs (Figure 1A and B). Fiber-optic bronchoscopy was performed, which revealed a large amount of purulent secretions, bronchoalveolar lavage fluid (BALF) fungi (1-3)- β -d glucan: 728.06, and GM test: 3.239. Pleomorphic fungi were observed by gram staining of BALF smear (Figure 2A and B). Acid-fast bacilli were not found in BALF smear and brush smear. Cryptococcus latex agglutination test was negative. No bacteria were cultured in BALF. No bacteria, fungi, viruses, parasites, *M. tuberculosis*, mycoplasma, chlamydia, or rickettsia were found by mNGS (BALF).

CTPA and bronchial arterial angiography showed left bronchial artery–left pulmonary artery shunt (Figure 1A and B) and right bronchial artery–right pulmonary artery shunt. Fungal hyphae and spores were observed by gram staining of BALF smear. Two consecutive BALF fungal cultures grew *A. mycotoxinivorans* (Figure 2A and B), the identity of which was confirmed by internal-transcribed-spacer (ITS) sequencing. The phagocytosis of *A. mycotoxinivorans* by leukocytes was observed under the microscope (Figure 3). Intravenous amphotericin B liposome (30mg; 0.5mg/kg, QD) was given for 2 weeks, embolization was performed, and itraconazole (voriconazole allergy) was taken orally for 9 months after operation. Hemoptysis and pulmonary lesions gradually improved after treatment. Fiber-optic bronchoscopy was performed once again. Acid-fast bacilli were found on BALF smears two times, and *Mycobacterium intracellulare* was detected by mNGS. Oral rifabutin (0.3g qd), ethambutol (15–25mg/kg-d), and clarithromycin (0.5, bid) were given for 6 months at the same time. The patient had clinical remission of pulmonary infection. After infection control, oral methylprednisolone (30mg qd) and hydroxychloroquine (0.2g bid Po) were given for 2 months for SLE. Re-examination of the lesion showed absorption, and no hemoptysis occurred in the patient after 6 months of follow-up.

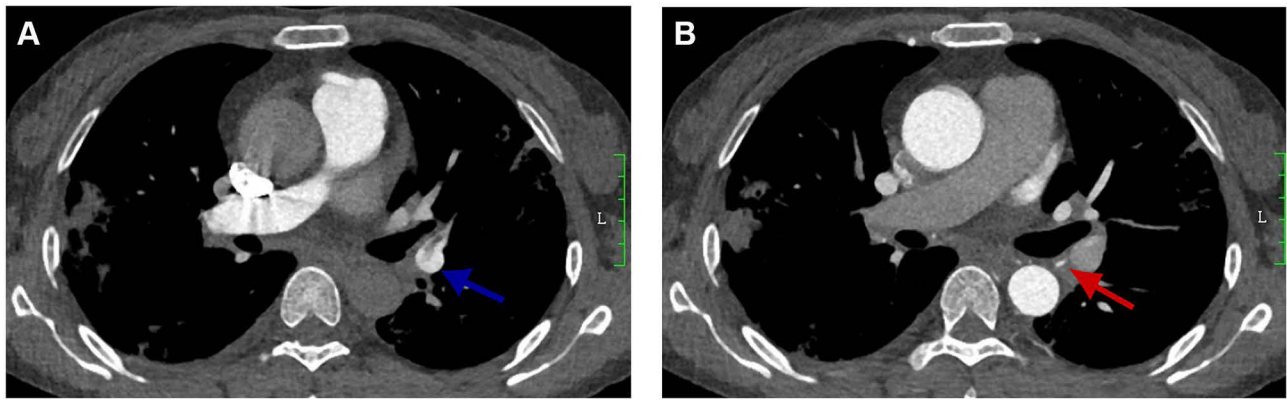


Figure 1 (A) The blue arrow shows the left bronchial artery–the left pulmonary artery fistula; filling defects can be seen in image. (B) The red arrow shows the thickened bronchial artery (over 2mm). (A and B) Irregular patchy and nodular density was observed in both lungs.

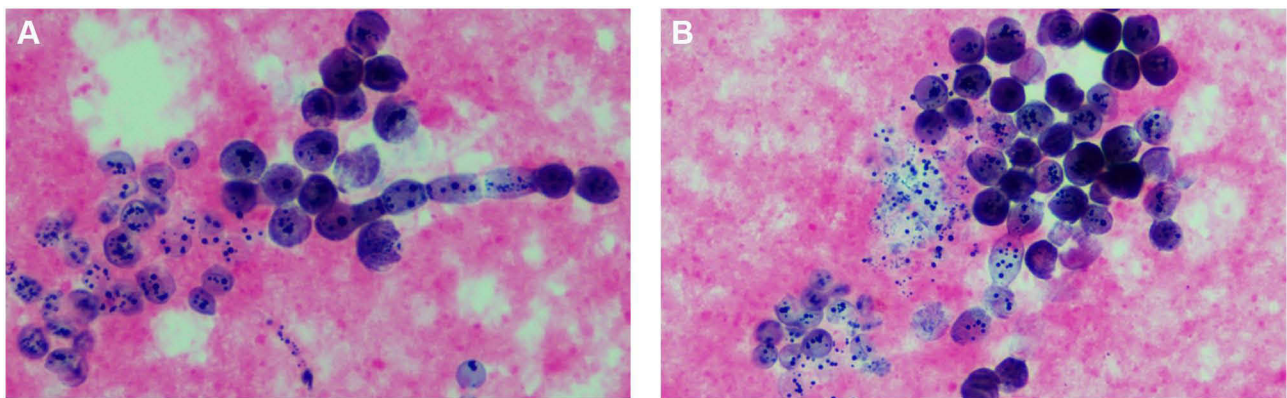


Figure 2 (A and B) Pleomorphic fungi were observed by gram staining of BALF smear.

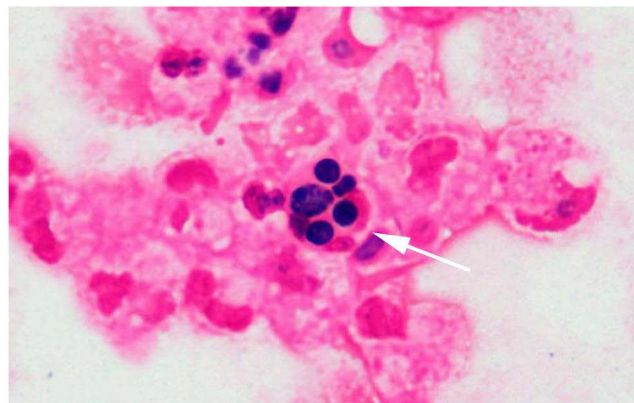


Figure 3 The white arrow shows that *A. mycotoxinivorans* were engulfed by leukocytes.

Discussion and Conclusions

A. mycotoxinivorans infection is rare, and pathogenicity is the most hotly discussed topic among the limited reports on *A. mycotoxinivorans*. We know that virulence factors are closely related to pathogenicity because they allow fungi to establish and develop in host tissue species. Studies¹¹ have confirmed that *Apiotrichum* has the highest temperature tolerance among yeast-like basidiomycetes and has lipase and biofilm production.⁵ These virulence factors also increase the possibility of long-term infection of *Apiotrichum* to some extent. In our case, leukocyte phagocytosis of the fungus

was observed in gram-stained BALF pathological specimen, which is generally considered an evidence of infection rather than colonization, thus indicating the potential pathogenicity of *A. mycotoxinivorans*.

A review of relevant literature found that invasive infection is related to immunosuppression or invasive operation, risk factors for infection or colonization in CF patients are unknown, and invasive infection in non-CF patients is related to mucosal destruction or systemic immune dysfunction caused by tumor or HIV.¹² The patient in our case had no neoplastic disease before onset and no history of use of immunosuppressant or hormone drugs. However, SLE was found in subsequent examination, which indirectly suggested the existence of potential immune disorder in our patient. The exact host and mechanism are still unclear. Mucosal damage may be a predisposing factor. So far, no relevant literature has reported the possible infection route of *A. mycotoxinivorans*. Our patient was a greening worker who had also grown vegetables for many years, which was suspected to be related to environmental inhalation. The exact pathophysiological mechanism of *A. mycotoxinivorans* is not clear.

Bronchial artery–pulmonary artery fistula is a rare congenital disorder that occurs mostly in children. Adult bronchial artery–pulmonary artery fistula could be associated with persistent lung inflammation, such as common actinomycete infection, tuberculosis, and bacterial pneumonia,¹³ leading to the reopening of potential traffic branches. In our case, *A. mycotoxinivorans* infection could have been an important factor in the formation of bronchial artery–pulmonary shunt in our patient. It provides a new diagnostic perspective and further evidence for the possibility of long-term infection of *A. mycotoxinivorans*. *Mycobacterium* was found after ITCZ treatment and surgical treatment. Therefore, *Mycobacterium* could have been a secondary infection. Due to its common symptoms of cough and hemoptysis, it can easily be misdiagnosed as tuberculosis or bronchiectasis. Up to now, the routine diagnosis of bronchial artery fistula still depends on further imaging interventions. In the case of shunt findings, catheter embolization should be performed.

In terms of treatment for *A. mycotoxinivorans*, Hickey et al³ believed that amphotericin B and lipid formulations as well as the echinocandins had limited efficacy against *Trichosporon* species and were even resistant to echinocandins. Triazole drugs are considered the first choice. Among the limited selection of antifungal triazole agents, voriconazole may be preferred for its intravenous and oral preparations and bioavailability. Do et al¹¹ reported a case of *A. mycotoxinivorans* infection and found that the MIC of FLC was the highest, followed by AMB, and ITCZ was the lowest. In our case, after itraconazole was administered, the pulmonary infection foci did not increase, and triazole was proved to be effective. However, due to the small sample size, whether it is worth promoting remains to be supported by more clinical and microbiological research data.

In conclusion, *A. mycotoxinivorans* infection is rare, and infection or colonization of *A. mycotoxinivorans* is controversial. The histopathophysiological changes caused by the disease are unknown. We report a rare case of *A. mycotoxinivorans* in a patient with bronchial artery–pulmonary artery fistula. Phagocytosis of fungi by leukocytes was observed. This is the first case in China and is also not reported worldwide before. Clinical reports on *A. mycotoxinivorans* are rare, and due to the difficulties in clinical isolation and identification of pathogens, it is particularly difficult to diagnose *A. mycotoxinivorans*, which is easy to be missed or misdiagnosed. We provide new data on the clinical manifestations of this emerging microbe under current knowledge, providing evidence for further clinical research to better understand *A. mycotoxinivorans* and bronchial artery–pulmonary fistula.

Ethics Approval and Informed Consent

Written informed consent to have the case details and any accompanying images published has been provided by the patient. No ethical committee approval was required for this study as the data were analyzed in a retrospective manner.

Acknowledgments

All authors thank the patient and her families for their support.

Author Contributions

All authors made substantial contributions to the conception and design, acquisition of data, or analysis and interpretation of data; participated in drafting the article or revising it substantially; agreed to submit to the current journal; gave final approval of the version to be published; and agreed to take responsibility for all aspects of the work.

Funding

There is no funding to report.

Disclosure

The authors report no conflicts of interest in this work.

References

1. Liu XZ, Wang QM, Goker M, et al. Towards an integrated phylogenetic classification of the Tremellomycetes. *Stud Mycol.* 2015;81:85–147.
2. Molnar O, Schatzmayr G, Fuchs E, Prillinger H. *Trichosporon mycotoxinivorans* sp. nov., a new yeast species useful in biological detoxification of various mycotoxins. *Syst Appl Microbiol.* 2004;27(6):661–671.
3. Hickey PW, Sutton DA, Fothergill AW, et al. *Trichosporon mycotoxinivorans*, a novel respiratory pathogen in patients with cystic fibrosis. *J Clin Microbiol.* 2009;47(10):3091–3097.
4. Hirschi S, Letscher-Bru V, Pottecher J, et al. Disseminated *Trichosporon mycotoxinivorans*, *Aspergillus fumigatus*, and *Scedosporium apiospermum* coinfection after lung and liver transplantation in a cystic fibrosis patient. *J Clin Microbiol.* 2012;50(12):4168–4170.
5. Almeida JN, Francisco EC, Barberino M, et al. Emergence of *Trichosporon mycotoxinivorans* (*Apiotrichum mycotoxinivorans*) invasive infections in Latin America. *Mem Inst Oswaldo Cruz.* 2017;112(10):719–722.
6. Peng L, Jiang YQ, Jiang GM, et al. Molecular identification and biological characteristic analysis of an *Apiotrichum mycotoxinivorans* (formerly *Trichosporon mycotoxinivorans*) strain isolated from sputum specimens of a pediatric patient with pneumonia. *J Mycol Med.* 2019;29(2):120–126.
7. Sadamatsu H, Takahashi K, Tashiro H, et al. A rare case of *Trichosporon mycotoxinivorans* and *Cryptococcus neoformans* co-infection in lung. *J Infect Chemother.* 2020;26(8):838–842.
8. Shah AV, McColley SA, Weil D, Zheng X. *Trichosporon mycotoxinivorans* infection in patients with cystic fibrosis. *J Clin Microbiol.* 2014;52(6):2242–2244.
9. Goldenberger D, Hinic V, Prince SS, et al. A case report of a cystic fibrosis patient with repeated isolation of *Trichosporon mycotoxinivorans* identified by a novel short-extraction method. *BMC Infect Dis.* 2016;16(1):601.
10. Martinez Muniz Fde B, Martinez Redondo M, Prados Sanchez C, Garcia Rodriguez J. Chronic lung infection caused by *Trichosporon mycotoxinivorans* and tricosporin mucoides in an immunocompetent cystic fibrosis patient. *Arch Bronconeumol.* 2016;52(7):400.
11. Do Espirito Santo EPT, Monteiro RC, da Costa ARF, Marques-da-Silva SH. Molecular identification, genotyping, phenotyping, and antifungal susceptibilities of medically important *Trichosporon*, *Apiotrichum*, and *Cutaneotrichosporon* species. *Mycopathologia.* 2020;185(2):307–317.
12. Kröner C, Kappler M, Grimmelt A-C, Laniado G, Würstl B, Griese M. The basidiomycetous yeast *Trichosporon* may cause severe lung exacerbation in cystic fibrosis patients – clinical analysis of *Trichosporon* positive patients in a Munich cohort. *BMC Pulm Med.* 2013;13(1):1–10.
13. Yon JR, Ravenel JG. Congenital bronchial artery-pulmonary artery fistula in an adult. *J Comput Assist Tomogr.* 2010;34(3):418–420.

Infection and Drug Resistance

Dovepress

Publish your work in this journal

Infection and Drug Resistance is an international, peer-reviewed open-access journal that focuses on the optimal treatment of infection (bacterial, fungal and viral) and the development and institution of preventive strategies to minimize the development and spread of resistance. The journal is specifically concerned with the epidemiology of antibiotic resistance and the mechanisms of resistance development and diffusion in both hospitals and the community. The manuscript management system is completely online and includes a very quick and fair peer-review system, which is all easy to use. Visit <http://www.dovepress.com/testimonials.php> to read real quotes from published authors.

Submit your manuscript here: <https://www.dovepress.com/infection-and-drug-resistance-journal>