



## NOTE

Avian Pathology

# Change of pathotype and phylogenetic analysis of infectious bronchitis virus detected in Kagoshima prefecture, Japan

Jiro IWAMOTO<sup>1)\*</sup>, Daisuke OKADA<sup>1)</sup>, Syouei KITAHARA<sup>1)</sup> and Kenichi CHITOSE<sup>1)</sup><sup>1)</sup>Kagoshima Prefectural Kagoshima Central Livestock Hygiene Service Center, 1678 Yuda, Higashiichiki-cho, Hioki, Kagoshima 899-2201, Japan

*J. Vet. Med. Sci.*  
82(4): 431–436, 2020  
doi: 10.1292/jvms.19-0491

Received: 3 September 2019  
Accepted: 24 January 2020  
Advanced Epub:  
10 February 2020

**ABSTRACT.** Infectious bronchitis (IB) is a highly contagious disease in chickens, induced by IB virus (IBV) infection. The pathotype and S1 genotype of IBV field strain that was detected from 2008 to 2018 were investigated in Kagoshima prefecture, Japan. The frequency of cases that the renal lesion characteristic of IBV infection was histopathologically confirmed was significantly higher from 2014 to 2018 than from 2008 to 2009, suggesting the altered pathotype of IBV. Of 7 genotypes (JP-I, JP-II, JP-III, JP-IV, Mass, Gray, and 4/91) that have been detected in Japan, 6 genotypes except for JP-II were detected since 2008 and it appeared that the JP-III and JP-I have been predominant. The JP-IV with different antigenicity from other genotypes was detected since 2009.

**KEY WORDS:** genotype, infectious bronchitis, infectious bronchitis virus, pathogenicity, pathotype

Infectious bronchitis (IB) is a highly infectious and contagious disease in chickens and induces numerous economic losses in the poultry farms. The IB virus (IBV), which is a causative agent of IB, primarily infects the respiratory tract and some variants or several field isolates affect the kidney and reproductive system, and subsequently induces various disorders to the host. The pathogenicity of IBV is very complex and constantly alters in the field strain, making it difficult to take control and protection measures for IB.

IBV is a *gammacoronavirus* belonging to the family *Coronaviridae* and has a 27.6 kb, positive-sense, and single-stranded RNA genome. The IBV genome encodes the non-structural protein, accessory protein, and four structural proteins. Of the structural proteins, the spike (S) glycoprotein is processed into two subunits, S1 and S2, by post-translational cleavage. The S1 glycoprotein is serologically essential as the target of the neutralization antibody against IBV [5, 12]. Hence, it has been focused on the sequence of the S1 gene to analyze the molecular characterization of IBV. In Japan, Mase *et al.* initially identified the five genotypes (JP-I, JP-II, JP-III, Mass and Gray) based on the S1 sequence of IBV isolated since 1950 [17]. Subsequently, the existence of another genotype (4/91 and JP-IV) was reported [18, 19]. The 7 genotypes have been identified in Japan so far.

Generally, the vaccination is the first choice for the prevention and control of IB in poultry farms. More than twenty vaccines for IB were commercialized in Japan now. The affected farms should select a vaccine using a strain with homologous serotype to prevalent field strain. However, the serotyping of prevalent strain by the virus neutralization test is very laborious and time-consuming. Because of easier and faster identification, the S1 genotyping of IBV became to be utilized as a tool for vaccine selection, as the relationship between serotype and S1 genotype of IBV became clear [1, 13, 22].

Kagoshima prefecture is one of the largest poultry farming regions in Japan. Recently, the change of pathological and molecular characterization in IBV field strain was suspected in Kagoshima prefecture because of the increased case that was diagnosed as IB since 2014, although there were few reports of IB between 2008 and 2013. In the present study, the change of pathotype and S1 genotype of IBV field strain was investigated in Kagoshima prefecture.

Of the cases that the diagnostic test was requested to Kagoshima Prefectural Kagoshima Central Livestock Hygiene Service Center from January 2008 to January 2018, 17 cases that the gene of IBV field strain was detected were subjected to the present study (Table 1). Because the gene of IBV field strain was not detected from 2010 to 2013, the 17 cases were divided into two groups, 6 cases from 2008 to 2009 (2008–2009) and 11 cases from 2014 to 2018 (2014–2018).

To investigate the change of pathotype of IBV, the records of histopathological findings were reconsidered in the 17 cases. The histopathological lesions in affected chickens during IBV infection include the respiratory lesions such as loss of cilia, edema, rounding and sloughing of epithelial cells, and infiltration by lymphocyte in the trachea and renal lesions such as interstitial

\*Correspondence to: Iwamoto, J.: jirou-iwamoto@pref.kagoshima.lg.jp

©2020 The Japanese Society of Veterinary Science



This is an open-access article distributed under the terms of the Creative Commons Attribution Non-Commercial No Derivatives (by-nc-nd) License. (CC-BY-NC-ND 4.0: <https://creativecommons.org/licenses/by-nc-nd/4.0/>)

**Table 1.** The overview of the cases and samples subjected to the present study

Group	Case No.	Sample name	Farm <sup>a)</sup>	Month of occurrence	Days of age	Breed	Vaccination	Detected genotype	Histopathological findings <sup>c)</sup>		Diagnosis <sup>d)</sup>
									Respiratory lesion	Renal lesion	
2008–2009	1	JP/Kagoshima-1/2008	A	March	36	Broiler	Vaccinated	JP-I	+	-	<i>Colibacillosis</i> Swollen head syndrome (suspected)
	2	JP/Kagoshima-2/2009	B	January	39	Broiler	Unvaccinated	JP-IV	-	-	<i>Colibacillosis</i> (suspected)
	3	JP/Kagoshima-3/2009	C	February	32, 36	Broiler	Unknown	4/91	-	-	<i>Colibacillosis</i> (suspected)
	4	JP/Kagoshima-4/2009	A	March	51	Broiler	Unknown	JP-III	+	-	<i>Colibacillosis</i>
	5	JP/Kagoshima-5/2009	D	April	25	Broiler	Vaccinated	JP-III	+	+	<b>IB (suspected)</b> Coccidiosis, <i>Colibacillosis</i>
	6	JP/Kagoshima-6/2009	E	April	30	Broiler	Vaccinated	JP-III	-	-	Inclusion body hepatitis Coccidiosis, <i>Colibacillosis</i>
2014–2018	7	JP/Kagoshima-7/2014	F	April	11	Broiler	Unvaccinated	JP-I	-	-	Inclusion body hepatitis
	8 <sup>b)</sup>	JP/Kagoshima-8/2014 JP/Kagoshima-9/2014	G	June	46	Broiler	Unknown	Mass (kidney) JP-IV (trachea)	+	+	<b>IB</b> Coccidiosis
	9	JP/Kagoshima-10/2014	G	June	52	Broiler	Unknown	Gray	+	+	<b>IB</b> Ascariidiosis, <i>Colibacillosis</i> Aspergillosis
	10	JP/Kagoshima-11/2014	H	September	40, 41	Broiler	Unvaccinated	JP-III	+	+	<i>Colibacillosis</i>
	11	JP/Kagoshima-12/2014	G	December	56	Broiler	Unknown	JP-IV	+	+	<b>IB</b> <i>Colibacillosis</i>
	12	JP/Kagoshima-13/2015	I	July	23, 29	Broiler	Vaccinated	JP-III	+	+	<b>IB (suspected)</b>
	13	JP/Kagoshima-14/2016	G	February	115	Broiler	Vaccinated	JP-I	+	-	<b>IB</b> <i>Colibacillosis</i>
	14	JP/Kagoshima-15/2016	G	April	26	Broiler	Unknown	JP-I	-	+	<b>IB</b> Coccidiosis
	15	JP/Kagoshima-16/2017	J	February	37	Broiler	Vaccinated	JP-III	+	+	<b>IB</b>
	16	JP/Kagoshima-17/2017	K	October	13	Broiler	Unvaccinated	Mass	+	-	<b>IB</b>
	17	JP/Kagoshima-18/2018	F	January	41	Broiler	Vaccinated	JP-I	+	+	<b>IB</b>

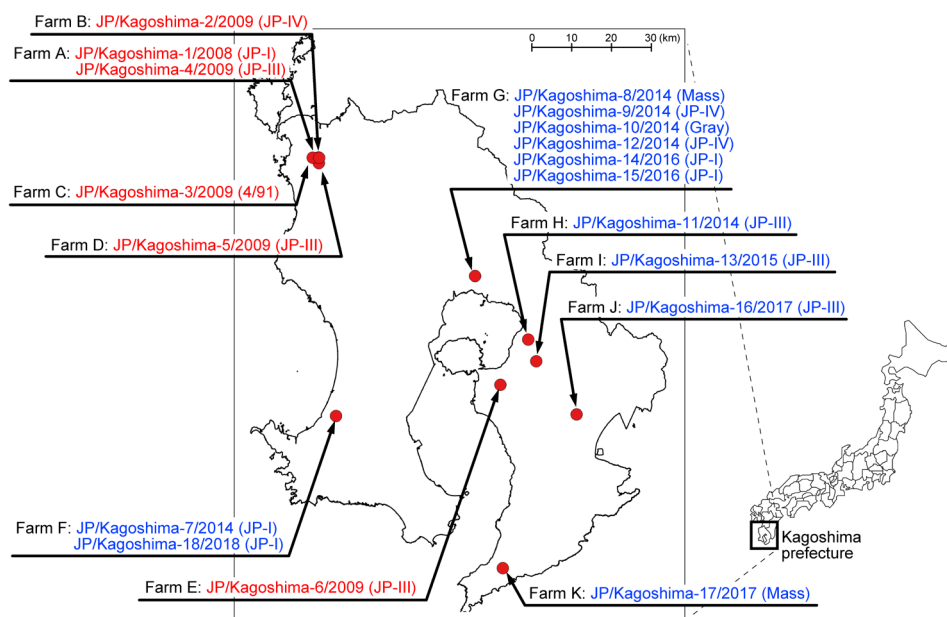
a) The identical alphabets indicate identical farms. b) In Case 8, the two genotypes of infectious bronchitis virus were detected from the trachea and kidney respectively, which is a pooled sample of three chickens. c) +: The case that the lesions were histopathologically observed, -: not observed. d) The “suspected” indicates the case that it was difficult to make a definitive diagnosis because the histopathological lesions were not observed or were very mild, despite the pathogen detection such as isolation or specific gene detection of the virus. IB: Infectious bronchitis.

nephritis, tubular degeneration, and infiltration by heterophils in the kidney [3]. The frequency of cases that the respiratory and renal lesions as described above were histopathologically observed in the trachea and kidney was compared between 2008–2009 and 2014–2018 by Fisher’s exact test.

Eighteen of RNA samples (6 samples from 2008–2009 and 12 samples from 2014–2018) utilized for diagnosis in the 17 cases were subjected to the phylogenetic analysis (Table 1 and Fig. 1). The reverse transcription-polymerase chain reaction was performed by One-Step RT-PCR kit (Qiagen, Hilden, Germany) with the primer set which amplifies the S1 gene of IBV [17]. After 1.5% agarose gel electrophoresis, the amplification products were purified by QIAquick Gel Extraction Kit (Qiagen, Hilden, Germany). The commercialized outsourcing sequence service (Fasmac DNA sequence service, [http://fasmac.co.jp/gene\\_loupe](http://fasmac.co.jp/gene_loupe)) was utilized for the sequence of amplification products. Based on the sequences of amplification products and several S1 gene sequences of IBV retrieved from GenBank (<https://www.ncbi.nlm.nih.gov/genbank>), the phylogenetic tree was constructed by the neighbor-joining method (500 bootstrap replicates) using MEGA 6 Software (<https://www.megasoftware.net>). The S1 genotypes of each sample were defined according to the classification that Mase *et al.* identified [17–19]. The detection rate of each genotype was calculated though the investigation period and in two groups (2008–2009 and 2014–2018), respectively. The detection rate between the two groups was compared by Fisher’s exact test.

All statistical analyses were performed using free statistical software R (version 3.5.2), distributed by The R Project (<https://www.r-project.org>). The significant level was  $P < 0.05$  in all tests.

There was no significant difference in the frequency of histopathological observation of respiratory lesion between two groups,



**Fig. 1.** The location of farms that the samples were collected for the present study, the sample name for phylogenetic analysis, and the genotype detected.

whereas the observation frequency of renal lesion was significantly higher in 2014–2018 (72.7%) than in 2008–2009 (16.7%) (Table 2).

All of the genotypes except for JP-II were confirmed from 2008 to 2018 in Kagoshima Prefecture (Figs. 1 and 2). The detection rate of JP-III was the highest (33.3%), and subsequently JP-I (27.8%), JP-IV (16.7%), Mass (11.1%), Gray and 4/91 (5.6%) (Table 3).

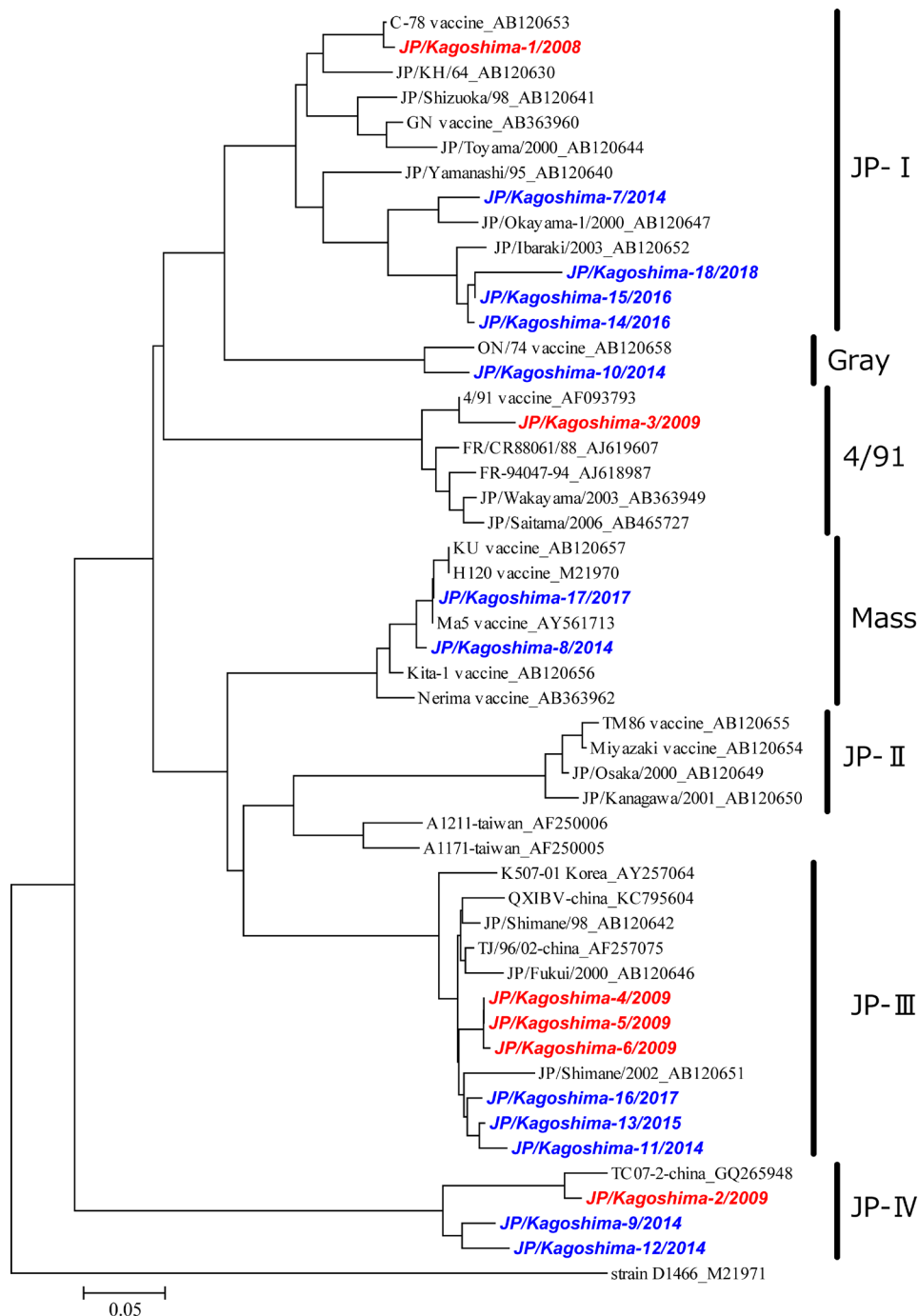
The detection rate of JP-1, JP-IV and 4/91 was 33.3%, 16.7% and 0% in 2014–2018 whereas they were all 16.7% in 2008–2009. Mass and Gray were not detected in 2008–2009 although the detection rate of them was 16.7% and 8.3% in 2014–2018, respectively. The detection rate of JP-III was 50% in 2008–2009 and was 25% in 2014–2018. There was no significant difference in the detection rate of each genotype between the two groups (Table 3).

In Japan, the most of reports regarding IB were with nephritis until around 1990 [7, 9, 10, 16, 24] since the first report of IB nephritis in 1971 [11], although there were a few reports of IB which developed the respiratory sign alone in affected chickens [23]. Also, the major clinical sign caused by IBV isolates submitted from the various regions in Japan for phylogenetic analysis was mostly nephritis since 1989, whereas that was respiratory from 1951 to 1980 [17]. Hence, it appeared that the pathotype of IBV field strain chronologically changed from respiratory to nephropathogenic in Japan. In Kagoshima prefecture, there was no report regarding the pathotype of IBV field strain except for the report in 1981 [20] and the predominant pathotype of IBV has not been known for a long period. The result of the present study showed that the detection of IBV field strain with nephropathogenicity has significantly increased in Kagoshima prefecture since 2014, suggesting that the nephropathogenic strain of IBV became predominant in Kagoshima prefecture. Conversely, the change of pathogenicity from highly nephropathogenic to respiratory has been reported in the field strain in Australia [8], and thus it appeared that IBV field strains have constantly altered the pathogenic features.

Cavanagh *et al.* [6] described that the relationship between the pathogenicity of IBV and S protein is “open question”, although it has been known that the S protein of IBV is the determinant factor of cell tropism [4]. In this study, there was no significant difference in the detection rate of the S1 genotype between the two groups, despite the change of pathotype in field strain, and the relationship between the pathogenicity of IBV and S1 gene remained unclear. Recently, some studies suggested that non-structural protein of IBV such as replicase or accessory proteins involved the pathogenicity of IBV [2, 14]. Although the S gene might not be significant to determine the pathogenicity of IBV, further studies will be needed to elucidate the relationship.

It is assumed that the elicitation of the histopathological lesion by IBV infection and the determination of IBV pathotype would be affected by the various factors (genetic factors, host factors such as breeds, days of age, and vaccination history, and environmental factors such as season, hygiene management of the farm, and the pathogens other than IBV) in the IB field case. However, there were no significant relationships between the observation of histopathological lesion and days of age, vaccination, and month of occurrence in the 17 cases of the present study (data not shown). Also, the histopathological lesions characteristic of IBV infection were not observed in 4 cases (Case 2, 3, 6, and 7) despite the complication with other diseases, as shown in Table 1. It would be hard to identify and explain the determination factors of IBV pathotype only by the data in the present study.

The detection rate of each genotype, shown in Table 3, might not necessarily reflect the prevalent status of IBV genotype in Kagoshima prefecture since 2008 because of the small sample size and bias regarding the region and farm of samples subjected to



**Fig. 2.** Phylogenetic tree based on the sequence of the S1 gene of infectious bronchitis virus. The samples subjected to the present study are expressed in bold italics of red (2008–2009) and blue (2014–2018). The sequences retrieved from GenBank are showed in black and the Accession number in GenBank is revealed after the sequence name.

the present study. However, the JP-III and JP-I have been constantly detected for a long period at the wide area in the prefecture, as shown in Fig. 1. Therefore, it appeared that the two genotypes have been predominant in Kagoshima prefecture since 2008. The JP-I is indigenous to Japan [17], and it was speculated that the JP-I has originally evolved for a long time also in Kagoshima prefecture. On the other hand, the origin of JP-III is unclear. The phylogenetic analysis of present and previous studies suggests that the JP-III is closely related to the isolate in China [1, 17]. It has been believed that the IBV has a wide host range and infects not only poultry but also wild birds such as a duck [6, 15]. Mase *et al.* inferred the possibility of involvement of wild birds regarding the dissemination of IBV into Japan [17]. In Kagoshima prefecture, there is a large plain (called “Izumi plain”) as an overwintering site for wild migrant birds including a duck that infects with a virus such as avian influenza virus and that migrates

**Table 2.** The frequency of cases that the respiratory and renal lesion characteristic of infectious bronchitis virus infection was histopathologically observed

Histopathological lesion	Frequency of cases that the lesion was observed		P value
	2008–2009	2014–2018	
Respiratory lesion	3/6 (50.0%)	9/11 (81.8%)	0.280
Renal lesion	1/6 (16.7%)	8/11 (72.7%)	0.0498

**Table 3.** The detection rate of each genotype through the investigation period and in two groups

Genotype	Detection rate of each genotype			P value
	Total <sup>a)</sup>	2008–2009	2014–2018	
JP-I	27.8% (5/18)	16.7% (1/6)	33.3% (4/12)	0.615
JP-II	ND <sup>b)</sup>	ND	ND	NC <sup>c)</sup>
JP-III	33.3% (6/18)	50.0% (3/6)	25.0% (3/12)	0.344
JP-IV	16.7% (3/18)	16.7% (1/6)	16.7% (2/12)	1
Mass	11.1% (2/18)	0.0% (0/6)	16.7% (2/12)	0.529
Gray	5.6% (1/18)	0.0% (0/6)	8.3% (1/12)	1
4/91	5.6% (1/18)	16.7% (1/6)	0.0% (0/12)	0.333

a) Total detection rate from 2008 to 2018. b) ND: Not detected. c) NC: Not calculated.

among neighboring countries including China [21]. The predominance of JP-III in Kagoshima prefecture might not be irrelevant to the existence of a “portal site”, such as Izumi plain, for viruses derived from neighboring countries.

It is essential for the prevention and control of IB to estimate the S1 genotype of IBV field strain because the S1 genotype of field strain is associated with the vaccine selection in a chicken farm. All of the S1 genotypes, except for JP-II, were detected in Kagoshima prefecture since 2008. It implied the diversity of IBV field strain in Kagoshima prefecture. A flexible vaccination strategy would be needed for the prevention and control of IB.

The JP-IV was detected in 3 of 18 samples subjected to the phylogenetic analysis in the present study. The 3 samples were collected from 3 different cases (Case 2, 8 and 11 in Table 1) and the earliest detection case was in January 2009 in a broiler farm (Case 2 in Table 1). On the other hand, the JP-IV was initially reported as a novel genotype of IBV in Japan, which was identified from the samples collected in September 2009 in a layer farm located at Ibaraki prefecture [19], more than 1,000 km far away from Kagoshima prefecture. Although the JP-IV was found in the farms located at Ibaraki and Kagoshima prefecture almost during the corresponding period, there was no geographic and epidemiological relationship between the two farms. Hence, it appeared that JP-IV has widely disseminated into Japan since at least 2009. In addition, the virulence of JP-IV was believed to be low in the previous study [19]. However, the both of respiratory and renal lesions were histopathologically confirmed in 2 of 3 cases (Case 8 and 11, Table 1) that the JP-IV was detected, and the JP-IV alone was detected in Case 11 (Table 1). The 2 cases suggest the altered pathogenicity of JP-IV strain in Japan although the virulence to affected chickens in the cases might not necessarily be due to the IBV alone because of the complications such as Coccidiosis and Colibacillosis. Moreover, the antigenicity of JP-IV differs from others detected in Japan [19]. Therefore, the JP-IV strain could be a great threat to all of the chicken farms in Japan. Further studies regarding the pathogenicity and the prevalent status of JP-IV strain in Japan would be needed for the prevention of IB caused by JP-IV strain.

## REFERENCES

1. Ariyoshi, R., Kawai, T., Honda, T. and Tokiyoshi, S. 2010. Classification of IBV S1 genotypes by direct reverse transcriptase-polymerase chain reaction (RT-PCR) and relationship between serotypes and genotypes of strains isolated between 1998 and 2008 in Japan. *J. Vet. Med. Sci.* **72**: 687–692. [Medline] [CrossRef]
2. Armesto, M., Cavanagh, D. and Britton, P. 2009. The replicase gene of avian coronavirus infectious bronchitis virus is a determinant of pathogenicity. *PLoS One* **4**: e7384. [Medline] [CrossRef]
3. Bande, F., Arshad, S. S., Omar, A. R., Bejo, M. H., Abubakar, M. S. and Abba, Y. 2016. Pathogenesis and diagnostic approaches of avian infectious bronchitis. *Adv. Virol.* **2016**: 4621659. [Medline] [CrossRef]
4. Casais, R., Dove, B., Cavanagh, D. and Britton, P. 2003. Recombinant avian infectious bronchitis virus expressing a heterologous spike gene



- demonstrates that the spike protein is a determinant of cell tropism. *J. Virol.* **77**: 9084–9089. [[Medline](#)] [[CrossRef](#)]
5. Cavanagh, D., Davis, P. J. and Mockett, A. P. 1988. Amino acids within hypervariable region 1 of avian coronavirus IBV (Massachusetts serotype) spike glycoprotein are associated with neutralization epitopes. *Virus Res.* **11**: 141–150. [[Medline](#)] [[CrossRef](#)]
  6. Cavanagh, D. 2007. Coronavirus avian infectious bronchitis virus. *Vet. Res.* **38**: 281–297. [[Medline](#)] [[CrossRef](#)]
  7. Goryo, M., Umemura, T. and Itakura, C. 1984. Concurrence of nephrosis-nephritis due to infectious bronchitis virus and infectious bursal disease in broiler chickens. *Avian Pathol.* **13**: 191–200. [[Medline](#)] [[CrossRef](#)]
  8. Ignjatovic, J., Ashton, D. F., Reece, R., Scott, P. and Hooper, P. 2002. Pathogenicity of Australian strains of avian infectious bronchitis virus. *J. Comp. Pathol.* **126**: 115–123. [[Medline](#)] [[CrossRef](#)]
  9. Iritani, Y. and Takigami, S. 1995. Comparative characteristics among infectious bronchitis viruses isolated from broiler chickens with nephritis. *Nippon Juishikai Zasshi* **48**: 75–78.
  10. Ishibashi, K., Shirakawa, H., Tomishita, Y., Matuo, H., Watanabe, A. and Yagyu, K. 1993. Diagnosis of avian infectious bronchitis by indirect fluorescent antibody technique using monoclonal antibody. *Nippon Juishikai Zasshi* **46**: 117–119.
  11. Itakura, C. and Kawai, Y. 1972. Pathology of spontaneous cases of avian transmissible tubulonephrosis. *Nippon Juigaku Zasshi* **34**: 61–69. [[Medline](#)] [[CrossRef](#)]
  12. Kant, A., Koch, G., van Roozelaar, D. J., Kusters, J. G., Poelwijk, F. A. and van der Zeijst, B. A. 1992. Location of antigenic sites defined by neutralizing monoclonal antibodies on the S1 avian infectious bronchitis virus glycopolyptide. *J. Gen. Virol.* **73**: 591–596. [[Medline](#)] [[CrossRef](#)]
  13. Ladman, B. S., Loupos, A. B. and Gelb, J. Jr. 2006. Infectious bronchitis virus S1 gene sequence comparison is a better predictor of challenge of immunity in chickens than serotyping by virus neutralization. *Avian Pathol.* **35**: 127–133. [[Medline](#)] [[CrossRef](#)]
  14. Lin, S. Y., Li, Y. T., Chen, Y. T., Chen, T. C., Hu, C. J. and Chen, H. W. 2016. Identification of an infectious bronchitis coronavirus strain exhibiting a classical genotype but altered antigenicity, pathogenicity, and innate immunity profile. *Sci. Rep.* **6**: 37725. [[Medline](#)] [[CrossRef](#)]
  15. Liu, S., Chen, J., Chen, J., Kong, X., Shao, Y., Han, Z., Feng, L., Cai, X., Gu, S. and Liu, M. 2005. Isolation of avian infectious bronchitis coronavirus from domestic peafowl (*Pavo cristatus*) and teal (*Anas*). *J. Gen. Virol.* **86**: 719–725. [[Medline](#)] [[CrossRef](#)]
  16. Lin, Z., Kato, A., Kudou, Y., Umeda, K. and Ueda, S. 1991. Typing of recent infectious bronchitis virus isolates causing nephritis in chicken. *Arch. Virol.* **120**: 145–149. [[Medline](#)] [[CrossRef](#)]
  17. Mase, M., Tsukamoto, K., Imai, K. and Yamaguchi, S. 2004. Phylogenetic analysis of avian infectious bronchitis virus strains isolated in Japan. *Arch. Virol.* **149**: 2069–2078. [[Medline](#)]
  18. Mase, M., Inoue, T., Yamaguchi, S. and Imada, T. 2008. Existence of avian infectious bronchitis virus with a European-prevalent 4/91 genotype in Japan. *J. Vet. Med. Sci.* **70**: 1341–1344. [[Medline](#)] [[CrossRef](#)]
  19. Mase, M., Kawanishi, N., Ootani, Y., Murayama, K., Karino, A., Inoue, T. and Kawakami, J. 2010. A novel genotype of avian infectious bronchitis virus isolated in Japan in 2009. *J. Vet. Med. Sci.* **72**: 1265–1268. [[Medline](#)] [[CrossRef](#)]
  20. Otsuki, K., Nakamura, T., Kubota, N., Kawaoka, Y. and Tsubokura, M. 1987. Comparison of two strains of avian infectious bronchitis virus for their interferon induction, viral growth and development of virus-neutralizing antibody in experimentally-infected chickens. *Vet. Microbiol.* **15**: 31–40. [[Medline](#)] [[CrossRef](#)]
  21. Ozawa, M., Matsuu, A., Tokorozaki, K., Horie, M., Masatani, T., Nakagawa, H., Okuya, K., Kawabata, T. and Toda, S. 2015. Genetic diversity of highly pathogenic H5N8 avian influenza viruses at a single overwintering site of migratory birds in Japan, 2014/15. *Euro Surveill.* **20**: 21132. [[Medline](#)] [[CrossRef](#)]
  22. Shimazaki, Y., Harada, M., Horiuchi, T., Yoshida, K., Tanimura, C., Nakamura, S., Mase, M. and Suzuki, S. 2009. Serological studies of infectious bronchitis vaccines against Japanese field isolates of homologous and heterologous genotypes. *J. Vet. Med. Sci.* **71**: 891–896. [[Medline](#)] [[CrossRef](#)]
  23. Yamashita, H. and Lin, Z. 1998. Typing of avian infectious bronchitis virus isolates in Hiroshima prefecture by RT-PCR and restriction enzyme analysis. *Nippon Juishikai Zasshi* **51**: 718–721.
  24. Yamanaka, M., Amimoto, K., Hiramatsu, K., Nakai, M. and Sasaki, N. 1988. Some characteristics of infectious bronchitis virus strains isolated from chickens with nephritis. *Nippon Juishikai Zasshi* **41**: 416–420.