

# ECG Changes Due to Hypothermia Developed After Drowning: Case Report

Suda Boğulma Sonrası Gelişen Hipotermiye Bağlı EKG Değişiklikleri: Olgu Sunumu

Sabiye YILMAZ,<sup>1</sup> Mehmet Akif ÇAKAR,<sup>2</sup> Mehmet Bulent VATAN,<sup>2</sup> Harun KILIC,<sup>2</sup> Nurgul KESER<sup>2</sup>

<sup>1</sup>Department of Cardiology, Yenikent State Hospital, Sakarya;

<sup>2</sup>Department of Cardiology, Sakarya University Faculty of Medicine, Sakarya

## SUMMARY

Drowning is one of the fatal accidents frequently encountered during the summer and is the most common cause of accidental death in the world. Anoxia, hypothermia, and metabolic acidosis are mainly responsible for morbidity. Cardiovascular effects may occur secondary to hypoxia and hypothermia. Atrial fibrillation, sinus dysrhythmias (rarely requiring treatment), and, in serious cases, ventricular fibrillation or asystole may develop, showing as rhythm problems on electrocardiogram and Osborn wave can be seen, especially during hypothermia. A 16-year-old male patient who was admitted to our hospital's emergency service with drowning is presented in this article. In our case, ventricular fibrillation and giant J wave (Osborn wave) associated with hypothermia developed after drowning was seen. We present this case as a reminder of ECG changes due to hypothermia that develop after drowning. Response to cardiopulmonary resuscitation after drowning and hypothermia is not very good. Mortality is very high, so early resuscitation and aggressive treatment of cardiovascular and respiratory problems are important for life.

**Key words:** Arrest; drowning; hypothermia; osborn wave; trauma.

## ÖZET

Suda boğulmalar özellikle yaz aylarında sıkça karşılaştığımız ölümcül kazalardandır, dünyada kaza ile ölümlerin en sık sebeplerinden biridir. Boğulmalardaki morbiditeden esas olarak anoksi, hipotermi ve sonucunda gelişen metabolik asidoz sorumludur. Kardiyovasküler etkiler hipoksi ve hipotermiye sekonderdir. Elektrokardiyografide (EKG) atriyal fibrilasyon, sinüs disritmileri (nadiren tedavi gerektirir), ciddi olgularda ventriküler fibrilasyon ya da asistol gibi ritim problemleri ve özellikle hipotermi sırasında sık karşılaşılan Osborn dalgaları izlenebilir. Bu yazıda soğuk suda boğulma sonrasında hastane acil servisine getirilen 16 yaşında erkek hasta sunuldu. Olguda boğulma sonrası gelişen hipotermi ile ilişkili ventriküler fibrilasyon ve dev J dalgaları (Osborn dalgası) izlendi. Bu olguyu sunmamızın nedeni suda boğulma sonrası gelişen hipotermiye bağlı EKG değişikliklerini hatırlatmaktır. Suda boğulma ve hipotermi sonrası kardiyopulmoner resüsitasyona cevap çok iyi değildir. Mortalite oldukça yüksektir, erken resüsitasyon, agresif kardiyovasküler ve respiratuvar tedavi sağkalım için önemlidir.

**Anahtar sözcükler:** Arrest; suda boğulma; hipotermi; osborn dalgası; travma.

## Introduction

Drowning is one of the most common causes of accidental death in the world. Among adults between 20 and 44 years of age, drowning is the second most common cause of accidental death. Drowning is especially common for young

children (younger than five years old) and young adults (between 15 and 29 years old).<sup>[1]</sup> Anoxia, hypothermia, and metabolic acidosis are mainly responsible for morbidity in drowning. Hypothermia due to cold water drowning, can be monitored via various electrocardiographic changes: T wave

**Submitted:** 11.02.2013 **Accepted:** 15.05.2013 **Published online:** 18.07.2013

**Correspondence:** Dr. Sabiye Yılmaz. Korucuk Baytur Sitesi, Orkide 1, Daire 6, Sakarya, Turkey.

**e-mail:** ssevincdr@gmail.com

© 2014 Emergency Medicine Association of Turkey. Production and Hosting by Elsevier B.V. Originally published in [2014] by Kare Publishing. This is an open access article under CC BY-NC-ND license (<http://creativecommons.org/licenses/by-nc-nd/4.0/>)

Turk J Emerg Med 2014;14(1):37-40 doi: 10.5505/1304.7361.2014.60590



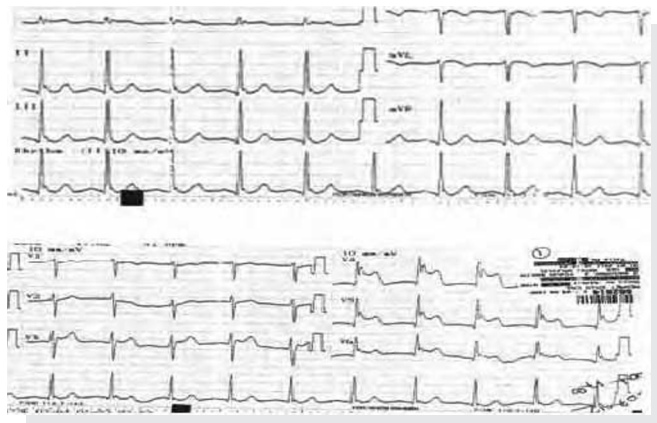
inversion; PR, QRS, and QT prolongation; Osborn waves; and dysrhythmias (sinus bradycardia, atrial fibrillation and flutter, nodal rhythm, AV block, ventricular premature beats, ventricular fibrillation, and asystole).<sup>[2]</sup> Osborn waves are dome-like deflections which are observed as late delta waves following the QRS complex or the small secondary R wave (R') in electrocardiography (ECG).<sup>[3]</sup> Osborn waves and ST elevation usually return to normal as body temperature increases and hypoxia and acidosis regress.

The current report presents the case of a patient who developed hypothermia after drowning and whose ECG results revealed Osborn waves and ST segment elevation.

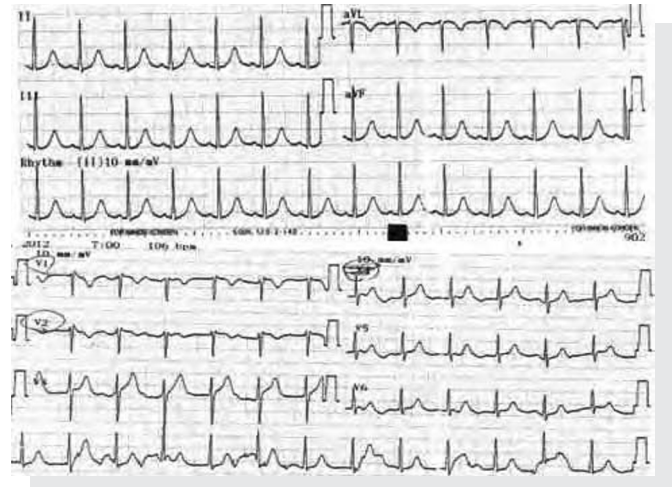
## Case Report

A 16-year-old male patient was admitted to our emergency department after drowning in cold water. Cardiopulmonary resuscitation was initiated and the patient intubated within approximately 25 minutes at the scene. The patient's relatives reported that he had no medical history and that he was in the water for approximately 10 minutes. The patient had ventricular fibrillation, and defibrillation was conducted during transport and in the emergency room. The patient was then taken to the intensive care unit and connected to a mechanical ventilator. Positive end-expiratory pressure (PEEP) was applied.

Physical examination of the unconscious patient revealed mydriasis and flexor motor response in the form of retraction in the upper extremities. Transtympanic body temperature was 28°C, heart rate was 82/min, blood pressure was 150/70 mmHg, and O<sub>2</sub> saturation was 87%. ECG revealed sinus rhythm, Osborn waves with concave ST segment elevation in V3-6, and a significant J wave in V4-6 in the precordial leads (Figure 1). The following laboratory results were detected: troponin level, 5.08 ng/ml (normal range <0.1 ng/



**Figure 1.** Osborn waves with concave ST segment elevation in V3-6, and a significant J wave in V4-6 in the precordial leads.



**Figure 2.** After 24 hours, blood temperature and ECG results returned to normal.

ml); hyponatremia, 150.8 mmol/L (136-145 mmol/L); hypokalaemia, 2.9 mmol/L (3.5-5.1 mmol/L); urea, 77 mg/dL (16.6-48.5mg/dL); creatinine, 2.5 mg/dL (0.5- 0.9 mg/dl); glucose, 279 mg/dl (<105 mg/dl); aspartate aminotransferase (AST), 189 mg/dL (0-32 U/L); alanine aminotransferase (ALT), 116 mg/dL (0-33 U/L); hemoglobin (HGB), 15.7 g/dL (12.2-18.1 g/dL); and hematocrit (HTC), 51.8% (37.7-53.7). Respiratory acidosis (pH: 7.296) in arterial blood gas and retention of carbon dioxide (PCO<sub>2</sub>: 52.3) were observed.

External and internal heating were immediately applied to the patient using heated intravenous infusion, moistening of the inspired gas, and heated blanket. When the patient's blood temperature exceeded 32°C, ST segment elevation began to decline and, after 24 hours, blood temperature and ECG results returned to normal (Figure 2). Treatment with positive inotropes (dopamine 5-10 mcg/kg/min) was started for the patient, who had no pulmonary edema. To control the convulsions which developed during follow-up in intensive care, valproic acid and prophylactic antibiotic treatment was started. On echocardiography, no regional wall motion abnormality was observed with the increase in cardiac enzyme levels. No pathology except anoxia-induced brain edema was identified on cranial CT. The patient experienced multiple organ failure during his follow-up in intensive care and died on the third day of hospitalization.

## Discussion

Drowning is defined as death caused by the inability to breathe after submersion in water. Drowning is one of the most common causes of accidental death in the world, and is the second most common cause of accidental death among adults between the ages of 20 and 44 years. Drowning is especially common among young children (younger

than five years old) and young adults (between 15 and 29 years).<sup>[1]</sup> Anoxia, hypothermia, and metabolic acidosis are mainly responsible for morbidity in drowning.<sup>[4]</sup>

The human body must maintain a temperature of 37°C in order to perform normal functions. In cases of severe hypothermia, in which body temperature is below 30°C, critical bodily functions are significantly suppressed.<sup>[5]</sup> Resuscitation should be continued until body temperature exceeds 30°C.<sup>[6]</sup> If body temperature is below 25°C, cardiac arrest due to ventricular fibrillation is frequently observed. If body temperature is below 18°C, asystole occurs.<sup>[7]</sup>

In drowning cases, cardiovascular effects are secondary to hypoxia and hypothermia. Heart rate and blood pressure first increase and then decrease. During hypothermia some ECG changes are observed, such as various dysrhythmias (including sinus bradycardia, atrial fibrillation and flutter, nodal rhythm, AV block, ventricular premature beats, ventricular fibrillation, and asystole) and T wave inversion; PR, QRS, and QT prolongation; and Osborn waves.<sup>[8]</sup> Hypothermia decreases cardiac conduction and extends all measured electrocardiographic intervals due to slowed repolarization. Hypothermia ultimately leads to the development of atrioventricular block. On the other hand, Osborn waves develop in hypothermic patients due to electrolyte or acid-base imbalance rather than lack of heat. Osborn waves may be detected in 80% of the patients whose body temperatures fall below 30°C. Osborn waves and ST elevation usually return to normal as body temperature increases, and hypoxia and acidosis decrease.<sup>[9]</sup>

The Osborn wave was defined for the first time in 1953 by Joseph Osborne<sup>[10]</sup> and is the positive deflection wave at the J point after the R wave. The amplitude of an Osborn wave is usually between 0.5 and 2 mm. Although observed frequently on 12-lead ECG, Osborn waves sometimes occur only in the anterolateral leads. Osborn waves are observed most frequently in hypothermia (hypothermic hump). Wave amplitude is related to the severity of hypothermia. Very small Osborn waves are observed in normothermic patients, especially in V5-6; after head trauma; after defibrillation; or in association with early repolarization; coronary heart disease and pericarditis; hypokalemia; hypercalcemia; hypoglycemia; diabetic ketoacidosis; or Brugada syndrome.<sup>[9,11-13]</sup> For example, in a previous report, Yalçın M. and his colleagues presented a case of sepsis-induced hypothermia and Osborn waves in association with hypokalemia.<sup>[14]</sup>

ECG is the most commonly used non-invasive method for diagnosing cardiac disease. ECG changes, non-ischemic myocardial destruction, and increases in cardiac enzyme levels encountered in the emergency department may have a range of etiologies, including hypothermia, electric shock,

trauma, myocarditis, chemotherapy, and subarachnoid hemorrhage. The patient's clinical condition, cardiovascular risk factors, specific ECG changes, and ECG course help to reveal the cause of myocardial destruction. Imaging methods, such as echocardiography, are also important in differential diagnosis of myocardial ischemia and other cardiac events.

In the present case, Osborn waves in V4-6 and severe ST elevation were observed. The ST elevation and Osborn waves improved as the hypothermia declined. No pattern of ST elevation supporting MI and no reciprocal ECG changes were observed in the patient, whose increased cardiac enzyme levels were also monitored. No regional wall motion abnormalities matching any coronary perfusion area or supporting MI were observed with echocardiography. The absence of the Q wave after the decline of ST elevation suggested against atherosclerotic coronary artery disease. Based on the findings of this case, ECG changes and cardiac enzyme rise are interpreted as secondary to defibrillation, hypoxia, and hypothermia. Although the patient's ECG changes returned to normal with recovery from hypothermia, he passed away on the third day of hospitalization as a result of multiple organ failure.

In conclusion, drowning is a significant cause of morbidity and mortality. It is more common during adolescence and for men. The prognosis is determined by the damage to the myocardium and the brain, which are targeted primarily by hypoxia. Osborn waves detected on ECG are not pathognomonic, although Osborn waves are characteristic of hypothermia. Thus, other potential causes of Osborn waves should be investigated to achieve successful resuscitation. The best treatment for a hypothermic patient is body temperature regulation. If body temperature does not increase, resuscitation may not be successful. Early diagnosis of possible arrhythmias and ECG changes is very valuable in determining necessary interventions.

### Conflict of Interest

The authors declare that there is no potential conflicts of interest.

### References

1. Hwang V, Shofer FS, Durbin DR, Baren JM. Prevalence of traumatic injuries in drowning and near drowning in children and adolescents. *Arch Pediatr Adolesc Med* 2003;157:50-3.
2. Bessen HA. Hypothermia. In: Tintinalli JE, Kelen GD, Stapczynski JS, editors. *Emergency medicine. A comprehensive study guide*. 6th ed. New York: McGraw-Hill; 2003. p.1231-5.
3. Gussak I, Bjerregaard P, Egan TM, Chaitman BR. ECG phenomenon called the J wave. History, pathophysiology, and clinical significance. *J Electrocardiol* 1995;28:49-58.
4. Ibsen LM, Koch T. Submersion and asphyxial injury. *Crit Care*

- Med 2002;30:402-8.
5. Holzer M, Behringer W, Schörkhuber W, Zeiner A, Sterz F, Lagner AN, et al. Mild hypothermia and outcome after CPR. Hypothermia for Cardiac Arrest (HACA) Study Group. *Acta Anaesthesiol Scand Suppl* 1997;111:55-8.
  6. Fiser DH. Near-drowning. *Pediatr Rev* 1993;14:148-51.
  7. Alhaddad IA, Khalil M, Brown EJ Jr. Osborn waves of hypothermia. *Circulation* 2000;101:E233-44.
  8. Wollenek G, Honarwar N, Golej J, Marx M. Cold water submersion and cardiac arrest in treatment of severe hypothermia with cardiopulmonary bypass. *Resuscitation* 2002;52:255-63.
  9. Vassallo SU, Delaney KA, Hoffman RS, Slater W, Goldfrank LR. A prospective evaluation of the electrocardiographic manifestations of hypothermia. *Acad Emerg Med* 1999;6:1121-6.
  10. OSBORN JJ. Experimental hypothermia; respiratory and blood pH changes in relation to cardiac function. *Am J Physiol* 1953;175:389-98.
  11. Patel A, Getsos JP, Moussa G, Damato AN. The Osborn wave of hypothermia in normothermic patients. *Clin Cardiol* 1994;17:273-6.
  12. Martínez Martínez JA. Postoperative pericarditis and Osborn wave. [Article in Spanish] *Medicina (B Aires)* 1998;58:428. [Abstract]
  13. Abbott JA, Cheitlin MD. The nonspecific camel-hump sign. *JAMA* 1976;235:413-4.
  14. Yalçın M, Işılak Z, Uz Ö, Doğan M. Hipokalemi ve hipotermi ile ilişkili dev J dalgası (Osborn dalgası). *Anadolu Kardiyoloji Dergisi* 2012;12:698-703.