



Since January 2020 Elsevier has created a COVID-19 resource centre with free information in English and Mandarin on the novel coronavirus COVID-19. The COVID-19 resource centre is hosted on Elsevier Connect, the company's public news and information website.

Elsevier hereby grants permission to make all its COVID-19-related research that is available on the COVID-19 resource centre - including this research content - immediately available in PubMed Central and other publicly funded repositories, such as the WHO COVID database with rights for unrestricted research re-use and analyses in any form or by any means with acknowledgement of the original source. These permissions are granted for free by Elsevier for as long as the COVID-19 resource centre remains active.

## COVID-19: Pathophysiology of Acute Disease 4



# A tricompartamental model of lung oxygenation disruption to explain pulmonary and systemic pathology in severe COVID-19

Dennis McGonagle, Charlie Bridgewood, James F M Meaney

The emergent 21st century betacoronaviruses, including SARS-CoV-2, lead to clinicopathological manifestations with unusual features, such as early-onset chest pain, pulmonary infarction, and pulmonary and systemic thromboembolism that is pathologically linked to extensive capillary, arteriolar, and venular thrombosis. Early ground glass opacities detected by CT, which are reminiscent of lung infarcts associated with pulmonary embolism, point to a novel vascular pathology in COVID-19. Under physiological conditions, normal parenchymal oxygenation is maintained by three sources: the alveolus itself and dual oxygen supply from the pulmonary and bronchial artery circulations. We propose a model in which these three components are disrupted in COVID-19 pneumonia, with severe viral alveolitis and concomitant immunothrombotic obstruction of the pulmonary and bronchiolar circulation. Tricompartamental disruption might have two main consequences: systemic clot embolisation from pulmonary vein territory immunothrombosis, and alveolar–capillary barrier disruption with systemic access of thrombogenic viral material. Our model encompasses the known pathological and clinical features of severe COVID-19, and has implications for understanding patient responses to immunomodulatory therapies, which might exert an anti-inflammatory effect within the vascular compartments.

### Introduction

COVID-19, caused by the novel betacoronavirus SARS-CoV-2, represents a spectrum from mild upper airway disease to life-threatening pneumonia.<sup>1</sup> SARS-CoV-2 shows a proclivity for infection of angiotensin-converting enzyme 2 (ACE2)-expressing cells that are widely distributed in the respiratory tract, including a subset of lung parenchymal type II pneumocytes, and also uses other co-receptors, including transmembrane serine protease 2 (TMPRSS2), for viral entry.<sup>2,3</sup> Post-mortem studies show severe alveolus-centred viral pneumonia and pulmonary infarction, which might help to explain the unusually high frequency of chest pain in COVID-19, a pattern seen infrequently in other viral pneumonias.<sup>4,5</sup> Despite the central role of viral alveolitis, the term COVID-19 pneumonia conceals the fact that much of the pathology of COVID-19 represents pulmonary vascular territory immunothrombosis.<sup>6–9</sup> The clot composition in severe COVID-19 is rich in megakaryocytes, platelets, neutrophils including NETotic neutrophils, and other immune cells and has been well described elsewhere.<sup>10,11</sup>

Although the concept of immune-driven pulmonary vascular thrombosis, termed immunothrombosis, is well established in severe COVID-19 pneumonia, how this process links to heterogeneous extrapulmonary disease features and to the beneficial effect of some immunotherapies in severe COVID-19 remains enigmatic. The aim of this Series paper is to propose a unifying theory to reconcile the protean manifestations of severe COVID-19, invoking compromised pulmonary parenchymal oxygenation as a result of severe viral alveolitis and concomitant immunothrombotic

obstruction of the pulmonary and bronchiolar circulation, the three oxygen inputs to the lung compartment. We show how CT imaging in early COVID-19 is key to explaining this lung pathology.

Beyond the lung, we highlight how alveolar–vascular compartment disruption, in the absence of systemic viral infection and replication, might contribute to extrapulmonary COVID-19 manifestations. We also

### Key messages

- Novel betacoronavirus infections, including SARS-CoV-2, have a distinct immunopathology that arises from viral infection of the alveolar compartment and immunothrombosis of the juxtaposed pulmonary vascular compartment
- Our tricompartamental model invokes both pulmonary circulation and terminal bronchial circulation obstruction over a wide area, and accounts for the propensity for pulmonary infarction that is relatively uncommon in other conditions, including conventional pulmonary embolism
- Pulmonary venular territory thrombosis with clot embolisation of viral RNA-containing immunothrombotic material might explain some of the extrapulmonary features of severe COVID-19
- SARS-CoV-2 infection is compartmentalised to the alveolar space and immunothrombosis is compartmentalised to the vascular space; therefore, beneficial effects of corticosteroids and immunotherapy might arise due to positive effects in the vascular space

*Lancet Respir Med* 2021; 9: 665–72

Published Online  
May 14, 2021  
[https://doi.org/10.1016/S2213-2600\(21\)00213-7](https://doi.org/10.1016/S2213-2600(21)00213-7)  
See [Comment](#) page 551

This is the fourth in a [Series](#) of four papers about COVID-19

Leeds Institute of Rheumatic and Musculoskeletal Medicine, University of Leeds, Leeds, UK (Prof D McGonagle FRCPI, C Bridgewood PhD); National Institute for Health Research Leeds Biomedical Research Centre, Leeds Teaching Hospitals, Leeds, UK (Prof D McGonagle); and Department of Radiology and Thomas Mitchell Centre for Advanced Medical Imaging, St James Hospital and Trinity College Dublin, Dublin, Ireland (Prof J F M Meaney FRCR)

Correspondence to: Prof Dennis McGonagle, Leeds Institute of Rheumatic and Musculoskeletal Medicine, University of Leeds, Leeds LS7 4SA, UK  
[d.g.mcgonagle@leeds.ac.uk](mailto:d.g.mcgonagle@leeds.ac.uk) and

Prof James F M Meaney, Department of Radiology and Thomas Mitchell Centre for Advanced Medical Imaging, St James Hospital and Trinity College Dublin, Dublin 8, Ireland  
[jmeaney@tcd.ie](mailto:jmeaney@tcd.ie)

consider how immunothrombosis of the pulmonary venous drainage territory in COVID-19 might contribute to impaired oxygenation and also predispose to clot propagation, with ensuing systemic embolisation leading to manifestations such as cryptogenic stroke, renal infarction, peripheral artery occlusion, and cutaneous vasculitis.<sup>12</sup> We hope that our synthesis of data provides a robust model for better understanding of novel betacoronavirus infections, with implications for improved therapeutic approaches.

### Vascular pathology: CT and clinical findings

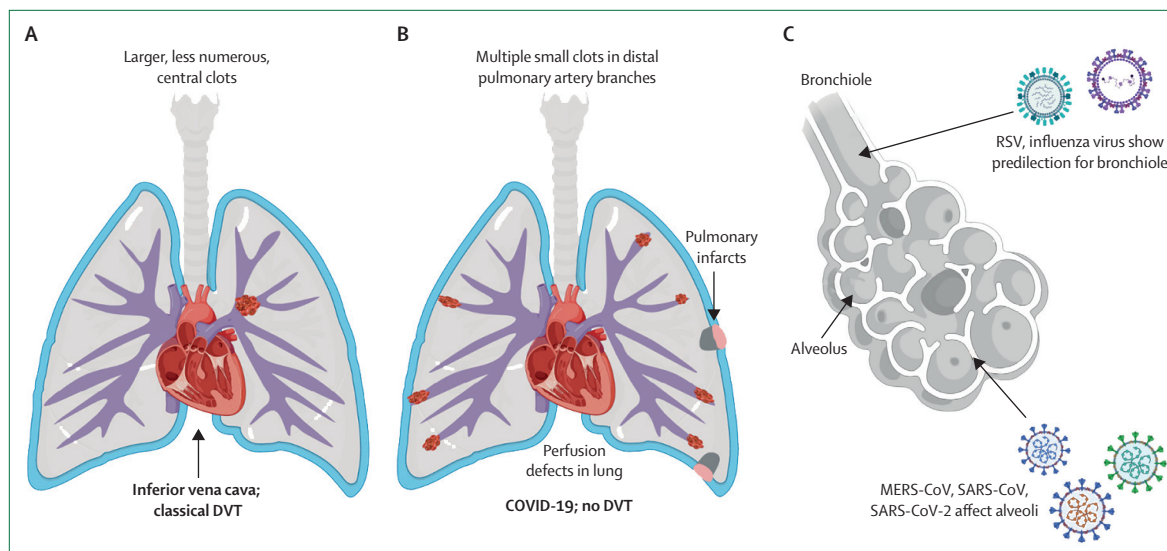
Unlike pathological post-mortem studies, chest CT or CT pulmonary angiogram (CTPA) can provide a dynamic pan-pulmonary view of severe COVID-19 from a timepoint early in the disease course. An important pointer to the central role of the vascular compartment in COVID-19 comes from CT studies showing a high prevalence of pulmonary thromboembolism features. A meta-analysis of SARS-CoV-2 infection revealed chest pain to be a major feature of the clinical presentation of COVID-19 compared with other viral pneumonias,<sup>13,14</sup> which is probably related to these CT features. The alveolar tropism of SARS-CoV-2 explains the extensive early appearance of ground glass opacities on CT, a pattern characteristic of severe SARS-CoV-2 infection that is highly specific for suspected COVID-19<sup>15,16</sup> and uncommon in other viral pneumonias.<sup>17–19</sup> Recently, we reported that patients with chest pain—which might lead to suspicion of pulmonary embolism—who presented in the outpatient setting during the COVID-19 pandemic era and who had CTPA negative for pulmonary embolism were more likely to have ground glass opacities in the lung periphery than were patients presenting in the same way in 2019, highlighting the vascular disease component in early COVID-19.<sup>20</sup>

In addition to showing severe alveolitis, several autopsy studies have confirmed extensive in-situ thrombosis of the capillary networks and adjacent microcirculation, and larger vessel thrombosis in COVID-19, corresponding to areas of ground glass opacities demonstrated on CT.<sup>10,21,22</sup> This localised form of pulmonary immunothrombosis, which we have termed pulmonary intravascular coagulopathy (PIC),<sup>23,24</sup> is a discrete entity in COVID-19 that is characterised by capillary and larger pulmonary vessel thrombosis as the dominant feature—a pattern less common in influenza and other viral pneumonias.<sup>7</sup> The typical lung abnormalities on CT in the early stages of severe COVID-19 are peripherally located, with a dominant posterior distribution and occasionally a reversed halo sign (the so-called atoll sign),<sup>16,25</sup> a finding previously reported in acute thromboembolic pulmonary infarction. Other vascular findings include dilated peripheral vessels supplying areas of abnormal lung parenchyma, perfusion defects including mottled or amorphous perfusion defects (analogous to chronic pulmonary thromboembolic disease) with increased perfusion of the adjacent lung, as

shown by dual-energy CT (DECT), or wedge-shaped defects analogous to acute pulmonary infarcts.<sup>26</sup> Mechanistically, these vascular pathology changes in severe COVID-19 pneumonia probably relate to high ACE2 and other receptor expression on type II pneumocytes, which leads to SARS-CoV-2 infection in close juxtaposition to a myriad of capillaries and other small vessels.<sup>6</sup>

### In-situ thrombosis and pulmonary thromboembolic disease

Early in the course of the pandemic, all pulmonary intravascular clots were attributed (probably erroneously) to conventional pulmonary embolism,<sup>27–29</sup> of which there was undoubtedly a higher incidence in COVID-19 compared with pneumonias due to other causes.<sup>30</sup> Patients with suspected pulmonary embolism had higher D-dimer levels than those without pulmonary embolism, were more likely to be in the intensive care unit (ICU; 75% vs 32%), and were treated more often with low-molecular-weight heparin before CT angiography (78% vs 23%). In COVID-19 infection, D-dimer greater than 2660 µg/L had a sensitivity of 100% and a specificity of 67% for pulmonary embolism diagnosed on CT angiography.<sup>31</sup> The pattern and distribution of pulmonary arterial filling defects on CTPA differ in COVID-19 compared with non-COVID-19 cases (figure 1). Van Dam and colleagues<sup>27</sup> compared 23 consecutive patients with COVID-19 pneumonia with 100 consecutive patients diagnosed with acute pulmonary embolism before the COVID-19 era, and reported clots of smaller size, more numerous and more widespread clots, and higher frequency of associated lung parenchymal changes (infarction) in COVID-19. Remarkably, a total of 178 of 460 (39%) pulmonary artery segments were affected by what was deemed to be pulmonary embolism, all of which were in areas with ground glass opacities, and none of the 23 patients with COVID-19 had deep vein thrombosis (DVT), suggesting that the intravascular clots did not originate from the lower extremities—the usual source of conventional pulmonary embolism—but instead represented in-situ immunothrombosis (figure 1).<sup>27</sup> Further evidence for in-situ thrombus was the lower thrombus load and the fact that smaller vessels were involved. Leonard-Lorant and colleagues<sup>31</sup> reported acute pulmonary embolism in 32 of 106 (30%) patients, with a higher occurrence of embolism to smaller arteries (44% to segmental and subsegmental arteries) than would be expected in thromboembolism, a finding also reported by Poyiadji and colleagues,<sup>32</sup> who noted embolism in 72 of 328 (22%) patients, with an unusually high proportion (56·5%) of segmental and subsegmental clots. Echocardiographic studies also showed that right ventricular strain, which is more common in embolism to proximal arteries, was less frequent in patients with COVID-19 than in patients with conventional embolism; nevertheless, right ventricular strain was associated with mortality in both conventional pulmonary embolism and severe COVID-19.<sup>33,34</sup>



**Figure 1: Pulmonary arterial filling defects in severe COVID-19**

(A) Typical pulmonary emboli originating from the deep venous circulation, detected by CT pulmonary angiogram, are larger, fewer in number, and more central than those reported in severe COVID-19. Pulmonary emboli described in severe COVID-19 might be linked, at least in part, to conventional risk factors. (B) Pulmonary intravascular coagulopathy is a type of inflammation-driven immunothrombosis that arises due to the extensive interface between alveoli and the capillary network, manifesting as distal pulmonary artery and vein branch occlusion in COVID-19. We propose that extensive small vessel arteriolar inflammation and immunothrombotic occlusion could lead to retrograde extension, manifesting as multiple distal emboli (actually thrombi) supplying areas of pneumonic consolidation. Distal territory infarction might contribute to pleuritic chest pain with a negative CT pulmonary angiogram (thrombi are beyond the resolution capability of CT). (C) Coronaviruses including MERS-CoV, SARS-CoV, and SARS-CoV-2 show proclivity to alveolar pneumocyte infection and damage. Severe viral alveolitis is associated with immunothrombosis of the integrated arteriolar, capillary, and venular networks adjacent to sites of extensive viral alveolitis or extensive immune activation in response to alveolitis. By contrast, RSV and influenza show a more bronchiole-centric infection that is proximal to the alveolar network and cause damage without the same degree of insult to the alveolar capillary network. DVT=deep vein thrombosis. MERS-CoV=Middle East respiratory syndrome coronavirus. RSV=respiratory syncytial virus. SARS-CoV=severe acute respiratory syndrome coronavirus.

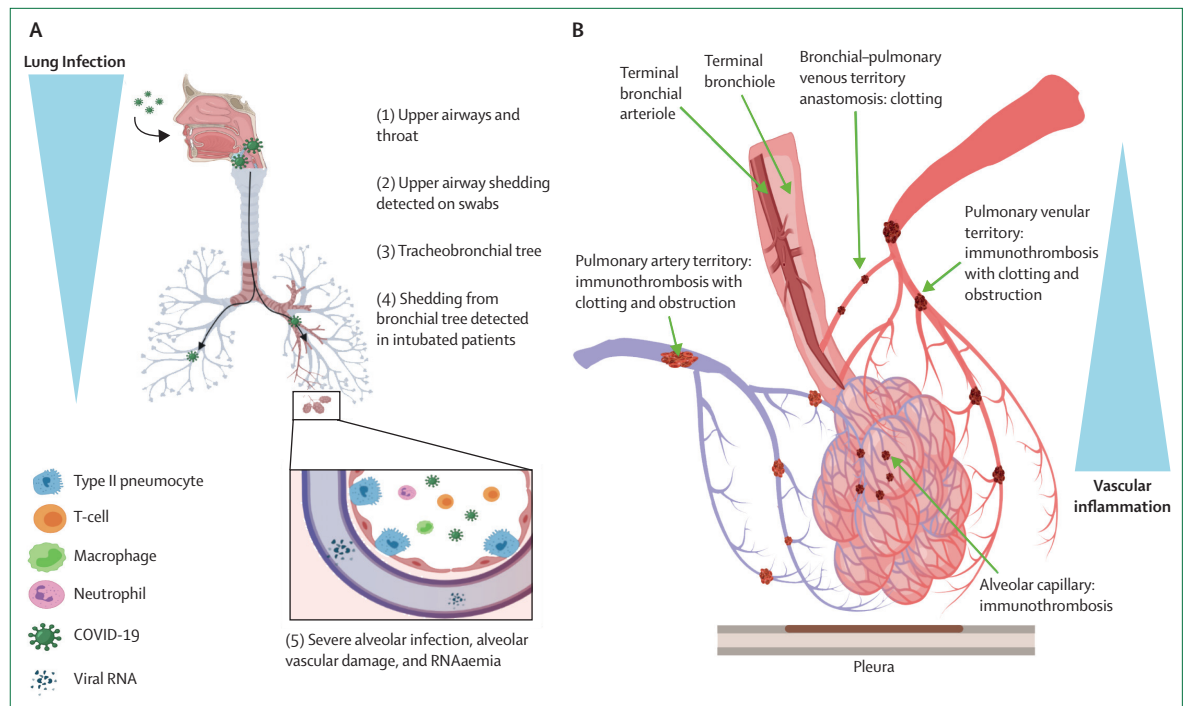
The observation that pulmonary arterial filling defects visible on CTPA in patients with COVID-19 are preferentially localised to areas of ground glass opacities has led to the suggestion that they develop by proximal extension of extensive distal PIC, rather than representing emboli per se. In essence, PIC walls off the infection and restricts viraemia,<sup>23,24</sup> but at the potential expense of pulmonary infarction. Regardless of the presence of larger clots, whether embolic in origin or developing locally as a consequence of immunothrombosis, pulmonary infarction would account for the unusually high incidence of chest pain at presentation owing to involvement of the exquisitely pain-sensitive pleural surface.<sup>14,17,35,36</sup> However, considering the small size of the vessels supplying the area of lung occupied by ground glass opacities, visualisation of PIC-induced clots is limited by the resolution constraints of CT, although clots can be easily identified at post-mortem. Despite the spatial limitation of CTPA in detecting microemboli or microthrombi, magnetic resonance pulmonary perfusion and single-photon emission CT (SPECT) pulmonary perfusion could potentially show the small areas of hypoperfusion secondary to PIC (and at the same time could also confirm or exclude pulmonary embolism to large and medium-sized arteries).<sup>37,38</sup> Moreover, the alveolar tropism of betacoronavirus and the functional integration of alveoli with the capillary network and

adjacent small vessels distinguishes COVID-19 from the disease caused by other respiratory viruses, including influenza and respiratory syncytial virus, which show more proximal airway involvement with discrete pathological mechanisms (figure 1C).

### Tricompartamental model of severe COVID-19

#### The alveolus and vascular territory interlink

The lung parenchyma (compartment) receives oxygen input from a triad of sources: dual blood supply from the pulmonary and bronchial arteries, and a third supply directly from the alveoli (see the tricompartamental model; figure 2).<sup>40</sup> The three sources maintain adequate lung parenchymal oxygenation under physiological conditions, and interference with one or more of these sources can cause lung infarction under some circumstances. The differential contribution of the bronchial and pulmonary arteries to lung oxygenation is crucial to understanding why infarction—as manifested by wedge-shaped parenchymal abnormalities, which are similar to the ground glass opacities of COVID-19—is rare in pulmonary embolism, but common in COVID-19. For example, despite high flow within the pulmonary arteries (100% of the cardiac output goes to the lungs), pulmonary artery blood is deoxygenated and provides minimal alveolar oxygenation, whereas the bronchial arteries, which transmit only 1% of the cardiac



**Figure 2: A tricompartamental model of severe COVID-19**

The three oxygen inputs to the lung are compromised in COVID-19: direct alveolar oxygenation; the pulmonary circulation comprising arteriolar, capillary, and pulmonary venular territory; and the bronchial artery circulation. (A) SARS-CoV-2 infection leads to severe alveolitis, which restricts the direct oxygen supply in COVID-19 pneumonia. (B) Immunothrombosis disrupts the alveolar capillary network and the terminal pulmonary arterioles (one of the dual blood supplies). Stasis within multiple pulmonary arteriolar vessels, with retrograde clot extension into larger pulmonary arteries, can be detected on CT pulmonary angiogram. The second blood supply, from the bronchial artery (which is known to terminate at the level of terminal bronchioles, where it anastomoses with pulmonary capillaries and venules) is also disrupted and is key to understanding why pulmonary infarction occurs,<sup>39</sup> because it transmits oxygenated blood to the alveolus, unlike the pulmonary artery, in which blood is deoxygenated. Pulmonary infarction in COVID-19 also arises from pulmonary venular territory thrombosis caused by stasis of the pulmonary and bronchial circulations, and the inflammatory response within the circulation and the closely juxtaposed extra-venular alveolar networks. The vascular compartment is strongly linked to immune-driven thrombosis rather than direct viral infection.

output, provide a critical oxygen supply as they arise from the aorta and contain oxygenated blood.<sup>39–43</sup>

The bronchial arteries form a dual-layered adventitial and submucosal plexus along the airways, but crucially form extensive anastomoses between the bronchial and pulmonary arteries at the bronchiolar level but also within the lung lobule, where extensive anastomoses between the pulmonary arteriolar circulation and alveolar capillary beds exist.<sup>39</sup> Additional anastomoses exist between precapillary bronchial arteries (in the pleura and bronchial walls) and pulmonary veins (figure 2). Furthermore, the bronchial venous drainage located in the peripheral lung forms broad venous networks that communicate extensively with the pulmonary veins and ultimately drain into the left side of the heart, creating the so-called bronchial systemic-to-pulmonary flow. It is likely that the extensive alveolus-centric immunothrombosis in severe COVID-19 comprises the terminal but not the proximal bronchial arterial tree supply, explaining distal necrosis but relative airway preservation (figure 2).

The rare occurrence of lung infarction in non-COVID-19-related pulmonary embolism is

explained by the fact that embolic occlusion of the pulmonary artery removes only one component of the tricompartamental model—the one that supplies deoxygenated blood and therefore little oxygenation to the parenchyma—while the remaining two sources (the bronchial artery and direct oxygenation from the alveoli) remain unscathed and provide sufficient oxygenation to prevent infarction. Also, because of the interconnectedness of the pulmonary arterial and bronchial arterial circulation, reduced pulmonary arterial flow is offset by augmented bronchial artery flow, which has been shown to increase by 300% following pulmonary embolism, thus further reducing the risk of infarction.<sup>39,42</sup> In severe COVID-19, we hypothesise that immunothrombosis of the terminal bronchial arteriolar to pulmonary venular vascular network disrupts all three components of the tricompartamental model: direct supply of oxygen from the alveoli obliterated by alveolitis, and pulmonary and bronchial artery supplies lost by PIC or immunothrombosis, leading to widespread lung infarcts. We propose that our model offers an additional reason for the strong association between ground glass opacities and what might

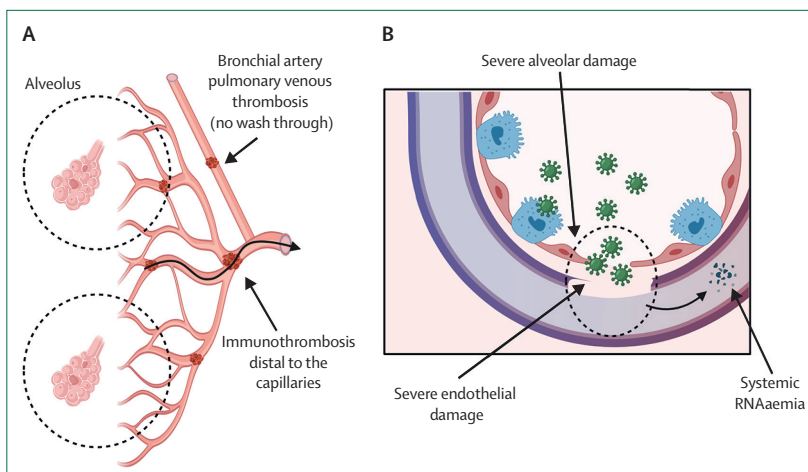


previously have been viewed as emboli in the same segments, but which probably represent in-situ thrombi that have extended proximally in the pulmonary arteriolar tree rather than representing true emboli. In essence, COVID-19-involved lung rendered ischaemic by impairment of all components of the tricompartamental model could be tipped into infarcted lung with further compromise in blood supply by proximal pulmonary artery clotting.

How does this model differ from pulmonary infarction in typical pulmonary embolism? With respect to conventional pulmonary embolism, distal emboli in smaller vessels are more likely to lead to infarction, whereas larger, central pulmonary emboli are associated with a compensatory increase in bronchial artery flow and reduced risk of infarction.<sup>44</sup> Pulmonary infarction in pulmonary embolism is also associated with concomitant heart failure, which might lead to elevated pulmonary venous pressures and reduced cardiac output, both of which negatively affect the bronchial–pulmonary axis.<sup>45</sup>

### Pulmonary venular territory

Our tricompartamental model encompasses a central role for pulmonary venules, with two crucial effects. First, pulmonary venular territory involvement in the inflammatory process provides a double insult to the lung as any blood traversing the alveolus will meet with further obstruction, and collateral flow from adjacent, uninvolved lung would be ineffective owing to venous obstruction. In essence, terminal pulmonary artery, terminal bronchial artery, capillary, and venous occlusion all follow COVID-19 viral alveolitis and represent a scenario hitherto unappreciated in pulmonology (figure 2). This picture could account for the unusually high frequency of infarction at autopsy, corresponding to the widespread, severe parenchymal abnormalities on CT. Second, we have suggested that pulmonary venous thrombosis developing within the lung parenchyma affected by PIC has another deleterious effect, in that clots developing within the pulmonary venules that lie beyond the capillary network provide a source from which systemic embolism can occur.<sup>23</sup> Referring back to the tricompartamental model, flow within the bronchial artery is sufficient to perfuse the pulmonary veins in conventional pulmonary embolism and prevent thrombosis owing to profuse bronchial–pulmonary anastomoses. However, in severe COVID-19, we hypothesise that thrombosis of the distal bronchial arteries (which remain patent in conventional pulmonary embolism) removes the flush-through effect, thus exacerbating stasis and leading to venular territory thrombosis (figure 3). Post-mortem studies have shown venous thrombosis in COVID-19,<sup>10,46</sup> but the small pulmonary vein network is currently beyond the resolution capability of CT. However, case reports of large pulmonary vein thrombosis have now emerged in severe



**Figure 3: Tricompartamental dysregulation and the severe systemic impact of COVID-19**

(A) Immunothrombosis disrupts the terminal pulmonary arterioles (one of the dual blood supplies) and also eliminates anastomoses between the small bronchial artery and the distal pulmonary arteriole or capillary and vein, eliminating the wash-through effect of the pulmonary venules by the bronchial artery, which maintains venous patency in pulmonary embolism. Clot formation within pulmonary venules that are distal to the capillary networks provides a source from which systemic embolisation can occur. (B) Breakdown of the alveolar–capillary barrier permits direct systemic circulation access to viral RNA (RNAemia), viral proteins, and whole SARS-CoV-2 with the effect that the immunothrombotic process initially confined to the lung now becomes systemic, compounded by other independent factors including hypercoagulability and severe systemic immune activation of neutrophils, platelets, and mononuclear cells. Thus, failure of the tricompartamental model to constrain SARS-CoV-2 locally might lead to similar immunothrombotic complications in organs distant from the lung.

COVID-19,<sup>47,48</sup> which provides a plausible mechanism to explain the propensity for systemic manifestations such as embolism to the kidney and brain, and might also explain the cutaneous manifestations of severe COVID-19 pneumonia.<sup>12,23</sup>

### Other aspects of pathology in the vascular compartment

In our proposed model, severe COVID-19 alveolitis is intimately associated with a lung vasculopathy, with extrapulmonary effects potentially stemming from the unique way in which the virus interferes with the physiology of the tricompartamental model. Generally, SARS-CoV-2 RNA is not detectable in the blood in milder infection, but can be detected in some severe cases<sup>49–52</sup> and correlates with interleukin-6 concentrations in critically ill patients.<sup>53</sup> Patients with detectable RNA in the blood were found to be older and to have more comorbidities, and were more likely to require ICU admission and mechanical ventilation.<sup>50,54</sup> Despite the fact that alveolar cells are separated from a massive pulmonary capillary network by approximately 2–3  $\mu\text{m}$  only, immunothrombosis-mediated containment of the pathogen is the reason why SARS-CoV-2 blood detection is the exception rather than the rule.<sup>55,56</sup>

Breakdown of the tricompartamental alveolar–vascular barrier and systemic access of viral RNA, viral proteins, and viral particles undoubtedly contribute to systemic vascular pathology that complicates severe COVID-19 disease (figure 3B). However, there is very little compelling evidence for active viral endotheliitis as a key driver of

**Panel: Goals of future research**

- Identify factors that determine the extent of pulmonary venular and arteriolar territory thrombosis
- Determine the role of the bronchial arteriolar territory in immunothrombosis
- Understand the effects of immunotherapy through the lens of the tricompartamental model and homeostasis restoration
- Establish whether anticoagulation therapy affects tricompartamental barrier disruption, and whether such therapy is associated with increased RNAemia
- Determine to what extent similar mechanisms might lead to systemic thromboembolic disease in other types of pneumonia
- Explore whether alveolar–vascular barrier breakdown that results in RNAemia is due to virus-mediated or immune-driven damage
- Conduct further studies to establish whether SARS-CoV-2 can cause capillary viral endotheliitis in vivo
- Assess the extent of embolisation arising from the pulmonary venular territory in imaging and pathological studies

vascular immunopathology, with SARS-CoV-2 replication being confined largely to the alveolar compartment. The initial electron microscopy reports of viral endotheliitis were thought by Goldsmith and colleagues to represent cell organelles.<sup>57</sup> Furthermore, several laboratory studies have failed to culture SARS-CoV-2 in endothelial cells.<sup>58–60</sup> Hence, severe COVID-19 might also show uni-compartmentalisation of replicating SARS-CoV-2 to the alveolar compartment (figure 2).

**Conclusions**

We have highlighted how disruption of a tricompartamental model of lung parenchymal oxygenation in severe COVID-19 might offer an overarching hypothesis for the clinicopathological features of severe disease. The model explains the unique clinical and CT findings in COVID-19, including intravascular clots and the pathological correlates of widespread pulmonary infarcts due to tricompartamental disruption, which account for the high incidence of chest pain in early pneumonia. The tricompartamental model also accounts for differences in the likelihood of lung infarction in conventional pulmonary embolism compared with COVID-19. Directions for future research are highlighted in the panel.

The model is not predicated on a unique role for the ACE2 receptor, since an identical tricompartamental model seems to apply to Middle East respiratory syndrome coronavirus, which uses the dipeptidyl peptidase 4 (DPP4) receptor for alveolar cell entry.<sup>61</sup> Indeed, the TMPRSS2 co-receptor for SARS-CoV-2 also has a key role for cellular entry of other betacoronaviruses and other respiratory

**Search strategy and selection criteria**

We searched PubMed for papers published in English from database inception to April 5, 2021, using combinations of the search terms “COVID-19 pneumonia”, “SARS-CoV-2”, “SARS”, and “MERS”, with “pulmonary thrombosis”, “embolism”, and “pulmonary infarction”. We also searched for “pulmonary vein thrombosis”, focusing on its causes and complications. We reviewed the literature and publications on lung microvascular anatomy through searches of PubMed, from database inception to April 5, 2021, and our own files. For SARS-CoV-2, articles published in English between Dec 22, 2019, and April 5, 2021, were reviewed. The final list of references was selected with a view to developing a model of lung oxygenation disruption in severe COVID-19.

viruses.<sup>62</sup> Essentially, early active viral alveolitis, when severe, might be a trigger for local immunothrombosis, and the tricompartamental model might represent a method of virus containment that limits the potentially more dangerous dissemination of viral adjuvants to the systemic circulation. Therefore, the optimum management of pulmonary and bronchial vascular territory immunothrombosis in subjects with active SARS-CoV-2 alveolitis might pose considerable challenges.

Our model suggests a role for occult pulmonary venular territory thrombosis, caused by venous stasis secondary to disruption of the tricompartamental model, which might lead to systemic thromboembolism. The fact that viral replication occurs largely, or possibly exclusively, within the alveolar compartment, coupled with the fact that an excessive immune response can occur within the vascular compartments, offers a novel insight into the reported efficacy of corticosteroids and other therapies in some patients with severe COVID-19 pneumonia (figure 2). Further studies are needed to address the issue of pulmonary viral endotheliitis in vivo (panel). However, the clot complexity in severe COVID-19, with prominent neutrophilic and platelet material, points to possible resistance to anticoagulation strategies in severe disease.<sup>63</sup> We hope that targeted pathological studies of the pulmonary microvasculature in severe COVID-19 will provide further insights into this recently recognised immunopathological entity, and point the way to improved management strategies for patients.

**Contributors**

DMcG and JFMM jointly developed the compartmental model for lung disease in COVID-19. All three authors contributed to discussion of the systemic implications of the tricompartamental model of lung oxygenation disruption. CB made the figures. All authors addressed the editors' and reviewers' comments, and approved the final version of the article.

**Declaration of interests**

We declare no competing interests.

**Acknowledgments**

DMcG's work is supported by the Leeds National Institute for Health Research Biomedical Research Centre. JFMM's research centre, the

Thomas Mitchell Centre for Advanced Medical Imaging, is funded by The Health Research Board of Ireland. No funding was received for the writing of this Series paper.

## References

- Chen N, Zhou M, Dong X, et al. Epidemiological and clinical characteristics of 99 cases of 2019 novel coronavirus pneumonia in Wuhan, China: a descriptive study. *Lancet* 2020; **395**: 507–13.
- Verdecchia P, Cavallini C, Spanevello A, Angeli F. The pivotal link between ACE2 deficiency and SARS-CoV-2 infection. *Eur J Intern Med* 2020; **76**: 14–20.
- Hoffmann M, Kleine-Weber H, Schroeder S, et al. SARS-CoV-2 cell entry depends on ACE2 and TMPRSS2 and is blocked by a clinically proven protease inhibitor. *Cell* 2020; **181**: 271–80.e8.
- Edler C, Schröder AS, Aepfelbacher M, et al. Dying with SARS-CoV-2 infection—an autopsy study of the first consecutive 80 cases in Hamburg, Germany. *Int J Legal Med* 2020; **134**: 1275–84.
- Nicholls JM, Poon LL, Lee KC, et al. Lung pathology of fatal severe acute respiratory syndrome. *Lancet* 2003; **361**: 1773–78.
- Sungnak W, Huang N, Bécavin C, et al. SARS-CoV-2 entry factors are highly expressed in nasal epithelial cells together with innate immune genes. *Nat Med* 2020; **26**: 681–87.
- Ackermann M, Verleden SE, Kuehnel M, et al. Pulmonary vascular endothelialitis, thrombosis, and angiogenesis in Covid-19. *N Engl J Med* 2020; **383**: 120–28.
- Varga Z, Flammer AJ, Steiger P, et al. Endothelial cell infection and endotheliitis in COVID-19. *Lancet* 2020; **395**: 1417–18.
- Lang M, Som A, Carey D, et al. Pulmonary vascular manifestations of COVID-19 pneumonia. *Radiol Cardiothorac Imaging* 2020; **2**: e200277.
- Fox SE, Akmatbekov A, Harbert JL, Li G, Brown JQ, Vander Heide RS. Pulmonary and cardiac pathology in African American patients with COVID-19: an autopsy series from New Orleans. *Lancet Respir Med* 2020; **8**: 681–86.
- Middleton EA, He X-Y, Denorme F, et al. Neutrophil extracellular traps contribute to immunothrombosis in COVID-19 acute respiratory distress syndrome. *Blood* 2020; **136**: 1169–79.
- McGonagle D, Bridgewood C, Ramanan AV, Meaney JF, Wadat A. COVID-19 vasculitis and novel vasculitis mimics. *Lancet Rheumatol* 2021; **3**: e224–33.
- Zhu J, Ji P, Pang J, et al. Clinical characteristics of 3,062 COVID-19 patients: a meta-analysis. *J Med Virol* 2020; **92**: 1902–14.
- Li K, Wu J, Wu F, et al. The clinical and chest CT features associated with severe and critical COVID-19 pneumonia. *Invest Radiol* 2020; **55**: 327–31.
- Ooi GC, Khong PL, Müller NL, et al. Severe acute respiratory syndrome: temporal lung changes at thin-section CT in 30 patients. *Radiology* 2004; **230**: 836–44.
- Zhu J, Zhong Z, Li H, et al. CT imaging features of 4121 patients with COVID-19: a meta-analysis. *J Med Virol* 2020; **92**: 891–902.
- Wu J, Wu X, Zeng W, et al. Chest CT findings in patients with coronavirus disease 2019 and its relationship with clinical features. *Invest Radiol* 2020; **55**: 257–61.
- Kanne JP. Chest CT findings in 2019 novel coronavirus (2019-nCoV) infections from Wuhan, China: key points for the radiologist. *Radiology* 2020; **295**: 16–17.
- Liu P, Tan X-Z. 2019 novel coronavirus (2019-nCoV) pneumonia. *Radiology* 2020; **295**: 19.
- Harrison SR, Klassen JR, Bridgewood C, Scarsbrook A, Marzo-Ortega H, McGonagle D. Chest pain mimicking pulmonary embolism may be a common presentation of COVID-19 in ambulant patients without other typical features of infection. *J Intern Med* 2021; published online Feb 9. <https://doi.org/10.1111/joim.13267>
- Lax SF, Skok K, Zechner P, et al. Pulmonary arterial thrombosis in COVID-19 with fatal outcome: results from a prospective, single-center, clinicopathologic case series. *Ann Intern Med* 2020; **173**: 350–61.
- Thachil J, Srivastava A. SARS-2 coronavirus-associated hemostatic lung abnormality in COVID-19: is it pulmonary thrombosis or pulmonary embolism? *Semin Thromb Hemost* 2020; **46**: 777–80.
- McGonagle D, O'Donnell JS, Sharif K, Emery P, Bridgewood C. Immune mechanisms of pulmonary intravascular coagulopathy in COVID-19 pneumonia. *Lancet Rheumatol* 2020; **2**: e437–45.
- McGonagle D, Sharif K, O'Regan A, Bridgewood C. The role of cytokines including interleukin-6 in COVID-19 induced pneumonia and macrophage activation syndrome-like disease. *Autoimmun Rev* 2020; **19**: 102537.
- de Farias LPG, Strabelli DG, Sawamura MVY. COVID-19 pneumonia and the reversed halo sign. *J Bras Pneumol* 2020; **46**: e20200131.
- Si-Mohamed S, Chebib N, Sigovan M, et al. In vivo demonstration of pulmonary microvascular involvement in COVID-19 using dual-energy computed tomography. *Eur Respir J* 2020; **56**: 2002608.
- van Dam LF, Kroft LJM, van der Wal LI, et al. Clinical and computed tomography characteristics of COVID-19 associated acute pulmonary embolism: a different phenotype of thrombotic disease? *Thromb Res* 2020; **193**: 86–89.
- Rotzinger DC, Beigelman-Aubry C, von Garnier C, Qanadli SD. Pulmonary embolism in patients with COVID-19: time to change the paradigm of computed tomography. *Thromb Res* 2020; **190**: 58–59.
- Al-Ani F, Chehade S, Lazo-Langner A. Thrombosis risk associated with COVID-19 infection. A scoping review. *Thromb Res* 2020; **192**: 152–60.
- Suh YJ, Hong H, Ohana M, et al. Pulmonary embolism and deep vein thrombosis in COVID-19: a systematic review and meta-analysis. *Radiology* 2021; **298**: e70–80.
- Leonard-Lorant I, Delabranche X, Severac F, et al. Acute pulmonary embolism in COVID-19 patients on CT angiography and relationship to D-Dimer levels. *Radiology* 2020; **296**: e189–91.
- Poyiadji N, Shahin G, Noujaim D, Stone M, Patel S, Griffith B. COVID-19-associated acute hemorrhagic necrotizing encephalopathy: CT and MRI features. *Radiology* 2020; **296**: e119–20.
- Li Y, Li H, Zhu S, et al. Prognostic value of right ventricular longitudinal strain in patients with COVID-19. *JACC Cardiovasc Imaging* 2020; **13**: 2287–99.
- Bryce YC, Perez-Johnston R, Bryce EB, Homayoon B, Santos-Martin EG. Pathophysiology of right ventricular failure in acute pulmonary embolism and chronic thromboembolic pulmonary hypertension: a pictorial essay for the interventional radiologist. *Insights Imaging* 2019; **10**: 18.
- de Oliveira Lima CMA. Information about the new coronavirus disease (COVID-19). *Radiol Bras* 2020; **53**: V–VI.
- Debray M-P, Tarabay H, Males L, et al. Observer agreement and clinical significance of chest CT reporting in patients suspected of COVID-19. *Eur Radiol* 2021; **31**: 1081–89.
- Bajc M, Lindqvist A. Ventilation/perfusion SPECT imaging—diagnosing other cardiopulmonary diseases beyond pulmonary embolism. *Semin Nucl Med* 2019; **49**: 4–10.
- Johns CS, Swift AJ, Hughes PJC, Ohno Y, Schiebler M, Wild JM. Pulmonary MR angiography and perfusion imaging—a review of methods and applications. *Eur J Radiol* 2017; **86**: 361–70.
- Deffebach ME, Charan NB, Lakshminarayan S, Butler J. The bronchial circulation: small, but a vital attribute of the lung. *Am Rev Respir Dis* 1987; **135**: 463–81.
- Frazier AA, Galvin JR, Franks TJ, Rosado-de-Christenson ML. From the archives of the AFIP: Pulmonary vasculature: hypertension and infarction. *Radiographics* 2000; **20**: 491–524.
- Tsao M-S, Schraufnagel D, Wang N-S. Pathogenesis of pulmonary infarction. *Am J Med* 1982; **72**: 599–606.
- Kauczor H-U, Schwickert HC, Mayer E, Schweden F, Schild HH, Thelen M. Spiral CT of bronchial arteries in chronic thromboembolism. *J Comput Assist Tomogr* 1994; **18**: 855–61.
- Meaney JF, Weg JG, Chenevert TL, Stafford-Johnson D, Hamilton BH, Prince MR. Diagnosis of pulmonary embolism with magnetic resonance angiography. *N Engl J Med* 1997; **336**: 1422–27.
- Dalen JE, Haffajee CI, Alpert JS, Howe JP 3rd, Ockene IS, Paraskos JA. Pulmonary embolism, pulmonary hemorrhage and pulmonary infarction. *N Engl J Med* 1977; **296**: 1431–35.
- Schraufnagel DE, Tsao M-S, Yao Y, Wang N-S. Factors associated with pulmonary infarction: a discriminant analysis study. *Am J Clin Pathol* 1985; **84**: 15–18.
- Schaefer I-M, Padera RF, Solomon IH, et al. In situ detection of SARS-CoV-2 in lungs and airways of patients with COVID-19. *Mod Pathol* 2020; **33**: 2104–14.



- 47 Pasha AK, Rabinstein A, McBane RD. Pulmonary venous thrombosis in a patient with COVID-19 infection. *J Thromb Thrombolysis* 2021; **51**: 985–88.
- 48 van Kruijsdijk RC, de Jong PA, Abrahams AC. Pulmonary vein thrombosis in COVID-19. *BMJ Case Rep* 2020; **13**: e239986.
- 49 Andersson MI, Arancibia-Carcamo CV, Auckland K, et al. SARS-CoV-2 RNA detected in blood products from patients with COVID-19 is not associated with infectious virus. *Wellcome Open Res* 2020; **5**: 181.
- 50 Hogan CA, Stevens BA, Sahoo MK, et al. High frequency of SARS-CoV-2 RNAemia and association with severe disease. *Clin Infect Dis* 2020; published online Sep 23. <https://doi.org/10.1093/cid/ciaa1054>.
- 51 Berastegui-Cabrera J, Salto-Alejandre S, Valerio M, et al. SARS-CoV-2 RNAemia is associated with severe chronic underlying diseases but not with nasopharyngeal viral load. *J Infect* 2021; **82**: e38–41.
- 52 Bermejo-Martin JF, González-Rivera M, Almansa R, et al. Viral RNA load in plasma is associated with critical illness and a dysregulated host response in COVID-19. *Crit Care* 2020; **24**: 691.
- 53 Chen X, Zhao B, Qu Y, et al. Detectable serum SARS-CoV-2 viral load (RNAemia) is closely correlated with drastically elevated interleukin 6 (IL-6) level in critically ill COVID-19 patients. *Clin Infect Dis* 2020; **71**: 1937–42.
- 54 Shi F, Wu T, Zhu X, et al. Association of viral load with serum biomarkers among COVID-19 cases. *Virology* 2020; **546**: 122–26.
- 55 McGonagle D, Plein S, O'Donnell JS, Sharif K, Bridgewood C. Increased cardiovascular mortality in African Americans with COVID-19. *Lancet Respir Med* 2020; **8**: 649–51.
- 56 Wölfel R, Corman VM, Guggemos W, et al. Virological assessment of hospitalized patients with COVID-2019. *Nature* 2020; **581**: 465–69.
- 57 Goldsmith CS, Miller SE, Martines RB, Bullock HA, Zaki SR. Electron microscopy of SARS-CoV-2: a challenging task. *Lancet* 2020; **395**: e99.
- 58 McCracken IR, Saginc G, He L, et al. Lack of evidence of ACE2 expression and replicative infection by SARS-CoV-2 in human endothelial cells. *Circulation* 2021; **143**: 865–68.
- 59 Ahmetaj-Shala B, Peacock TP, Baillon L, et al. Resistance of endothelial cells to SARS-CoV-2 infection in vitro. *bioRxiv* 2020; published online Nov 9. <https://doi.org/10.1101/2020.11.08.372581> (preprint).
- 60 Stahl K, Bräsen JH, Hoeper MM, David S. Absence of SARS-CoV-2 RNA in COVID-19-associated intestinal endothelitis. *Intensive Care Med* 2021; **47**: 359–60.
- 61 Arabi YM, Balkhy HH, Hayden FG, et al. Middle East respiratory syndrome. *N Engl J Med* 2017; **376**: 584–94.
- 62 Hatesuer B, Bertram S, Mehnert N, et al. Tmprss2 is essential for influenza H1N1 virus pathogenesis in mice. *PLoS Pathog* 2013; **9**: e1003774.
- 63 Nicolai L, Leunig A, Brambs S, et al. Immunothrombotic dysregulation in COVID-19 pneumonia is associated with respiratory failure and coagulopathy. *Circulation* 2020; **142**: 1176–89.

© 2021 Published by Elsevier Ltd. All rights reserved