

Expression of the RNase III enzyme DROSHA is reduced during progression of human cutaneous melanoma

Seyed Mehdi Jafarnejad¹, Cecilia Sjoestroem¹, Magdalena Martinka², and Gang Li¹

¹Department of Dermatology and Skin Science, Vancouver Coastal Health Research Institute, University of British Columbia, Vancouver, British Columbia, Canada

²Department of Pathology, Vancouver Coastal Health Research Institute, University of British Columbia, Vancouver, British Columbia, Canada

Abstract

Aberrant expression of miRNAs and their biogenesis factors has been frequently observed in different types of cancer. We recently reported that expression of DICER1 is reduced in metastatic melanoma. Nevertheless, so far very little is known about the expression pattern of other miRNA biogenesis factors in this type of malignancy. Here, we investigated the expression pattern of DROSHA in a large set of melanocytic lesions by tissue microarray and immunohistochemistry (n = 409). We found that nuclear expression of DROSHA is markedly reduced in the early stages of melanoma progression ($P = 0.0001$) and is inversely correlated with melanoma thickness ($P = 0.0001$), AJCC stages ($P = 0.0001$), and ulceration status ($P = 0.002$). We also confirmed the reduced expression of nuclear DROSHA by a second specific antibody raised against a different region of the DROSHA protein. In addition, we observed that the reduced nuclear expression of DROSHA during melanoma progression is accompanied by an increased cytoplasmic expression of this protein ($P = 0.0001$). Finally, we found that expression pattern of DROSHA varies from that of DICER1 and concomitant loss of expression of both DICER1 and DROSHA confers the worse outcome for melanoma patients. Our results demonstrate a reduced nuclear expression of DROSHA which further highlights a perturbed miRNA biogenesis pathway in melanoma. In addition, the aberrant subcellular localization of DROSHA indicates possible deregulation in the mechanisms responsible for its proper localization in the nucleus.

Keywords

Melanoma; DROSHA; TMA; Tumor progression

Users may view, print, copy, and download text and data-mine the content in such documents, for the purposes of academic research, subject always to the full Conditions of use:http://www.nature.com/authors/editorial_policies/license.html#terms

Correspondence: Dr G Li, Jack Bell Research Centre, 2660 Oak Street, Vancouver, BC V6H 3Z6 Canada. Phone: 1-604-875-5826; Fax: 1-604-875-4497. gangli@mail.ubc.ca.

Disclosure/conflict of interest

The authors state no conflict of interest.

Introduction

MicroRNAs (miRNAs) are a large family of single-stranded noncoding RNAs of approximately 22-nucleotides involved in posttranscriptional regulation of gene expression. Human genome produces more than a thousand miRNAs, each of which act via the RNA silencing pathway to regulate stability, degradation or rate of translation of the target mRNAs.¹ With some exceptions, miRNAs are transcribed by RNA polymerase II from independent genes or as parts of introns of protein-coding genes in the form of pri-miRNAs.² The pri-miRNAs are processed within the nucleus by microprocessor complex, core components of which are the RNase III enzyme DROSHA and the DiGeorge syndrome critical region gene 8 (DGCR8) proteins. The product of the microprocessor complex are ~70-nucleotide pre-miRNAs which are subsequently transported to the cytoplasm by Ran GTPase-Exportin-5 complex.¹ Upon arrival in cytoplasm, DICER1 further processes the pre-miRNAs to ~22-nt duplexes. One strand of each duplex, representing a mature miRNA, is then incorporated into the RNA-induced silencing complex (RISC) which then causes translational repression or deadenylation and degradation of the target mRNAs identified by base-pairing to the core sequences of the corresponding miRNAs.¹

The known miRNAs' targets in human transcriptome are involved in a wide range of cellular functions such as development,³ proliferation and apoptosis⁴ and angiogenesis.⁵ Therefore, dysregulation of miRNA biogenesis, hence alteration in miRNA expression levels, can lead to variety of diseases, including cancer. Widespread aberrant expression of miRNAs has been frequently observed in cancers.⁶⁻⁸ These widespread changes in expression pattern of miRNAs could be due to chromosomal abnormalities⁹ or epigenetic effects and aberrant transcription.¹⁰⁻¹¹ However, the aberrant expression or function of miRNA biogenesis factors could also potentially alter the miRNAome of the cells; therefore contribute to the tumorigenesis process. Accordingly, expression of several miRNA biogenesis factors such as DICER1 and Argonautes have been observed to be deregulated in cancers.¹²⁻¹⁴

Widespread deregulated expression of miRNAs in melanoma has been observed in different studies¹⁵⁻¹⁶ accompanied by revelation of involvement of several individual miRNAs in regulation of different features of melanoma such as invasion, proliferation and evasion of apoptosis.¹⁶⁻¹⁸ We recently revealed that expression of DICER1 is reduced in metastatic melanoma which was inversely correlated with survival of melanoma patients.¹⁹ Nevertheless, so far very little is known about the expression pattern of other miRNA biogenesis factors in melanoma. Several lines of evidence indicate that expression of DROSHA is deregulated in malignancies and may influence clinical outcomes.^{13, 20-22} In this study, to identify the expression pattern of DROSHA in melanoma we investigated the expression of its protein in a large set of melanocytic lesions by immunohistochemistry.

Materials and Methods

Construction of TMA

All specimens were obtained from the 1990 to 1998 archives of the Department of Pathology, Vancouver General Hospital. The use of human skin tissues in this study was approved by the Clinical Research Ethics Board of The University of British Columbia. The

most representative tumor area from each sample was carefully selected by a certified dermatopathologist and marked on the H&E-stained slide. The TMAs were assembled using a tissue-array instrument (Beecher Instruments, Silver Spring, MD). Duplicate 0.6-mm thick formalin-fixed paraffin-embedded tissue cores were taken from each biopsy specimen and spotted on five high-density TMA blocks. Four- μ m sections were cut with a Leica microtome and transferred to adhesive coated slides. Tissues from 29 normal nevi, 43 dysplastic nevi, 226 primary melanomas, and 111 metastatic melanomas were used in construction of the tissue microarray. In this study we also used a smaller TMA construct (two slides) with 48 dysplastic nevi, 86 primary melanomas, and 49 metastatic melanomas.

Immunohistochemistry

TMA slides or single tumor slides were dewaxed at 55°C for 30 minutes and three consequent washes with xylene. Tissues were rehydrated by a series of washes in 100%, 95%, and 80% ethanol, followed by two washes in distilled water. Antigen retrieval was done by heating the samples at 95°C for 30 minutes in 10 mmol/L sodium citrate (pH 6.0). After inactivating the endogenous peroxidase by incubating in 3% H₂O₂ for 30 minutes and blocking with universal blocking serum for 30 minutes, slides were incubated with polyclonal rabbit anti-DROSHA antibodies (1:50 dilution, ab12286 Abcam, Cambridge, MA; or 1:50; sc-33778 Santa Cruz Biotechnology, Santa Cruz, CA) at 4°C overnight. The slides were then incubated with biotin-labeled secondary antibody and streptavidin-peroxidase for 30 minutes each, followed by developing with diaminobenzidine substrate kit (Vector Laboratories, Burlington, Ontario, Canada) and counterstained with hematoxylin.

Evaluation of immunostaining

The evaluation of DROSHA expression was made blindly by two independent observers (including one dermatopathologist) simultaneously. The nuclear or cytoplasmic DROSHA staining was scored into four grades according to the following staining intensities: 0, 1+, 2+, and 3+. Percentages of DROSHA-positive cells were also scored into five categories: 0 (0%), 1 (1–25%), 2 (26–50%), 3 (51–75%), and 4 (76–100%). The immunoreactive score, which is calculated by multiplying the scores of staining intensity and the percentage of positive cells, was used as the final staining score.

Statistical analyses

The Kruskal-Wallis test was applied to compare the DROSHA staining between normal nevi, dysplastic nevi, primary melanomas and metastatic melanomas using the GraphPad prism5 software. Other statistical analyses were performed with the SPSS 11.5 software. The correlations between DROSHA expression and clinicopathologic variables, including AJCC stages, age, gender, tumor thickness, location, and ulceration were analyzed by χ^2 test. Spearman test was used to analyse the correlation between nuclear DROSHA and cytoplasmic DICER1 expression and correlation between nuclear and cytoplasmic DROSHA expression. In all cases a *P* value of less than 0.05 was considered significant.

Results

Reduced nuclear DROSHA staining correlates with melanoma progression

We used a polyclonal rabbit antibody raised against the N-terminal (residues 1–100) of human DROSHA protein to investigate its expression pattern in 409 melanocytic lesions (29 normal nevi, 43 dysplastic nevi, 226 primary melanomas, and 111 metastatic melanomas). We observed a predominant nuclear DROSHA staining in different samples (Figure 1a). We also detected some cytoplasmic signal with this antibody in melanocytic lesions in all stages. A significant difference in nuclear DROSHA staining was observed between different stages of melanoma. Kruskal-Wallis test revealed a clear reduction in the expression of nuclear DROSHA during melanoma progression ($P=0.0001$; Figure 1b). We found significant reduction in expression of nuclear DROSHA from normal nevi to dysplastic nevi ($P=0.002$) and from dysplastic nevi to primary melanomas ($P=0.0001$) but not between primary melanomas and metastatic melanomas ($P=0.052$). Similarly, when we divided the samples from each stage into two groups based on expression of nuclear DROSHA, we observed an increase in percentage of samples with no nuclear DROSHA staining during melanoma progression ($P=0.0001$; Figure 1c). Accordingly, while 82.7% of normal nevi and 62.7% of dysplastic nevi had positive nuclear staining for DROSHA, only 26.1% of primary melanomas and 17.1% of metastatic melanomas stained positive for nuclear DROSHA.

Inverse correlation between nuclear DROSHA staining and tumor thickness, AJCC staging and ulceration status

To assess whether reduced nuclear DROSHA staining correlates with clinicopathologic variables of the patients, we examined the expression pattern of nuclear DROSHA in 226 primary melanoma samples (Table 1). Although DROSHA staining did not have a significant correlation with patients' age or sex, location of tumor and lymphocytic response, it showed a significant inverse correlation with tumor thickness (Breslow's depth of invasion). Accordingly, percentage of samples with positive staining for nuclear DROSHA reduced from 41.0% in tumors ≤ 1 mm thick to 18.2% in tumors thicker than 1 mm ($P=0.0001$, χ^2 test; Figure 2a). We also observed an inverse correlation between expression of nuclear DROSHA and ulceration status of the melanoma patients. While 30.6% of the samples without ulceration stained positive for nuclear DROSHA, only 6.9% of those with ulceration had positive nuclear DROSHA staining ($P=0.002$, χ^2 test; Table 1). In addition, when compared the nuclear DROSHA staining between different subtypes of melanoma, we found that lentigo maligna and superficial spreading subtypes express less DROSHA than other subtypes ($P=0.016$, Table 1).

Importantly, our data also demonstrated that nuclear DROSHA expression is inversely correlated with American Joint Committee on Cancer (AJCC) stages of melanoma ($P=0.0001$, χ^2 test; Figure 2b). We found that the main and only significant difference in nuclear DROSHA staining exist between stage I and II ($P=0.0001$, χ^2 test) but not the other stages ($P>0.05$, χ^2 test).

Subcellular compartment shift of DROSHA expression to the cytoplasm during melanoma progression

As mentioned earlier, in addition to the nuclear staining for DROSHA we also observed cytoplasmic staining for this protein in all stages of melanocytic lesion. To investigate if the cytoplasmic nuclear staining has any significant in melanoma progression, we evaluated DROSHA staining in cytoplasm. Kruskal-Wallis test revealed a marked increase in cytoplasmic expression of DROSHA during melanoma progression ($P=0.026$; Figure 3a). Significant difference for the cytoplasmic DROSHA staining was observed between dysplastic nevi and primary melanomas ($P=0.016$), but not between normal nevi and dysplastic nevi or between primary melanomas and metastatic melanomas ($P>0.05$). Furthermore, to examine whether the reduced nuclear DROSHA staining is due to a subcellular shift we divided the samples in each stage of melanoma progression into four categories based on their nuclear and cytoplasmic DROSHA expression profile: 1) negative nuclei and cytoplasm; 2) negative nuclei but positive cytoplasm; 3) positive nuclei but negative cytoplasm; 4) positive nuclei and cytoplasm. Interestingly, we observed a considerable shift in DROSHA expression from nuclei to cytoplasm during melanoma progression ($P=0.0001$, χ^2 test; Figure 3b). Accordingly, category 2 which represents samples with negative nuclear but positive cytoplasmic staining for DROSHA increased from 10.3% in normal nevi to 30.2% in dysplastic nevi, 54.2% in primary melanomas and 56.8% in metastatic melanomas, whereas category 3 which represents samples with positive nuclear but negative cytoplasmic staining for DROSHA decreased from 34.5% in normal nevi to 20.9% in dysplastic nevi, and further to 1.3% in primary melanomas and 0.9% in metastatic melanomas.

Validation of DROSHA staining with a second antibody

To further validate our observation that expression of nuclear DROSHA is reduced in melanoma we used a second rabbit polyclonal antibody against the C-terminal (amino acids 1071–1370) to probe for expression of DROSHA in a smaller TMA construct, containing 48 dysplastic nevi, 86 primary melanomas, and 49 metastatic melanomas (Figure 4). We observed an expression pattern of nuclear DROSHA very similar to the first antibody by using this antibody (Figure 4a). Indeed, Kruskal-Wallis test revealed a reduced expression of nuclear DROSHA during melanoma progression ($P=0.0001$, Figure 4b). Furthermore, when we divided the samples from each stage into two groups (positive and negative) based on expression of nuclear DROSHA, we observed an increase in percentage of samples with no nuclear DROSHA staining during melanoma progression ($P=0.001$, χ^2 test; Figure 4c). Accordingly, while 56.2% of dysplastic nevi had positive nuclear staining for DROSHA, only 20.9% of primary melanomas and 12.2% of metastatic melanomas stained positive for nuclear DROSHA.

Concomitant loss of DROSHA and DICER1 expression renders worse prognosis for melanoma progression

To evaluate whether the reduced nuclear DROSHA staining in human melanomas correlates with patient survival, we constructed Kaplan-Meier survival curves using overall or disease-specific 5-year survival to compare biopsies with positive nuclear DROSHA staining to

those with negative nuclear DROSHA staining. Our results revealed that despite a trend toward higher survival rate in samples with positive nuclear DROSHA signals, this correlation is not significant for either overall ($P=0.073$) or disease-specific ($P=0.097$) 5-year survival of the patients (data not shown). Our analysis with the second anti-DROSHA antibody also produced similar non-significant results (data not shown).

We previously reported that expression of cytoplasmic DICER1 is reduced during melanoma progression towards metastasis.¹⁹ Since DROSHA and DICER1 are two main players in the miRNA biogenesis pathway, we investigated the potential correlation in the expression of these two proteins in melanocytic lesions and the correlation between concomitant expression of these two factors and melanoma patients' survival. We found that despite reduced expression of cytoplasmic DICER1 and Nuclear DROSHA during melanoma progression, there is no significant correlation between their expression patterns in the single sample level (data not shown). However, when we divided the samples into three groups; positive DROSHA -positive DICER1 (category 1; $n=49$), positive DICER1-negative DROSHA or negative DICER1-positive DROSHA (category 2; $n=192$) and negative DICER1-negative DROSHA (category 3; $n=33$), we found a significant correlation between their concomitant expression and patient survival ($P=0.019$ for overall and 0.001 for disease-specific survival; Figure 5a and b). We observed that samples in category 3 represented the worst survival outcome (36.7% for both overall and disease-specific survival; Figure 5a and b), whereas category 1 represented the best outcome (65.3% for overall and 75.5% for disease-specific survival; Figure 5a and b). Interestingly, survival rate for samples in category 2 was between the other two categories (54.7% for overall and 59.4% for disease-specific survival; Figure 5a and b).

Discussion

Expressions pattern of DROSHA has been investigated in regard to tumor progression and survival prediction in a number of malignancies. However, to our knowledge, this is the first study to investigate the DROSHA protein expressions in human cutaneous melanoma. Using two different antibodies raised against different regions of the DROSHA protein, we observed a marked downregulation of nuclear DROSHA expression during melanoma progression (Figure 1 and 4). We also observed an inverse correlation between nuclear expression of DROSHA and tumor thickness, AJCC stage, and ulceration status (Figure 2 and Table 1). These data indicate a possible tumor suppressor function for DROSHA in melanoma.

Interestingly, we also observed an increased cytoplasmic staining for DROSHA along with the reduced nuclear DROSHA expression during melanoma progression (Figure 3). This observation suggests that the nuclear-to-cytoplasm translocation of DROSHA protein may be a relevant event in melanomagenesis. In esophageal cancer samples, DROSHA was shown by immunohistochemistry to be strongly expressed in both nuclei and cytoplasm.²³ Cytoplasmic localization of DROSHA was also recently reported in colorectal carcinoma cells by immunofluorescence analyses.²⁴ Similarly, cytoplasmic DROSHA expression was detected in MCF-7 breast cancer cell line.²⁵

It should be noted that alternatively spliced transcripts, encoding C-terminally truncated DROSHA proteins lacking part of the RIIIDb and the entire dsRBD have been detected in human melanoma cell lines. Proteins generated from these alternative splice variants fail to bind to DGCR8 and form the microprocessor complex.²⁶ These splice variants are deficient in pri-miRNA processing. However, these aberrant transcripts in melanoma cells do not hamper miRNA biogenesis process.²⁶ In our study, it is possible that these splice isoforms contribute to the signals detected by the antibody that targets the N-terminal of DROSHA protein; nevertheless, we believe this possibility is remote since the second antibody that targets the C-terminal of the DROSHA protein (therefore, unable to detect these isoforms) shows a pattern of DROSHA expression in melanocytic lesions very similar to the other antibody.

Previous reports demonstrated various degrees of correlation between DROSHA expression and survival^{13, 272820242923} Nevertheless, despite a clear trend, our Kaplan–Meier analysis did not reveal a significant correlation between nuclear DROSHA expression and patients' overall or disease-specific survival. This lack of significant correlation may be explained by the notion that reduction of nuclear DROSHA expression mainly happens at earlier stages of melanomagenesis (from normal nevi to dysplastic nevi and further from dysplastic nevi to primary melanomas; Figure 1 and 4).

A previous report on breast cancers showed that DROSHA and DICER1 were concurrently down-regulated in 15% of cases.²⁹ Down-regulation of DROSHA in endometrial cancer was also shown to be significantly correlated with decreased expression of DICER1.³⁰ Nonetheless, we did not observe any correlation between nuclear DROSHA and cytoplasmic DICER1 expression in melanocytic lesions. In addition, when we compared the expression pattern of nuclear DROSHA with that of cytoplasmic DICER1 during melanoma progression,¹⁹ we observed that while the expression of DICER1 reduces mainly in the latest stage of melanoma progression (metastatic melanoma), nuclear DROSHA expression is progressively reduced in almost all stages of melanoma progression. These data indicate that expression pattern of these two factors differ in different stages of melanoma progression, suggesting the existence of distinct mechanisms responsible for differential regulation of their expression. However, despite this lack of correlation at the expression level, our survival analysis revealed that concomitant expression of these two factors confers the best survival outcome for the patients (Figure 4). In line with our observation in melanoma, studies in ovarian cancer showed that cases with both high DICER1 expression and high DROSHA expression were associated with increased survival.¹³ Altogether, our data suggest that integrity of the miRNA biogenesis pathway is perturbed in a considerable subset of melanomas and that those cases whose expression pattern of miRNA biogenesis factors (and probably expression pattern of miRNAs) resembles that of normal tissues represent a better rate of survival.

Loss of expression of DROSHA and DICER1 has been shown before to cause different phenotypes. For instance, it was reported that DICER1 knockdown significantly decreases migration of endothelial cells, whereas DROSHA knockdown has no effect.³¹ Similarly, silencing of DICER1 but not DROSHA reduces angiogenesis *in vivo*.³¹ Also, Chong et al. revealed that in early-stage thymocytes, deficiency in DROSHA or DICER1 does not always

result in identical phenotypes and using the mouse embryonic fibroblasts they showed that loss of DROSHA expression results in a pattern of gene expression different than loss of DICER1.³² Interestingly, they showed that DROSHA also recognizes and directly cleaves many mRNAs with secondary stem-loop structures. In addition, a subset of miRNAs was found to be generated by a DICER1-dependent but DROSHA -independent mechanism, explaining the distinct and non-overlapping phenotypes caused by loss of DROSHA and DICER1.³² Reduced DROSHA, but not DICER1, expression in human mesenchymal stem cells was demonstrated to significantly reduce proliferation rate.³³ In addition, unlike DICER1 knockdown, DROSHA knockdown human mesenchymal stem cells contained an increased number of G1 phase cells, with a reduced level of cells in S phase, accompanied by decreased pRB, 28S and 18S rRNA expression and increased p16 and p15 (two key regulators of the G1/S phase transition) expression, indicating that DROSHA modifies human mesenchymal stem cells proliferation through a miRNA independent mechanism.³³ Our data demonstrating further reduction in survival rate of the melanoma cases with negative DICER1-negative and DROSHA expression compared with that of the cases with loss of either DICER1 or DROSHA (Figure 5) also indicate the possible existence of at least some non-overlapping functions of these two factors. However, beside its direct role in biogenesis of miRNAs, so far very little is known of putative functions of DROSHA in melanocytic cells. Future studies will delineate these functions of DROSHA and its possible contribution to suppression of melanomagenesis.

In conclusion, our data revealed a decreased nuclear expression of DROSHA during melanoma progression along with subcellular compartment shift of its expression toward the cytoplasm. We observed that expression of DROSHA inversely correlates with tumor thickness, AJCC stage and ulceration status. In addition, we revealed that concurrent loss of expression of DROSHA and DICER1 confers an adverse affect on melanoma patient survival, worse than singular loss of each of these factors. Our data suggest a possible tumor suppressor function for DROSHA in melanoma and highlights the requirement for future studies on its role in this type of malignancy and its possible miRNA-independent functions.

Acknowledgments

We would like to thank Dr. Gholamreza Safaee Ardekani, Dr. Ladan Fazli and Scot Kwong for technical assistance and Drs. Michael Cox, Aziz Ghahary and Vincent Duronio for helpful discussions. This work is funded by grants from the Canadian Institutes of Health Research (MOP-93810, MOP-110974 and CCI-117958) and Canadian Dermatology Foundation to G.L. S.M.J. is a recipient of Sandy Kyo-Hyun Park Scholarship in Cancer Research, University of British Columbia Graduate Fellowship and Canadian Institutes of Health Research - Skin Research Training Centre Trainee Awards.

References

1. Bushati N, Cohen SM. microRNA functions. *Annu Rev Cell Dev Biol.* 2007; 23:175–205. [PubMed: 17506695]
2. Krol J, Loedige I, Filipowicz W. The widespread regulation of microRNA biogenesis, function and decay. *Nat Rev Genet.* 2010; 11:597–610. [PubMed: 20661255]
3. Carrington JC, Ambros V. Role of microRNAs in plant and animal development. *Science.* 2003; 301:336–8. [PubMed: 12869753]

4. Cheng AM, Byrom MW, Shelton J, Ford LP. Antisense inhibition of human miRNAs and indications for an involvement of miRNA in cell growth and apoptosis. *Nucleic Acids Res.* 2005; 33:1290–7. [PubMed: 15741182]
5. Chen Y, Gorski DH. Regulation of angiogenesis through a microRNA (miR-130a) that down-regulates antiangiogenic homeobox genes GAX and HOXA5. *Blood.* 2008; 111:1217–26. [PubMed: 17957028]
6. Wilting SM, Snijders PJ, Verlaet W, et al. Altered microRNA expression associated with chromosomal changes contributes to cervical carcinogenesis. *Oncogene.* 2012 (in press).
7. Landi MT, Zhao Y, Rotunno M, et al. MicroRNA expression differentiates histology and predicts survival of lung cancer. *Clin Cancer Res.* 2010; 16:430–41. [PubMed: 20068076]
8. Ozen M, Creighton CJ, Ozdemir M, Ittmann M. Widespread deregulation of microRNA expression in human prostate cancer. *Oncogene.* 2008; 27:1788–93. [PubMed: 17891175]
9. Png KJ, Yoshida M, Zhang XHF, et al. MicroRNA-335 inhibits tumor reinitiation and is silenced through genetic and epigenetic mechanisms in human breast cancer. *Gene Dev.* 2011; 25:226–31. [PubMed: 21289068]
10. Baer C, Claus R, Frenzel LP, et al. Extensive promoter hypermethylation and hypomethylation is associated with aberrant microRNA expression in chronic lymphocytic leukemia. *Cancer Res.* 2012; 72:3775–85. [PubMed: 22710432]
11. Kuchen S, Resch W, Yamane A, et al. Regulation of MicroRNA Expression and Abundance during Lymphopoiesis. *Immunity.* 2010; 32:828–39. [PubMed: 20605486]
12. Faggad A, Kasajima A, Weichert W, et al. Down-regulation of the microRNA processing enzyme Dicer is a prognostic factor in human colorectal cancer. *Histopathology.* 2012 (in press).
13. Merritt WM, Lin YG, Han LY, et al. Dicer, Drosha, and outcomes in patients with ovarian cancer. *N Engl J Med.* 2008; 359:2641–50. [PubMed: 19092150]
14. Zhou YM, Chen LJ, Barlogie B, et al. High-risk myeloma is associated with global elevation of miRNAs and overexpression of EIF2C2/AGO2. *P Natl Acad Sci USA.* 2010; 107:7904–9.
15. Caramuta S, Egyhazi S, Rodolfo M, et al. MicroRNA expression profiles associated with mutational status and survival in malignant melanoma. *J Invest Dermatol.* 2010; 130:2062–70. [PubMed: 20357817]
16. Xu Y, Brenn T, Brown ER, Doherty V, Melton DW. Differential expression of microRNAs during melanoma progression: miR-200c, miR-205 and miR-211 are downregulated in melanoma and act as tumour suppressors. *Br J Cancer.* 2012; 106:553–61. [PubMed: 22223089]
17. Schultz J, Lorenz P, Gross G, Ibrahim S, Kunz M. MicroRNA let-7b targets important cell cycle molecules in malignant melanoma cells and interferes with anchorage-independent growth. *Cell Res.* 2008; 18:549–57. [PubMed: 18379589]
18. Felicetti F, Errico MC, Bottero L, et al. The promyelocytic leukemia zinc finger-microRNA-221/-222 pathway controls melanoma progression through multiple oncogenic mechanisms. *Cancer Res.* 2008; 68:2745–54. [PubMed: 18417445]
19. Jafarnejad SM, Ardekani GS, Ghaffari M, Martinka M, Li G. Sox4-mediated Dicer expression is critical for suppression of melanoma cell invasion. *Oncogene.* 2012 (in press).
20. Guo XF, Liao QJ, Chen P, et al. The microRNA-processing enzymes: Drosha and Dicer can predict prognosis of nasopharyngeal carcinoma. *J Cancer Res Clin.* 2012; 138:49–56.
21. Papachristou DJ, Sklirou E, Corradi D, et al. Immunohistochemical analysis of the endoribonucleases Drosha, Dicer and Ago2 in smooth muscle tumours of soft tissues. *Histopathology.* 2012; 60:E28–36. [PubMed: 22394132]
22. Shu GS, Yang ZL, Liu DC. Immunohistochemical study of Dicer and Drosha expression in the benign and malignant lesions of gallbladder and their clinicopathological significances. *Pathol Res Pract.* 2012; 208:392–7. [PubMed: 22658478]
23. Sugito N, Ishiguro H, Kuwabara Y, et al. RNASEN regulates cell proliferation and affects survival in esophageal cancer patients. *Clin Cancer Res.* 2006; 12:7322–8. [PubMed: 17121874]
24. Papachristou DJ, Korpetinou A, Giannopoulou E, et al. Expression of the ribonucleases Drosha, Dicer, and Ago2 in colorectal carcinomas. *Virchows Arch.* 2011; 459:431–40. [PubMed: 21769619]

25. Passon N, Gerometta A, Puppini C, et al. Expression of Dicer and Drosha in triple-negative breast cancer. *J Clin Pathol.* 2012; 65:320–6. [PubMed: 22259182]
26. Grund SE, Polycarpou-Schwarz M, Luo C, Eichmuller SB, Diederichs S. Rare Drosha splice variants are deficient in microRNA processing but do not affect general microRNA expression in cancer cells. *Neoplasia.* 2012; 14:238–48. [PubMed: 22496623]
27. Shu GS, Yang ZL, Liu DC. Immunohistochemical study of Dicer and Drosha expression in the benign and malignant lesions of gallbladder and their clinicopathological significances. *Pathol Res Pract.* 2012; 208:392–7. [PubMed: 22658478]
28. Vaksman O, Hetland TE, Trope CG, Reich R, Davidson B. Argonaute, Dicer, and Drosha are up-regulated along tumor progression in serous ovarian carcinoma. *Hum Pathol.* 2012; 43:2062–9. [PubMed: 22647351]
29. Dedes KJ, Natrajan R, Lambros MB, et al. Down-regulation of the miRNA master regulators Drosha and Dicer is associated with specific subgroups of breast cancer. *Eur J Cancer.* 2011; 47:138–50. [PubMed: 20832293]
30. Torres A, Torres K, Paszkowski T, et al. Major regulators of microRNAs biogenesis Dicer and Drosha are down-regulated in endometrial cancer. *Tumour Biol.* 2011; 32:769–76. [PubMed: 21559780]
31. Kuehbacher A, Urbich C, Zeiher AM, Dimmeler S. Role of dicer and Drosha for endothelial MicroRNA expression and angiogenesis. *Circ Res.* 2007; 101:59–68. [PubMed: 17540974]
32. Chong MM, Zhang G, Cheloufi S, et al. Canonical and alternate functions of the microRNA biogenesis machinery. *Genes Dev.* 2010; 24:1951–60. [PubMed: 20713509]
33. Oskowitz AZ, Penforis P, Tucker A, Prockop DJ, Pochampally R. Drosha regulates hMSCs cell cycle progression through a miRNA independent mechanism. *Int J Biochem Cell B.* 2011; 43:1563–72.

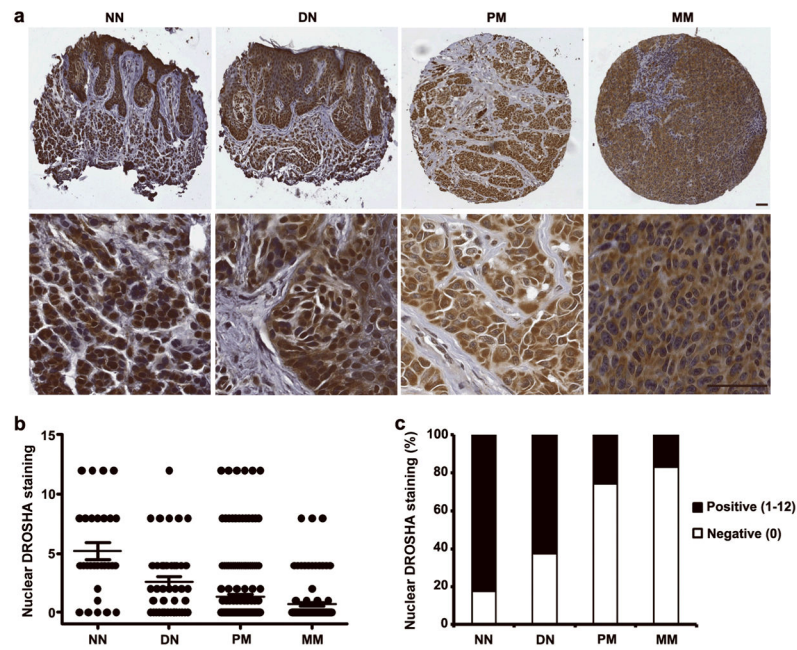


Figure 1. Reduced expression of nuclear Drosha correlates with melanoma progression. (a) Representative images of normal nevi (NN) and dysplastic nevi (DN) with strong nuclear Drosha staining, primary melanoma (PM) with weak staining, and metastatic melanoma (MM) with negative nuclear Drosha staining. Scale bar = 50 μ m. (b) Kruskal-Wallis test for differences in nuclear Drosha staining among NN, DN, PM, and MM. Median is depicted as a horizontal line in each group ($P = 0.0001$). (c) Chi-square test for differences in nuclear Drosha staining in NN, DN, PM, and MM. Significant difference was found between DN and PM ($P = 0.0001$) but not NN and DN ($P = 0.068$) or PM and MM ($P = 0.066$).

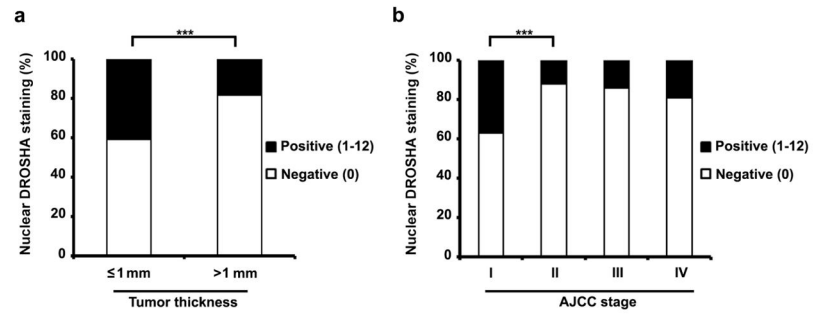


Figure 2. Nuclear Drosha expression is negatively correlated with (a) tumor thickness ($P=0.0001$, χ^2 test), and (b) AJCC stage of melanoma ($P=0.0001$, χ^2 test).

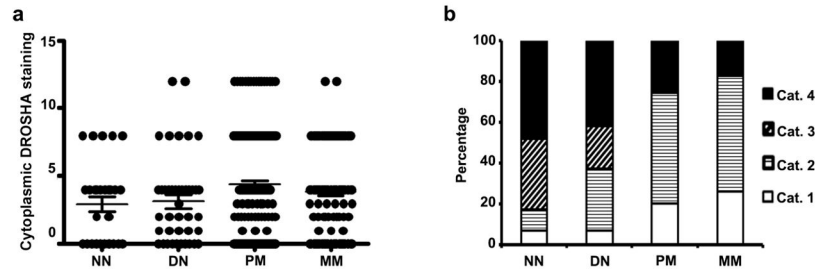


Figure 3.

Cytoplasmic expression of Drosha is increased during melanoma progression. **(a)** Kruskal-Wallis test for differences in cytoplasmic expression of Drosha among NN, DN, PM, and MM ($P=0.026$). Significant difference was found between dysplastic nevi and primary melanomas ($P=0.016$), but not between normal nevi and dysplastic nevi or between primary melanomas and metastatic melanomas ($P>0.05$). **(b)** Combined analysis of nuclear and cytoplasmic Drosha staining in NN, DN, PM, and MM. Each sample was categorized based on nuclear and cytoplasmic Drosha expression as following: 1) negative nuclei and negative cytoplasm; 2) negative nuclei but positive cytoplasm; 3) positive nuclei but negative cytoplasm; and 4) positive nuclei and positive cytoplasm.

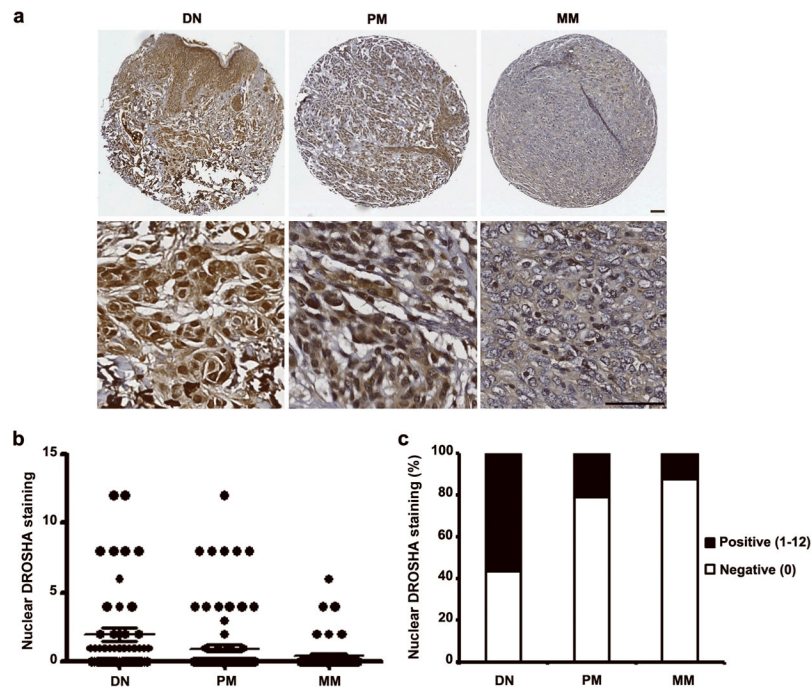


Figure 4. Tissue microarray using a second specific antibody raised against the C-terminal region of the human Droscha protein confirms the reduced nuclear Droscha expression during melanoma progression. (a) Representative images of dysplastic nevi (DN) with strong nuclear Droscha staining, primary melanoma (PM) with weak and metastatic melanoma (MM) with negative nuclear Droscha staining. (b) Kruskal-Wallis test for differences in nuclear Droscha staining among DN, PM, and MM. The median is depicted as a horizontal line in each group ($P = 0.0001$). Significant difference was found between DN and PM ($P = 0.001$, Mann-Whitney test) but not PM and MM ($P = 0.36$, Mann-Whitney test). (c) Chi-square test for differences in nuclear Droscha staining in DN, PM, and MM. Significant difference was found between DN and PM ($P = 0.001$) but not PM and MM ($P = 0.204$).

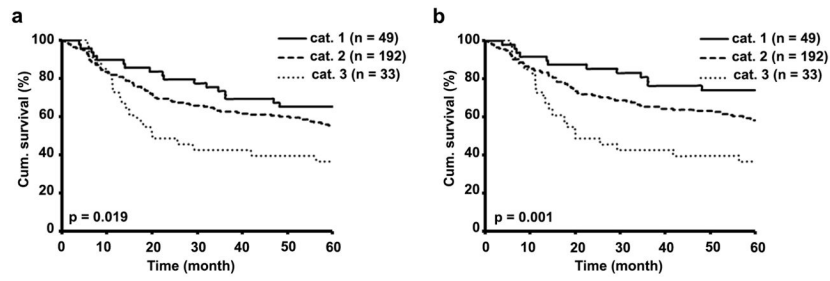


Figure 5. Concomitant loss of nuclear Drosha and cytoplasmic DICER1 inversely correlates with (a) Overall and (b) disease-specific 5-year survival of all primary and metastatic melanoma patients.

Table 1

Nuclear Droscha staining and clinicopathologic characteristics of 226 primary melanomas

Variables	Nuclear DROSHA staining			P value*
	Negative	Positive	Total	
Age				
63	81 (71.1%)	33 (28.9%)	114	0.327
>63	86 (76.8%)	26 (23.2%)	112	
Sex				
Male	91 (71.6%)	36 (28.4%)	127	0.385
Female	76 (76.8%)	23 (23.2%)	99	
Ulceration				
Present	40 (93.0%)	3 (7.0%)	43	0.002
Absent	127 (69.4%)	56 (30.6%)	183	
Lymphocytic response				
Present	56 (75.7%)	18 (24.3%)	74	0.670
Absent	111 (73.0%)	41 (27.0%)	152	
Tumor subtype				
Lentigo maligna	36 (65.5%)	19 (34.5%)	55	0.016
Superficial spreading	56 (68.3%)	26 (31.7%)	82	
Other [†]	75 (84.3%)	14 (15.7%)	89	
Site [‡]				
Sun-exposed	44 (74.6%)	15 (25.4%)	59	0.890
Sun-protected	123 (73.7%)	44 (26.3%)	127	

* χ^2 test.[†]Other: unspecified subtype.[‡]Sun-protected sites: trunk, arm, leg and feet; Sun-exposed sites: head and neck.