

Arthroscopically Assisted Reduction in a Chronic Locked Posterior Shoulder Dislocation



Niti Prasathaporn, M.D., Thongchai Laohathaimongkol, M.D., Vantawat Umprai, M.D., and Vanasiri Kuptniratsaikul, M.D.

Abstract: Neglected posterior shoulder dislocation is a difficult condition in terms of decision making and surgical technique. Not only the bony deformity but also the soft tissue and patient's underlying disease are of concern. Whether the poor results are associated with a time delay or the treatment method is not clear yet. To date, there is neither a consensus nor treatment guidelines. We describe an arthroscopically assisted reduction and open McLaughlin procedure. The advantage of this procedure is preservation of the soft tissue of the anterior part of the shoulder during the surgical reduction technique for chronic neglected posterior shoulder dislocation cases.

Posterior shoulder dislocation is an uncommon injury (Fig 1). The worldwide epidemiology is unclear, but the condition is claimed to account for approximately 2% to 10% of all shoulder dislocations globally.¹⁻³ The diagnosis of acute posterior dislocation is often missed, making it a regularly neglected condition. Because it used to be commonly unrecognized, there is a high level of suspicion for this condition.⁴ However, knowledge regarding the appropriate treatment of the neglected case is still lacking. According to Burkhead and Rockwood,⁵ primary functional management is generally used in most cases, with an 80% success rate in cases of hyperlaxity or absence of bone abnormality. However, in chronic traumatic cases with bone or soft-tissue defects, only 16% of patients gain excellent outcomes from the method, and most need further surgical intervention.⁵ Various treatment options are available depending on the type of associated bone and soft-tissue injuries. We

describe an arthroscopically assisted reduction and open McLaughlin procedure.

Surgical Technique

After receiving general anesthesia, the patient is placed in the beach-chair position (Fig 2A). The subacromial space is approached through a posterior portal, and removal of the subacromial bursa is then performed until the coracoacromial ligament is defined (Fig 3, Video 1). The viewing portal is switched from the posterior portal to a lateral portal. An anterior portal is created as a working portal. Thereafter, we clearly define the coracoacromial ligament, coracoid, conjoined tendon, and rotator interval (Fig 4). The intra-articular space is anteriorly approached through the rotator interval. We remove the intra-articular tissue, which is an obstacle to reduction. After debridement, a rod is inserted through the anterior portal. Then, it is passed between the humeral head and posterior glenoid rim (Fig 5A). We use the rod as a lever to reduce the impinging locked humeral head. The reduction is assisted by positioning the shoulder in external rotation while the humeral head is levered back to the level of the glenoid surface (Fig 5B).

After the reduction, the humeral head still shows posterior instability. We then decide to perform an open McLaughlin procedure, and the anterior deltopectoral approach is chosen. The glenohumeral joint is clearly defined through the previously created rotator interval (Fig 6). The arm is externally rotated to adequately visualize the subscapularis border. The lesser tuberosity undergoes osteotomy with a quarter-inch curved osteotome and is freed with the insertion of the

From the Department of Orthopaedics, Queen Savang Vadhana Memorial Hospital, Chonburi, Thailand.

The authors report that they have no conflicts of interest in the authorship and publication of this article. Full ICMJE author disclosure forms are available for this article online, as [supplementary material](#).

Received November 21, 2018; accepted March 13, 2019.

Address correspondence to Vanasiri Kuptniratsaikul, M.D., Department of Orthopaedics, Queen Savang Vadhana Memorial Hospital, 290 Jermjomphol Rd, Sriracha Province, Chonburi, Thailand. E-mail: van.kupt@gmail.com

© 2019 by the Arthroscopy Association of North America. Published by Elsevier. This is an open access article under the CC BY-NC-ND license (<http://creativecommons.org/licenses/by-nc-nd/4.0/>).

2212-6287/181403

<https://doi.org/10.1016/j.eats.2019.03.015>

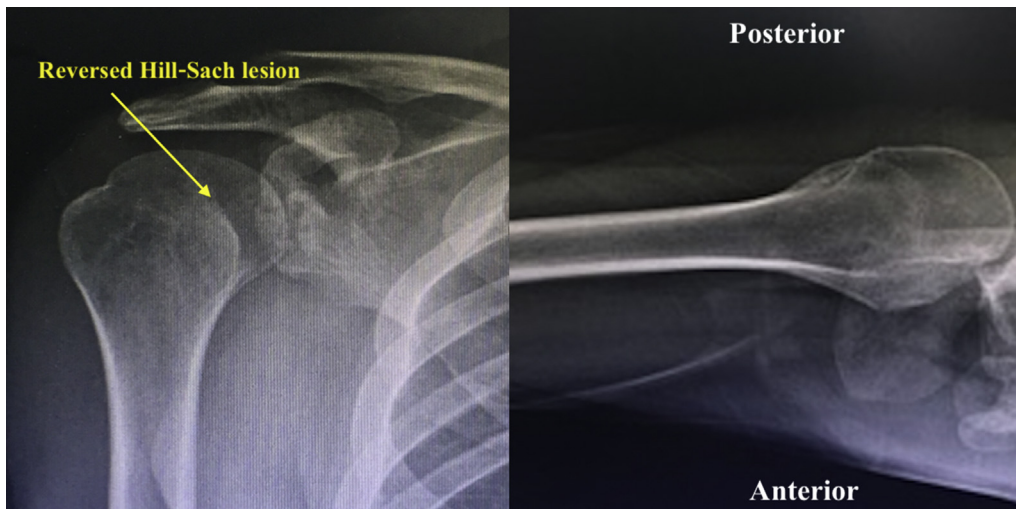


Fig 1. The posterior shoulder dislocation is defined with plain radiographs in anteroposterior and transaxillary views of the right shoulder.

subscapularis tendon (Fig 7). The reverse Hill-Sachs defect is identified, and the surface is refreshed using a high-speed burr (Fig 8). The lesser tuberosity is transferred and fixed to the reverse Hill-Sachs defect with two 3.0-mm headless Herbert screws (Osteomed, Addison, TX) (Fig 9). Trans-articular pin fixation with a 3.5-mm Steinmann pin is required if the glenohumeral joint is still unstable after the McLaughlin procedure (Fig 10), which is considered one of the limitations of this procedure (Table 1). The arm is set in a neutrally rotated position in an abduction arm sling for 4 weeks.

Postoperative Protocol

Passive range-of-motion exercise is allowed immediately after the operation. However, internal rotation motion is prohibited for 6 weeks. After 4 weeks, active-assisted passive motion exercise is started progressively. At 3 months postoperatively, full daily activities are

allowed. However, in cases requiring trans-articular pin fixation, full immobilization is needed for 6 weeks. After 6 weeks, active motion exercise is started. At 3 months postoperatively, full daily activities are allowed.

Discussion

Locked posterior shoulder dislocation is an uncommon condition that is usually misdiagnosed because of an inadequate initial physical examination and inadequate plain radiographs. In the previous literature, a misdiagnosis rate of 60% to 80% was reported.⁶ There are many causes of posterior shoulder dislocation, including seizures, electrical accidents, and traumatic events.

Locked posterior shoulder dislocation is a challenging situation. Not only the bony alignment but also problems with the soft tissue (e.g., soft-tissue stiffness,

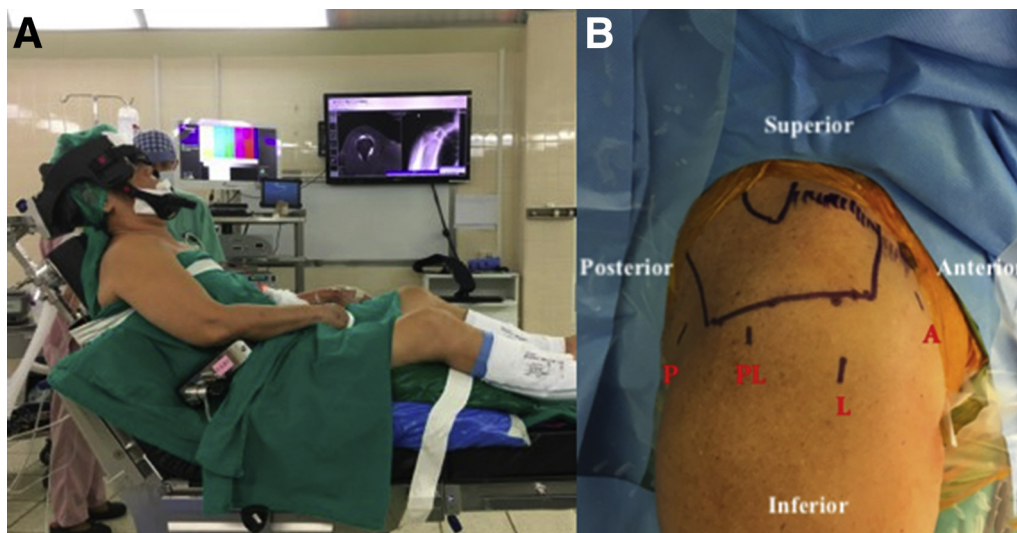
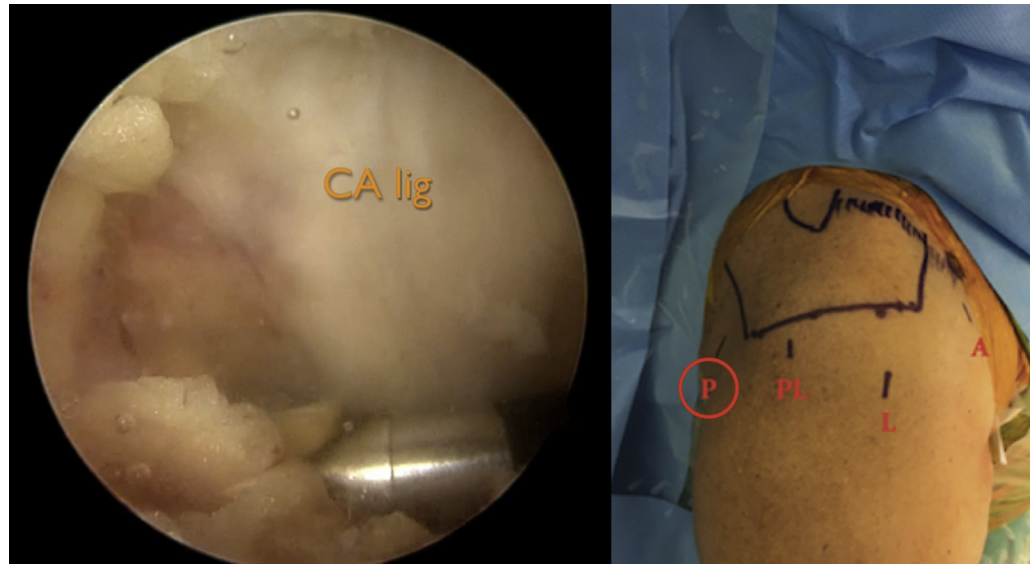


Fig 2. (A) After general anesthesia, the patient is placed in the beach-chair position with skin preparation on the right shoulder. (B) Four portals are used in this procedure: posterior (P), posterolateral (PL), lateral (L), and anterior (A).

Fig 3. Arthroscopic visualization of the right shoulder from the posterior portal (P) with the patient in the beach-chair position. The subacromial space is approached first, and removal of the subacromial bursa is then performed until the coracoacromial ligament (CA lig) is defined. (A, anterior portal; L, lateral portal; PL, posterolateral portal.)



muscle-force imbalance, capsulolabral lesion, and reverse Hill-Sachs lesion) are concerning conditions. These may also be the cause of failed reduction. Complete preoperative planning should be performed to prevent any further complications, especially avascular necrosis of the humeral head.

The longest duration of chronicity ever reported was only 28 months.⁷ In that case, with a split articular surface of the humeral head, shoulder hemiarthroplasty was performed via an open deltopectoral approach without a preceding reduction method. An arthroscopically assisted reduction technique has not been considerably discussed in cases of chronic locked posterior shoulder dislocation because it usually coexists with a large reverse Hill-Sachs lesion. We found only 1

case report, by Verma et al.,⁸ in which arthroscopic reduction and arthroscopic repair of the posterior capsulolabral complex were performed. The patient had no pain and no limitations regarding his shoulder at 4 years' follow-up. Nevertheless, the time from injury to surgery was only 4 weeks, and the size of the lesion was only 20%. In general, if closed reduction fails, open reduction through an anterior approach is advocated.⁸ However, we chose arthroscopically assisted reduction to eliminate the need for an open procedure because we planned to reconstruct the posterior structure from the open technique. The technique not only is less invasive but also is beneficial in terms of direct visualization of the intra-articular soft-tissue pathology obstructing the reduction (Table 1).

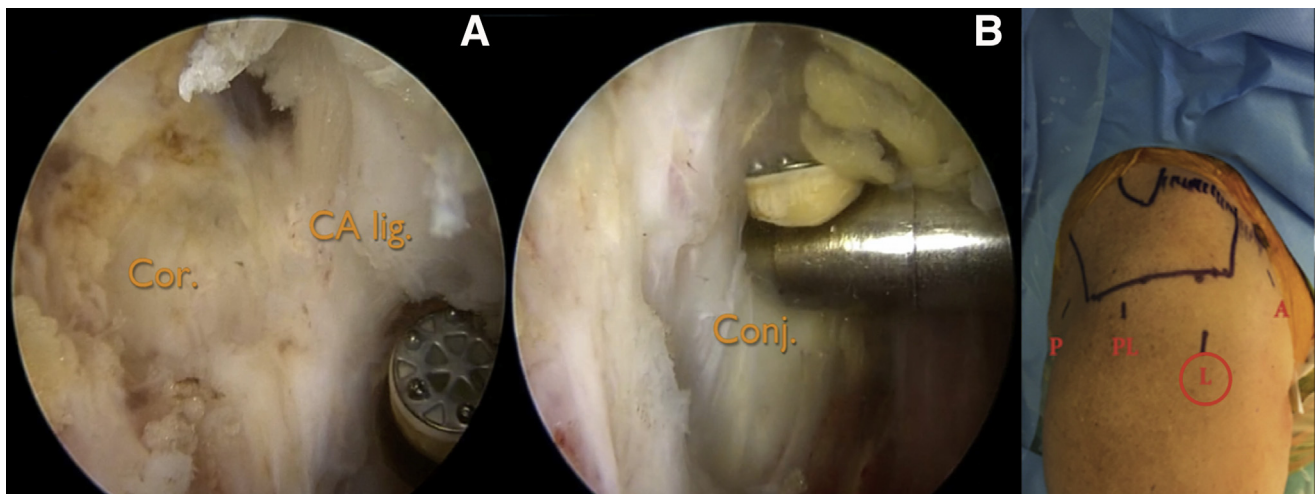


Fig 4. Arthroscopic visualization of the right shoulder with the patient in the beach-chair position. The viewing portal is switched to the lateral portal (L), and the soft tissue posterior to the rotator interval is removed from the anterior working portal until the coracoacromial ligament (CA lig) and coracoid (Cor) (A), as well as the conjoint tendon (Conj) (B), are defined. (A, anterior portal; P, posterior portal; PL, posterolateral portal.)

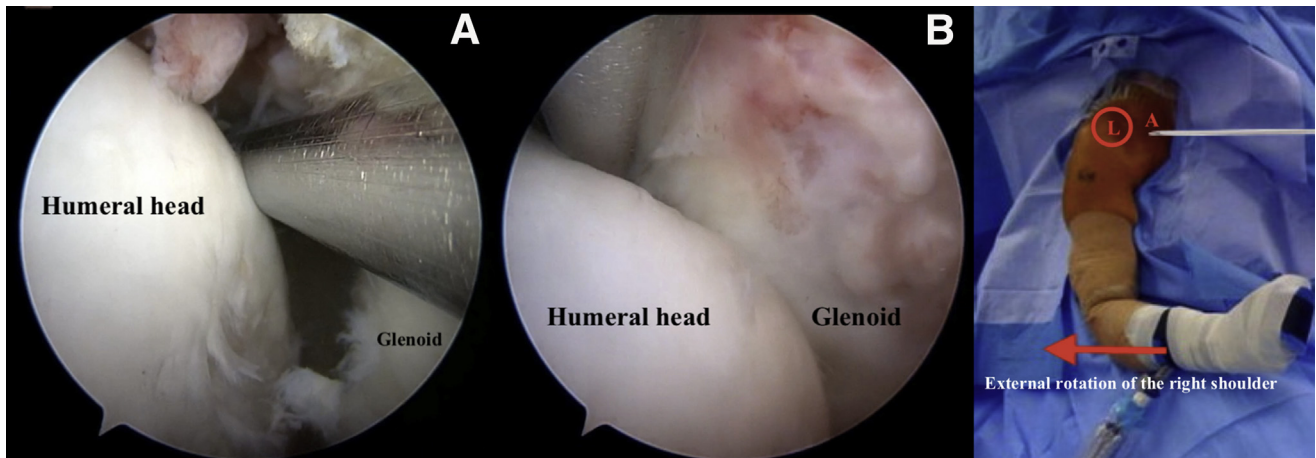


Fig 5. Arthroscopic visualization of the right shoulder from the lateral portal (L) with the patient in the beach-chair position. (A) The rod is inserted through the anterior portal and passed between the humeral head and posterior glenoid rim to use as a lever during the reduction. (B) The right shoulder is positioned in external rotation while the humeral head is levered back to the level of the glenoid surface. (A, anterior portal.)

Numerous procedures have been recommended for the management of reverse Hill-Sachs lesions, including the McLaughlin procedure,⁹ filling of the Hill-Sachs defect with allograft or autograft,¹⁰ balloon expansion with polymethyl methacrylate injection,¹¹ and closed reduction with arthroplasty.¹² In their study, Hawkins et al.¹² recommended performing an arthroplasty if the humeral defect is larger than 50%. In contrast, if the lesion involves 30% to 50% of the humeral head, the gold-standard treatment is the McLaughlin procedure or a modified technique.¹² In this study, after arthroscopically assisted reduction, the humeral head was redislocated while the arm was

internally rotated. Our patient's reverse Hill-Sachs lesion involved 30% of the humeral head, so we chose a standard open deltopectoral approach and the McLaughlin procedure.

Even though the McLaughlin procedure provides significantly superior results in acute shoulder dislocations, a recent systematic review found that the results were not different in chronic cases.¹³ Recently, there have been studies reporting case series of shoulder hemiarthroplasty in cases of chronic posterior shoulder dislocation in which the Hill-Sachs lesions did not even reach 50% of the humeral head. Gavriilidis et al.¹⁴ reported 6 cases of revision arthroplasty of chronic locked

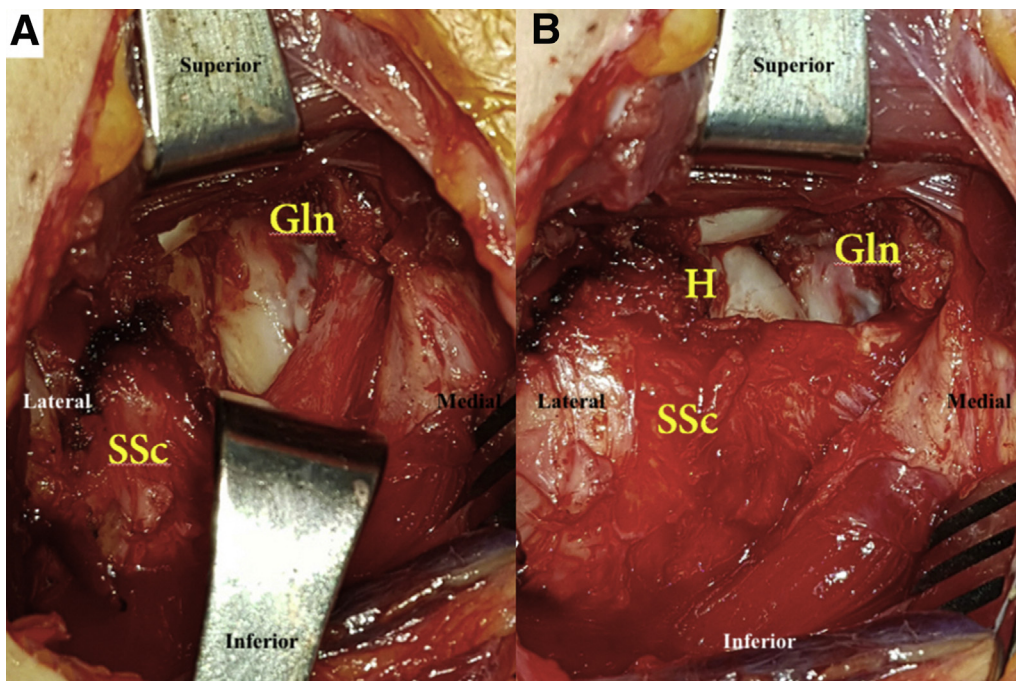


Fig 6. Right shoulder with the patient in the beach-chair position. An open McLaughlin procedure through a deltopectoral approach is performed. (A) The right posterior shoulder dislocation is defined. (B) After reduction, the humeral head (H) is located on the glenoid surface (Gln). (SSc, subscapularis tendon.)

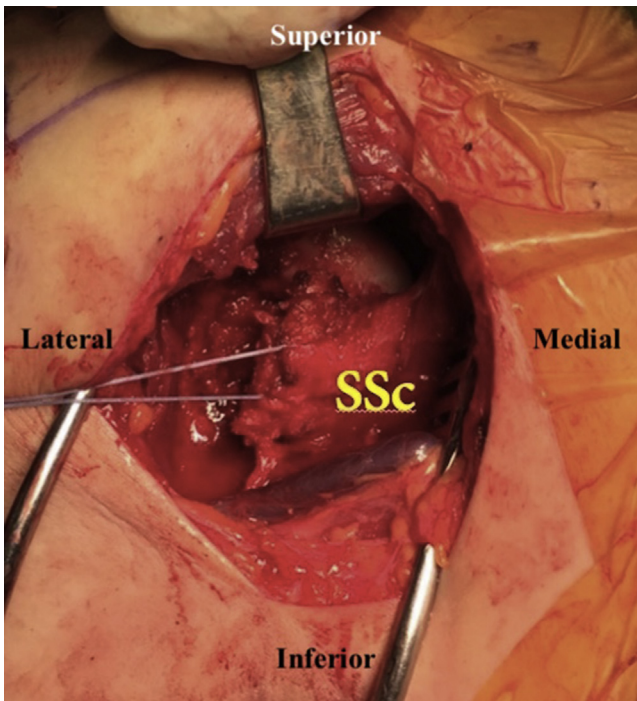


Fig 7. Right shoulder with the patient in the beach-chair position. The lesser tuberosity undergoes osteotomy with a quarter-inch curved osteotome and is freed with the insertion of the subscapularis tendon (SSc).

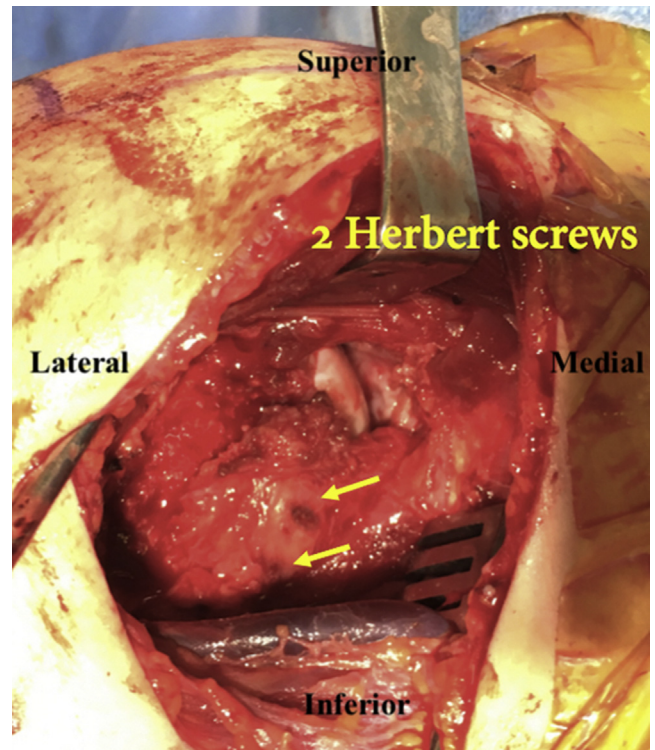


Fig 9. Right shoulder with the patient in the beach-chair position. The lesser tuberosity is transferred and fixed to the reverse Hill-Sachs defect with two 3.0-mm headless Herbert screws (arrows).

posterior shoulder dislocation after previous open reduction and emphasized that it is an appropriate option for humeral head defects of more than 45%. The

main benefit of primary arthroplasty is avoiding the complexity of the reduction technique or complications from postoperative immobilization, such as pin-tract infection from pins or screws across the joint in extensive exposure case.¹⁵ Moreover, it allows patients

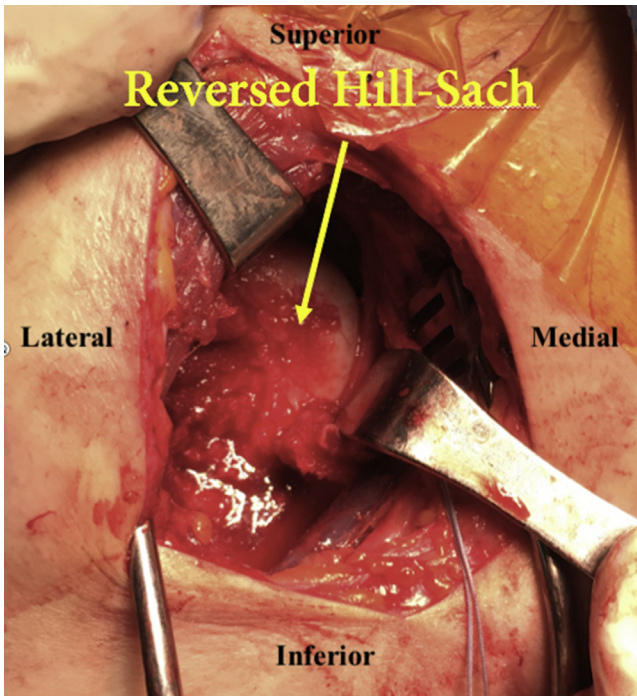


Fig 8. Right shoulder with the patient in the beach-chair position. The reverse Hill-Sachs defect is identified, and the surface is refreshed using a high-speed burr.

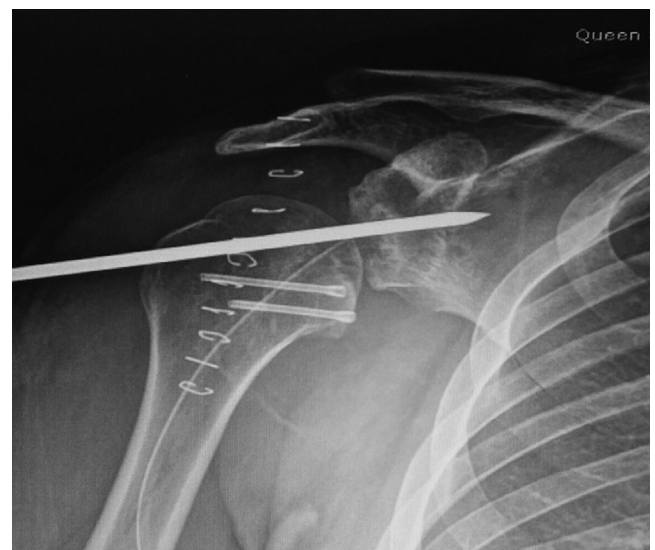


Fig 10. Postoperative radiograph, anteroposterior view, of the right shoulder after the McLaughlin procedure and fixation with a 3.5-mm Steinmann pin.

Table 1. Advantages, Tips and Pearls, and Limitations**Advantages**

The technique is less invasive and yields good cosmetic outcomes. The posterior labral tear can be arthroscopically repaired in the same setting.

Tips and pearls

The coracoacromial ligament is a key structure to help identify the coracoid.

The coracoid and conjoined tendon are key structures to define the rotator interval from an arthroscopic posterior viewing portal, allowing the glenohumeral joint to be approached from anteriorly.

While the humeral head is levered back to the level of the glenoid surface, the reduction is assisted by positioning the shoulder in external rotation.

Limitations

In unstable chronic locked posterior dislocation cases, open procedures (e.g., McLaughlin procedure) are required to stabilize the glenohumeral joint, even if the posterior labral tear was arthroscopically repaired.

After the open stabilization procedure, the imbalance of muscles and soft tissues in some prolonged chronic cases leads to a risk of recurrent dislocation. In such cases, trans-articular pin fixation is recommended for 6 weeks.

to start motion immediately, which is important for older patients.

We generally agree that the chronicity also affects the results of treatment. However, whether the poor results are associated with a time delay or the treatment method is not clear yet. To date, we have followed up our patient for 6 months and found no recurrent dislocation or instability. Further midterm to long-term results and complications are important aspects and must be followed up.

References

- Hatzis N, Kaar TK, Wirth MA, Rockwood CA Jr. The often overlooked posterior dislocation of the shoulder. *Tex Med* 2001;97:62-67.
- Owens BD, Duffey ML, Nelson BJ, DeBerardino TM, Taylor DC, Mountcastle SB. The incidence and characteristics of shoulder instability at the United States Military Academy. *Am J Sports Med* 2007;35:1168-1173.
- Kowalsky MS, Levine WN. Traumatic posterior glenohumeral dislocation: Classification, pathoanatomy, diagnosis, and treatment. *Orthop Clin North Am* 2008;39:519-533.viii.
- Rouleau DM, Hebert-Davies J. Incidence of associated injury in posterior shoulder dislocation: Systematic review of the literature. *J Orthop Trauma* 2012;26:246-251.
- Burkhead WZ Jr, Rockwood CA Jr. Treatment of instability of the shoulder with an exercise program. *J Bone Joint Surg Am* 1992;74:890-896.
- Xu W, Huang LX, Guo JJ, Jiang DH, Zhang Y, Yang HL. Neglected posterior dislocation of the shoulder: A systematic literature review. *J Orthop Translat* 2015;3:89-94.
- Takase K, Watanabe A, Yamamoto K. Chronic posterior dislocation of the glenohumeral joint complicated by a fractured proximal humerus: A case report. *J Orthop Surg (Hong Kong)* 2006;14:204-207.
- Verma NN, Sellards RA, Romeo AA. Arthroscopic reduction and repair of a locked posterior shoulder dislocation. *Arthroscopy* 2006;22:1252.e1-1252.e5.
- Delcogliano A, Caporaso A, Chiossi S, Menghi A, Cillo M, Delcogliano M. Surgical management of chronic, unreduced posterior dislocation of the shoulder. *Knee Surg Sports Traumatol Arthrosc* 2005;13:151-155.
- Diklic ID, Ganic ZD, Blagojevic ZD, Nho SJ, Romeo AA. Treatment of locked chronic posterior dislocation of the shoulder by reconstruction of the defect in the humeral head with an allograft. *J Bone Joint Surg Br* 2010;92:71-76.
- Sandmann GH, Siebenlist S, Imhoff FB, et al. Balloon-guided inflation osteoplasty in the treatment of Hill-Sachs lesions of the humeral head: Case report of a new technique. *Patient Saf Surg* 2016;10:4.
- Hawkins RJ, Neer CS II, Pianta RM, Mendoza FX. Locked posterior dislocation of the shoulder. *J Bone Joint Surg Am* 1987;69:9-18.
- Basal O, Dincer R, Turk B. Locked posterior dislocation of the shoulder: A systematic review. *EFORT Open Rev* 2018;3:15-23.
- Gavriilidis I, Magosch P, Lichtenberg S, Habermeyer P, Kircher J. Chronic locked posterior shoulder dislocation with severe head involvement. *Int Orthop* 2010;34:79-84.
- Pritchett JW, Clark JM. Prosthetic replacement for chronic unreduced dislocations of the shoulder. *Clin Orthop Relat Res* 1987;(216):89-93.