

# Comparison Between PE-TLIF and MIS-TLIF in the Treatment of Middle-Aged and Elderly Patients with Single-Level Lumbar Disc Herniation

Qi Han<sup>1</sup>, Feifan Meng<sup>1</sup>, Ming Chen<sup>1</sup>, Xiangjun Lu<sup>1</sup>, Deyuan Zhao<sup>1</sup>, Dongze Wu<sup>1</sup>, Tingting Wang<sup>2</sup>, Rujie Qin<sup>1</sup>

<sup>1</sup>Department of Orthopedics, The First People's Hospital of Lianyungang Affiliated to Xuzhou Medical University, Lianyungang, Jiangsu, People's Republic of China; <sup>2</sup>Department of Dermatology, The First People's Hospital of Lianyungang Affiliated to Xuzhou Medical University, Lianyungang, Jiangsu, People's Republic of China

Correspondence: Rujie Qin, Department of Orthopedics, The First People's Hospital of Lianyungang Affiliated to Xuzhou Medical University, No. 6 East Zhenhua Road, Haizhou, Lianyungang, Jiangsu, 222061, People's Republic of China, Email gkdrqlyg@sina.com

**Objective:** To evaluate the early clinical effect of percutaneous endoscopic transforaminal lumbar interbody fusion (PE-TLIF) and minimally invasive transforaminal lumbar interbody fusion (MIS-TLIF) surgery in the treatment of middle-aged and elderly patients with single-level lumbar disc herniation accompanied by lumbar instability.

**Methods:** From January 2019 to June 2020, a total of 82 consecutive patients were categorised into PE-TLIF group and MIS-TLIF group based on different surgical methods. The visual analog scale (VAS), Oswestry disability index (ODI), Japanese Orthopaedic Association (JOA) score, perioperative objective serological index, operation time, intraoperative blood loss, time to back to work or normal life, and Modified MacNab score were used as the evaluation indexes. The differences between the two groups were analyzed and the clinical effects were compared.

**Results:** The VAS back pain of PE-TLIF group was decreased compared to that of MIS-TLIF group in the postoperative 1 week and 1 month. The operative time in PE-TLIF group was obviously longer than that in MIS-TLIF group. The hospital stay was significantly shorter in PE-TLIF group than that in MIS-TLIF group. More intraoperative blood loss and postoperative drainage were recorded in MIS-TLIF group. Compared with MIS-TLIF, PE-TLIF surgery was associated with a shorter time to ambulation after surgery and a shorter time to back to work or normal life. Significant statistical differences were observed in IL-6, CRP, and CK on postoperative 3 days between the two groups.

**Conclusion:** For middle-aged and elderly patients, PE-TLIF and MIS-TLIF surgery both have obvious clinical efficacy and safety. However, with less intraoperative blood loss, shorter recovery time and less injury to the patients, people undergoing PE-TLIF surgery can return to work or normal life faster. It is speculated that PE-TLIF has a higher incidence of complications and recurrence rate than that MIS-TLIF. PE-TLIF may be a better choice for middle-aged and elderly patients with single-level lumbar disc herniation.

**Keywords:** lumbar disc herniation, minimally invasive surgery, percutaneous endoscopic transforaminal lumbar interbody fusion, minimally invasive transforaminal lumbar interbody fusion, middle-aged and elderly

## Introduction

Lumbar disc herniation (LDH) is 1 of the commonest reasons for lower back and leg pain in adults, which seriously affects the health and life quality, and brings a heavy burden on society and families. Low back pain has a lifetime prevalence of 84%<sup>1</sup> and has a high prevalence in middle adulthood and old age,<sup>2</sup> 60% of which are also accompanied by leg pain symptoms.<sup>3</sup> Although non-surgical treatment is the primary treatment for these conditions, those with intractable symptoms may need surgical treatment, especially middle-aged and elderly patients, whose disc, intervertebral ligaments, paravertebral muscle, facet joint cartilage have degenerated, and are usually accompanied by lumbar instability, discectomy combined with spinal fusion is a better choice.<sup>4</sup> When traditional open surgery was used for the treatment

of patients with LDH, the operative incision needed to be lengthened, which may result in greater surgical trauma, as well as increased bleeding and infection risk.<sup>5,6</sup> Spinal stability was also reduced after lumbar laminectomy. These increased surgery traumas have a greater influence on middle-aged and older patients. Therefore, spine surgeons are accompanied by great challenges in reducing the surgical trauma for patients with LDH and decreasing perioperative complications, as well as enhancing clinical outcomes and patient satisfaction. Against this backdrop, minimally invasive procedures are receiving increasing attention in the field of spine surgery.

Percutaneous endoscopic transforaminal lumbar interbody fusion (PE-TLIF), which evolved from percutaneous transforaminal endoscopic discectomy (PTED) technology, is 1 of the recently-developed minimally invasive spinal decompression and fusion procedures.<sup>7,8</sup> With the development of surgical techniques and new devices, PTED techniques have evolved to perform minimally invasive decompression and lumbar interbody fusion. Taking advantage of the safe corridor of Kambin's Triangle,<sup>9</sup> the endoscopic transforaminal approach allowed directly reaching the intervertebral space, for achieving neural decompression and lumbar interbody fusion without excision of the lamina, articular processes, and ligamentum flavum.<sup>7,10–13</sup> From a technology perspective, a direct yet safe decompression and endplate preparation under endoscopic visualization should be superior to traditional open decompression and interbody fusion surgery.<sup>11</sup> However, a deep learning curve and the anatomical limitations of the endoscopic approach created a great challenge in this technique, even for skilled spine surgeons.<sup>14</sup>

Minimally invasive transforaminal lumbar interbody fusion (MIS-TLIF), another minimally invasive spine surgery technique which was first developed by Foley<sup>15</sup> in 2003, has been shown to be a feasible and effective therapy for lumbar disc herniation.<sup>6,16–19</sup> The merits of MIS-TLIF include, but are not limited to less intraoperative blood loss, smaller iatrogenic soft tissue injury, less postoperative pain, early ambulation, shorter length of stay in hospital, and lower incision complications.<sup>6,19–23</sup> However, the shortcomings of MIS-TLIF, such as limited operative view and space, should not be ignored.<sup>16,21</sup>

To compare the medium-short term postoperative clinical effectiveness and the surgical injury of the 2 MIS (Minimally Invasive Surgery) procedures, in this study, we made a retrospective clinical comparison. We analyzed a series of 82 patients who received single level PE-TLIF and MIS-TLIF, and compared the perioperative parameters, clinical and radiographic results. The outcomes in prior studies, involving visual analog scale (VAS), Oswestry Disability Index (ODI) score, and Japanese Orthopaedic Association (JOA) score, were usually based on patient-reported.<sup>7,13,24–26</sup> The objective serological indexes, which are utilized for evaluating surgical trauma are still lacking. In this study, three objective serological indexes (IL-6, interleukin-6; CRP, C-reactive protein; CK, creatine kinase) were added to assess the surgical trauma. The purpose of our work was to provide a reference for the selection of the MIS surgeries in the treatment of middle-aged and elderly patients with single-level lumbar disc herniation.

## Materials and Methods

### Patient Population

From January 2019 to June 2020, a total of 82 consecutive patients who were diagnosed as single-level L3-4, L4-5, or L5-S1 disc herniation in the spine group of orthopedics department of The Affiliated Lianyungang Hospital of Xuzhou Medical University were analyzed retrospectively. Our study protocol was approved by the ethics committee of the Affiliated Lianyungang Hospital of Xuzhou Medical University. Depending on different surgical approaches employed, the enrolled patients were sub-clustered into a PE-TLIF group and a MIS-TLIF group. There were 39 patients in the PE-TLIF group, including 18 males and 21 females; their ages varied from 47 to 77 years, with an average of 60.35±8.04 years; the duration of symptoms was 1 to 4 years, with an average of 2.24±0.92 years. The lesion segment was L3-4 in 9 patients, L4-5 in 27 patients, and L5-S1 in 3 patients. There were 43 patients in the MIS-TLIF group, including 23 males and 20 females; their age varied from 47 to 77 years, with an average of 60.98±6.62 years; the duration of symptoms was 1 to 3.5 years, with a mean of 2.00±0.76 years. The lesion segment was L3-4 in 10 patients, L4-5 in 24 patients, and L5-S1 in 9 patients. No significant differences were found in gender, age, Body Mass Index (BMI), duration of symptoms, or lesion segment between the two treatment groups ( $P>0.05$ ), as shown in [Table 1](#).

**Table 1** Patient Basic Information of Group PE-TLIF and Group MIS-TLIF

	Group PE-TLIF	Group MIS-TLIF	P value
N	39	43	
Gender (male:female)	18:21	23:20	0.66
Age (years)	60.35±8.04	60.98±6.62	0.94
BMI (kg/m <sup>2</sup> )	23.32±2.52	22.98±2.23	0.52
Levels (%)			0.57
L3-4	9(23%)	10(23%)	
L4-5	27(69%)	24(56%)	
L5-S1	3(8%)	9(21%)	
Duration of symptoms (years)	2.24±0.92	2.00±0.76	0.20
Follow-up (months)	19.49±2.86	19.19±2.22	0.60

**Abbreviations:** PE-TLIF, percutaneous endoscopic transforaminal lumbar interbody fusion; MIS-TLIF, minimally invasive transforaminal lumbar interbody fusion; BMI, body mass index.

## Selection Criteria

### Inclusion Criteria

(1) Age  $\geq 45$  and  $\leq 80$  years; (2) typical clinical signs and symptoms of lumbar disc herniation with low back pain and leg pain; (3) imaging evidence of single level lumbar disc herniation accompanied by lumbar spinal instability and/or mild lumbar spinal stenosis, such as dynamic X-ray, computed tomography (CT), and magnetic resonance imaging (MRI); (4) bone mineral density (BMD) values were measured to confirm the absence of severe osteoporosis; (5) patients who have received rigorous conservative treatment for a minimum of 3 months, but with poor efficacy.

### Exclusion Criteria

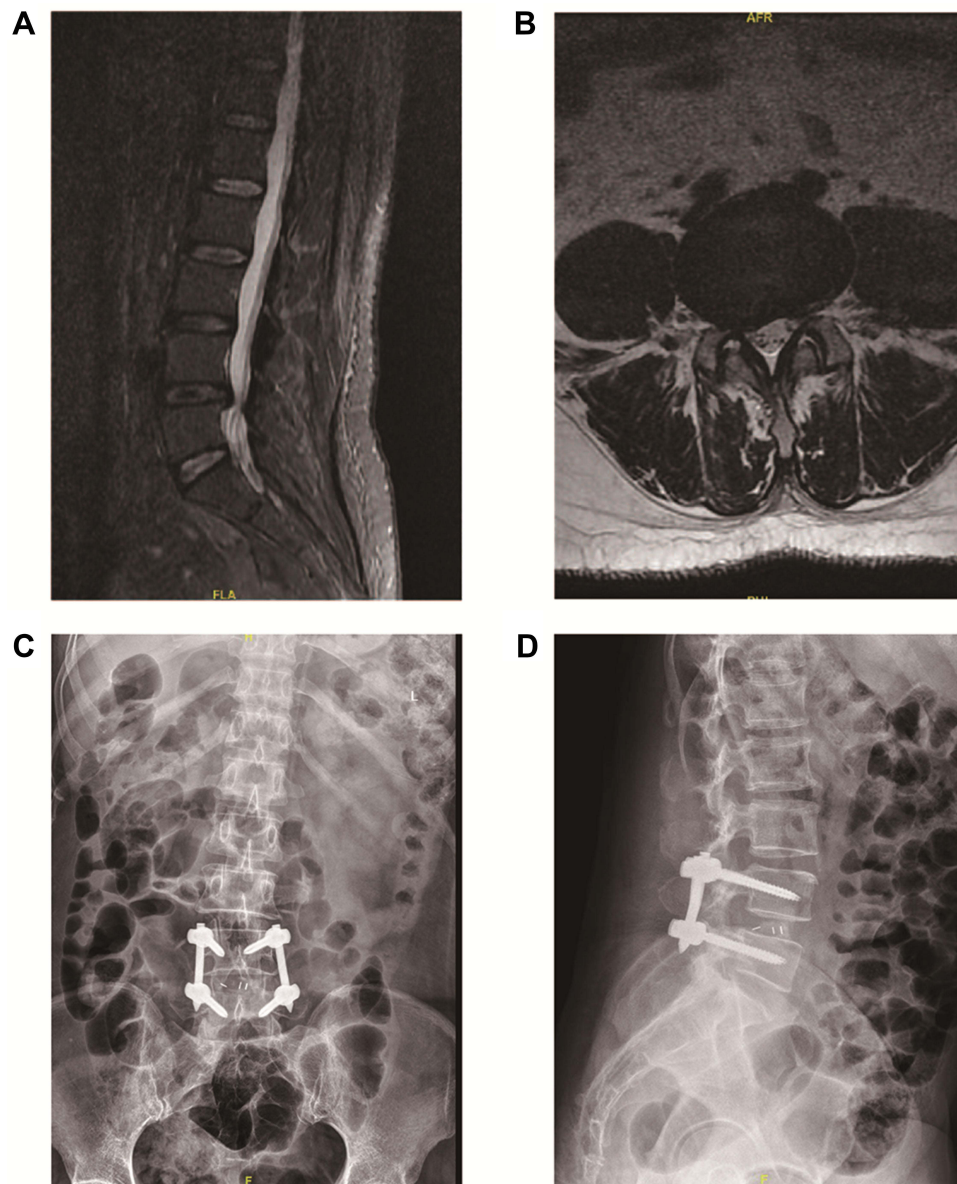
(1) Patients with two or multi-level lumbar disc herniation; (2) patients with severe spinal deformity, severe lumbar spinal canal stenosis; (3) patients with spinal infections, spinal tuberculosis, or tumors; (4) patients with serious coagulation dysfunction; (5) patients with severe underlying diseases or psychotic disorders; (6) cauda equina syndrome; (7) reluctant to or incapable of partaking in treatment scheme and complete valid follow-up.

## Surgical Procedures

PE-TLIF group: after induction of general anesthesia, the patient was placed in a prone position on the radiolucent operation table, intraoperative neurophysiological monitoring was performed during the whole surgery. First, under the supervision of C-arm X-ray machine, 4 retractor connecting rods were tapped into pedicles with a Wiltse's paraspinous approach<sup>23</sup> at the responsibility segments. Two stretchers were placed in preparation for stretch. The skin entry and incision point of percutaneous endoscope was made about 8 cm lateral off the spinous process line. Then, an 18G puncture needle was inserted into the intervertebral space and then the needle was exchanged with a 0.8 mm guidewire past the guide cannula. A 2 mm primary expansion guiderod was inserted along the guidewire. Then 3.5, 4.5, and 5.5 mm dilatation catheters were inserted step by step to expand the surgical passage, and foraminoplasty at the superior articular process was performed by using endoscopic high-speed diamond burr and a bipolar radiofrequency device. After traditional guidewire/rod, a TESSYS (Joimax GmbH, Karlsruhe, Germany) working cannula was placed and intervertebral disc tissue was stained by methylene blue. A working channel endoscope is then introduced and decompression of nerve roots was performed by nucleus pulposus forceps under the monitoring of endoscope. After the decompression of nerve roots, the intervertebral space of the affected side was propped open by pre-installed two stretchers and the TESSYS working tube was withdrawn, replaced by a patented C-shaped working cannula (15 mm of inner diameter). The instruments, such as nucleus pulposus forceps, raspatories, and a series of endoscopic curettes and reamers were used to further clear intervertebral discs, and the endplate preparation was performed by endoscopic monitoring. Autogenous bone obtained from foraminoplasty and allograft bone (Shandong Weigao Group Medical Polymed Co., Ltd., Shandong, China) were impacted into the anterior intervertebral space. A standard rigid intervertebral PEEK cage (Halis<sup>®</sup>, Sanyou, Inc., Shanghai, China), filled with autograft bone graft, was inserted obliquely across the disc space. After the cage was released, neural decompression and the location of the implant cage were evaluated

again through endoscopic visualization. Four percutaneous pedicle screws (Jiangsu Chuangsheng Medical Co., Ltd., Changzhou, China) were placed, and percutaneous posterior rods were fixed and locked. A subfascial drainage tube was placed and each incision was closed directly (typical example can be seen in Figure 1).

MIS-TLIF group: after general anesthesia, the patient was placed in a prone position on the radiolucent operating table, intraoperative neurophysiological monitoring was employed during the whole surgery. The anatomical landmarks and paravertebral skin incision of 3 cm at the operation segment were marked via C-arm fluoroscopic guidance for canal decompression and instrumented fusion. To begin with, the 2 pedicle screws (Jiangsu Chuangsheng Medical Co., Ltd., Changzhou, China) on the asymptomatic side were placed with Wiltse's paraspinal approach<sup>23</sup> at the responsibility level. Then a tubular retractor (Fule Science & Technology Development Co., Ltd, Beijing, China) was placed after graded muscle dilation. Under the exposure of the dilated channel, the ligamentum flavum and bone of the inferior margin of the lamina were resected with laminectomy forceps. Under direct vision, the nerve root canal was enlarged, the nerve root



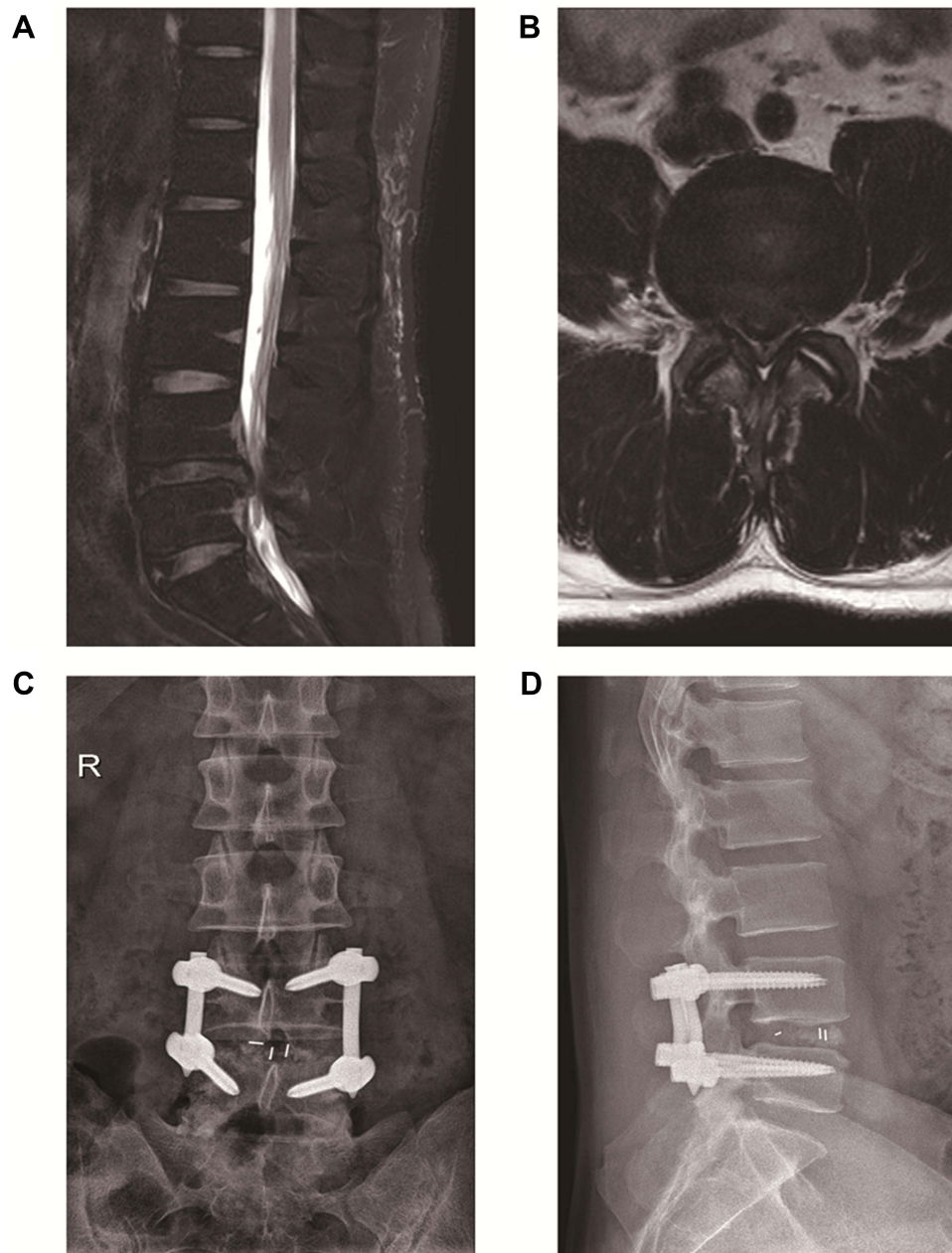
**Figure 1** A case of PE-TLIF surgery.

**Notes:** (A and B) lumbar MRI revealed L4-5 lumbar disc herniation. (C) Frontal and (D) lateral X-ray images represented permanent positions after 3 months.

**Abbreviations:** PE-TLIF, percutaneous endoscopic transforaminal lumbar interbody fusion; MRI, magnetic resonance imaging.



was fully released, and the spinal canal was sufficiently decompressed. After completion of spinal canal decompression and endplate preparation, autologous bone which was obtained from decompression, including facet and lamina was impacted into the anterior intervertebral space. Then a standard rigid intervertebral PEEK cage (Halis<sup>®</sup>, Sanyou, Inc., Shanghai, China), filled with autogenous bone graft, was implanted under X-ray guidance. After the tubular retractor was removed, the two percutaneous pedicle screws (Jiangsu Chuangsheng Medical Co., Ltd., Changzhou, China) in the symptomatic side were placed and percutaneous posterior rods were fixed. A subfascial drainage tube was also placed before the incisions were closed (typical example can be seen in Figure 2).



**Figure 2** A case of MIS-TLIF surgery.

**Notes:** (A and B) lumbar MRI revealed L4-5 lumbar disc herniation. (C) Frontal and (D) lateral X-ray image represented permanent position after 3 months.

**Abbreviations:** MIS-TLIF, minimally invasive transforaminal lumbar interbody fusion; MRI, magnetic resonance imaging.

## Postoperative Care

Antibiotic prophylaxis was routinely administered to all patients 30 minutes preoperatively and 24 hours postoperatively. Patients in the PE-TLIF group were able to take straight-leg raise exercises 6 hours after surgery, able to exercise the back muscles, and able to get out of bed with the protection of the lumbar-brace 1 day after surgery. Patients in the MIS-TLIF group were able to take straight-leg raise exercises in bed three days postoperatively, and able to get out of bed with the protection of the lumbar-brace 7 days after the operation.

## Observation Indicators

The following evaluation indexes were evaluated and compared between the two groups:

- (1) Perioperative indexes: including operative time, length of hospital admissions, time to ambulation after surgery, back to work/normal lifetime, intraoperative blood loss and postoperative volume of drainage, etc.;
- (2) Pre and postoperative VAS scores, ODI scores, JOA scores, and Modified MacNab criterion;
- (3) Postoperative complications, interbody vertebral fusion rate, and recurrence rate.

## Statistical Analysis

SPSS 26.0 (IBM Corp.) was used to process all statistical analyses, and GraphPad Prism 9 (GraphPad Software, Inc.) was used to visualize the data images. The Chi-square test or Fisher's exact test was used for counting data in this study. Measurement data were presented as mean±standard deviation (SD). Normal distribution data were evaluated by Student's *t*-test to compare the differences of the 2 groups, while the non-normality distribution data and grade data were identified by nonparametric Mann–Whitney *U*-test.  $P < 0.05$  was considered as statistically significant.  $P < 0.01$  was considered as extremely statistically significant.

## Results

82 patients (Group PE-TLIF, 39 patients; Group MIS-TLIF, 43 patients) who underwent the two MIS surgery between January 2019 to June 2020 were included in this retrospective study. All patients received single segment of the lumbar spine fusion surgery and were followed up for at least 15 months. No differences were found in gender, age, lesion level, BMI, duration of symptoms, follow-up period, or preoperative diagnosis between the 2 groups (Table 1). No conversion to open surgery was observed in either of the studied groups. No patients were lost to follow-up in our study.

As shown in Table 2, no significant differences were detected between the two treatment groups in objective serological index preoperatively ( $P > 0.05$ ). Nevertheless, Table 2 also showed significant differences in IL-6 ( $P = 0.0016$ ), CRP ( $P < 0.001$ ), and CK ( $P < 0.001$ ) on postoperative 3 days.

The operating time in PE-TLIF group (146.2±18.25 min) was significantly longer than that in MIS-TLIF group (127.90 ±7.76 min;  $P < 0.001$ ). Patients in PE-TLIF group (4.64±0.87d) stayed significantly shorter in the hospital than patients in

**Table 2** Comparison of Serological Markers in Group PE-TLIF and Group MIS-TLIF

Serological Markers	Group PE-TLIF	Group MIS-TLIF	P value
IL-6(pg/mL)			
Preoperative	4.37±0.49	4.43±0.49	0.57
3 days	1.13±0.20*	1.23±0.12*	<b>0.0016</b>
CRP (mg/L)			
Preoperative	5.00±0.78	4.89±0.67	0.31
3 days	75.89±15.83*	102.71±23.75*	<b>&lt;0.0001</b>
CK (IU/L)			
Preoperative	62.55±9.61	60.71±7.05	0.32
3 days	355.01±45.92*	463.41±32.74*	<b>&lt;0.0001</b>

**Note:** \*Compared with preoperative,  $P < 0.05$ . Bold values indicate statistical significance. Values are presented as mean ± SD.

**Abbreviations:** PE-TLIF, percutaneous endoscopic transforaminal lumbar interbody fusion; MIS-TLIF, minimally invasive transforaminal lumbar interbody fusion; IL-6, interleukin-6; CRP, C-reactive protein; CK, creatine kinase.

MIS-TLIF group ( $7.79 \pm 0.74$ ;  $P < 0.001$ ). More blood loss and volume of drainage after surgery was recorded in MIS-TLIF group ( $86.56 \pm 8.90$  mL;  $150.90 \pm 10.27$  mL) than in PE-TLIF group ( $48.87 \pm 7.14$  mL;  $80.44 \pm 12.19$  mL) ( $P < 0.001$ ). Compared with MIS-TLIF, PE-TLIF surgery was associated with a shorter postoperative activity time and a shorter time to back to work or normal life ( $P < 0.01$ ) (Table 3). Both groups showed remarkable improvement in VAS back pain, VAS leg pain, ODI scores, and JOA scores at any time-point postoperatively ( $P < 0.001$ ). The VAS back pain in the postoperative 1 week ( $3.24 \pm 0.48$ ) and 1 month ( $2.47 \pm 0.44$ ) of the PE-TLIF group was significantly lower than that of MIS-TLIF group (1 week:  $3.95 \pm 0.72$ ; 1 month:  $2.83 \pm 0.62$ ) ( $P < 0.01$ ). However, no statistical differences were observed in postoperative 3 months, 6 months, and final follow-up VAS back pain ( $P > 0.05$ ). The VAS-LP, ODI, and JOA at any time-point after surgery between

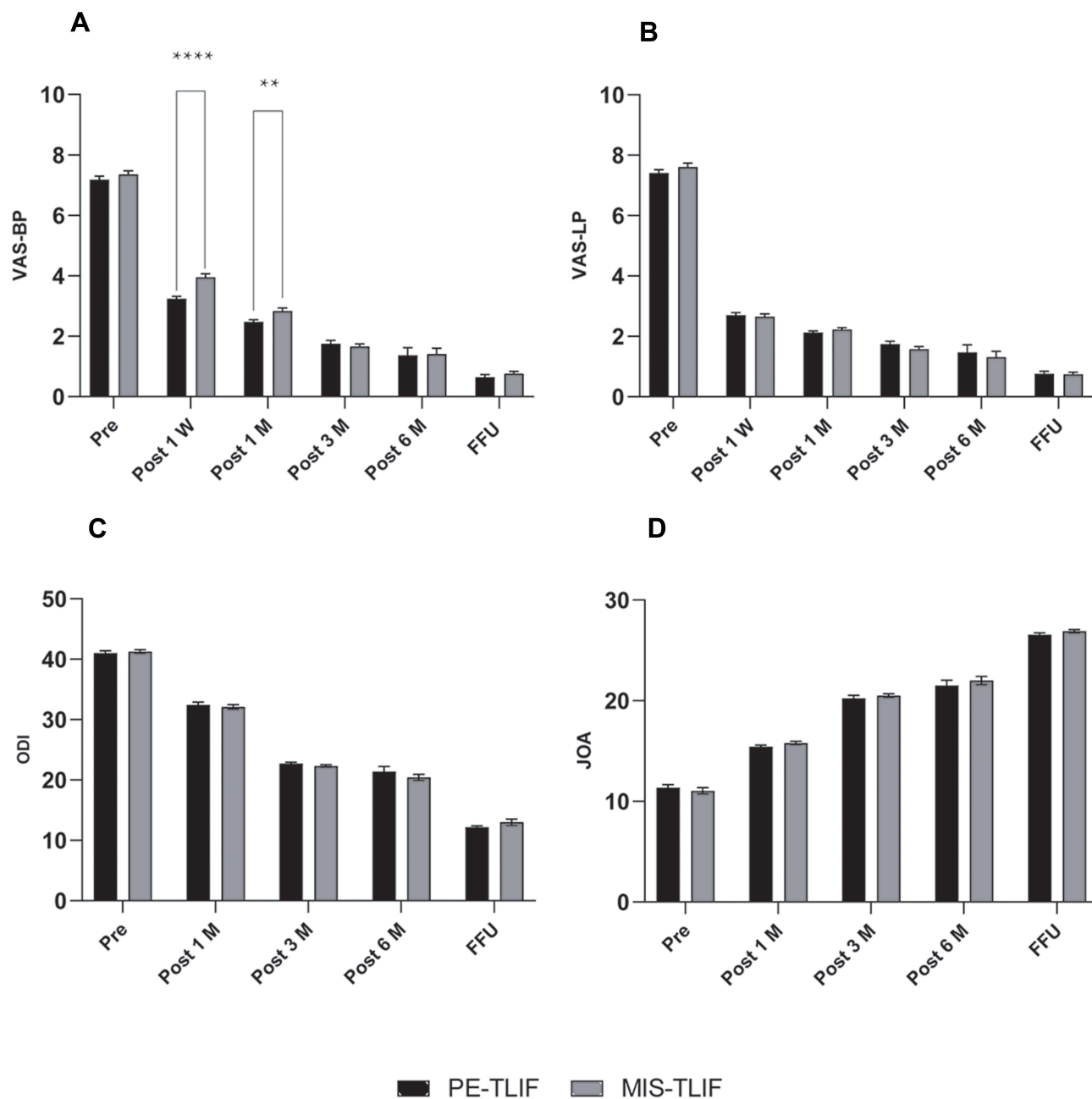
**Table 3** Comparison of Clinical Outcomes Between PE-TLIF and MIS-TLIF

Clinical Data	Group PE-TLIF	Group MIS-TLIF	P value
VAS back pain			<b>0.025</b>
Preoperative	7.18±0.72	7.36±0.75	0.27
1 week	3.24±0.48*	3.95±0.72*	<b>&lt;0.001</b>
1 month	2.47±0.44*	2.83±0.62*	<b>0.004</b>
3 months	1.76±0.63*	1.66±0.54*	0.47
6 months	1.37±1.56*	1.41±1.25*	0.89
Final follow up	0.65±0.49*	0.76±0.46*	0.29
VAS leg pain			0.57
Preoperative	7.41±0.67	7.62±0.77	0.20
1 week	2.71±0.53*	2.65±0.63*	0.68
1 month	2.13±0.30*	2.23±0.35*	0.15
3 months	1.74±0.56*	1.58±0.53*	0.18
6 months	1.47±1.53*	1.31±1.24*	0.60
Final follow up	0.76±0.48*	0.74±0.42*	0.84
ODI			0.32
Preoperative	41.03±2.19	41.26±1.90	0.61
1 month	32.44±2.79*	32.12±2.40*	0.58
3 months	22.72±1.34*	22.33±1.23*	0.17
6 months	21.38±5.30*	20.44±3.20*	0.33
Final follow up	12.17±1.28*	13.00±3.44*	0.17
JOA			0.69
Preoperative	11.36±1.93	11.05±1.99	0.47
1 month	15.44±0.99*	15.79±1.08*	0.13
3 months	20.23±1.97*	20.51±1.18*	0.43
6 months	21.51±3.32*	22.00±2.75*	0.47
Final follow up	26.56±1.02*	26.90±0.99*	0.14
Operative time (minutes)	146.20±18.25	127.90±7.76	<b>&lt;0.001</b>
Intraoperative blood loss (mL)	48.87±7.14	86.56±8.90	<b>&lt;0.001</b>
Postoperative drainage (mL)	81.23±9.374	150.5±15.12	<b>&lt;0.001</b>
Length of hospital stay (days)	4.79±0.89	7.79±0.74	<b>&lt;0.001</b>
Time to ambulation after surgery (days)	6.54±1.07	15.35±1.98	<b>&lt;0.001</b>
Back to work/ normal lifetime (months)	3.82±0.92	4.43±0.95	<b>0.0043</b>
Complications (%)	12.82%(5/39)	4.65%(2/43)	0.25
Recurrence (%)			
3–6 months	7.69%(3/39)	4.65%(2/43)	0.66
CT fusion rates			
12 months	89.74%(35/39)	95.35%(41/43)	0.41
Modified MacNab <sup>a</sup>			
12 months	23:13:2:1	24:15:3:1	0.77

**Notes:** \*Compared with preoperative,  $P < 0.001$ . Bold values indicate statistical significance. Values are presented as mean  $\pm$  SD. <sup>a</sup>Excellent; good; fair; poor.

**Abbreviations:** PE-TLIF; percutaneous endoscopic transforaminal lumbar interbody fusion; MIS-TLIF; minimally invasive transforaminal lumbar interbody fusion; VAS, visual analog scale; ODI, Oswestry disability index; JOA, Japanese Orthopaedic Association; CT, computed tomography.

the two treatment groups did not show a significant difference (Table 3, Figure 3). The modified Macnab criteria showed no difference between the 2 groups with 92.31% (36/39) patients of PE-TLIF group and 90.70% (39/43) of MIS-TLIF group showing “excellent” or “good” ( $P=0.77$ ). The status of interbody fusion was assessed by CT examination at the 12 months follow-up. According to the Bridwell-Lenke interbody fusion grading system, PE-TLIF group composed of 18, 15.3, and 0 cases of grades I, II, III, and IV respectively, whereas MIS-TLIF group consisted of 24, 15, 2, and 0 cases of grades I, II, III, and IV, respectively. No statistically significant difference was found in the fusion rate (percentage of grade I and II) between PE-TLIF group (89.74%) and MIS-TLIF group (95.35%). The complications and recurrences of PE-TLIF group



**Figure 3** Comparison of (A) VAS back pain, (B) VAS leg pain, (C) ODI scores, and (D) JOA scores between the PE-TLIF and MIS-TLIF groups.

**Notes:** Pre, preoperative; Post 1 W, postoperative 1 week; Post 1 M, postoperative 1 month; Post 3 M, postoperative 3 months; Post 6 M, postoperative 6 months; FFU, Final Follow Up. Data are presented as mean  $\pm$  SD. \*\* $P < 0.01$ , \*\*\*\* $P < 0.0001$  compared with MIS-TLIF group.

**Abbreviations:** VAS-BP, VAS back pain; VAS-LP, VAS leg pain; ODI, Oswestry disability index; JOA, Japanese Orthopaedic Association; PE-TLIF, percutaneous endoscopic transforaminal lumbar interbody fusion; MIS-TLIF, minimally invasive transformation lumbar interbody fusion.



were recorded and compared with MIS-TLIF group. The complications included neurological deficit, cage subsidence/migration, and infection of incision, and there was no significant difference in postoperative complications between the two treatment groups ( $P=0.25$ ). PE-TLIF group had 3 patients (7.69%) with recurrence, and MIS-TLIF group had 2 patients (4.65%) with recurrence ( $P=0.66$ ) (Table 3). All the patients with recurrence received PTED as revision surgery and had a satisfactory recovery.

## Discussion

LDH is the most prevalent clinical condition in spinal surgery. Patients with LDH accompanied by lumbar instability are usually treated surgically with spinal canal decompression and intervertebral fusion.<sup>27</sup> Compared with traditional open posterior lumbar interbody fusion, minimally invasive lumbar interbody fusion surgery has gained increasing interest in the past few years. In recent years, minimally invasive spinal surgery has evolved quickly, and conventional open surgery has gradually been replaced with minimally invasive surgery as a standard procedure in the treatment of LDH.<sup>28</sup>

PE-TLIF and MIS-TLIF are two novel and emerging minimally invasive spinal decompression and fusion surgeries. Compared with conventional open surgery, either of them can achieve comparable clinical results as the traditional open surgery but with less damage and faster rehabilitation.<sup>6,7,16,21</sup> In this retrospective study, we performed PE-TLIF and MIS-TLIF in middle-aged and elderly patients with single-level lumbar disc herniation. We first analyzed the strengths and weaknesses of PE-TLIF and MIS-TLIF in perioperative period by common perioperative parameters binding to objective serological indexes in our study, which will provide references for the selection of minimally invasive spinal surgery.

IL-6 plays an aposematic role in the inflammatory process of lumbar disc herniation. It could be used as a biomarker for assessing postoperative pain relief and disability improvement.<sup>29</sup> The association between IL-6 and discopathy-related pain has been proved.<sup>30,31</sup> In this study, the IL-6 of PE-TLIF group was statistically significantly lower than those of MIS-TLIF group at postoperative 3 days ( $P=0.0016$ ). This result suggested that the PE-TLIF surgery can achieve a significant decrease in early postoperative pain.

CRP is a feasible parameter for evaluating surgical trauma of these two different surgeries. Serial CRP detections can be used not only as a diagnostic marker for infection, but also for assessing the effect of surgical interventions.<sup>32,33</sup> The CRP levels reached a peak on postoperative 3 days.<sup>32</sup> As an indicator of the degree of tissue trauma, CRP in PE-TLIF group was significantly lower than that in MIS-TLIF group on the third postoperative day ( $P<0.001$ ). This result showed that the PE-TLIF surgery preserved the posterior structures and left less surgical trauma.

Serum CK, an index of skeletal muscle injury, could be exploited to evaluate muscle injury. A close association between the serum CK levels and degree of impairment of the paraspinal muscle.<sup>34</sup> In our study, the postoperative serum CK in PE-TLIF group was significantly lower than that of MIS-TLIF group at the time point of postoperative 3 days ( $P<0.001$ ). The result indicated that less iatrogenic muscle damage can be achieved in PE-TLIF versus MIS-TLIF.

The clinical results indicated that PE-TLIF group was superior over MIS-TLIF group in hospital length of stay, time to ambulation after surgery, back to work/normal lifetime, intraoperative bleeding volume, and postoperative volume of drainage. Due to the limited operating space and longer fluoroscopy time, however, the operation time for PE-TLIF procedure was obviously longer compared to MIS-TLIF procedure. Not so long ago, a prospective study reported similar results showed that PE-TLIF had a significant strength versus MIS-TLIF in terms of length of hospital stay, intraoperative bleeding volume, and postoperative volume of drainage.<sup>7</sup> The reason indicates the possibility that PE-TLIF is based on endoscopic dilation techniques and percutaneous access techniques and has less injury to normal structure of the lumbar spine, thus being more beneficial for the rehabilitation of the patients.

The scores of VAS, ODI, and JOA are commonly used indexes to assess the lumbar functions recovery and the postoperative efficacy.<sup>35</sup> Our results indicated that, in both groups, a significant decrease was observed in the VAS and ODI scores, and an increase was found in JOA scores at different post-surgical time points. No statistically significant difference was found for VAS leg pain, ODI, and JOA scores between the two groups at any follow-up time point. However, significant differences were found in VAS back pain in the 2 treatment groups ( $P=0.025$ ), particularly less pain on one day and one month after surgery for PE-TLIF group. This showed that PE-TLIF and MIS-TLIF could efficiently relieve low back pain and leg pain of LDH patients and improve the functional status of the lumbar spine. Particularly

during the early postoperative period, with shorter skin incisions and minor injury to paravertebral muscles, PE-TLIF could lead to less low back pain and bring a better quality of life. This result was similar to those of several previous studies.<sup>7,8,36</sup> Modified MacNab criterion is often used to assess the symptomatic improvement of LDH patients.<sup>37</sup> In this study, the efficacy in patients from the 2 groups was evaluated by Modified MacNab and the excellent rate was found was 92.31% in PE-TLIF group, and 90.70% in MIS-TLIF group. This suggested that the clinical symptoms of LDH patients were significantly improved in both PE-TLIF group and MIS-TLIF group, and the efficacy of the 2 treatment groups is similar.

In our study, all surgeries were completed uneventfully no matter by PE-TLIF or MIS-TLIF technique, but with 5 peri-operative complications (12.82%) in PE-TLIF group, including neurological deficit, cage subsidence/migration, and infection of incision, 2 (4.65%) in MIS-TLIF group. Three cases in PE-TLIF group and 1 case in MIS-TLIF group developed neurological symptoms after surgery, including numbness and pain of a lower limb. Following administration of dexamethasone combined with dehydration and neurotrophic drugs, a full recovery was achieved in the four patients. Three cases in PE-TLIF group (7.69%) and 2 cases in MIS-TLIF group (4.65%) experienced early postoperative recurrences 3–6 months after surgery. The main complaints of the patients are pain in the contralateral limb and all of them recovered fully after receiving percutaneous transforaminal endoscopic discectomy as revision surgery. Cage subsidence/migration was found in 2 cases in PE-TLIF group 6 months postoperatively, but interbody vertebral bone fusion was achieved 1 year after surgery. One case in MIS-TLIF group developed superficial surgical incision infection and the incision healed well after antibiotics and drainage therapy. Our study shows a higher incidence of complications in PE-TLIF group, which may be mainly related to the narrow operating space and a steeper learning curve. The interbody vertebral fusion rate was 89.74% in PE-TLIF group and 95.35% in MIS-TLIF group. This may be associated with the implantation of allografts in PE-TLIF surgery. No incurable complications were found in both groups.

This study revealed the strengths and weaknesses of PE-TLIF and MIS-TLIF in the treatment of LDH accompanied by lumbar instability, which has some clinical instructive significance, but also has some study limitations. First, the postoperative follow-up period was relatively short in this study. Thus, the long-term effects of the two surgical techniques remain uncertain. Secondly, the degeneration of adjacent segments was not included in this study. Third, the financial cost of the two treatments was not documented. Moreover, the therapeutic effects of PE-TLIF and MIS-TLIF on patients of different sexes and prominent types have not been intensively explored. The sample included in present study is relatively small, the follow-up time is short, and additional clinical studies with large-scale and longer-term follow-up clinical studies are still needed.

## Conclusions

In conclusion, based on our results, PE-TLIF surgery and MIS-TLIF surgery both have obvious clinical efficacy and safety as a minimally invasive surgery for middle-aged and elderly patients with single-level lumbar disc herniation accompanied by lumbar instability, and there are certain advantages and disadvantages. PE-TLIF is inferior to MIS-TLIF in the operation time and complications rates, while PE-TLIF outperforms MIS-TLIF in the length of hospital stay, time to ambulation after surgery, time to back to work or normal life, intraoperative blood loss, and postoperative volume of drainage. In summary, we believe that PE-TLIF may be a better choice for middle-aged and elderly patients with single-level lumbar disc herniation. Further investigation with large-scale and longer-term follow-up is necessary.

## Ethics Approval and Consent to Participate

The studies involving patients were approved by The Ethics Committee of the Affiliated Lianyungang Hospital of Xuzhou Medical University. The participants provided their written informed consent to participate in this study. This study was conducted in accordance with the Declaration of Helsinki.

## Author Contributions

All authors made a significant contribution to the work reported, whether that is in the conception, study design, execution, acquisition of data, analysis and interpretation, or in all these areas; took part in drafting, revising or critically

reviewing the article; gave final approval of the version to be published; have agreed on the journal to which the article has been submitted; and agree to be accountable for all aspects of the work.

## Funding

This research received no specific grant from any funding agency in the public, commercial, or not-for-profit sectors.

## Disclosure

The authors declare no conflicts of interest for this work.

## References

1. Puta C, Franz M, Blume KR, Gabriel HH, Miltner WH, Weiss T. Are there abnormalities in peripheral and central components of somatosensory evoked potentials in non-specific chronic low back pain? *Front Hum Neurosci.* 2016;10:521. doi:10.3389/fnhum.2016.00521
2. Wettstein M, Eich W, Bieber C, Tesarz J. Pain intensity, disability, and quality of life in patients with chronic low back pain: does age matter? *Pain Med.* 2019;20:464–475. doi:10.1093/pm/pny062
3. Fernandez M, Moore C, Peng W, et al. The profile of chiropractors managing patients with low back-related leg pain: analyses of 1907 chiropractors from the ACORN practice-based research network. *Chiropr Man Therap.* 2019;27:19. doi:10.1186/s12998-019-0239-x
4. Wang JC, Dailey AT, Mummaneni PV, et al. Guideline update for the performance of fusion procedures for degenerative disease of the lumbar spine. Part 8: lumbar fusion for disc herniation and radiculopathy. *J Neurosurg Spine.* 2014;21:48–53. doi:10.3171/2014.4.SPINE14271
5. Li L, Liu Y, Zhang P, Lei T, Li J, Shen Y. Comparison of posterior lumbar interbody fusion with transforaminal lumbar interbody fusion for treatment of recurrent lumbar disc herniation: a retrospective study. *J Int Med Res.* 2016;44:1424–1429. doi:10.1177/0300060516645419
6. Zhao J, Zhang S, Li X, He B, Ou Y, Jiang D. Comparison of minimally invasive and open transforaminal lumbar interbody fusion for lumbar disc herniation: a retrospective cohort study. *Med Sci Monit.* 2018;24:8693–8698. doi:10.12659/MSM.912808
7. Ao S, Zheng W, Wu J, et al. Comparison of Preliminary clinical outcomes between percutaneous endoscopic and minimally invasive transforaminal lumbar interbody fusion for lumbar degenerative diseases in a tertiary hospital: is percutaneous endoscopic procedure superior to MIS-TLIF? A prospective cohort study. *Int J Surg.* 2020;76:136–143. doi:10.1016/j.ijssu.2020.02.043
8. Zhu L, Cai T, Shan Y, Zhang W, Zhang L, Feng X. Comparison of clinical outcomes and complications between percutaneous endoscopic and minimally invasive transforaminal lumbar interbody fusion for degenerative lumbar disease: a systematic review and meta-analysis. *Pain Physician.* 2021;24:441–452.
9. Kambin P. Arthroscopic microdiscectomy. *Mt Sinai J Med.* 1991;58:159–164.
10. He EX, Guo J, Ling QJ, Yin ZX, Wang Y, Li M. Application of a narrow-surface cage in full endoscopic minimally invasive transforaminal lumbar interbody fusion. *Int J Surg.* 2017;42:83–89. doi:10.1016/j.ijssu.2017.04.053
11. Ahn Y, Youn MS, Heo DH. Endoscopic transforaminal lumbar interbody fusion: a comprehensive review. *Expert Rev Med Devices.* 2019;16:373–380. doi:10.1080/17434440.2019.1610388
12. Wang MY, Grossman J. Endoscopic minimally invasive transforaminal interbody fusion without general anesthesia: initial clinical experience with 1-year follow-up. *Neurosurg Focus.* 2016;40:E13. doi:10.3171/2015.11.FOCUS15435
13. Yang Y, Liu B, Rong L-M, et al. Microendoscopy-assisted minimally invasive transforaminal lumbar interbody fusion for lumbar degenerative disease: short-term and medium-term outcomes. *Int J Clin Exp Med.* 2015;8:21319–21326.
14. Yuan C, Wang J, Zhou Y, Pan Y. Endoscopic lumbar discectomy and minimally invasive lumbar interbody fusion: a contrastive review. *Wideochirurgia i inne techniki maloinwazyjne = Videosurg Other Miniinvasive Tech.* 2018;13:429–434. doi:10.5114/wiitm.2018.77744
15. Foley KT, Holly LT, Schwender JD. Minimally invasive lumbar fusion. *Spine.* 2003;28:S26–35. doi:10.1097/01.BRS.0000076895.52418.5E
16. Lv Y, Chen J, Chen J, et al. Three-year postoperative outcomes between MIS and conventional TLIF in 1-segment lumbar disc herniation. *Minim Invasive Ther Allied Technol.* 2017;26:168–176. doi:10.1080/13645706.2016.1273837
17. Zhao CQ, Ding W, Zhang K, Zhao J. Transforaminal lumbar interbody fusion using one diagonal fusion cage with unilateral pedicle screw fixation for treatment of massive lumbar disc herniation. *Indian J Orthop.* 2016;50:473–478. doi:10.4103/0019-5413.189595
18. Ren W, Chen Y, Xiang L. Minimally invasive surgical techniques for the therapy of far lateral disc herniation in middle-aged and elderly patients. *Comput Assist Surg.* 2019;24:13–19. doi:10.1080/24699322.2018.1557897
19. Wong AP, Smith ZA, Stadler JA, et al. Minimally invasive transforaminal lumbar interbody fusion (MI-TLIF): surgical technique, long-term 4-year prospective outcomes, and complications compared with an open TLIF cohort. *Neurosurg Clin N Am.* 2014;25:279–304. doi:10.1016/j.nec.2013.12.007
20. Wang YP, An JL, Sun YP, Ding WY, Shen Y, Zhang W. Comparison of outcomes between minimally invasive transforaminal lumbar interbody fusion and traditional posterior lumbar intervertebral fusion in obese patients with lumbar disk prolapse. *Ther Clin Risk Manag.* 2017;13:87–94. doi:10.2147/TCRM.S117063
21. Chen Y-C, Zhang L, Li E-N, et al. An updated meta-analysis of clinical outcomes comparing minimally invasive with open transforaminal lumbar interbody fusion in patients with degenerative lumbar diseases. *Medicine.* 2019;17:98. doi:10.1186/s12916-019-1332-7
22. Emami A, Faloon M, Issa K, et al. Minimally invasive transforaminal lumbar interbody fusion in the outpatient setting. *Orthopedics.* 2016;39:e1218–e22. doi:10.3928/01477447-20160721-04
23. Badlani N, Yu E, Kreitz T, Khan S, Kurd MF. Minimally Invasive Transforaminal Lumbar Interbody Fusion (TLIF). *Clin Spine Surg.* 2020;33:62–64. doi:10.1097/BSD.0000000000000902
24. Wang YT, Wu XT, Chen H, Wang C. Endoscopy-assisted posterior lumbar interbody fusion in a single segment. *J Clin Neurosci.* 2014;21:287–292. doi:10.1016/j.jocn.2013.04.039
25. Liu C, Zhou Y. Comparison between percutaneous endoscopic lumbar discectomy and minimally invasive transforaminal lumbar interbody fusion for lumbar disc herniation with biradicular symptoms. *World Neurosurg.* 2018;120:e72–e9. doi:10.1016/j.wneu.2018.07.146

26. Wang A, Yu Z. Comparison of percutaneous endoscopic lumbar discectomy with minimally invasive transforaminal lumbar interbody fusion as a revision surgery for recurrent lumbar disc herniation after percutaneous endoscopic lumbar discectomy. *Ther Clin Risk Manag.* 2020;16:1185–1193. doi:10.2147/TCRM.S283652
27. Esses SI, Huler RJ. Indications for lumbar spine fusion in the adult. *Clin Orthop Relat Res.* 1992;279:87–100. doi:10.1097/00003086-199206000-00011
28. Kosztowski TA, Choi D, Fridley J, et al. Lumbar disc reherniation after transforaminal lumbar endoscopic discectomy. *Ann Transl Med.* 2018;6:106. doi:10.21037/atm.2018.02.26
29. Haddadi K, Abediankenari S, Alipour A, et al. Association between serum levels of interleukin-6 on pain and disability in lumbar disc herniation surgery. *Asian J Neurosurg.* 2020;15:15.
30. Weber KT, Alipui DO, Sison CP, et al. Serum levels of the proinflammatory cytokine interleukin-6 vary based on diagnoses in individuals with lumbar intervertebral disc diseases. *Arthritis Res Ther.* 2016;18:3. doi:10.1186/s13075-015-0887-8
31. Koerner JD, Markova DZ, Schroeder GD, et al. Correlation of early outcomes and intradiscal interleukin-6 expression in lumbar fusion patients. *Neurospine.* 2020;17:36–41. doi:10.14245/ns.2040054.027
32. Thelander U, Larsson S. Quantitation of C-reactive protein levels and erythrocyte sedimentation rate after spinal surgery. *Spine.* 1992;17:400–404. doi:10.1097/00007632-199204000-00004
33. Kraft CN, Kruger T, Westhoff J, et al. CRP and leukocyte-count after lumbar spine surgery: fusion vs. *Nucleotomy Acta Orthop.* 2011;82:489–493. doi:10.3109/17453674.2011.588854
34. Kumbhare D, Parkinson W, Dunlop B. Validity of serum creatine kinase as a measure of muscle injury produced by lumbar surgery. *J Spinal Disord Tech.* 2008;21:49–54. doi:10.1097/BSD.0b013e31805777fb
35. Wang W, Sun X, Zhang T, Sun S, Kong C, Topping-Off LS. Technology versus posterior lumbar interbody fusion in the treatment of lumbar disc herniation: a meta-analysis. *Biomed Res Int.* 2020;2020:2953128. doi:10.1155/2020/2953128
36. Zhao XB, Ma HJ, Geng B, Zhou HG, Xia YY. Early clinical evaluation of percutaneous full-endoscopic transforaminal lumbar interbody fusion with pedicle screw insertion for treating degenerative lumbar spinal stenosis. *Orthop Surg.* 2021;13:328–337. doi:10.1111/os.12900
37. Jing Z, Li L, Song J. Percutaneous transforaminal endoscopic discectomy versus microendoscopic discectomy for upper lumbar disc herniation: a retrospective comparative study. *Am J Transl Res.* 2021;13:3111–3119.

Journal of Pain Research

Dovepress

## Publish your work in this journal

The Journal of Pain Research is an international, peer reviewed, open access, online journal that welcomes laboratory and clinical findings in the fields of pain research and the prevention and management of pain. Original research, reviews, symposium reports, hypothesis formation and commentaries are all considered for publication. The manuscript management system is completely online and includes a very quick and fair peer-review system, which is all easy to use. Visit <http://www.dovepress.com/testimonials.php> to read real quotes from published authors.

Submit your manuscript here: <https://www.dovepress.com/journal-of-pain-research-journal>