

Contents lists available at [ScienceDirect](http://www.sciencedirect.com)

## International Journal of Surgery Case Reports

journal homepage: [www.casereports.com](http://www.casereports.com)

# Unstable thoracic spine fracture with aortic encroachment: A potentially fatal association and a suggested treatment



Francesco Cultrera<sup>a</sup>, Emiliano Gamberini<sup>b,\*</sup>, Gustavo Iacono<sup>c</sup>, Giorgio Ubaldo Turicchia<sup>c</sup>, Vanni Agnoletti<sup>b</sup>, Luigino Tosatto<sup>a</sup>

<sup>a</sup> Neurosurgery Department, Romagna Trauma Center “Maurizio Bufalini” Hospital, Viale Ghirotti 286, 47521, Cesena, Italy

<sup>b</sup> Anesthesia and Intensive Care Department, Romagna Trauma Center “Maurizio Bufalini” Hospital, Viale Ghirotti 286, 47521, Cesena, Italy

<sup>c</sup> Vascular Surgery Department, Romagna Trauma Center “Maurizio Bufalini” Hospital, Viale Ghirotti 286, 47521, Cesena, Italy

## ARTICLE INFO

## Article history:

Received 18 May 2017

Received in revised form 9 August 2017

Accepted 9 August 2017

Available online 18 August 2017

## Keywords:

Case report

Spinal injury

Aorta

Endovascular procedure

Fracture fixation

Trauma team

Trauma center

## ABSTRACT

**BACKGROUND:** The coexistence of an unstable spinal fracture with a pending aortic lesion is potentially catastrophic and a therapeutic challenge as to timing of treatment, assigning priorities and selecting the best approach.

**CASE REPORT:** A 41 year-old healthy male victim of bike accident. Imaging revealed a fracture of 6th and 7th thoracic vertebrae with a bone fragment in close proximity to the descending thoracic aorta. After consultation with spine/vascular surgeons and interventional radiologists it was decided to secure the potential aortic injury with an endovascular stent-graft followed by posterior vertebral instrumentation for fracture's reduction.

**DISCUSSION/CONCLUSION:** A multi-specialists teamwork approach is mandatory. Vascular lesion is priority, followed by vertebral surgery. As to the treatment options, we suggest a “best but still safest” philosophy: endovascular repair and posterior spinal instrumentation should be considered first in the acute stage.

© 2017 The Authors. Published by Elsevier Ltd on behalf of IJS Publishing Group Ltd. This is an open access article under the CC BY-NC-ND license (<http://creativecommons.org/licenses/by-nc-nd/4.0/>).

## 1. Introduction

Traumatic aortic rupture (TAR) is often fatal (up to 85% pre-hospital mortality) with the thoracic descending segment most frequently affected [1–3]. In hospitalized patients one can observe an association between spinal fractures and aortic lesions [4,5]. In such cases direct trauma to the aorta may be the result of fracture “per se” or it may secondarily complicate surgery for fracture's reduction [6].

While several papers describe the occurrence and treatment of aortic lesions secondary to spinal surgery [7–11] there are few reports focusing on the management of unstable vertebral column fractures with a concomitant or potential aortic injury [3,6,12–14]. Such cases pose a real therapeutic dilemma as to the optimal timing for treatment, the priorities to be assigned and the most adequate procedures to be adopted. The decision-making process requires a close multidisciplinary cooperation between spine/vascular sur-

geons and interventional radiologists with proper consideration given to individual cases [6,7,9,10]. The actual or potential vascular lesion takes absolute precedence [3,6,7,12,14]. Open, direct surgical repair (via thoracotomy) and endovascular treatment are alternative options followed by surgical reduction of the fracture. There are no clear guidelines as to the best therapeutic choice [6,10,13] although endovascular treatment has gained widespread use in recent years [1,2,3,8,10]. The decision should be made balancing the risks of each procedure versus the clinical condition of the patient to be treated. We report a case of traumatic dorsal column fracture with a fragment encroaching on the descending thoracic aorta. The adopted treatment is discussed with an effort to derive suggestions as to the best management of analogue cases.

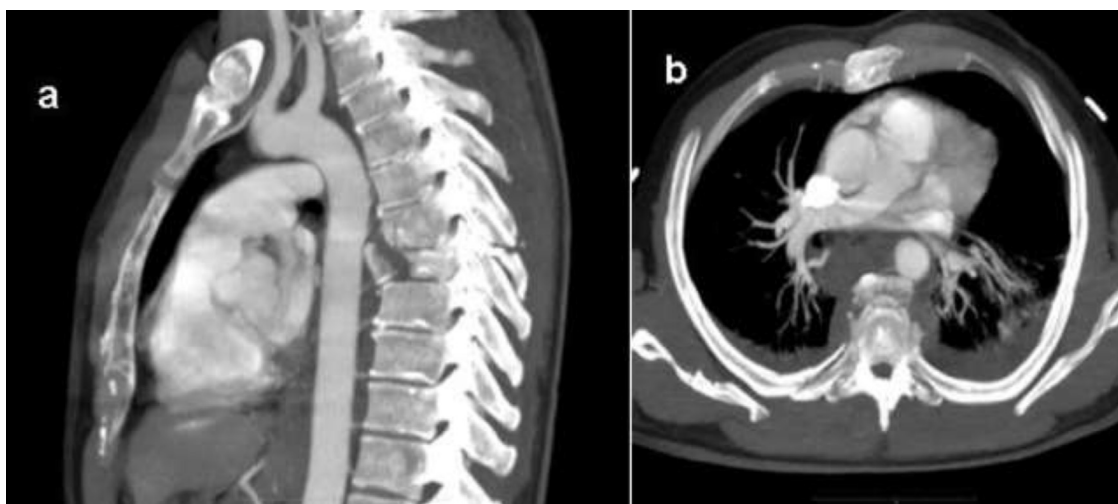
This work has been reported in line with the SCARE criteria [11].

## 2. Case description

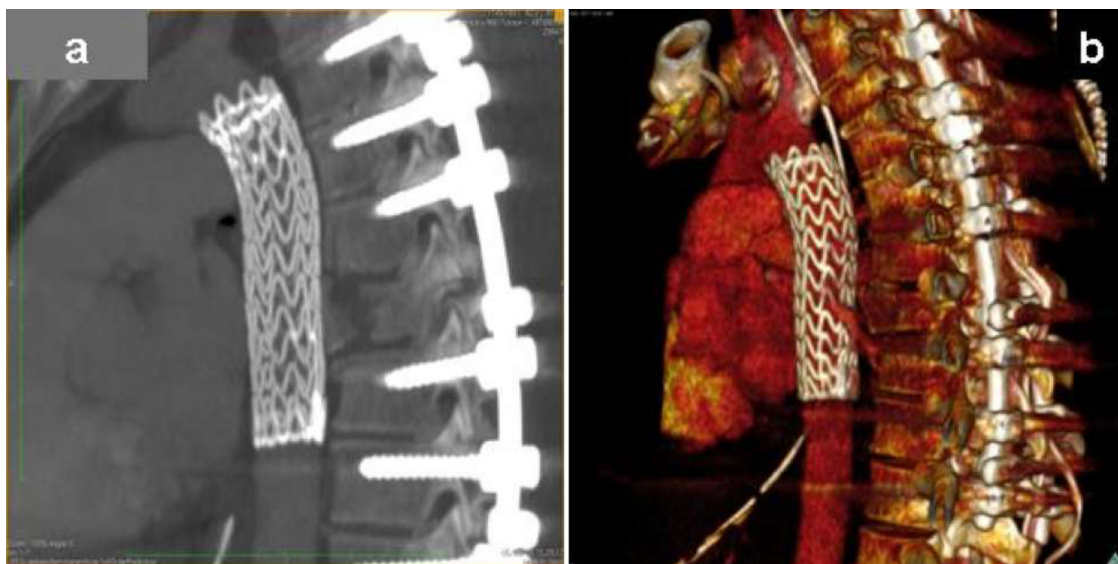
A 41 year-old healthy male referred to our hospital after bike accident. No neuro-deficits detected. After intubation, a total-body CT scan and CT-angiography revealed a compression/distraction fracture of 6th and 7th dorsal vertebrae with a fracture fragment in close proximity to the descending thoracic aorta, although without signs of wall's disruption (Fig. 1). Other injuries included: atlas and multiple ribs fractures, bilateral pleural effusion, left pneumothorax and mediastinal hematoma. After multi-specialists

\* Corresponding author.

E-mail addresses: [francesco.cultrera@auslromagna.it](mailto:francesco.cultrera@auslromagna.it) (F. Cultrera), [emiliano.gamberini@auslromagna.it](mailto:emiliano.gamberini@auslromagna.it), [egamberini74@gmail.com](mailto:egamberini74@gmail.com) (E. Gamberini), [gustavo.iacono@auslromagna.it](mailto:gustavo.iacono@auslromagna.it) (G. Iacono), [giorgioubaldo.turicchia@auslromagna.it](mailto:giorgioubaldo.turicchia@auslromagna.it) (G.U. Turicchia), [vanni.agnoletti@auslromagna.it](mailto:vanni.agnoletti@auslromagna.it) (V. Agnoletti), [marcello.bisulli@auslromagna.it](mailto:marcello.bisulli@auslromagna.it) (L. Tosatto).



**Fig. 1.** Sagittal (a) and axial (b) CT-angiography: compression/distraction fracture of 6th and 7th dorsal vertebrae. A bone fragment is encroaching on the descending thoracic aorta although without signs of wall disruption (i.e. absent peri-vascular contrast leakage). A 3-D volume rendering reconstruction (c) confirms integrity of the aortic walls.



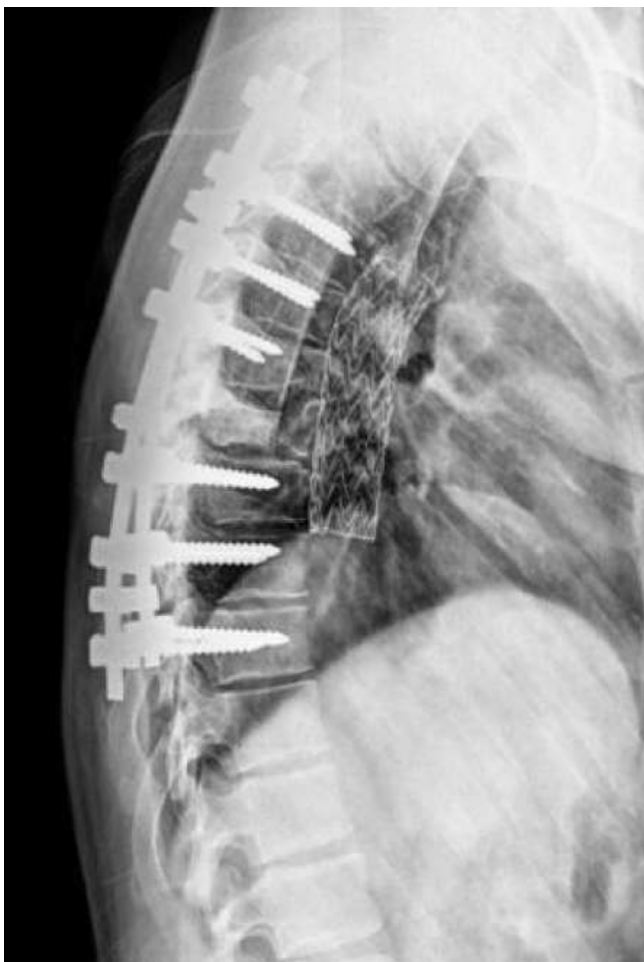**Fig. 2.** Post-treatment CT-angiography: sagittal (a) and 3-D reconstruction views (b): aortic stent-graft in place with posterior instrumentation of the spine.

consultation it was decided to “secure” the thoracic aorta first and to carry on surgery of the spine successively. Preference was given to endovascular treatment: trauma team vascular surgeon performed an arterial trans-femoral access (GORE TAG, 26-26-100) and deployed a stent-graft into the Th4-8 segment of the thoracic aorta. Aortography confirmed adequate positioning and fitting of the stent graft with patent vascular branches. Trauma team neurosurgeon then stabilized dorsal spine with posterior instrumentation (Th3-Th10 fixation). The patient made a good recovery with uneventful postoperative courses and was discharged with short-term anti-platelet therapy. Follow-up imaging (at 1, 3 and 6 months) shows no further dislodgment of fracture with satisfactory bony healing as well as absence of stent complications (Figs. 2 and 3).

### 3. Discussion

TAR is a leading cause of death with up to 85% pre-hospital mortality [1–3]. Among hospitalized patients one can observe an association between aortic lesions and unstable spinal fractures requiring surgery. In such cases direct trauma to the aorta may

be the result of the fracture “per se” or it may secondarily complicate surgery for fracture’s reduction [6], making them a true challenge-to-treat in terms of priority, timing, choice of approach. While several authors describe iatrogenic aortic injuries following spinal surgery [6–10,12] only a few focus on the management of unstable vertebral column fractures with concomitant or potential aortic lesions [3,6,13–15]. Although reports are anecdotal one can attempt to get some statements. The depicted 5, 5% incidence of TAR with Th1-8 segment fractures [4] is probably underestimated [6]. Of notice, aortic lesions may manifest acutely but also evolve with pseudoaneurysm formation and delayed bleeding. In the setting of severe trauma patients, aortic injuries must therefore be always ruled out with appropriate imaging (CT +/- conventional angiography, MRI) [2,5,6,9]. If actual or potential aortic lesions and unstable spinal fractures coexist, the former takes absolute priority in the treatment schedule and should be addressed “as soon as possible” relatively to patient’s condition [1,3,7,13,15]. At this time, a multidisciplinary evaluation involving spine/vascular surgeons, interventional radiologists and ICU specialists becomes mandatory [6,7]. Direct, open surgical repair (via thoracotomy) has been gold standard for years but it’s burdened with a fairly high rate



**Fig. 3.** Lateral X-ray projection at 6 months: no further dislodgment of fracture with satisfactory bony healing as well as absence of stent complications are seen.

of related morbidity: ventilatory dysfunction, pneumonia, renal failure and -most feared- ischemic damage to spinal cord with transient or permanent sequelae are all reported. Furthermore, in the setting of severely ill, multiple-trauma patient, its use may be hardly desirable (i.e. avoid single lung ventilation in the presence of pulmonary lesions). With specific regard to coexisting vertebral column fractures, the lateral decubitus required for thoracotomy may aggravate spinal instability leading to cord damage [1,2,7,10]. Conversely, an anterior approach seems justified when anterior vertebral column reconstruction or bony fragment removal are planned at the same stage, though the need for additional posterior instrumentation could be a concern [12,13]. In recent years, thoracic endovascular aortic repair (TEVAR) has gained widespread popularity leading to a paradigm shift in favour of this technique [1]: “minimal” invasiveness (shorter procedural time, supine decubitus, decreased hospital stay,) and a relevantly lower rate of intrinsic complications (no respiratory failure, no need for vascular clamping) are obvious advantages. Potential disadvantages are linked with individual vascular anatomy preventing optimal stent positioning or posing aortic branches at risk (careful pre-treatment evaluation), risk of “endoleak” (graft “not fitting” inside aortic walls) and, in the long-term, stent mobilization or fracture. As a consequence, periodic imaging follow-up (CT-angiography and X-rays) with a potentially lifelong increased radiation exposure, together with the eventual use of anti-platelet agents deserve consideration [1,2]. Nevertheless TEVAR is nowadays suggested as a first option for severely-ill patients as those harbouring multiple lesions like

concomitant unstable vertebral fractures [1,2,3,7,8]. Once the aortic lesion is secured, surgery for the spinal fracture may be undertaken. At our department unstable vertebral fractures are usually treated with posterior stabilization at first stage. Anterior approaches are reserved to selected cases or as a second tier surgery (e.g. failure of posterior construct). Posterior approaches with prone decubitus could end up in a disaster when aortic injuries are pending. In our case, we could have risked additional aortic mechanical compression and/or bone fragment dislodgment leading to intraoperative rupture and massive bleeding. This again underscores the importance of treating first any actual or potential vascular injury and of multidisciplinary teamwork. A criticism that could be raised toward our approach is that having left in place the anterior bone fragment could potentially risk a mechanical conflict between the fragment itself and the pulsatile stented aorta with delayed injury [12], hence the need for periodical imaging. On the other hand, it may be speculated that the anterior bony fragment would eventually undergo gradual resorption with time [16,17].

#### 4. Conclusion

Aortic lesions may be a more than expected occurrence in multiple trauma patients. In the event of coexisting unstable spinal fracture with actual or potential vascular injury some advices can be offered. A multi-specialist approach (with spine and vascular surgeons, interventional radiologist and ICU physician) is definitely mandatory. The vascular side takes absolute priority and only after treating or prophylactically securing the aorta could spinal surgery be undertaken. In the acute phase we suggest a “best but still safest” treatment philosophy, tailored on individual patient’s condition but with preference given to less invasive methods (endovascular repair recommended as first line, allowing for posterior vertebral instrumentation to be performed harmlessly).

#### Conflict of interest

None.

#### Funding

No funding has been received for this work.

#### Ethical approval

This case report did not involve any research activity. Ethical approval from institutional committee was not required.

#### Consent

Written informed consent was obtained from the patient for publication of this case-report and accompanying images. A copy of the written consent is available for review by the Editor-in Chief of this journal upon request.

FC: bibliography collection, conceiving and writing of the report.

EG: patient’s data collection, report’s supervision and designing, manuscript’s preparation.

GI: patient’s data collection, bibliography collection, co-writing of the report, images’ selection.

GUT: report’s supervision and coordination.

VA: designing and supervision of the report.

LT: report’s supervision and coordination, selection of references.

## Financial disclosure

The authors declare that they haven't any financial involvement of any sort.

## Registration of research studies

No research was undertaken for this paper.

## Guarantor

Guarantor for this work is Emiliano Gamberini.

## References

- [1] G.W. Leong-Tan, C.H. Pek, D. Wong, S. Punamiya, M.T. Chiu, V. Appasamy, K.H. Chia, C.W. Lee, Management of blunt traumatic thoracic aorta injuries with endovascular stent-grafts in a tertiary hospital in Asian city, *Ann. Vasc. Surg.* 25 (2011) 605–611.
- [2] P.J. Riesenman, M.A. Farber, P.B. Rich, B.C. Sheridan, R.R. Mendes, W.A. Marston, B.A. Keagy, Outcomes of surgical and endovascular treatment of acute traumatic thoracic aortic injury, *J. Vasc. Surg.* 46 (2007) 934–940.
- [3] M.M. Chock, J. Aho, N. Naik, M. Clarke, S. Heller, G.S. Oderich, Endovascular treatment of distal thoracic aortic transection associated with severe thoracolumbar spine fracture, *Vascular* 23 (2015) 550–552.
- [4] J.T. Sturm, J.T. Hynes, J.F. Pery jr., Thoracic spinal fractures and aortic rupture: a significant and fatal association, *Ann. Thorac. Surg.* 50 (1990) 931–933.
- [5] C. de Mestral, A.D. Dueck, D. Gomez, B. Haas, A.B. Nathens, Associated injuries, management, and outcomes of blunt abdominal aortic injury, *J. Vasc. Surg.* 56 (2012) 656–660.
- [6] R. Kopp, R. Beisse, R. Weidenhagen, S. Plitz, S. Hauck, C.R. Becker, O. Pieske, V. Bühren, K.W. Jauch, L. Lauterjung, Strategies for prevention and operative treatment of aortic lesions related to spinal interventions, *Spine* 32 (2007) 753–760; Y. Yoshioka, Y. Morimoto, T. Sugimoto, H. Arase, K. Araki, Blunt abdominal aortic injury associated with L2 vertebral fracture, *Ann. Vasc. Surg.* (2016) 34, 273e1–3.
- [7] K. Watanabe, A. Yamazaki, T. Hirano, T. Izumi, A. Sano, O. Morita, R. Kikuchi, T. Ito, Descending aortic injury by a thoracic pedicle screw during posterior reconstructive surgery. A case report, *Spine* 20 (2010) 1064–1068.
- [8] A. Salsano, G. Salsano, F. Petrocelli, G. Passerone, C. Ferro, F. Santini, A nearly missed catastrophic aortic injury after reduction of a thoracic spine fracture managed by prompt endovascular treatment, *Ann. Thorac. Surg.* 100 (2015) 1112.
- [9] A. Carmignani, S. Lentini, E. Aciri, G. Vazzana, M. Campello, P. Volpe, I.E. Aciri, F. Spinelli, Combined thoracic endovascular aortic repair and neurosurgical intervention for injury due to posterior spine surgery, *J. Card. Surg.* 28 (2013) 163–167.
- [10] S. Decker, M. Omar, C. Kettek, C.W. Müller, Elective thoracotomy for pedicle screw removal to prevent severe aortic bleeding, *World J. Clin. Cases* 2 (2014) 100–103.
- [11] R.A. Agha, A.J. Fowler, A. Saetta, I. Barai, S. Rajmohan, D.P. Orgill, for the SCARE Group, The SCARE statement: consensus-based surgical case report guidelines, *Int. J. Surg.* 34 (October) (2016) 180–186.
- [12] A. Freyre, A. Gasbarrini, C.E. Simoes, E. Gallitto, M. Gargiulo, Delayed presentation of a thoracic aortic injury with a vertebral pedicle screw, *Ann. Vasc. Surg.* 27 (2013) (499e1–3).
- [13] F.C. Bakker, P. Patka, H.J. Haarman, Combined repair of a traumatic rupture of the aorta and anterior stabilization of a thoracic spine fracture: a case report, *J. Trauma* 40 (1996) 128–129.
- [14] Y. Yoshioka, Y. Morimoto, T. Sugimoto, H. Arase, K. Araki, Blunt abdominal aortic injury associated with L2 vertebral fracture, *Ann. Vasc. Surg.* 34 (2016) (273e1–3).
- [15] M. Domenicucci, A. Ramieri, A. Landi, A.G. Melone, A. Raco, M. Ruggiero, F. Speciale, Blunt abdominal aortic disruption (BAAD) in shear fracture of the adult thoraco-lumbar spine: case report and literature review, *Eur. Spine J.* 20 (2011) S314–S319.
- [16] S.P. Mohanty, The effect of posterior instrumentation of the spine on canal dimensions and neurological recovery in thoracolumbar and lumbar burst fractures, *Musculoskelet. Surg.* 95 (2011) 101–106.
- [17] R. Scapinelli, S. Candiotti, Spontaneous remodeling of the spinal canal after burst fractures of the low thoracic and lumbar region, *J. Spinal Disord.* 8 (1995) 486–493.

## Open Access

This article is published Open Access at [sciedirect.com](http://sciedirect.com). It is distributed under the [IJSCR Supplemental terms and conditions](#), which permits unrestricted non commercial use, distribution, and reproduction in any medium, provided the original authors and source are credited.