



Original Article

Relationship of age and type of obstetric brachial plexus paralysis in forearm pronosupination[☆]



Yussef Ali Abdouni^{a,*}, Gabriel Faria Checoli^a, Valdênia das Graças Nascimento^b, Antonio Carlos da Costa^a, Ivan Chakkour^a, Patricia Maria de Moraes Barros Fucs^a

^a Faculdade de Ciências Médicas da Santa Casa de São Paulo, Departamento de Ortopedia e Traumatologia, São Paulo, SP, Brazil

^b Universidade Federal do Triângulo Mineiro, Departamento de Ortopedia e Traumatologia, Uberaba, MG, Brazil

ARTICLE INFO

Article history:

Received 29 June 2016

Accepted 22 August 2016

Available online 23 August 2017

Keywords:

Brachial plexus

Obstetric paralysis

Supination

Forearm

Palavras-chave:

Plexo braquial

Paralisia obstétrica

Supinação

Antebraço

ABSTRACT

Objective: To evaluate the arc of forearm pronosupination of patients with sequelae of birth paralysis and correlate with these variables.

Methods: 32 children aged between 4 and 14 years with total or partial lesions of the brachial plexus were evaluated; measurements of pronation and supination, active and passive, were made, both on the injured side and the unaffected side.

Results: A statistically significant difference was observed between the injured side and the normal side, but there was no difference between the groups regarding age or type of injury.

Conclusion: The age and type of injury did not impact on the limitation of the forearm pronosupination in children with sequelae of birth paralysis.

© 2016 Sociedade Brasileira de Ortopedia e Traumatologia. Published by Elsevier Editora Ltda. This is an open access article under the CC BY-NC-ND license (<http://creativecommons.org/licenses/by-nc-nd/4.0/>).

Relação entre a idade e o tipo de paralisia obstétrica do plexo braquial com o movimento de pronosupinação do antebraço

RESUMO

Objetivo: Avaliar o arco de pronosupinação do antebraço dos pacientes com sequela de paralisia obstétrica do plexo braquial e correlacionar com essas variáveis.

Métodos: Foram avaliadas 32 crianças entre 4 e 14 anos, com lesões totais ou parciais do plexo braquial, foram tiradas as medidas de pronação e supinação, ativa e passiva, tanto do lado lesionado quanto do lado não afetado.

Resultados: Observou-se diferença estatisticamente significativa entre o lado lesionado e o lado normal, porém não houve diferença entre os grupos por faixas etárias, nem quanto ao tipo de lesão.

[☆] Paper developed at Hospital da Irmandade da Santa Casa de São Paulo, Departamento de Ortopedia e Traumatologia, São Paulo, SP, Brazil.

* Corresponding author.

E-mail: dr.yussefali@gmail.com (Y.A. Abdouni).

<http://dx.doi.org/10.1016/j.rboe.2017.08.006>

2255-4971/© 2016 Sociedade Brasileira de Ortopedia e Traumatologia. Published by Elsevier Editora Ltda. This is an open access article under the CC BY-NC-ND license (<http://creativecommons.org/licenses/by-nc-nd/4.0/>).

Conclusão: Os fatores idade e tipo de lesão não tiveram efeito sobre a pronossupinação nas crianças portadoras de seqüela de paralisia obstétrica do plexo braquial.

© 2016 Sociedade Brasileira de Ortopedia e Traumatologia. Publicado por Elsevier Editora Ltda. Este é um artigo Open Access sob uma licença CC BY-NC-ND (<http://creativecommons.org/licenses/by-nc-nd/4.0/>).

Introduction

Brachial plexus lesion in newborns occurs during the period of delivery, and is often associated with shoulder dystocia, gestational or pre-gestational diabetes, and macrosomic fetuses, or even low-weight children with pelvic presentation. The first clinical description occurred in 1764, when Smellie reported bilateral paralysis in a pelvic newborn. However, the term obstetric paralysis was attributed to Duchenne in 1872. It is characterized by a flaccid paralysis, which affects the limb partially or totally, depending on the number of roots involved.

The incidence of obstetric brachial plexus paralysis (OBPP) in the United States is 0.38–2.6 per one thousand full-term children, affecting both genders equally. In spite of advances in obstetrics, this incidence has not been reduced.¹

Narakas² classified the children with OBPP into four groups: group 1 with lesions of only C5 and C6 (extended Erb) roots, group 2 with involvement of C5, C6 and C7 roots (extended Erb), group 3 with lesions of all plexus roots, and group 4 that has the Claude Bernard-Horner sign associated with the total lesion.

Most OBPP patients have spontaneous recovery; it is greater than 80% in groups 1 and 2.^{2,3} Normal limb function is expected if recovery occurs in the first four years of life. However, in a considerable portion, such recovery will not occur.⁴ Residual paralysis and its sequelae in daily life activities are related to the severity of the initial injury, and may range from minimal loss of upper limb function to complete paralysis.⁵

Patients with proximal root lesions (C5, C6, C7) or with total brachial plexus lesions who had partial recovery tend to develop a deformity in supination of the forearm over time, due to the imbalance between the active supination muscles and paralyzed pronator muscles. This imbalance occurs because the biceps, innervated by the musculocutaneous nerve, and the supinator, innervated by the radial nerve recover, while the pronators teres and quadratus, innervated by the median nerve do not usually recover.⁵⁻⁷ Initially, the deformity can be corrected passively, but with development, the deformity becomes fixed due to the contracture of the interosseous membrane. The hand assumes a position in supination and hyperextension, aggravated by the lack of wrist flexors.

Bahm and Gilbert,⁶ Zancolli,⁸ Masse,⁹ Manske et al.,¹⁰ among other authors, recommend tendon transfers in the initial phases, when the deformity is not yet fixed.

Kapandji¹¹ described a progressive radius deformity, in which its curvature was not formed due to the paralysis of the pronator musculature, which further limited the pronation.

When a fixed deformity already exists, the pronation osteotomy of the forearm is used to achieve a better positioning of the hand, thus conferring greater use to the affected limb.¹¹⁻¹³

The aim of this study was to evaluate the degree of forearm pronosupination in children with OBPP sequelae, and to correlate the deformity with the type of lesion and the age group.

Material and method

This paper was approved by the Ethics Committee of the institution under number CAAE-03724712.1.0000.5479.

A retrospective cross-sectional study was carried out, in which 36 children with OBPP and upper trunk lesions (C5 and C6), upper and medium trunk (C5, C6 and C7) or total lesions who had partial recovery and who had not undergone a surgical procedure on the forearm were evaluated between July and December 2012. Three children with associated cerebral palsy, and one child with bilateral brachial plexus lesion were excluded.

The passive (PS) and active (AS) supination degrees, and passive (PP) and active (AP) pronation degrees were measured on the injured and normal sides. Measurements were taken when the child kept the shoulder near the trunk, and with the elbow at 90 degrees; this was always performed by the same evaluator, with the aid of a goniometer and expressed in angle degrees. The results are shown in Table 1.

For statistical analysis, we used the software IBM-SPSS (Statistical Package for Social Sciences) version 17.0, and Excel Office 2010. We compared the measurements of the affected limb with those of the normal limb, with the anatomical classification, and with age. We used the paired Student t test to compare the affected limb and the normal limb measurements. In order to evaluate whether there was a relation of age or type of injury to the measurements performed on the injured side of these children, we used the Anova test (Analysis of variance). We also used the Kruskal-Wallis test to compare age groups, and the Mann-Whitney test to compare types of injury (total or partial). We consider $p < 0.05$ as statistical significant.

Results

Thirty-two children were selected for the study, 18 were male and 14 female. Regarding the affected side, 17 had lesions on the right side and 15 on the left side. The age ranged from four to 14 years, with an average of 7.6.

For statistical analysis, the children were divided into two groups according to the type of lesion: group 1 with partial lesions (11 patients) and group 2 with total lesions (21 patients) (Fig. 1). Regarding age, children were grouped into three age groups: range 1, from four to six years, range 2, from seven to nine years, and range 3, above 10 years (Fig. 2).

Table 1 – Demographic data of patients included in the study.

	Gender	Age	Type of lesion	PP-injured	PP-normal	AP-injured	AP-normal	PS-injured	PS-normal	AS-injured	AS-normal
1	M	6	2	-10	70	-50	70	90	90	90	90
2	F	6	2	0	70	-10	45	90	90	45	90
3	F	10	2	0	80	-20	70	90	90	90	90
4	F	7	2	20	90	10	90	90	90	60	90
5	M	11	1	20	35	15	35	90	90	45	90
6	F	11	1	10	80	0	80	80	80	40	80
7	M	7	1	-10	60	-30	60	90	90	90	90
8	M	10	2	30	80	-70	80	90	90	90	90
9	M	6	2	85	85	50	85	90	90	80	90
10	F	4	2	90	90	30	90	70	90	0	90
11	M	9	1	90	90	60	90	90	90	50	90
12	M	8	1	90	90	70	90	90	90	60	90
13	F	8	1	70	90	60	85	50	90	60	90
14	F	12	1	90	90	80	90	90	90	80	90
15	F	14	1	80	90	70	90	80	90	70	90
16	M	6	2	80	95	70	90	90	90	85	90
17	M	9	2	90	90	10	80	10	90	10	80
18	M	6	1	60	90	40	90	70	90	30	85
19	M	8	2	80	90	70	90	80	90	70	90
20	M	9	2	90	90	70	90	90	90	70	80
21	M	9	2	90	90	90	90	90	90	70	90
22	M	5	1	80	90	60	90	90	90	90	90
23	F	10	2	45	90	30	90	90	90	80	90
24	F	8	2	80	90	70	90	90	90	80	90
25	F	10	2	0	80	-70	80	90	90	90	90
26	F	6	2	70	80	60	70	80	90	40	90
27	F	5	2	50	80	30	75	40	80	20	70
28	M	6	2	70	80	60	70	80	90	40	90
29	M	4	2	60	90	40	85	85	90	45	90
30	F	7	1	50	90	40	80	60	90	30	90
31	M	4	2	50	90	30	90	80	90	40	90
32	F	7	1	80	90	60	80	80	90	70	80

AP, active pronation; PP, passive pronation; AS, active supination; SP, passive supination.

After statistical test application, a statistically significant difference was observed between the normal and affected sides in all measurements (Table 2).

Then, considering only the results on the injured side (Table 3) and the use of Anova, we compared the age groups

for each of the variables. We found that there is no mean difference between age groups, that is, there is no effect of age on PP, AP, PS and AS results.

Finally, we compared the type of lesions and, similarly, after the application of Anova, we concluded that there is no

Table 2 – Angulation values of the PP, AP, PS and AS movements, measured in the normal limb and on the affected side of all patients.

	Mean	Median	Standard deviation	VC	Min	Max	N	CI	p-Value
PP									
Injured	55.6	70	34.4	62%	-10	90	32	11.9	<0.001
Normal	83.9	90	11.8	14%	35	95	32	4.1	
PA									
Injured	32	40	43.1	135%	-70	90	32	14.9	<0.001
Normal	80.6	85	13.5	17%	35	90	32	4.7	
SP									
Injured	80.2	90	17.8	22%	10	90	32	6.2	0.005
Normal	89.4	90	2.5	3%	80	90	32	0.9	
SA									
Injured	59.7	65	25.4	43%	0	90	32	8.8	<0.001
Normal	88	90	4.7	5%	70	90	32	1.6	

VC, variation coefficient; CI, confidence interval; AP, active pronation; PP, passive pronation; AS, active supination; PS, passive supination.

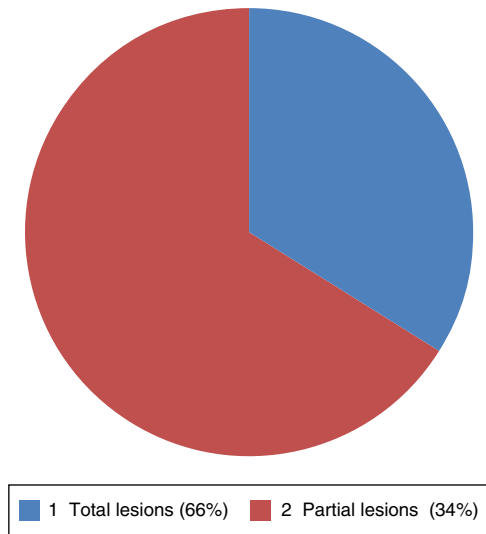


Fig. 1 - Distribution according to the type of lesion.

statistically significant mean difference between the groups with partial and total lesions for the evaluated variables. These results are expressed in Table 4.

Discussion

OBPP leads to anatomical alterations in the patients upper limbs, causing difficulty in daily life activities, besides esthetic damage.

Although a OBPP supination condition occurs more in total paralyzes, it has also been observed in patients with C5/C6/C7 paralyzes. In these cases, with the biceps impairment, the forearm remains supinated due to the action of the supinator muscle.

Yam et al.¹⁴ found a supination deformity incidence of 6.9%. They also observed that this condition was not present

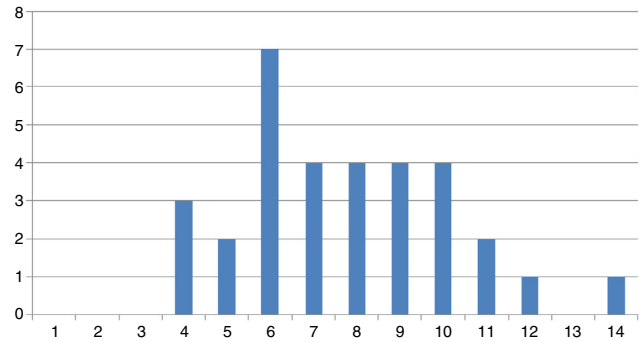


Fig. 2 - Distribution according to age group.

in patients in group I of Narakas. In type II, supination contracture occurred in 5.7% of patients, 9.6% in type III and 23.4% in type IV. Our study did not assess the incidence of deformity but agrees with Yam’s article because it did not find the deformity in Narakas group I. However, we did not observe a significant difference between the lesions of group II and total lesions.

Bahm and Gilbert⁶ and Zancolli⁸ affirm that the deformity is progressive and becomes fixed with age. Zancolli⁸ relates the fixed deformity with interosseous membrane contracture. In our series, 13 patients presented passive pronation that was lower than or equal to 50° (40.6%), between four and 11 years of age, associated with progressive retraction of the interosseous membrane.

Kapandji¹¹ describes the loss of radius curvature. Seringue and Dubousset¹⁵ describe three stages of supination deformity, in the third stage there is dislocation of the radius head. In our study we did not observe any difference between the age groups, there were children with loss of pronosupination in the three groups. Therefore, we believe that the fixed deformity could be more related to the lack of an early rehabilitation program than to age itself, since many patients in our environment arrive at the specialized centers already with the established contracture, without undergoing a previous

Table 3 - Comparison of age groups for PP, AP, PS and AS measurements on the injured side through the Anova test.

Age	Mean	Median	Standard deviation	VC	Min	Max	N	CI	p-Value
PP									
From 4 to 6 years	57.1	65	31.8	56%	-10	90	12	18	0.092
From 7 to 9 years	68.3	80	32.4	47%	-10	90	12	18.3	
More than 10 years	34.4	25	34.8	101%	0	90	8	24.1	
PA									
From 4 to 6 years	34.2	40	34	99%	-50	70	12	19.2	0.077
From 7 to 9 years	48.3	60	34.6	72%	-30	90	12	19.6	
More than 10 years	4.4	7.5	56.7	1295%	-70	80	8	39.3	
SP									
From 4 to 6 years	79.6	82.5	14.5	18%	40	90	12	8.2	0.365
From 7 to 9 years	75.8	90	24.7	33%	10	90	12	14	
More than 10 years	87.5	90	4.6	5%	80	90	8	3.2	
SA									
From 4 to 6 years	50.4	42.5	29.3	58%	0	90	12	16.6	0.147
From 7 to 9 years	60	65	21.7	36%	10	90	12	12.3	
More than 10 years	73.1	80	20.2	28%	40	90	8	14	

VC, variation coefficient; CI, confidence interval; AP, active pronation; PP, passive pronation; AS, active supination; PS, passive supination.

Table 4 – Comparison of type of lesion for PP, AP, PS and AS measurements on the injured side by the Anova test.

Type of lesion	Mean	Median	Standard deviation	VC	Min	Max	N	CI	p-Value
PP									
Partial	59.2	75	34.5	58%	-10	90	12	19.5	0.66
Total	53.5	65	35.1	66%	-10	90	20	15.4	
AP									
Partial	43.8	60	33	75%	-30	80	12	18.7	0.24
Total	25	30	47.6	191%	-70	90	20	20.9	
PS									
Partial	80	85	13.5	17%	50	90	12	7.6	0.97
Total	80.3	90	20.3	25%	10	90	20	8.9	
AS									
Partial	59.6	60	21.2	36%	30	90	12	12	0.986
Total	59.8	70	28.2	47%	0	90	20	12.3	

VC, variation coefficient; CI, confidence interval; AP, active pronation; PP, passive pronation; AS, active supination; PS, passive supination.

rehabilitation treatment. In addition, we also observed some difficulty for patients and their relatives in joining a rehabilitation program due to socioeconomic reasons. The common characteristic among our patients was the absence of a regular physical therapy treatment.

Zancolli⁸ states that a vigorous rehabilitation program, along with the use of a nocturnal orthosis in forearm pronation position, may prevent interosseous membrane contracture. Price et al.¹⁶ emphasized the role of maintaining passive mobility in the development of joint structures and, later, Sutcliffe¹⁷ stated that treatment could be done exclusively with physical therapy and occupational therapy and discard surgery. When relating these observations to the results obtained in the present study, we reinforce our impression that rehabilitation would play a more decisive role than age or level of lesion.

Despite the decrease in active pronation observed in patients with total lesion compared to those with partial lesion, and in children in the group above 10 years in relation to other age groups, the statistical tests did not indicate a significant difference. These results suggest that these variables would not be determinant for the loss of forearm pronosupination.

Conclusion

We concluded that there were patients with loss of forearm pronosupination in all groups evaluated. However, this limitation in children with OBPP sequelae was not observed regarding the effect of age and type of lesion.

Conflicts of interest

The authors declare no conflicts of interest.

REFERENCES

- Gilbert A, Brockman R, Carlouz H. Surgical treatment of brachial plexus birth palsy. *Clin Orthop Relat Res.* 1991;(264):39-47.
- Narakas AO. Obstetrical brachial plexus injuries. In: Lamb DW, editor. *The paralysed hand.* Edinburgh: Churchill Livingstone; 1987. p. 116-35.
- Mollberg M, Hagberg H, Bager B, Lilja H, Ladfors L. High birthweight and shoulder dystocia: the strongest risk factors for obstetrical brachial plexus palsy in a Swedish population-based study. *Acta Obstet Gynecol Scand.* 2005;84(7):654-9.
- Bager B. Perinatally acquired brachial plexus palsy – a persisting challenge. *Acta Paediatr.* 1997;86(11):1214-9.
- Zafeiriou DI, Psychogiou K. Obstetrical brachial plexus palsy. *Pediatr Neurol.* 2008;38(4):235-42.
- Bahm J, Gilbert A. Surgical correction of supination deformity in children with obstetric brachial plexus palsy. *J Hand Surg Br.* 2002;27(1):20-3.
- Brunelli G. Technique: oblique radial osteotomy for supination syndrome. *J Hand Surg Am.* 2004;4(1):50-4.
- Zancolli EA. Paralytic supination contracture of the forearm. *J Bone Joint Surg Am.* 1967;49(7):1275-84.
- Masse P. Obstetrical paralysis of the brachial plexus. II. Therapeutics. Treatment of sequelae. Surgical possibilities for the elbow and the hand. *Rev Chir Orthop Reparatrice Appar Mot.* 1972;58 Suppl. 1:196-220.
- Manske PR, McCarroll HR Jr, Hale R. Biceps tendon rerouting and percutaneous osteoclasia in the treatment of supination deformity in obstetrical palsy. *J Hand Surg Am.* 1980;5(2):153-9.
- Kapandji IA. *Fisiologia articular. Membro superior.* São Paulo: Manole; 1982.
- Dunham EA. Obstetrical brachial plexus palsy. *Orthop Nurs.* 2003;22(2):106-16.
- Blount WP. Osteoclasia for supination deformities in children. *J Bone Joint Surg Am.* 1940;22:300-14.
- Yam A, Fullilove S, Sinisi M, Fox M. The supination deformity and associated deformities of the upper limb in severe birth lesions of the brachial plexus. *J Bone Joint Surg Br.* 2009;91(4):511-6.
- Seringe R, Dubousset JF. Attitude of the paralytic supination of the forearm in children. Surgical treatment in 19 cases. *Rev Chir Orthop Reparatrice Appar Mot.* 1977;63(7):687-99.
- Price A, Tidwell M, Grossman JA. Improving shoulder and elbow function in children with Erb's palsy. *Semin Pediatr Neurol.* 2000;7(1):44-51.
- Sutcliffe TL. Brachial plexus injury in the newborn. *Neo Rev.* 2007;8:239-45.