

CASE REPORT

Open Access



Precision treatment of Singleton Merten syndrome with ruxolitinib: a case report

Philip Broser^{1*} , Ursula von Mengershausen¹, Katrin Heldt², Deborah Bartholdi³, Dominique Braun³, Christine Wolf⁴ and Min Ae Lee-Kirsch⁴

Abstract

Background: Singleton-Merten syndrome 1 (SGMRT1) is a rare type I interferonopathy caused by heterozygous mutations in the *IFIH1* gene. *IFIH1* encodes the pattern recognition receptor MDA5 which senses viral dsRNA and activates antiviral type I interferon (IFN) signaling. In SGMRT1, *IFIH1* mutations confer a gain-of-function which causes overactivation of type I interferon (IFN) signaling leading to autoinflammation.

Case presentation: We report the case of a nine year old child who initially presented with a slowly progressive decline of gross motor skill development and muscular weakness. At the age of five years, he developed osteoporosis, acro-osteolysis, alveolar bone loss and severe psoriasis. Whole exome sequencing revealed a pathogenic de novo *IFIH1* mutation, confirming the diagnosis of SGMRT1. Consistent with constitutive type I interferon activation, patient blood cells exhibited a strong IFN signature as shown by marked up-regulation of IFN-stimulated genes. The patient was started on the Janus kinase (JAK) inhibitor, ruxolitinib, which inhibits signaling at the IFN- α/β receptor. Within days of treatment, psoriatic skin lesions resolved completely and the IFN signature normalized. Therapeutic efficacy was sustained and over the course muscular weakness, osteopenia and growth also improved.

Conclusions: JAK inhibition represents a valuable therapeutic option for patients with SGMRT1. Our findings also highlight the potential of a patient-tailored therapeutic approach based on pathogenetic insight.

Keywords: Singleton Merten syndrome, Type I interferon, Therapy, Janus kinase inhibitor, Ruxolitinib, Autoinflammation, Autoimmunity

Background

Heterozygous gain-of-function mutations in the *IFIH1* gene underlie a spectrum of autoinflammatory phenotypes including Aicardi–Goutières syndrome type 7 (AGS7) [1, 2] and Singleton–Merten syndrome type 1 (SGMRT1) [3]. *IFIH1* encodes interferon-induced helicase C domain-containing protein 1, also known as melanoma differentiation associated gene 5 protein (MDA5), a pattern recognition receptor of the innate immune system which plays a pivotal role in antiviral defense. *IFIH1*/

MDA5 recognizes viral double-stranded RNA (dsRNA) in the cytosol and upon ligand binding activates antiviral type I interferon-(IFN) signaling [4]. *IFIH1* mutations in AGS7 and SGMRT1 act as gain-of-function mutations that lead to inappropriate sensing of self-derived RNA, resulting in constitutive overproduction of type I IFN with subsequent autoinflammation [1, 2]. As such, AGS and SGMRT are also referred to as type I Interferonopathies, a genetically and phenotypically heterogeneous group of autoinflammatory and autoimmune diseases associated with perturbation of the type I IFN system [5]. While AGS is characterized by inflammatory neurodegeneration and skin disease, the clinical features of SGMRT comprise abnormal calcification of the aorta and cardiac valves, alveolar bone loss, dental caries,

*Correspondence: philip.broser@me.com

¹ Department of Pediatric Neurology, Children's Hospital of Eastern Switzerland, Sankt Gallen, Switzerland

Full list of author information is available at the end of the article



osteoporosis, psoriasis, and muscular weakness [3]. However, a phenotypic overlap between these disorders has been described, suggesting that AGS and SGMRT due to *IFIH1* gain-of-function mutations constitute facets of the same disease spectrum [6–8]. Janus kinase (JAK) inhibitors have been recently reported as promising treatment option for type I interferonopathies [9–11]. However, whether JAK inhibition also ameliorates symptoms in patients with SGMRT is unknown. Here, we report the case of a child with SGMRT1, in whom treatment with the JAK inhibitor ruxolitinib led to sustained clinical improvement.

Case presentation

We report on a male patient who was born at term after an uncomplicated pregnancy to non-consanguineous parents. Birth weight, height and head circumference were within normal limits. The patient initially thrived well but was noted to reach developmental milestones later than expected. He was able to sit at 12 months of age, to stand at 18 months of age, and to walk unsupported at 27 months of age. At the age of four years, he presented with muscular weakness of the lower extremities. While he was able to walk on a flat surface, he had difficulties to climb up stairs or to squat. In addition, his growth stunted, and his length was below the 3rd percentile. During clinical examination, he showed a stiff gait with overextension of knee joints and a mild hyperlordosis. In contrast to the lower extremities, the patient exhibited a normal function of his upper extremities with a precise and well-controlled visual coordination of his hands. His speech and cognitive functions were within normal range. Neurophysiological examination revealed a discretely reduced motor nerve conduction speed (N. tibialis 39 m/s [$N > 45$], N. peroneus 43 m/s, [$N > 45$ m/s]) with unremarkable findings on repetitive nerve stimulation. His muscular mass was reduced with a normal muscle texture without any signs of inflammation on ultrasound and MR imaging. An MRI of the brain and spine showed normal findings. Endocrinological work-up for short stature revealed normal values for growth hormone, IGF-1 and IGFBP-III. His thyroid function test was normal and the inflammatory marker, C-reactive protein (CRP), was below 5 mg/ml. However, an X-ray of the hands showed osteopenia with a thinned cortex of the finger bones and a DEXA scan revealed reduced mineralization of bones (femur, Z-score -2.7SD; hip, Z-score -2.8SD; spine, Z-score -0.8SD). An X-ray of the skull revealed an absent nasal bone (Fig. 1A). The X-ray of the hip and femurs showed a pathological caput-colum-diaphyseal angle (Fig. 1B). The family declined further genetic testing at that point. The child was treated with physiotherapy and orthopedic support. Due to progressive pes equinus an Achilles tendon extension was performed.

In the following years, the patient exhibited normal cognitive development but his growth remained retarded

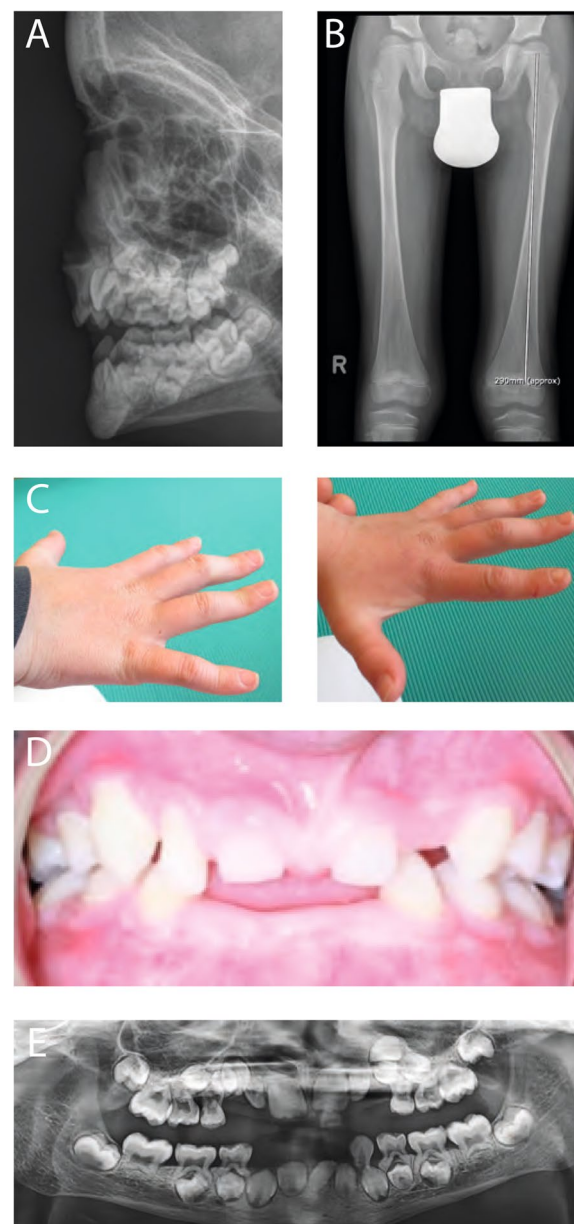


Fig. 1 Clinical findings. **A** Lateral X-ray image of facial bones showing absence of nasal bone. **B** Anterior–posterior X-ray of the hip and femurs showing hypoplastic acetabular roofs, marked osteopenia of femoral bones and enlarged CCD angles. **C** Boutonniere deformity of hands. **D** Image of the teeth at the age of nine years, showing defective dentition with hypoplastic teeth. **E** Anterior–posterior x-ray of the denture showing aplasia of teeth no. 18, 28, 31, 38 and 48, as well as hypoplastic shortened roots of most of remaining teeth (courtesy of Dr. Zettel)

progressive pes equinus an Achilles tendon extension was performed.

In the following years, the patient exhibited normal cognitive development but his growth remained retarded

and muscular weakness worsened. By the age of seven years, he could barely climb a stair without intense support. A boutonniere deformity of both hands was noted (Fig. 1C) and a hand X-ray showed acro-osteolysis (Fig. 3C, D), consistent with inflammatory bone destruction. At the age of eight years, the patient developed with severe psoriasis (Fig. 2A), unresponsive to steroid treatment. In addition, the patient exhibited failure of secondary dentition with aplasia of several teeth (18, 28, 31, 38 and 48) and hypoplastic roots of remaining teeth (Fig. 1D, E). A cardiologic examination, including echocardiography and electrocardiography, and an ophthalmologic exam were unremarkable.

The clinical findings of neuromuscular and inflammatory symptoms of bones and skin suggested a genetic etiology and eventually genetic testing was initiated. A trio exome analysis revealed a heterozygous de novo variant in the *IFIH1* gene (NM_022168.4: c.2465G>A; p.Arg822Gln) in the patient. This variant has been previously reported in patients with SGMRT1 [3], confirming the diagnosis of SGMRT1. Although the inheritance pattern of SGMRT1 is autosomal dominant, both healthy parents did not carry the disease-causing variant, p.Arg822Gln, indicating that it had occurred de novo. In

addition, there was no evidence for a mosaic in the NGS data.

The IFN signature in blood was measured as previously described [12]. In line with constitutive type I IFN activation, peripheral blood mononuclear cells of the patient exhibited a strong interferon signature (an IFN score above 12.49), as shown by up-regulation of IFN-stimulated genes (Fig. 2C). Based on the genetic and laboratory findings and in view of the refractory skin disease, the decision was made to treat the child with ruxolitinib, a JAK1/2 inhibitor, which blocks signaling at the IFN- α/β receptor. Following oral administration of 0.5 mg/kg ruxolitinib per day, the child experienced significant improvement of psoriatic skin lesions that was already visible after three days of treatment and over the course resulted in complete resolution of cutaneous inflammation (Fig. 2B). In addition, the interferon signature was markedly reduced during treatment (Fig. 2C). Six weeks after treatment was started, the child showed an increase in body weight and length (Fig. 3A, B). A hand X-ray revealed a significant increase of bone mineralization of fingers (Fig. 3C). Remarkably, after five months of treatment, the acro-osteolysis of the thumb was completely resolved (Fig. 3D). The patient also experienced

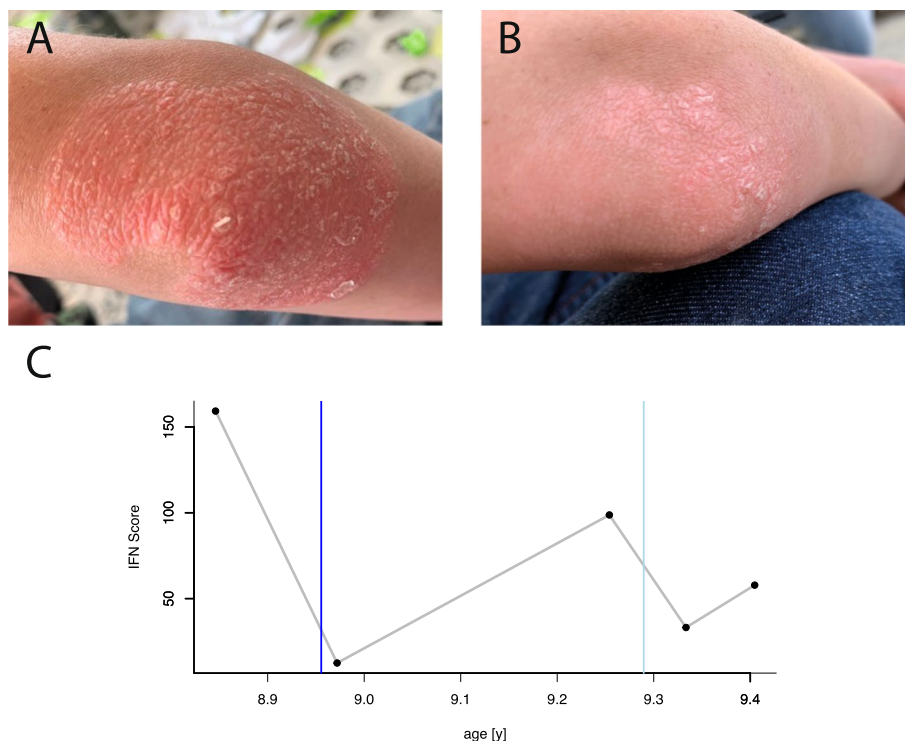
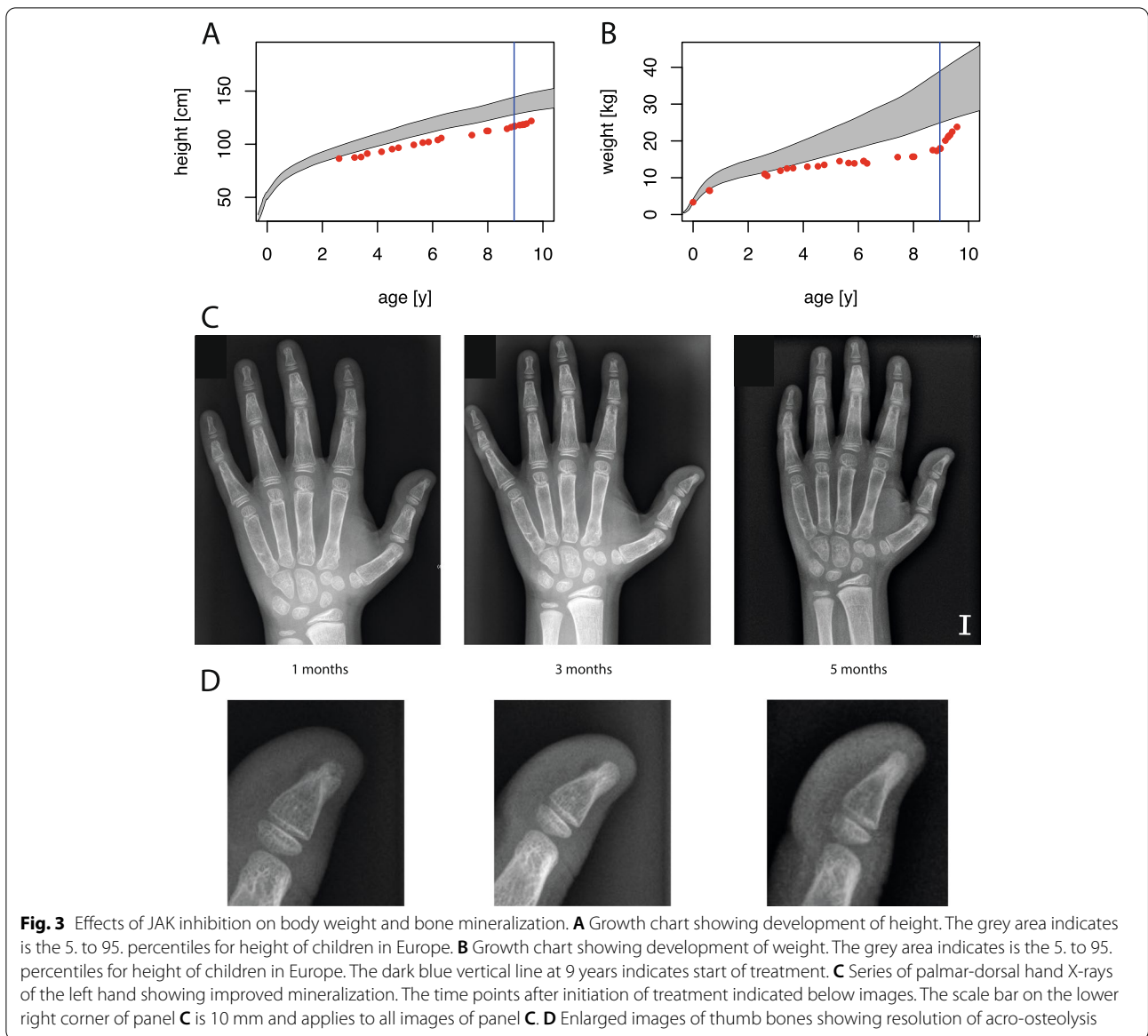


Fig. 2 Effects of JAK inhibition on skin and interferon signature. **A** Right elbow before initiation of treatment with ruxolitinib, showing psoriatic lesion with hyperkeratosis and scaling. **B** Resolution of psoriatic skin lesion after one week of treatment. **C** Interferon signature before and during treatment with ruxolitinib. An IFN score < 12.49 defines the median of 10 healthy controls plus 2 SDs. The dark blue vertical line marks the start of the treatment with ruxolitinib. The light blue vertical line marks the time when the treatment was increased to the final dosage



improvement of muscle weakness and his gross motor function classification system (GMFCS) score [13] improved from GMFCS level two (ambulatory with assistance) to GMFCS level one (independently mobile).

While the patient was on ruxolitinib, he experienced mild upper respiratory symptoms and elevated temperature for two days, followed by quick recovery. As the patient’s sister had been tested SARS-CoV-2-positive, a COVID-19 infection was suspected. Serologic testing confirmed sero-conversion both anti- spike antigen IgG and IgM. Three months after initiation of ruxolitinib, the dosage was slightly increased to a final maintenance dose of 0.75 mg/kg per day. The treatment with ruxolitinib was well tolerated without any side effects. Repeated

measurements of blood count and biochemistry did not show any changes and the patient felt very well.

Discussion and conclusions

In 1973, Singleton and Merten and shortly later, in 1976, Gay and Kuhn reported four patients with dental dysplasia, osteoporosis, widened medullary cavities of hand bones and calcification of the thoracic aorta [14, 15]. In addition, some of the patients presented with muscle weakness as well as psoriasiform skin lesions. Feigenbaum et al. noted dominant inheritance with significant phenotypic variability of SGMRT even within families and summarized the core manifestations to include progressive aortic calcification,

dental anomalies, osteopenia and acro-osteolysis and to a lesser extent, glaucoma, psoriasis, muscle weakness, and joint laxity [16]. In 2015, Rutsch et al. identified a p.Arg822Gln substitution in *IFIH1* as the cause of SGMRT1 in three unrelated families and demonstrated by functional analysis that the mutation exerts a gain-of-function, resulting in a heightened inflammatory state due to overproduction of type I IFN [3]. Activating mutations in *IFIH1* were subsequently shown to underlie AGS7, an early-onset inflammatory leukoencephalopathy characterized by basal ganglia calcification and constitutive type I IFN activation [2]. Notably, the p.Arg822Gln mutation initially identified in SGMRT1 was also observed in a patient presenting with typical clinical features of AGS, suggesting that SGMRT1 and AGS7 due to *IFIH1* gain-of-function mutations are part of the same disease spectrum [8].

The patient described here exhibited many of the typical features of SGMRT1, including dental anomalies, osteopenia, acro-osteolysis, psoriasis and muscle weakness, yet lacked the core feature of aortic calcification. Given that most patients with SGMRT1 develop aortic calcification early in childhood [17], the lack of this feature was unexpected. However, a patient with SGMRT1 without cardiac involvement carrying a different variant in the *IFIH1* gene (p.Leu329Pro) has recently been reported [18]. Nonetheless, due to the high cardiovascular risk we do monitor the patient regularly by echocardiography.

After establishing the diagnosis of SGMRT1 by genetic testing, we confirmed constitutive type I IFN activation in the patient by demonstrating up-regulation of IFN-stimulated genes in blood. Given the progressive disease course, in particular due to refractory skin inflammation, this led us to consider treatment with the JAK inhibitor ruxolitinib. While JAK inhibition had been shown to ameliorate symptoms in patients with type I interferonopathies, such as STING-associated vasculopathy, CANDLE syndrome or AGS [9–11], there have been no reports about targeted treatment approaches in SGMRT1 so far. Based on the assumption that uncontrolled type I IFN signaling was driving the inflammatory symptoms in our patient, we initiated treatment with ruxolitinib at 0.5 mg/kg bodyweight to inhibit type I IFN signaling. The patient responded with significant improvement that was visible within the first weeks of administration of the drug. Thus, psoriatic lesions vanished within days, the muscle weakness and bone mineralization improved, the patient showed a significant weight gain. Clinical improvement was accompanied by a marked reduction of the interferon signature in blood, indicating that inhibition of overactive type I IFN signaling was therapeutically effective.

In summary, this case report demonstrates that targeting of uncontrolled type I IFN activation by JAK inhibition is of therapeutic benefit in patients with SGMRT1 and highlights the role of precision medicine in the treatment of rare diseases in children. Moreover, our findings also suggest a hitherto unappreciated role of the interferon signaling pathway in bone metabolism.

Abbreviations

CCD angle: Caput-collum-diaphyseal angle; DEXA scan: Dual energy X-ray absorptiometry; *IFIH1*: Interferon-induced with helicase C domain 1; IFN: Interferon; ISG: Interferon-stimulated gene; JAK: Janus kinase; MDA5: Melanoma differentiation-associated protein 5; RIG-I: Retinoic acid-inducible gene 1; RLR: RIG-I-like receptor; SGMRT1: Singleton-Merten syndrome 1.

Acknowledgements

We thank the patient and his family for their participation in the study.

Authors' contributions

PB conceived the study as main responsible clinician and wrote the manuscript. UVM participated in clinical care. KH performed endocrinological testing for osteoporosis and growth retardation. DBA performed genetic testing and genetic counselling. DBR performed trio exome analysis. CW performed interferon signature measurements. MLK gave scientific advice and wrote the manuscript. All authors read and approved the final manuscript.

Funding

This work was supported by grants from the Deutsche Forschungsgemeinschaft (CRC237 369799452/B21 to MLK; CRC237 369799452/J01 to CW).

Availability of data and materials

Not applicable.

Declarations

Ethics approval and consent to participate

Treatment was conducted with informed consent by the patient and his parents. The patient was enrolled in an ongoing study on the pathogenesis of interferonopathies approved by the Ethics Committee of the Medical Faculty, Technische Universität, Dresden.

Consent for publication

The patient and his parents gave consent that his photos and medical data are published.

Competing interests

The authors declare that they have no competing interests.

Author details

¹Department of Pediatric Neurology, Children's Hospital of Eastern Switzerland, Sankt Gallen, Switzerland. ²Department of Pediatric Endocrinology, Children's Hospital of Eastern Switzerland, Sankt Gallen, Switzerland. ³Department of Human Genetics, University Hospital Bern, Bern, Switzerland. ⁴Department of Pediatrics, Medizinische Fakultät Carl Gustav Carus, Technische Universität Dresden, Dresden, Germany.

Received: 31 January 2022 Accepted: 3 April 2022

Published online: 11 April 2022

References

- Oda H, Nakagawa K, Abe J, Awaya T, Funabiki M, Hijikata A, et al. Aicardi-Goutières syndrome is caused by *IFIH1* mutations. *Am J Hum Genet.* 2014;95:121–5.

2. Rice GI, Del Toro DY, Jenkinson EM, Forte GM, Anderson BH, Ariaudo G, et al. Gain-of-function mutations in IFIH1 cause a spectrum of human disease phenotypes associated with upregulated type I interferon signaling. *Nat Genet.* 2014;46:503–9.
3. Rutsch F, MacDougall M, Lu C, Buers I, Mamaeva O, Nitschke Y, et al. A specific IFIH1 gain-of-function mutation causes Singleton-Merten syndrome. *Am J Hum Genet.* 2015;96:275–82.
4. Schlee M, Hartmann G. Discriminating self from non-self in nucleic acid sensing. *Nat Rev Immunol.* 2016;16:566–80.
5. Lee-Kirsch MA. The type I Interferonopathies. *Annu Rev Med.* 2017;68:297–315.
6. Rice GI, Park S, Gavazzi F, Adang LA, Ayuk LA, Eyck LV, et al. Genetic and phenotypic spectrum associated with IFIH1 gain-of-function. *Hum Mutat.* 2020;41:837–49.
7. Bursztejn A-C, Briggs TA, del Toro DY, Anderson BH, O'Sullivan J, Williams SG, et al. Unusual cutaneous features associated with a heterozygous gain-of-function mutation in IFIH1: overlap between Aicardi-Goutières and Singleton-Merten syndromes. *Br J Dermatol.* 2015;173:1505–13.
8. Buers I, Rice GI, Crow YJ, Rutsch F. MDA5-associated neuroinflammation and the singleton-merter syndrome: two faces of the same type I Interferonopathy Spectrum. *J Interferon Cytokine Res.* 2017;37:214–9.
9. Bienias M, Brück N, Griep C, Wolf C, Kretschmer S, Kind B, et al. Therapeutic approaches to type I Interferonopathies. *Curr Rheumatol Rep.* 2018;20:32.
10. Vanderver A, Adang L, Gavazzi F, McDonald K, Helman G, Frank DB, et al. Janus Kinase Inhibition in the Aicardi-Goutières syndrome. *N Engl J Med.* 2020;383:986–9.
11. Sanchez GAM, Reinhardt A, Ramsey S, Wittkowski H, Hashkes PJ, Berkun Y, et al. JAK1/2 inhibition with baricitinib in the treatment of autoinflammatory interferonopathies. *J Clin Invest.* 2018;128:3041–52.
12. Wolf C, Brück N, Koss S, Griep C, Kirschfink M, Palm-Beden K, Fang M, Röber N, Winkler S, Berner R, Latz E, Günther C, Lee-Kirsch MA. Janus kinase inhibition in complement component 1 deficiency. *J Allergy Clin Immunol.* 2020;146(6):1439–1442.e5 (Epub 2020 Apr 20. PMID: 32325142).
13. Palisano R, Rosenbaum P, Walter S, Russell D, Wood E, Galuppi B. Development and reliability of a system to classify gross motor function in children with cerebral palsy. *Dev Med Child Neurol.* 1997;39:214–23.
14. Singleton EB, Merten DF. An unusual syndrome of widened medullary cavities of the metacarpals and phalanges, aortic calcification and abnormal dentition. *Pediatr Radiol.* 1973;1:2–7.
15. Gay BB Jr, Kuhn JP. A syndrome of widened medullary cavities of bone, aortic calcification, abnormal dentition, and muscular weakness (the Singleton-Merten syndrome). *Radiology.* 1976;118:389–95.
16. Feigenbaum A, Müller C, Yale C, Kleinheinz J, Jezewski P, Kehl HG, et al. Singleton-Merten syndrome: an autosomal dominant disorder with variable expression. *Am J Med Genet A.* 2013;161A:360–70.
17. Ozyuksel A, Ersoy C, Canturk E, Akcevin A. Progressive supra-aortic stenosis in a young adult with the findings of Singleton Merten Syndrome. *BMJ Case Rep.* 2014;2014:bcr2014205985. <https://doi.org/10.1136/bcr-2014-205985>.
18. Vengoechea J, DiMonda J. A case of Singleton-Merten syndrome without cardiac involvement harboring a novel IFIH1 variant. *Am J Med Genet A.* 2020;182(6):1535–6. <https://doi.org/10.1002/ajmg.a.61556> (Epub 2020 Mar 23 PMID: 32202700).

Publisher's Note

Springer Nature remains neutral with regard to jurisdictional claims in published maps and institutional affiliations.

Ready to submit your research? Choose BMC and benefit from:

- fast, convenient online submission
- thorough peer review by experienced researchers in your field
- rapid publication on acceptance
- support for research data, including large and complex data types
- gold Open Access which fosters wider collaboration and increased citations
- maximum visibility for your research: over 100M website views per year

At BMC, research is always in progress.

Learn more biomedcentral.com/submissions

