



Endovascular Treatment of Intracranial Hypertension Associated with Venous Sinus Stenosis due to Tumor Compression

Satomi Mizuhashi and Shinya Kohyama

Objective: We report a patient with intracranial hypertension associated with venous sinus stenosis due to tumor compression. Embolization of tumor feeding blood vessels reduced the tumor volume, improved venous sinus stenosis, and alleviated the symptoms of intracranial hypertension.

Case Presentation: The patient was a 46-year-old woman with chronic headache and blurred vision. Magnetic resonance venography (MRV) revealed stenosis of the right transverse-sigmoid sinus. Intracranial hypertension was diagnosed by lumbar puncture. A high-intensity 2-cm tumor was detected on T2-weighted magnetic resonance imaging (MRI), and the homogeneously enhanced tumor was adjacent to the right transverse-sigmoid sinus. Cerebral angiography demonstrated tumor staining mainly from the right occipital artery (OA). Collateral venous flow was minimal. In such cases, resection and reconstruction of the involved sinus segment have a high risk of venous infarction. Accordingly, percutaneous transluminal angioplasty (PTA) was performed, but dilation of the stenosis was poor. Thus, feeder occlusion of the tumor was added and lumboperitoneal (LP) shunt was placed, alleviating the headache and blurred vision. Ten months later, reduction of the tumor volume and improvement of sinus stenosis were observed, and the LP-shunt system was removed. A decrease in tumor volume via feeder occlusion may lead to partial sinus decompression and increased venous flow, resulting in long-term clinical remission.

Conclusion: Transverse-sigmoid sinus stenosis can be a cause of intracranial hypertension, albeit rare. Embolization of the tumor is considered to be a treatment option for patients who cannot undergo resection.

Keywords ▶ intracranial hypertension, transverse-sigmoid sinus stenosis, percutaneous transluminal angioplasty, LP shunt, feeder occlusion

Introduction

The incidence of meningioma is 2–3% of the population.¹⁾ It is difficult to remove tumors that are in contact with or have infiltrated the venous sinuses. We report a patient with a small meningioma at the transverse-sigmoid sinus junction, compressing the venous sinuses and causing

symptoms of intracranial hypertension. The venous sinuses posterior to the superior sagittal sinus, such as the torcular herophili, where the superior sagittal sinus, straight sinus, and transverse sinuses join, are vulnerable to compression and invasion of external lesions,²⁾ and stenosis or obstruction by a tumor may disturb the blood flow of intracranial venous sinuses and cause intracranial hypertension. Compression or invasion of the unilateral transverse sinus or sigmoid sinus by a tumor may be symptomatic only when it affects the dominant sinus. The patient reported here was considered to have been symptomatic because the dominant transverse-sigmoid sinus junction was markedly stenosed due to tumor compression and the development of collateral vessels was poor. Some alternative treatments were considered,³⁾ but we performed feeding vessel embolization, which was previously reported to have a volume-reducing effect,⁴⁾ and using a subarachnoid lumboperitoneal shunt (LP-shunt). Ten months after embolization, the tumor size

Department of Neurosurgery, Saitama Medical University International Medical Center, Hidaka, Saitama, Japan

Received: August 2, 2019; Accepted: October 21, 2019
Corresponding author: Satomi Mizuhashi. Department of Neurosurgery, Saitama Medical University International Medical Center, 1397-1 Yamane, Hidaka, Saitama 350-1298, Japan
Email: satomi-mizuhashi@jcom.home.ne.jp



This work is licensed under a Creative Commons Attribution-NonCommercial-NoDerivatives International License.

©2020 The Japanese Society for Neuroendovascular Therapy

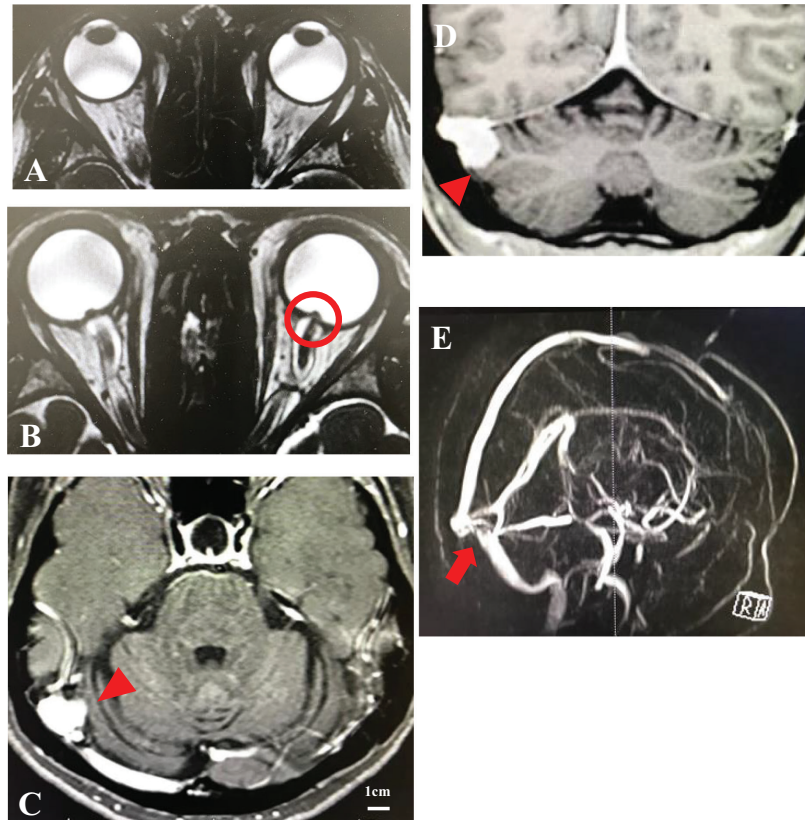


Fig. 1 CISS images showing eye protrusion (A), tortuosity of the bilateral optic nerve, expansion of the surrounding cerebrospinal cavity, and protrusion of optic disks (B). T1-weighted Gd-DTPA-enhanced axial (C) and coronal (D) MRI showing a tumor on the transverse sinus-sigmoid sinus (arrowheads). MRV showing severe stenosis (arrow) at the junction of the right transverse sinus and sigmoid sinus (E). CISS: constructive interference in steady state; MRI: magnetic resonance imaging; MRV: magnetic resonance venography

was reduced and venous sinus stenosis was alleviated, resulting in improvement of intracranial hypertension and enabling removal of the LP-shunt system. This case is reported with a review of the literature.

Case Presentation

The patient was a 46-year-old woman with headache, visual impairment, and pulsating tinnitus. She had a history of hysterectomy due to uterine fibroids at the age of 39 years. There was no notable familial history.

She had noted headache and decline in vision 3 months prior to presentation. She consulted the ophthalmology department, where she was found to have papilledema and was recommended to consult the neurology department. Magnetic resonance imaging (MRI) of the head revealed meandering of the bilateral optic nerves, flattening of the posterior part of the eyeball, protrusion of the optic disc into the eye, and, empty sella and enlargement of the

surrounding cerebrospinal fluid (CSF) space (**Fig. 1**). On lumbar puncture, the initial CSF pressure was 450 mm H₂O, and the patient was referred to the neurosurgery department under a diagnosis of intracranial hypertension.

On admission, the patient had clear consciousness, and complained of intense headache and pulsating tinnitus. The symptoms were not affected by changes in body position. She had no nausea or vomiting. Papilledema and enlargement of the Mariotte blind spot were observed bilaterally. No other neurological defects were noted observed.

Regarding neuroradiological findings, computed tomography (CT) of the head demonstrated a tumoral lesion of approximately 2 cm in diameter in contact with the junction of the right transverse and sigmoid sinuses. On brain MRI, the tumor was hypo-intense on T1-weighted imaging and hyper-intense on T2-weighted imaging, and mild edema was observed around it. The tumor exhibited intense contrast enhancement and its volume was 1.49 cm³ (**Fig. 1**). On magnetic resonance venography (MRV), the right

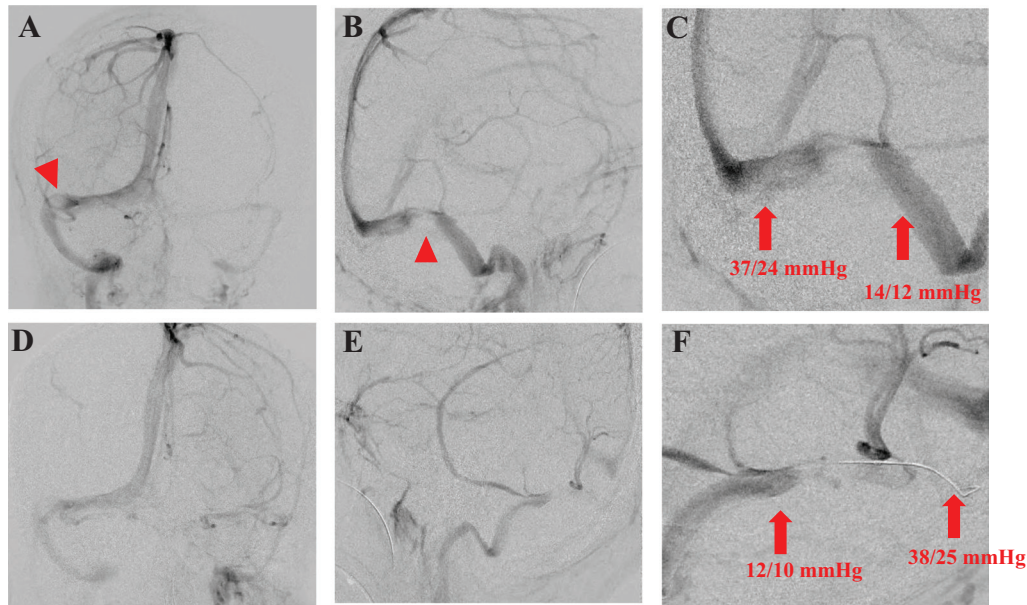


Fig. 2 Cerebral digital subtraction angiography showing severe stenosis of the right transverse sinus-sigmoid sinus compressed by the tumor (arrowheads) in the anteroposterior (A-P) view (A) and lateral view (B). Cerebral digital subtraction angiography showing the congenitally hypoplastic left transverse sinus-sigmoid sinus in the A-P view (D) and lateral view (E). C and F show the venous pressure before and after stenosis, respectively (arrows).

junction of transverse and sigmoid sinus was compressed by the tumor and was markedly stenosed. The left transverse sinus was hypoplastic. The possibility of hydrocephalus was excluded because no enlargement of the cerebral ventricles was observed.

On lumbar puncture, the initial CSF pressure was higher than 450 mm H₂O, indicating intracranial hypertension, and headache was mildly alleviated for approximately 24 hours after CSF drainage. No abnormalities were found by cytological or biochemical examination of CSF.

Cerebral angiography revealed marked stenosis of the right transverse-sigmoid sinus junction at the site of the tumor. And the transverse sinus distal to the tumor showed blood flow stasis (Fig. 2). The left transverse and sigmoid sinuses were hypoplastic. Intense tumor staining via the right mastoid branch of occipital artery (OA) was observed.

Meningioma affecting the junction of the right transverse and sigmoid sinuses was suspected, and it was suspected that the right transverse and sigmoid sinus was severely constricted due to the compression of the meningioma in the junction of the right transverse and sigmoid sinus. As a result, the symptoms of intracranial hypertension were considered to have been caused by impairment of venous flow accompanied by original hypoplasia of the contralateral left transverse sinus. We considered removal of meningioma, but judged it to be difficult due to the high risk of

venous infarction due to obstruction of the venous sinuses because the tumor was located inside the venous sinuses, and because of the junction of the dominant transverse and sigmoid sinuses with the contralateral hypoplastic transverse sinus, which made reconstruction of the venous sinuses difficult. The treatment plan was to perform (1) percutaneous transluminal angioplasty (PTA) of the stenosed part of the transverse sinus (unapproved application), (2) embolization of the feeding vessel of the meningioma to reduce its volume, (3) placement of an LP-shunt to alleviate the symptoms of intracranial hypertension, and (4) stereotactic radiosurgery (SRS) to reduce the tumor size.

Endovascular therapy was performed as follows: Before procedure, the patient was administered clopidogrel at 300 mg and aspirin at 200 mg. Under general anesthesia, a 4Fr Axcelguide 93 cm (MEDIKIT CO., LTD., Tokyo, Japan) was inserted to the right femoral artery and placed in the right common carotid artery for control angiography. A 7Fr sheath was inserted into the right femoral vein and 7Fr Guider (Stryker, Michigan, USA) was placed in the right jugular vein (JV). Renegade HI-FLO (Boston Scientific Co., MA, USA) and Chikai 14 (Asahi Intecc Co., LTD, Aichi, Japan) were placed at the site of stenosis in the right sigmoid sinus. The venous diameter was approximately 4 mm on the proximal and distal sides of stenosis, and was less than 1 mm in the narrowest part. The venous

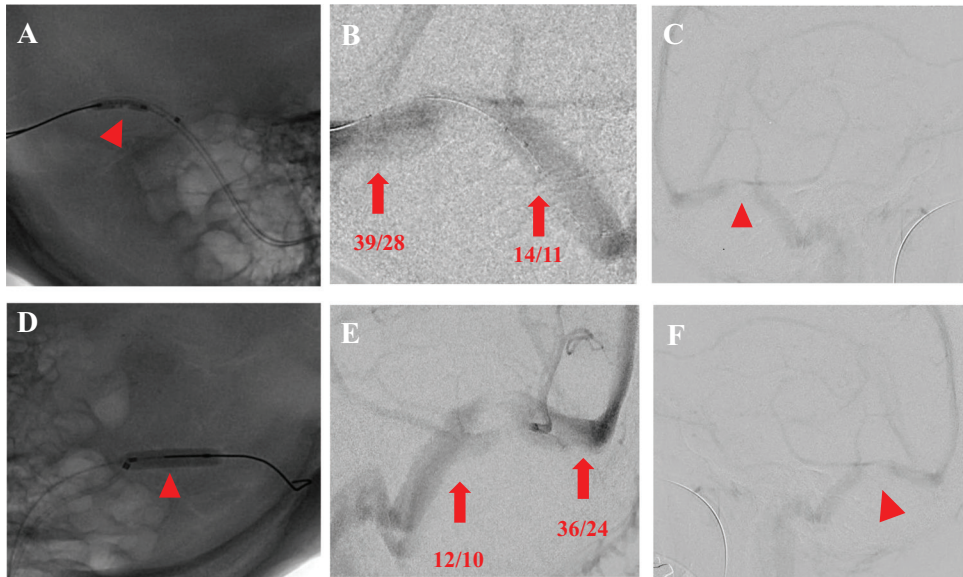


Fig. 3 Cerebral digital subtraction angiography showing PTA for severe stenosis of the transverse sinus-sigmoid sinus (arrowheads) on the right side (**A**) and left side (**D**). **B** and **E** show the venous pressure after PTA before and after stenosis, respectively (arrows). Cerebral digital subtraction angiography after PTA showing the transverse sinus-sigmoid sinus (arrowheads) on the right side (**C**) and left side (**F**). PTA: percutaneous transluminal angioplasty

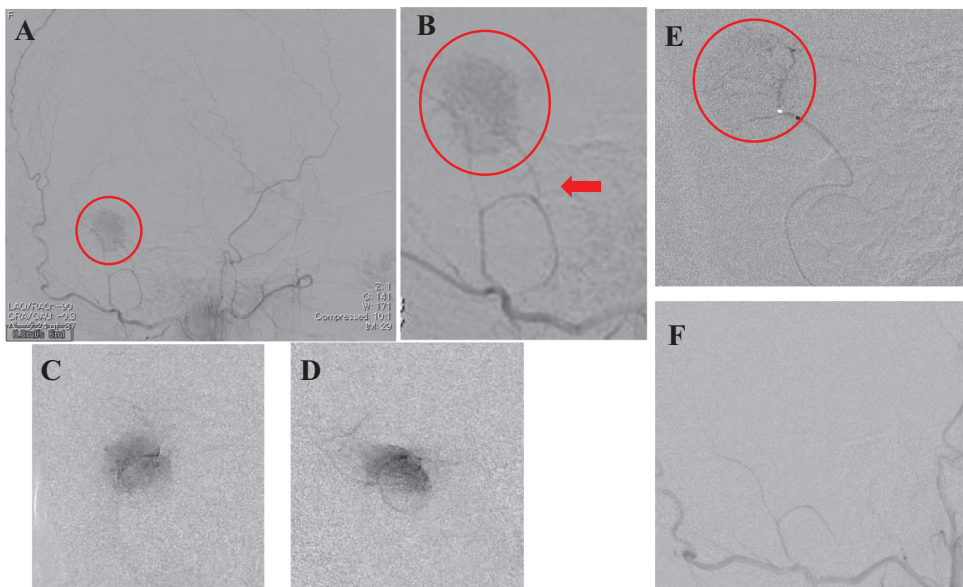


Fig. 4 Right external carotid angiograms showing the tumor (arrowheads) entering from the mastoid range of the OA (arrows) in the anteroposterior view (**A** and **B**). Superselective angiograms from a microcatheter in the right occipital artery in the anteroposterior view (**C**) and lateral view (**D**). Injection of NBCA through the microcatheter penetrating the tumor vessels (**E**). After the injection of NBCA, right external carotid angiograms show the disappearance of tumor staining (**F**). NBCA: n-butyl 2-cyanoacrylate; OA: occipital artery

pressure was measured by guiding the Renegade HI-FLO more distally through the stenosed part. The venous pressure was 37/24 (31) mmHg on the distal side and 14/12 (12) mmHg on the proximal side of the stenosis, the systemic blood pressure was 115/53 (75) mmHg, and the pressure

difference between the proximal and distal sides of the stenosis was 19 mmHg (**Fig. 2**). As symptoms of intracranial hypertension and a venous pressure gradient between the proximal and distal sides of the stenosis were observed, dilation of the stenosed area of the transverse-sigmoid

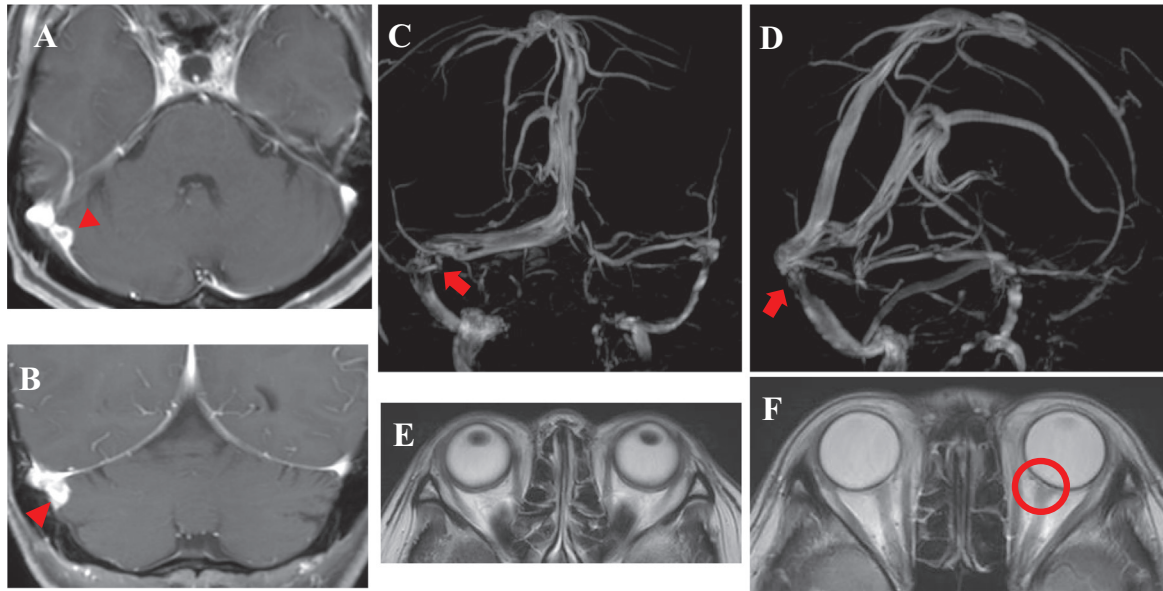


Fig. 5 T1-weighted Gd-DTPA-enhanced axial (A) and coronal (B) MRI show the reduction of the tumor on the transverse sinus-sigmoid sinus (arrowheads) 10 months after embolization. MRV showing the improvement of severe stenosis (arrows) at the junction of the right transverse sinus and the sigmoid sinus (C and D) 10 months after embolization. MRI showing the improvement of eye protrusion (E), tortuosity of the bilateral optic nerve, expansion of the surrounding cerebrospinal cavity, and protrusion of the optic disk (F). MRI: magnetic resonance imaging; MRV: magnetic resonance venography

sinus junction was attempted three times inflating a balloon Gateway 2 mm × 15 mm (Stryker, Michigan, USA). Although the balloon was able to be dilated easily, the venous sinuses recoiled to the state before treatment, and no improvement was observed; the venous pressures on the distal and proximal sides of the stenosis were 39/28 (34) mmHg and 14/11 (12) mmHg, respectively, and the pressure gradient between the proximal and distal sides of the stenosis was 22 mmHg (Fig. 3).

Therefore, to increase the flow to the contralateral left transverse sinus, which was markedly stenosed and hypoplastic, we decided to perform PTA at the stenosed site of the left transverse sinus. Similarly, we guided a 7Fr Guider into the left JV as distally as possible, guided the Renegade HI-FLO and CHIKAI 14 to the more distal hypoplastic transverse sinus, and measured the venous pressure there (38/25 (31) mmHg) and in the sigmoid sinus proximal to the site of stenosis (12/10 (11) mmHg). Furthermore, dilation of the site of stenosis was attempted three times inflating the balloon Gateway 3 mm × 12 mm (Stryker, Michigan, USA). Although the balloon was able to be dilated easily, the venous sinuses recoiled to the state before treatment. After PTA, the venous pressure was 36/24 (32) mmHg on the distal side of the transverse sinus and 12/10 (11) mmHg on the proximal side of the sigmoid sinus, and the pressure gradient was 21 mmHg, exhibiting no improvement (Fig. 3d).

We then decided to embolize the tumor and replaced a 4Fr Axcelguide 93 cm (Medikit Co., Ltd., Tokyo, Japan) in the right external carotid artery immediately before the bifurcation of the OA. Frontal and lateral angiography of the right external carotid artery demonstrated a feeder from the mastoid branch arising from the right OA with tumor staining (Fig. 4). A Marathon (Medtronic plc., Minnesota, USA) and Chikai 08 (Asahi Intecc Co., Ltd, Aichi, Japan) were guided with a microwire through the tortuous portion, and the Marathon was guided as distally as possible beyond the mastoid branch and placed immediately before the tumor. N-butyl cyanoacrylate (NBCA), which was reported to suppress tumor growth alone, was used as the embolization material.⁴⁾ The feeder to the tumor was embolized using low-concentration (17%) NBCA with care not to backflow to the proximal side of the bifurcation of the mastoid branch. NBCA penetrated to part of the intratumoral vessels, and disappearance of the tumor enhancement was confirmed by right external carotid angiography (Fig. 4).

No perioperative complications were observed. As headache persisted, an LP-shunt was placed (Codman Hakim Programmable Valve Shunt System [Codmann & Shurtleff, Inc., Massachusetts, USA] 12 cmH₂O) 2 days after the procedure. Headache was alleviated 1 week after surgery, and papilledema disappeared after 1 month. Low CSF pressure symptoms (headache and nausea were exacerbated

in the sitting position, but mitigated in the recumbent position) developed approximately 6 months after surgery, and the LP-shunt pressure was reset at 20 cmH₂O. The LP-shunt system was removed 10 months after embolization of tumor because a reduction in the tumor size (volume: 0.28 cm³) and improvement of venous sinus stenosis were confirmed by MRI of the head (**Fig. 5**), and because the low CSF pressure symptoms persisted. After removal of the shunt system, the low CSF pressure symptoms disappeared. The patient is presently followed up, but there has been no recurrence of symptoms of intracranial hypertension or enlargement of the tumor. Therefore, no shunt system reinsertion has been required and SRS has not been implemented as of 18 months after surgery.

Discussion

The possibility of intracranial hypertension secondary to compression or invasion of the transverse sinus by tumors has been suggested. Chazal et al. reported a patient with a small meningioma invading the left transverse sinus exhibiting an increase in the venous pressure in the superior sagittal sinus, which caused delayed CSF absorption in arachnoid granulations and intracranial hypertension.⁵ Similar reports have been made concerning lesions other than meningioma,⁶ including Ewing's sarcoma, metastatic tumors,⁷ epidermoid cysts,⁸ and eosinophilic granuloma.⁹ Tumor-induced intracranial hypertension may cause dural arteriovenous fistula in the transverse-sigmoid sinus region¹⁰ and hemorrhage around the tumor.^{11,12}

The pattern of the venous sinuses is markedly diverse. The bilateral transverse sinuses are drained symmetrically in less than 65% of normal individuals, and patterns, including those in which one transverse sinus is dominant and the contralateral sinus is hypoplastic or absent, are widely known.¹³ Hwang et al. classified the blood flow of the confluence of sinuses into four patterns in the guidelines for ligation of the transverse or sigmoid sinus during surgical resection of petroclival meningioma¹⁴: type A: blood drains from the confluence of sinuses nearly equally into the bilateral transverse sinuses; type B: blood drains from the confluence of sinuses primarily into the transverse sinus contralateral to the tumor; type C: blood drains from the confluence of sinuses primarily into the transverse sinus ipsilateral to the tumor; type D: blood drains into the transverse sinus ipsilateral to the tumor, and the contralateral transverse sinus is hypoplastic. Intracranial hypertension may develop in types C and D, which are infrequent.

This explains the low rate of patients who exhibit intracranial hypertension compared with that of meningioma invading the transverse sinus or sigmoid sinus.

In this patient, the venous sinuses were classified as type D according to cerebral angiograms. In addition, the tumor, although small, compressed the right transverse and sigmoid sinuses, causing marked stenosis. The left transverse sinus was hypoplastic, and the collateral development was poor, presumably resulting in the early appearance of symptoms of intracranial hypertension.

Treatment for meningioma invading the dominant transverse or sigmoid sinus has not been established. Resection of meningioma accompanied by resection and reconstruction of the venous sinuses is optimal, but it is difficult due to the risk of venous infarction when the tumor is adjacent to the dominant transverse sinus responsible for intracranial hypertension. In addition, reconstruction is more difficult if the meningioma is located at the junction of the transverse and sigmoid sinuses, as in this case. According to a report on aggressive surgical resection, the recurrence rate was low (4%), but 3% of the patients treated without venous sinus reconstruction died due to cerebral edema,¹⁵ and simultaneous resection of the venous sinuses was reported to be meaningless because it not only fails to reduce the recurrence rate but is also associated with a high complication rate.¹⁶ In the present case, we judged a one-stage operation consisting of total resection of the tumor and reconstruction of the venous sinuses to be risky, and considered as treatment options: (1) PTA of the stenosed part of the transverse sinus and the effect is insufficient, stenting of the transverse sinus (unapproved application), (2) embolization of the feeder of the meningioma to reduce the size of the tumor, (3) an LP-shunt to mitigate symptoms of intracranial hypertension, and (4) SRS to reduce the size of the tumor. Recently, stenting of the venous sinuses in patients with idiopathic venous sinus stenosis and those exhibiting symptoms of intracranial hypertension alone due to a small meningioma invading the venous sinuses has been reported with favorable results.¹⁷ However, the case reports of such treatments did not include long-term outcomes, and stenting requires prolonged administration of antiplatelets or anticoagulants.¹⁸ For our patient, we therefore selected PTA for the site of stenosis instead of stenting. However, no improvement in the pressure gradient between the proximal and distal sides of the stenosis or in the blood flow of the venous sinus was obtained by PTA. For this reason, based on the report that clinical remission and normalization of the ocular pressure are possible by reducing the tumor volume by partial resection,³ we performed

embolization of the feeder of the tumor using NBCA, considering decompression of the markedly stenosed venous sinuses by reducing the tumor size to be sufficient to increase the venous blood flow. Polyvinyl alcohol (PVA), Spongel, Embosphere and Gelpart, which are porous gelatin sponge particles (Nippon Kayaku, Tokyo), are often used as particulate embolic materials to embolize meningioma. One disadvantage of particulate embolic materials is that they may cause only occlusion of the proximal part of the artery, but NBCA is expected to reach intratumoral vessels. We selected NBCA for our patient because sufficient embolization of intratumoral vessels is effective for reducing the tumor volume. However, as the tumor volume-reducing effects appear slowly,⁴⁾ we placed an LP-shunt to alleviate the symptoms of intracranial hypertension as quickly as possible. Shunting is an established surgical procedure for idiopathic pseudotumour cerebri; however, according to our literature review, shunting has not been performed for symptoms of intracranial hypertension due to stenosis of the transverse and sigmoid sinuses by meningioma. Shunting, which can also be performed as an emergency procedure, is a useful technique that can quickly resolve primary complaints of intracranial hypertension. Radiosurgery is a useful adjuvant therapy for residual tumors,⁶⁾ and there is no difference in the tumor control by combinations, including gamma knife, for the management of enlargement of residual tumors between total and subtotal resection based on a 15-year follow-up study.¹⁹⁾ However, we did not perform SRS on our patient because of the possible exacerbation of edema after radiation therapy and induction of venous sinus obstruction by irradiation.²⁰⁾ From approximately half a year after treatment, the patient complained of low CSF symptoms, which persisted despite setting the LP-shunt pressure at the maximum. Thus, the LP-shunt was removed after 11 months because a decrease in the tumor size and improvement of stenosis due to tumor compression at the junction of the transverse and sigmoid sinuses were confirmed by contrast-enhanced MRI after 10 months, and the patient remained free of symptoms of intracranial hypertension for the following 18 months. In this case, compression of the venous sinuses was relieved by reducing the tumor volume by embolization without tumor resection, resulting in improvement of stenosis and disturbance of the blood flow of the venous sinuses, leading to clinical remission. However, the tumor may increase in size and compress the venous sinuses again in the future, necessitating long-term follow-up. We consider this treatment to be useful when the response to internal treatment and venous sinus reconstruction is poor.

Conclusion

We report a patient with symptoms of intracranial hypertension due to tumor compression of the dominant transverse and sigmoid sinuses, and hypoplasia of the contralateral transverse sinus. Although the optimal treatment was tumor resection, and partial resection and reconstruction of the venous sinuses invaded by the tumor, there was a high risk of venous infarction. We treated this patient by reducing the size of the tumor (80% reduction) by embolizing the feeding vessel without tumor resection, alleviating compression of the venous sinuses by the tumor, and improving stenosis and blood flow disturbance of the venous sinuses, leading to clinical remission. This treatment may be considered when the response to internal treatment and PTA is insufficient.

Disclosure Statement

The first author and coauthors have no conflicts of interest.

References

- 1) Porter KR, McCarthy BJ, Freels S, et al: Prevalence estimates for primary brain tumors in the United States by age, gender, behavior, and histology. *Neuro-oncology* 2010; 12: 520–527.
- 2) Bodkin PA, Hassan MF, Kane PJ, et al: ‘Surgical’ causes of benign intracranial hypertension. *J R Soc Med* 2008; 101: 259–261.
- 3) Mariniello G, Giamundo A, Donzelli R, et al: Intracranial hypertension due to meningioma of the unique transverse sinus. *Neuroradiol J* 2013; 26: 209–212.
- 4) Bendszus M, Martin-Schrader I, Schlake HP, et al: Embolisation of intracranial meningiomas without subsequent surgery. *Neuroradiology* 2003; 45: 451–455.
- 5) Chazal J, Janny P, Georget AM, et al: L’hypertension intracrânienne bénigne. Etude clinique. Etude physiopathologique: description d’un syndrome de gêne de la resorption du LCR. These, Clermont-Ferrand, 1979.
- 6) Chausson N, Bocquet J, Aveillan M, et al: Intracranial hypertension caused by a meningioma compressing the transverse sinus. *J Clin Neurosci* 2010; 17: 1589–1592.
- 7) Kim AW, Trobe JD: Syndrome simulating pseudotumor cerebri caused by partial transverse venous sinus obstruction in metastatic prostate cancer. *Am J Ophthalmol* 2000; 129: 254–256.
- 8) Owler BK, Parker G, Halmagyi GM, et al: Cranial venous outflow obstruction and pseudotumor Cerebri syndrome. *Adv Tech Stand Neurosurg* 2005; 30: 107–174.

- 9) Bodkin PA, Hassan MF, Kane PJ, et al: 'Surgical' causes of benign intracranial hypertension. *J R Soc Med* 2008; 101: 259–261.
- 10) Arnautović KI, Al-Mefty O, Angtuaco E, et al: Dural arteriovenous malformations of the transverse/sigmoid sinus acquired from dominant sinus occlusion by a tumor: report of two cases. *Neurosurgery* 1998; 42: 383–388.
- 11) Barua KK, Tamaki N, Ehara K, et al: Spontaneous peritumoral haemorrhage associated with sinus confluence meningioma: case report. *Surg Neurol* 2000; 54: 254–259.
- 12) Piazza O, De Robertis E, Caranci F, et al: Riedel's thyroiditis and cerebral venous sinuses thrombosis: a case report. *Panminerva Med* 2010; 52: 362–364.
- 13) Woodhale B. Variations of the cranial venous sinuses in the region of the torcular Herophili. *Arch Surg* 1936; 33: 297–302.
- 14) Hwang SK, Gwak HS, Paek SH, et al: Guidelines for the ligation of the sigmoid or transverse sinus during large petroclival meningioma surgery. *Skull Base* 2004; 14: 21–28; discussion 29.
- 15) Sindou MP, Alvernia JE: Results of attempted radical tumor removal and venous repair in 100 consecutive meningiomas involving the major dural sinuses. *J Neurosurg* 2006; 105: 514–525.
- 16) Tomasello F, Conti A, Cardali S, et al: Venous preservation-guided resection: a changing paradigm in parasagittal meningioma surgery. *J Neurosurg* 2013; 119: 74–81.
- 17) Ganesan D, Higgins JN, Harrower T, et al: Stent placement for management of a small parasagittal meningioma. Technical note. *J Neurosurg* 2008; 108: 377–381.
- 18) Haraguchi K, Matsumoto Y, Kondo R, et al: Percutaneous transluminal sinus angioplasty for transverse sinus-sigmoid sinus stenosis associated with recurrent dural arteriovenous fistula: case report. *JNET* 2010; 4: 33–39.
- 19) Sughrue ME, Rutkowski MJ, Shangari G, et al: Results with judicious modern neurosurgical management of parasagittal and falcine meningiomas. Clinical article. *J Neurosurg* 2011; 114: 731–737.
- 20) Abeloos L, Levivier M, Devriendt D, et al: Internal carotid occlusion following gamma knife radiosurgery for cavernous sinus meningioma. *Stereotact Funct Neurosurg* 2007; 85: 303–306.