

# Cryptococcal meningitis after transnasal transsphenoidal pituitary microsurgery of ACTH-secreting pituitary adenoma

## A case report

Yang Liu, MD, Ming Feng, MD, Yong Yao, MD, Kan Deng, MD, Xinjie Bao, MD, Xiaohai Liu, MD, Renzhi Wang, MD\*

### Abstract

**Rationale:** Microbial infection should be regarded in the differential diagnosis of neurosurgical complications after transnasal transsphenoidal pituitary microsurgery, albeit cryptococcal meningitis is rare. This article will discuss the risk factors of cryptococcal meningitis in patients underwent transnasal transsphenoidal pituitary microsurgery, and summary the potential origins of infection.

**Patient concerns and diagnosis:** Here, we report a case of 37-year-old male who had cryptococcal meningitis after transnasal transsphenoidal pituitary microsurgery of a relapsing ACTH-secreting pituitary adenoma.

**Intervention:** Standard therapy for *Cryptococcus neoformans* (fluconazole [400 mg per day] and flucytosine) was administered and followed by maintenance dose.

**Outcomes:** The patient had been on treatment for one and a half years during follow-up and reported neurologically well with repeated negative cerebrospinal fluid (CSF) culture until sudden death of heart arrest.

**Main lessons to learn:** *C. neoformans* can be a possible cause of meningitis in immunocompetent patients after transnasal transsphenoidal pituitary microsurgery. Risk factors, such as pre-existed pulmonary infection and Cushing-associated hypercortisolemia, should be stressed. Promising preventive measures may include preoperative routine sputum smear and India-ink stain for screening, preoperative treatment of cryptococcal pneumonia, postoperative antibiotic management, and a more secure skull base reconstruction. Radiation and pharmaceutical treatment may be alternative for recurrent Cushing disease.

**Abbreviations:** ACTH = adrenocorticotrophic hormone, CSF = cerebrospinal fluid, WBC = white blood cell.

**Keywords:** ACTH, cryptococcal meningitis, pituitary adenoma, transnasal transsphenoidal pituitary microsurgery

## 1. Introduction

Microbial infection should be regarded in the differential diagnosis of posttransnasal transsphenoidal neurosurgical complications. *Cryptococcus neoformans* was once recognized as an opportunistic pathogen among immunocompromised patients.<sup>[1]</sup> However, meningitis caused by *C. neoformans*, as a result of fungal dissemination from initial pulmonary infection in immunocompetent patients, was rarely seen. Here, we describe a patient who developed cryptococcal meningitis after transnasal

transsphenoidal excision of adrenocorticotrophic hormone (ACTH)-secreting pituitary adenoma. This should be the first report of immunocompetent individual who was infected with *C. neoformans* after surgeries with transnasal transsphenoidal approach.

## 2. Case report

This work was approved by the hospital's medical ethics committee. Informed consent was obtained in accordance with the institutional guidelines.

A 37-year-old man after transnasal transsphenoidal excision of ACTH-secreting pituitary adenoma 2 years ago was admitted with relapse of hypercortisolism for 4 months. Past history collection revealed negative history other major medical problems. He had no surgical history except the previous surgery for Cushing disease and he was not taking medicines. On admission, baseline inferior petrosal sinus to peripheral ACTH gradient was greater than 2, and inferior petrosal sinus to peripheral gradient after desmopressin activation was greater than 3. Contrast-enhanced pituitary magnetic resonance imaging evidenced hypointensity around the right-half pituitary gland. Thus, a transnasal transsphenoidal reoperation for relapsing pituitary tumor was indicated as elective surgery. Intraoperative leak was detected, and primary reconstruction of sella turcica was done using fascia lata and fibrin glue with fat packing of the sphenoid sinus. However, postoperative cerebrospinal fluid (CSF) leak still occurred and hypercortisolism was not alleviated with serum cortisol >75 µg/dL. Lumbar CSF

Editor: Somchai Amornyoitin.

YL and MF contributed equally to this work.

The authors have no funding and conflicts of interest to disclose.

Department of Neurosurgery, Peking Union Medical College Hospital, Peking Union Medical College and Chinese Academy of Medical Sciences, Beijing, China.

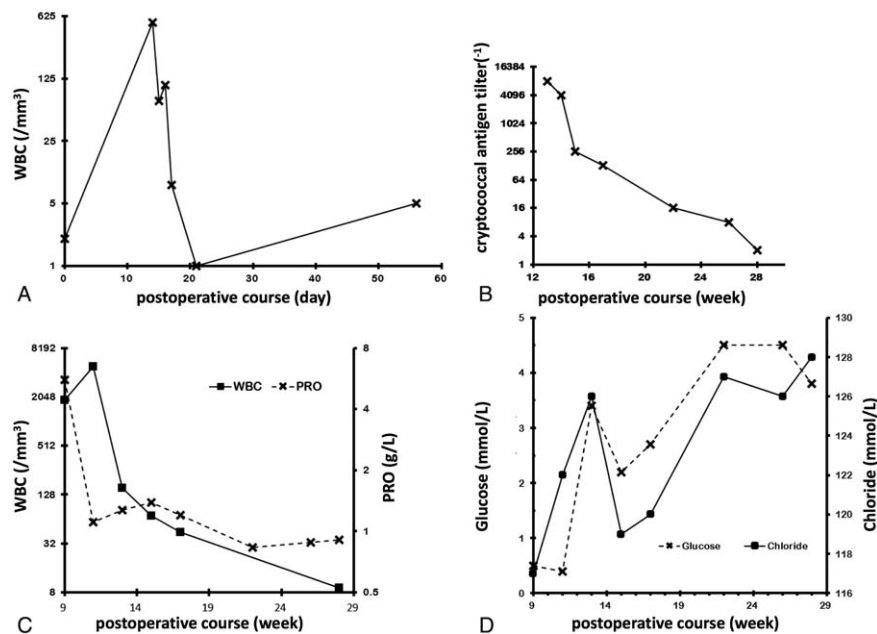
\* Correspondence: Renzhi Wang, Department of Neurosurgery, Peking Union Medical College Hospital, Peking Union Medical College and Chinese Academy of Medical Sciences, Beijing 100730, China (e-mail: 18611964099@126.com).

Copyright © 2017 the Author(s). Published by Wolters Kluwer Health, Inc. This is an open access article distributed under the Creative Commons Attribution-NoDerivatives License 4.0, which allows for redistribution, commercial and non-commercial, as long as it is passed along unchanged and in whole, with credit to the author.

Medicine (2017) 96:28(e7124)

Received: 29 March 2017 / Received in final form: 17 May 2017 / Accepted: 18 May 2017

<http://dx.doi.org/10.1097/MD.0000000000007124>



**Figure 1.** Biochemical monitor of CSF during antifungal course for Cryptococcal meningitis after transnasal transsphenoidal pituitary microsurgery. (A) Total WBC counts (CSF) during induction phase. (B) Cryptococcal antigen titer (CSF) during consolidation and maintenance phase. (C) Total WBC counts and protein levels (CSF) during consolidation and maintenance phase. (D) Glucose and chloride (CSF) during consolidation and maintenance phase. CSF=cerebrospinal fluid, WBC=white blood cell.

drainage was placed and CSF was regularly collected for laboratory study. Prophylactic cefuroxime was then administered.

The 1st month after surgery, the patient developed intermittent fever between 37 and 39°C. The diagnosis of suppurative meningitis was confirmed based on both the typical turbidity and the microscopic leukocyte counting of CSF. CSF germculture tests revealed oxacillin-resistant *Staphylococcus epidermidis* and *Acinetobacter baumannii*. Antibiotic scheme was modified into 3 courses of meropenem and vancomycin followed by 1 course of cefazidime, and the patient gradually restored normal body temperature and CSF test results returned to normal level.

Second month after surgery, the patient was presented with recurrent hyperpyrexia, neurological examination revealed stiff neck and Lasegue sign. Laboratory CSF study suggested central nervous system infection, with a leukocyte count of 4869/mm<sup>3</sup> (92% neutrophils and 8% monocytes), protein 5.58 g/L, glucose 0.5 mmol/L, and chloride ion 117 mmol/L. The patient was diagnosed with central nervous system infection based on the CSF results. But after administrating cefazidime and vancomycin empirically for 2 weeks, the CSF still showed high leukocyte count. Therefore, further microbiological investigation on CSF was conducted, including India-ink stain, which broke through with an encouraging result. Further past history collection regarding the patient's household environment did not suggest frequent contact with birds. Fungal culture of CSF grew cryptococcus species, and the titer of cryptococcal antigen was 1:8192. Further serum cryptococcal antigen titer was 1:1024. The patient started standard therapy as daily intravenous amphotericin B deoxycholate at 1 mg and oral flucytosine at 1 g tid. However, there was acute onset of epileptic seizure after administration of amphotericin B deoxycholate. Standard therapy had to be discontinued and alternated to intravenous fluconazole (400 mg qd) plus oral flucytosine (1 g tid) instead. Detailed data of CSF biochemistry during antifungal course for postsurgery cryptococcal meningitis was presented in Figure 1.

First week of antifungal therapy showed little effect. The patient was yet presented with fever, chill, even delirious status. But 1 week later, the patient's general condition went better. CSF re-evaluation revealed white blood cell (WBC) count 70/mm<sup>3</sup>, protein 1.39 g/L, and glucose 2.2 mmol/L, with negative fungal culture. The patient had been well on this antifungal therapy for 3 months. He then continued with maintenance therapy of oral fluconazole (400 mg per day) and flucytosine, without clinical relapse. Repeated CSF smears and CSF culture confirmed microbiologically negative.

One and a half years following the surgery, the patient developed acute onset of cyanosis, with oxygen saturation lower than 70% and blood pressure lower than 90/60 mmHg. Complete blood count was abnormal for WBCs as high as 12.6/mm<sup>3</sup> with neutrophilic predominance. Bedside chest X-ray revealed extensive plaques in his bilateral lungs. Pulmonary infection was highly suspected. Unfortunately, the patient had a heart arrest the other night, even cardiopulmonary resuscitation and epinephrine failed to retrieve his life.

### 3. Discussion

To our knowledge, cryptococcal meningitis following transnasal transsphenoidal pituitary microsurgery has not been reported previously. Common surgical complications of transnasal transsphenoidal pituitary microsurgery include pituitary dysfunction, CSF leak, and infection, which mainly comprises of sphenoiditis and meningitis. Transnasal transsphenoidal surgery entails the passage through nasal cavity, which is a flora reservoir for *Staphylococcus aureus*, *Haemophilus influenzae*, *Streptococcus pneumoniae*, *Staphylococcus epidermidis*, and other streptococcal species.<sup>[2]</sup> Such a clean-contaminated passage renders those microbes a way to the brain. Organisms predominantly involved in this surgical context are *S aureus*, coagulase-negative staphylococci, gram-negative bacillus, and enterococci<sup>[3]</sup>; however, *C neoformans* is rare condition.

*C neoformans* has been recognized as an opportunistic pathogen among immunocompromised patients.<sup>[1,4]</sup> Acquired immune deficiency syndrome epidemic has driven cryptococcal disease worldwide. Other underlying associations include the use of immunosuppressant, solid organ transplantation, malignancy, and congenital immunological disorders.<sup>[4]</sup> Apart from individuals with immunological defects, there have been reports of immunocompetent hosts developing cryptococcal infection.<sup>[1]</sup> By observation, cryptococcal meningitis among immunocompetent patients tends to have an indolent onset but harsh CSF result, with higher initial WBC count and higher protein level.<sup>[5]</sup> And our patient, who was presented with fever and stiff neck, just had typical CSF results.

Hypercortisolemia should be a risk factor for postoperative infection. Therefore for patients with Cushing syndrome who are suffering extreme hypercortisolism, the likelihood of developing bacterial or opportunistic infection can be greatest.<sup>[6]</sup> In our case, this is a 37-year-old male patient with relapsing ACTH-secreting pituitary adenoma. He did not arrive hormonal remission after transnasal transsphenoidal surgery, rendering him vulnerable to opportunistic infection. Other risk factors associated with immune compromise, such as malignancy or HIV infection, are not applicable to this patient. Another concern for cause of infection is pulmonary originated pathogens, that is, cryptococcal meningitis might be secondary to asymptomatic cryptococcal pneumonia. Previous report has demonstrated that patients with pulmonary cryptococcal infections usually show no symptoms until the disease disseminates to extrapulmonary sites, most notably to central nervous system.<sup>[7]</sup> In our case, this partially due to the stress of surgical excision, which bring down the immune system and unblock the fungal infection from disseminating into central nervous system. Direct spread from respiratory tract (nasopharynx) to brain through sphenoid sinus cannot be neglected as well.

This case deserves further reflections on measurements to avoid cryptococcal meningitis after transnasal transsphenoidal neurosurgery, especially for patients with Cushing syndrome. One of the major risk factors for neurosurgery-associated infection is persistent CSF leak.<sup>[8,9]</sup> Since CSF leak is the prime concern for transnasal transsphenoidal pituitary microsurgery,<sup>[10]</sup> different procedures on skull base reconstruction have been put forward. The combination of fascia lata graft, nasoseptal flap, and dura sealant show long-term effectiveness in secure closure of the cranial base.<sup>[11]</sup> Reconstruction with bone or bone substitute proved stable.<sup>[12]</sup>

Relapsing pituitary adenoma accounts for large percentage of pituitary surgeries. But do think twice before you operate on a relapsing pituitary adenoma. There are multiple reasons. First of all, reoperation of pituitary adenoma usually has poor outcome, unlikely to achieve biochemical remission. And the hypointensity foci on preoperative magnetic resonance imaging, which was suspected of recurrent tumor, might prove to be scar tissue by pathology. In such circumstance, positron emission tomography imaging potentially serves as a valuable tool in distinguishing recurrent adenoma, residue pituitary gland, and scar tissue. Also, a group of Cambridge team testified that 11C-methionine positron emission tomography-computed tomography may play a role in detection and treatment of ACTH-secreting tumors in Cushing syndrome.<sup>[13]</sup> Apart from surgical reintervention of the ACTH-secreting adenomas, there are alternatives including radiotherapy, adrenal surgery, and pharmaceutical therapy.<sup>[14]</sup> Progression has been made in the field of drug development, and pasireotide,<sup>[15]</sup> mifepristone, ketoconazole, metyrapone, and cabergoline<sup>[16]</sup> have approved effective in managing Cushing disease.<sup>[17]</sup>

Regarding treatment of cryptococcal meningitis, standard antifungal scheme for *C neoformans* has arrived at consensus and proved effective. But amphotericin B can bring the problem of drug intolerance. However, our experience suggests intravenous fluconazole might be an alternate.

This case serves to demonstrate that *C neoformans* can be a possible cause of meningitis after transnasal transsphenoidal pituitary microsurgery, and physicians must be aware of it. Perioperative management includes routine sputum smear and India-ink stain for pneumonia screening, preprocessing of cryptococcal pneumonia, empirical antibiotic management, regular and frequent neurological examination, and a more secure skull base reconstruction may secure a more stable postsurgical course.

## Acknowledgments

The authors would like to thank Dr. Rui Tian for her valuable comments and kind supports throughout this study.

## References

- Thompson HI. Not your "typical patient": cryptococcal meningitis in an immunocompetent patient. *J Neurosci Nurs* 2005;37:144-8.
- Somma T, Maraolo AE, Esposito F, et al. Efficacy of ultra-short single agent regimen antibiotic chemo-prophylaxis in reducing the risk of meningitis in patients undergoing endoscopic endonasal transsphenoidal surgery. *Clin Neurol Neurosurg* 2015;139:206-9.
- Bratzler DW, Dellinger EP, Olsen KM, et al. Clinical practice guidelines for antimicrobial prophylaxis in surgery. *Am J Health Syst Pharm* 2013;70:195-283.
- Sloan DJ, Parris V. Cryptococcal meningitis: epidemiology and therapeutic options. *Clin Epidemiol* 2014;6:169-82.
- Lui G, Lee N, Ip M, et al. Cryptococcosis in apparently immunocompetent patients. *QJM* 2006;99:143-51.
- Nicholas J, Sarlis SJC, Lynnette K. Nieman cortisolemic indices predict severe infections in cushing syndrome due to ectopic production of adrenocorticotropin. *J Clin Endocrinol Metab* 2000;85.
- Panigrahi MK, Kumar NN, Jaganathan V, et al. Pulmonary cryptococcosis with cryptococcal meningitis in an immunocompetent host. *Lung India* 2014;31:152-4.
- Eljamel MS, Foy PM. Acute traumatic CSF fistulae: the risk of intracranial infection. *Br J Neurosurg* 1990;4:381-5.
- Bernal-Sprekelsen M, Alobid I, Mullol J, et al. Closure of cerebrospinal fluid leaks prevents ascending bacterial meningitis. *Rhinology* 2005;43:277-81.
- Berker M, Hazer DB, Yucel T, et al. Complications of endoscopic surgery of the pituitary adenomas: analysis of 570 patients and review of the literature. *Pituitary* 2012;15:288-300.
- Hu F, Gu Y, Zhang X, et al. Combined use of a gasket seal closure and a vascularized pedicle nasoseptal flap multilayered reconstruction technique for high-flow cerebrospinal fluid leaks after endonasal endoscopic skull base surgery. *World Neurosurg* 2015;83:181-7.
- Cavallo LM, Messina A, Esposito F, et al. Skull base reconstruction in the extended endoscopic transsphenoidal approach for suprasellar lesions. *J Neurosurg* 2007;107:713-20.
- Koulouri O, Steuwe A, Gillett D, et al. A role for 11C-methionine PET imaging in ACTH-dependent Cushing's syndrome. *Eur J Endocrinol* 2015;173:M107-20.
- Espinosa-de-Los-Monteros AL, Sosa-Eroza E, Espinosa E, et al. Long-term outcome of the different treatment alternatives for recurrent and persistent Cushing's disease. *Endocr Pract* 2017;[Epub ahead of print].
- Guarnotta V, Ciresi A, Pitrone M, et al. Pasireotide versus pituitary surgery: a retrospective analysis of 12 months of treatment in patients with Cushing's disease. *Endocrine* 2017;doi: 10.1007/s12020-017-1276-7. [Epub ahead of print].
- Ferriere A, Cortet C, Chanson P, et al. Cabergoline for Cushing's disease: a large retrospective multicenter study. *Eur J Endocrinol* 2017;176:305-14.
- Ciato D, Mumbach AG, Paez-Pereda M, et al. Currently used and investigational drugs for Cushing's disease. *Expert Opin Invest Drugs* 2017;26:75-84.