



AKADEMISKA
SJUKHUSET

CASE REPORT FROM UPPSALA UNIVERSITY HOSPITAL

Symptomatic colloid cysts in the third ventricle of monozygotic twins

ELISABETH RONNE-ENGSTRÖM¹ & EDITH POPEK²

¹Department of Neuroscience, Section of Neurosurgery, Uppsala University, Uppsala, Sweden, and

²Department of Neurology, Örebro University Hospital, Örebro, Sweden

Abstract

In this case report we describe colloid cysts in the third ventricles of monozygotic twin sisters. They were 26 years old when their condition was discovered. One woman was admitted to us on an emergency basis, with signs of high intracranial pressure such as unconsciousness and extension posturing. Her sister was also brought to the hospital since she had a history of attacks of headache. They were both operated with removal of the colloid cysts, and the clinical courses are described in the case report. In reviewing the literature another 30 familial cases were found. Of these were two pairs of monozygotic and one pair of dizygotic twins.

Key words: *Intraventricular colloid cyst, twins*

Introduction

Colloid cysts in the third ventricle are of uncertain origin and occur in 1% of intracranial tumours. There have been previous reports on the familial occurrence of this condition. We were able to identify 30 published familial cases. Of these there were two pairs of monozygotic and one pair of dizygotic twins, the remaining being either parent–child or non-twin sibling pairs. The first case of monozygotic twin boys (1) had parents who were cousins. The boys had other malformations as well, including cataracts, retinal detachment, squint, and amblyopia. It was suggested that the cysts were a part of a diencephalic congenital malformation. One boy was symptomatic and was operated, while the other was followed. The second case of monozygotic twins was again two boys, one with symptoms and the other without. In the case of the dizygotic twin boys, both eventually developed symptoms, but more than a decade apart.

We can now report a third case involving monozygotic twins, in this case two sisters, admitted to our clinic when 26 years old. Both were operated for

symptomatic colloid cysts in the third ventricle within the same week. They also have a younger sister, and her MRI was found to be normal. The twin sisters gave their permission for publication of this case report.

Case report

The sisters were born full-term after a normal pregnancy and without previous medical problems.

Sister A

Sister A was admitted to us on an emergency basis. She had displayed some attacks that were initially interpreted as panic disorders. In the weeks before admission she had increasing problems with headache and neck pain, but she did not seek medical attention. On the day before admission she had a severe headache. Her boyfriend reported that she had attacks approximately every hour, during which she became unconscious and had spasms of the arms and legs. After these spasms she woke up and vomited. The following day they went to the emergency room. A CT

scan was done and a contrast-enhancing cyst in the third ventricle was found (Figure 1A). There was also a pronounced obstructive hydrocephalus. It was decided to transfer the patient immediately to the Department of Neurosurgery, Uppsala University Hospital. During the preparations for this she deteriorated again, became unconscious and displayed extension posturing. She also had bradycardia and arrhythmia. Her pupils dilated but still showed some slow reaction to light. She was intubated and transferred with intensive care helicopter to us, a 45-min flight.

On arrival to Uppsala she was withdrawing from painful stimuli. She went directly from the helicopter to the neurosurgical operating room and received a ventricular drain. She was treated with CSF drainage. Further investigations were done with MRI, supporting the diagnosis of an intraventricular colloid cyst. She was operated one week later, when we felt she had recovered sufficiently from the emergency event.

Surgery was carried out through a right-sided frontal craniotomy with a transcortical/transventricular approach to the cyst. Histopathology showed a single-layered epithelial cyst. Surgery was uneventful from a neurosurgical perspective, and she woke up soon afterwards. However, she contracted pneumonia and had to be reintubated. She also developed suspected meningitis, but bacterial growth could not be verified. The treatment of pneumonia and suspected meningitis was complicated by a severe adverse drug reaction to antibiotics. She developed a skin rash followed by a hepatic reaction and finally a transient kidney failure. After the pneumonia had been treated and the meningitis found to be aseptic, she was treated with steroids, which made the symptoms of meningitis disappear.

A CT scan before discharge showed bilateral infarctions in the territories of the posterior cerebral arteries. This was interpreted as caused by the impending herniation at the emergency event. On discharge to the home-town hospital one month later she was awake, but had a tracheostomy and was still on haemodialysis. Since then she has gradually improved, and her kidney function has improved.

Sister B

The day after Sister A had been admitted we got to know that she had a twin sister under investigation for severe headache. Contact was made with her home-town hospital. They brought her in the same day for a CT scan. This showed a large contrast-enhancing cyst in the third ventricle with a pronounced obstructive hydrocephalus (Figure 1B). She was in good clinical

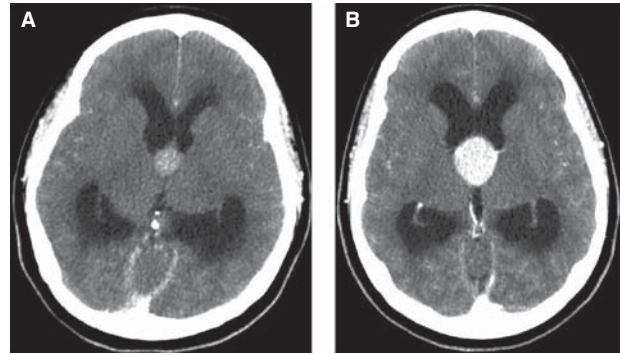


Figure 1. A: CT scan of Sister A, carried out when she went to the emergency room. There is a contrast-enhancing lesion in the third ventricle in the region of foramen Monroi. Also, there is a pronounced obstructive hydrocephalus with dilatation of the lateral ventricles. 201 × 201 mm (72 × 72 DPI). B: CT scan of Sister B, carried out when we got to know that she was under investigation for severe headache attacks. As in her twin sister, there is a contrast-enhancing lesion in the third ventricle in the region of foramen Monroi. There is a pronounced obstructive hydrocephalus with dilatation of the lateral ventricles as well. 201 × 201 mm (72 × 72 DPI).

condition otherwise, but was transferred to us on an emergency basis with intensive care helicopter.

She told us that she had suffered from headache attacks for a couple of years. These attacks were associated with blurred vision that lasted for only a short time. The headache was interpreted as migraine. The last year she had sometimes fainted in association with these attacks, and other persons had reported that she then had spasms in her arms. After arrival to us she was further investigated with MRI and was then operated, three days before her sister.

Surgery was carried out through a right-sided frontal craniotomy and a transcortical/transventricular approach to the cyst. Histopathology showed a benign cyst with a single-layered epithelium, WHO grade I. The postoperative course was uneventful, and she soon recovered fully.

Discussion

Including these monozygotic twin sisters, 32 cases of familial colloid cysts in the third ventricle have been reported (1-14): two previous reports of monozygotic twin brothers (1,9) and one pair of dizygotic twin brothers (14), and the remaining cases are siblings or parent-child. One-third of all twins are monozygotic, according to the Swedish twin register (15). If we include the now published cases, 3 out of 4 twin couples with colloid cysts were monozygotic, which is more than would be expected based on the natural prevalence ($p = 0.11$). This suggests that there may be a genetic component in the development of the cysts.

However, the genetic background for the familial colloid cysts is far from clear, and autosomal dominant as well as recessive genes have been suggested (9,11). We observed that 18 of 32 (56%) of the known familial cases were women. This is in contrast with many published series that show a male dominance (16). It is possible that the familial colloid cysts are of another nature than the single-appearing cysts. Also, the mean age for the cases becoming symptomatic in the familial cases seems to differ between men (mean 41 ± 21 years) and women (mean 35 ± 15 years). The natural course of the cysts has been studied, and it seems that patients with asymptomatic colloid cysts can safely be followed with serial neuroimaging (17). Neurosurgical intervention is necessary, however, if a patient shows symptoms, the cyst enlarges, or hydrocephalus develops (18). In that study the overall mortality of patients with symptoms was 12% during the 5-year follow up. It is surprising that our patients had severe and life-threatening symptoms for quite a long time before they had a CT scan done. CT scans on all patients with headache give a low yield, with only 22 significant findings and 1 colloid cyst in 1876 patients (19). Still, there must be a point when a physician has to rethink the postulated diagnosis. The combination of headache attacks with unconsciousness and blurred vision should lead to an immediate CT scan, and only when intracranial conditions have been proved normal can the headache investigation continue as before.

The complication with aseptic meningitis after cyst extirpation is a recognized clinical problem but only occasionally described. Wang and colleagues (20) reported a case with aseptic meningitis after extirpation of a colloid cyst in the fourth ventricle. Their cyst was adherent to the brain stem and could not be completely removed. The patient developed fever and an elevated CSF leukocyte count, but the microbiological examination was negative. The symptoms disappeared after steroid treatment had been initiated. We had a similar experience. Our patient developed pneumonia together with signs of meningitis. Once the pneumonia was treated and it was established that the meningitis was aseptic, treatment with steroids was started and the fever quickly disappeared. The pathophysiology of the aseptic reaction is unknown, but it is assumed that an inflammatory reaction to the cyst content is involved.

Surgical treatment of these cysts is a matter frequently discussed. Transcortical (21) or transcalsal (22,23) extirpation of the cyst are probably the most-used methods. They carry different risks, with epilepsy and memory deficits being the most severe, respectively. In recent years, less invasive techniques have been introduced, including endoscopic removal

(24) as well as stereotactic aspiration (25) and cyst wall rupture (26). It still has to be proven though whether or not these innovations are preferable to micro-neurosurgical removal. Endoscopic removal has been demonstrated to have fewer complications, but on the other hand more recurrence of the cysts (27).

Declaration of interest: The authors report no conflicts of interest. The authors alone are responsible for the content and writing of the paper.

References

1. Ibrahim AW, Farag H, Naguib M, Ibrahim E. Neuroepithelial (colloid) cyst of the third ventricle in identical twins. Case report. *J Neurosurg.* 1986;65:401-3.
2. Bengtson BP, Hedeman LS, Bauserman SC. Symptomatic neuroepithelial (colloid) cysts of the third ventricle. A unique case report in non-twin brothers. *Cancer.* 1990; 66:779-85.
3. Vandertop WP, Gosselaar PH, Nesselrooij B. Three sisters with colloid cyst of third ventricle. *Lancet.* 1995;346:643-4.
4. Akins PT, Roberts R, Coxe WS, Kaufman BA. Familial colloid cyst of the third ventricle: case report and review of associated conditions. *Neurosurgery.* 1996;38:392-5.
5. Mathiesen T, Grane P, Lindgren L, Lindquist C. Third ventricle colloid cysts: a consecutive 12-year series. *J Neurosurg.* 1997;86:5-12.
6. Aggarwal A, Corbett A, Graham J. Familial colloid cyst of the third ventricle. *J Clin Neurosci.* 1999;6:520-2.
7. Stoodley MA, Nguyen TP, Robbins P. Familial fatal and near-fatal third ventricle colloid cysts. *Aust N Z J Surg.* 1999;69: 733-6.
8. Nader-Sepahi A, Hamlyn PJ. Familial colloid cysts of the third ventricle: case report. *Neurosurgery.* 2000;46:751-3.
9. Ahmed SK, Stanworth PA. Colloid cysts of the third ventricle in identical twins. *Br J Neurosurg.* 2002;16:303-7.
10. Socin HV, Born J, Wallemacq C, Betea D, Legros JJ, Beckers A. Familial colloid cyst of the third ventricle: neuro-endocrinological follow-up and review of the literature. *Clin Neurol Neurosurg.* 2002;104:367-70.
11. Partington MW, Bookalil AJ. Familial colloid cysts of the third ventricle. *Clin Genet.* 2004;66:473-5.
12. Joshi SM, Gnanalingham KK, Mohaghegh P, Wilson A, Elsmore A. A case of familial third ventricular colloid cyst. *Emerg Med J.* 2005;22:909-10.
13. Babil MS, Vahedi P. Familial colloid cyst of the third ventricle in non-twin sisters: case report, review of the literature, controversies, and screening strategies. *Clin Neurol Neurosurg.* 2007;109:597-601.
14. Romani R, Niemela M, Korja M, Hernesniemi JA. Dizygotic twins with a colloid cyst of the third ventricle: case report. *Neurosurgery.* 2008;63:E1003; discussion E1003.
15. Lichtenstein P, De Faire U, Floderus B, Svartengren M, Svedberg P, Pedersen NL. The Swedish Twin Registry: a unique resource for clinical, epidemiological and genetic studies. *J Intern Med.* 2002;252:184-205.
16. Chen TC, Krieger M, Hinton DR, Zee CS, Apuzzo ML. The colloid cyst. In Mitchell CW, editor. *Surgery of the third ventricle.* 2nd ed. Baltimore: Williams and Wilkins; 1998. p 1047-132.
17. Pollock BE, Huston J 3rd. Natural history of asymptomatic colloid cysts of the third ventricle. *J Neurosurg.* 1999;91: 364-9.

18. de Witt Hamer PC, Verstegen MJ, De Haan RJ, Vandertop WP, Thomeer RT, Mooij JJ, et al. High risk of acute deterioration in patients harboring symptomatic colloid cysts of the third ventricle. *J Neurosurg.* 2002;96:1041–5.
19. Sempere AP, Porta-Etessam J, Medrano V, Garcia-Morales I, Concepcion L, Ramos A, et al. Neuroimaging in the evaluation of patients with non-acute headache. *Cephalalgia.* 2005;25:30–5.
20. Wang Z, Yan H, Wang D, Wang S, Liu R, Zhang Y. A colloid cyst in the fourth ventricle complicated with aseptic meningitis: a case report. *Clin Neurol Neurosurg.* 2012;114:1095–8.
21. Solaroglu I, Beskonakli E, Kaptanoglu E, Okutan O, Ak F, Taskin Y. Transcortical-transventricular approach in colloid cysts of the third ventricle: surgical experience with 26 cases. *Neurosurg Rev.* 2004;27:89–92.
22. Hernesniemi J, Romani R, Dashti R, Albayrak BS, Savolainen S, Ramsey C. 3rd, et al. Microsurgical treatment of third ventricular colloid cysts by interhemispheric far lateral transcallosal approach—experience of 134 patients. *Surg Neurol.* 2008;69:447–53.
23. Apuzzo ML, Chikovani OK, Gott PS, Teng EL, Zee CS, Giannotta SL, et al. Transcallosal, interfornicial approaches for lesions affecting the third ventricle: surgical considerations and consequences. *Neurosurgery.* 1982;10:547–54.
24. Boogaarts HD, Decq P, Grotenhuis JA, Le Guerinel C, Nseir R, Jarraya B, et al. Long-term results of the neuroendoscopic management of colloid cysts of the third ventricle: a series of 90 cases. *Neurosurgery.* 2011;68:179–87.
25. Rajshekhar V. Rate of recurrence following stereotactic aspiration of colloid cysts of the third ventricle. *Stereotact Funct Neurosurg.* 2012;90:37–44.
26. Kumar K, Kelly M, Toth C. Stereotactic cyst wall disruption and aspiration of colloid cysts of the third ventricle. *Stereotact Funct Neurosurg.* 1998;71:145–52.
27. Horn EM, Feiz-Erfan I, Bristol RE, Lekovic GP, Goslar PW, Smith KA, et al. Treatment options for third ventricular colloid cysts: comparison of open microsurgical versus endoscopic resection. *Neurosurgery.* 2007;60:613–18.