

# A Rare Bird: Diagnosis of Psittacosis Meningitis by Clinical Metagenomic Next-Generation Sequencing

K. Davar,<sup>1</sup> M. R. Wilson,<sup>2</sup> S. Miller,<sup>3,4</sup> C. Y. Chiu,<sup>3,4,5</sup> and T. Vijayan<sup>1</sup>

<sup>1</sup>Department of Medicine, Division of Infectious Diseases, University of California Los Angeles, Los Angeles, California, USA, <sup>2</sup>Weill Institute for Neurosciences, Department of Neurology, University of California San Francisco, San Francisco, California, USA, <sup>3</sup>Department of Laboratory Medicine, University of California San Francisco, San Francisco, California, USA, <sup>4</sup>UCSF-Abbott Viral Diagnostics and Discovery Center, San Francisco, California, USA, <sup>5</sup>Department of Medicine, Division of Infectious Diseases, University of California San Francisco, San Francisco, California, USA.

Psittacosis is a zoonotic infectious disease caused by the transmission of *Chlamydia psittaci*; it often presents as a pulmonary infection but rarely as disseminated disease. Because diagnoses of psittacosis are often underreported due to infrequent pathogen-specific testing, clinical metagenomic next-generation sequencing may be helpful to diagnose such an uncommon syndrome.

**Keywords.** *Chlamydia Psittaci*; clinical metagenomic next-generation sequencing; meningitis; psittacosis; zoonotic infection.

Psittacosis is a zoonotic infectious disease caused by the transmission of *Chlamydia psittaci* from birds to humans via contaminated aerosols from animal urine, feces, and respiratory secretions [1]. Psittacosis accounts for approximately 1% of cases of community-acquired pneumonia worldwide [1]. Diagnosis of psittacosis is often underreported due to infrequent pathogen-specific testing and usual empiric treatment of pneumonia. Psittacosis typically presents as a pulmonary infection; rarely, it manifests as disseminated disease.

Clinical metagenomic next-generation sequencing (mNGS) is an emerging approach for diagnosis of infections that relies on identification of genus or species-specific microbial reads in complex shotgun sequence data generated from clinical samples [2]. Clinical mNGS is particularly useful for unexpected and/or rare infections whose etiology was not considered a priori [3, 4]. In this study, we present the use of clinical mNGS

for diagnosis of a case of *C psittaci* meningitis, which has been infrequently reported in the medical literature.

## PATIENT CONSENT STATEMENT

The patient's written consent was obtained before publication and conforms with the current standards in the country of origin for patient consent and confidentiality.

## CASE PRESENTATION

A 67-year-old man with a past medical history significant for hypertension, dyslipidemia, and basal cell carcinoma presented with fevers, night sweats, arthralgias, and nonproductive cough.

He had traveled to Europe with his wife 2 months before his initial hospitalization in the fall. While spending time in Sicily, the Aeolian Islands, and Portugal, he had experienced fevers, malaise, a dry cough, and nonbloody, watery stools. Upon returning to United States, he saw his primary physician due to persistent fever and was found to be in acute renal failure. Microscopic hematuria was identified on urinalysis and he was admitted to the hospital.

Known exposures during the patient's travel to Europe included raw fish and unpasteurized cheese consumption with a stay on a farm with cows in Sicily, hiking on trails and beach activities, mosquito bites, and parrot sightings. While in Sicily, his resort would serve breakfast outdoors where he would occasionally notice parrots in the tree tops. He enjoys the outdoors, and he would often go for runs or hikes in the hills surrounding the Los Angeles basin.

An extensive workup was unrevealing, including negative microbiologic testing for stool bacterial and parasitic pathogens, endemic and opportunistic fungi, *Bartonella* spp, *Brucella* spp, *Rickettsia* spp, *Coxiella burnetii*, and *Leptospira interrogans*. The sole positive finding was a respiratory pathogen panel (RPP) positive for rhinovirus/enterovirus, although a chest radiograph was unremarkable. The patient was started on ceftriaxone and doxycycline and was transitioned to oral ciprofloxacin to complete a 5-day total course of antibiotics for presumed enteric fever. His symptoms resolved with the exception of a persistent but overall improved dry cough.

Two months later in the winter, he began experiencing an exacerbation of his nonproductive cough with increased frequency. He developed new onset of sinus congestion, malaise, muscle aches, headaches, and fevers. He denied any pharyngitis, nausea, vomiting, diarrhea, dysuria, or adenopathy. He had traveled to New York the prior month to see family, including his young grandchildren. None of his family members were sick and he denied any other unusual exposures at that time. He was evaluated in the infectious disease clinic where he was found

Received 9 June 2021; editorial decision 26 October 2021; accepted 2 November 2021; published online 8 December 2021.

Correspondence: Kusha Davar, MD, MBA, MS, 10833 Le Conte Ave., Room 37-121 CHS, Los Angeles, CA 90095, USA (kdavar@dhs.lacounty.gov).

## Open Forum Infectious Diseases® 2021

© The Author(s) 2021. Published by Oxford University Press on behalf of Infectious Diseases Society of America. This is an Open Access article distributed under the terms of the Creative Commons Attribution-NonCommercial-NoDerivs licence (<https://creativecommons.org/licenses/by-nc-nd/4.0/>), which permits non-commercial reproduction and distribution of the work, in any medium, provided the original work is not altered or transformed in any way, and that the work is properly cited. For commercial re-use, please contact journals.permissions@oup.com <https://doi.org/10.1093/ofid/ofab555>

to have a fever of 39.5°C and was sent to the hospital for further evaluation. His blood pressure and oxygen saturation were normal.

Upon admission to the hospital, he was noted to have slow speech, word finding difficulties, and a markedly stiff neck. Pertinent negative findings included an absence of photophobia, clear lungs to auscultation, and a normal cardiac exam. Laboratory work revealed leukocytosis (white blood cell [WBC] count of  $13.87 \times 10^6/\mu\text{L}$  [normal  $4.16\text{--}9.95 \times 10^6/\mu\text{L}$ ]), anemia (hemoglobin 9.4 g/dL [normal 13.5–17.1 g/dL]), and hyponatremia (sodium 127 mmol/L [normal 135–146 mmol/L]). The RPP testing was positive for a seasonal coronavirus (229E, HKU1, NL63, or OC43). Testing for severe acute respiratory syndrome coronavirus 2 (SARS-CoV-2) was not performed, because the patient had been hospitalized 1 month before the first reported case of SARS-CoV-2 in the United States.

A noncontrast computed tomography (CT) scan of his chest showed minor patchy distorted ground glass and airspace attenuation within the lingula, consistent with resolving pneumonia or aspiration. A noncontrast sinus CT scan revealed mild paranasal sinus mucosal thickening. Magnetic resonance imaging of the brain, performed with and without contrast, showed no acute infarct, intracranial hemorrhage, mass effect, or abnormal enhancement.

The patient underwent a lumbar puncture given concern for meningitis. The cerebrospinal fluid (CSF) profile revealed a lymphocytic and monocytic pleocytosis with normal glucose and elevated protein (Table 1). Bacterial, fungal, and viral cultures

from both serum and CSF were negative, as were *Rickettsia* serologies.

Empiric antimicrobial treatment was initiated with levofloxacin, ampicillin, and acyclovir. The patient improved with resolution of his fever and fluency of speech over the next 3 days. Acyclovir was discontinued after negative CSF polymerase chain reaction (PCR) testing for herpes simplex virus, and he completed a 5-day course of levofloxacin for community-acquired pneumonia. Repeat lumbar puncture showed an improved CSF profile, with decreasing WBC count and protein. His ampicillin was changed to trimethoprim/sulfamethoxazole after he developed a drug-associated morbilliform rash within 3 days of starting antibiotics, and he completed a 14-day course after discharge for empiric treatment of *Listeria* meningitis. He ultimately achieved full resolution of his clinical symptoms.

The patient's CSF sample was sent for clinical mNGS testing, which revealed the detection of sequence reads mapping to *C psittaci* (Figure 1), although below the threshold level for reporting. Follow-up serologic testing done for confirmation of mNGS results was immunoglobulin (Ig)G and IgM negative for *C psittaci*, but IgG positive for *Chlamydia pneumoniae*. The presence of *C psittaci* in the CSF was subsequently confirmed by positive PCR testing done by the US Centers for Disease Control and Prevention (CDC).

## DISCUSSION

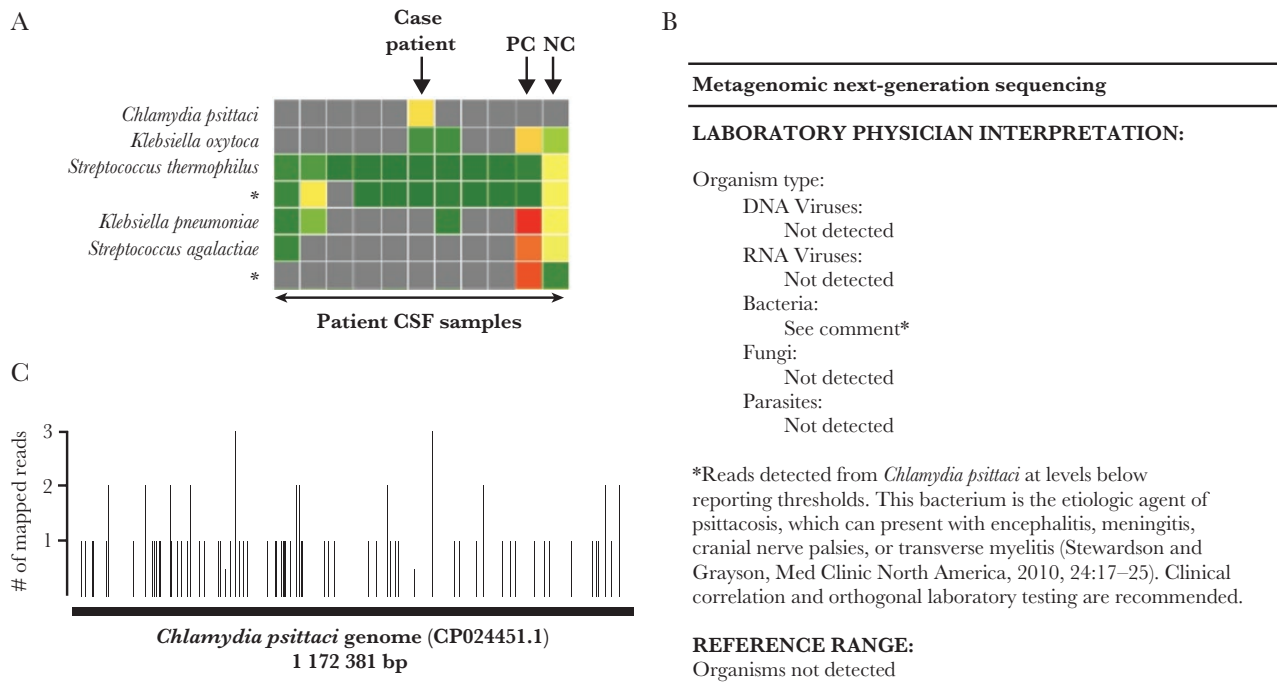
*Chlamydia psittaci* can cause various clinical syndromes, the most common of which is pneumonia. With pulmonary disease, a chest x-ray typically shows interstitial findings or lobar consolidation [5]. It is notable that neurological symptoms may be common with headache reported in 38% of patients and more severe symptoms such as photophobia, neck stiffness, and mental status changes occurring in 5%–9% of patients [6]. In addition, signs and symptoms localizing to the cerebellum can be seen [6]. Case reports have also described cryptogenic seizures as a presentation of psittacosis with neurologic involvement [7]. However, true meningitis with pleocytosis is uncommon [6]. Although the pathogenesis of neuroinvasive disease from psittacosis is unclear, localized vasculitis and an association with cold agglutinins have been hypothesized as potential precipitating factors [6]. *Chlamydia psittaci* deoxyribonucleic acid has also been detected in CSF from a patient in status epilepticus [8].

Tetracyclines are the therapeutic agent of choice for psittacosis. Most patients defervesce within 48 hours of initiating therapy, and treatment is generally continued for 7 to 10 days. Macrolides are recommended as second-line therapy when tetracyclines are contraindicated, including in children or in pregnancy [9]. The disease has also been successfully treated with fluoroquinolones, although the true efficacy of this class of antibiotics remains unknown [10].

**Table 1. Initial and Repeat CSF Findings**

CSF Studies	Initial CSF	Repeat CSF (48 Hours)
WBC/cmm	373 (0–5)	71 (0–5)
PMN (%)	22 (No reference range)	4 (No reference range)
Lymphocytes (%)	30 (40–80)	66 (40–80)
Monocytes (%)	46 (15–45)	29 (15–45)
Glucose (mg/dL)	65 (43–73)	45 (43–73)
Protein (mg/dL)	222 (15–45)	176 (15–45)
RBC/cmm	0 (0–10)	2 (0–10)
Bacterial/Fungal/AFB Cx	Negative	–
MTB PCR	Negative	–
Cocci EIA/ID/CF	Negative	–
West Nile IgM/IgG and PCR	Negative	–
HSV 1/2 PCR	Negative	–
VZV PCR	Negative	–
Meningoencephalitis (BioFire) Panel	Negative	–
UCSF mNGS	Positive— <i>Chlamydia psittaci</i>	–
CDC <i>Chlamydia psittaci</i> PCR	Positive	–

Abbreviations: AFB, acid-fast bacilli; CDC, Centers for Disease Control and Prevention; CF, complement fixation; CSF, cerebrospinal fluid; EIA, enzyme immunoassay; HSV, herpes simplex virus; ID, immunodiffusion; Ig, immunoglobulin; PCR, polymerase chain reaction; mNGS, metagenomic next-generation sequencing; MTB, *Mycobacterium tuberculosis*; PMN, polymorphonuclear; RBC, red blood cells; UCSF, University of California San Francisco; VZV, varicella-zoster virus; WBC, white blood cells.



**Figure 1.** Detection of *Chlamydia psittaci* by metagenomic next-generation sequencing (mNGS) of cerebrospinal fluid (CSF). (A) Heat map of sequence reads mapping to bacterial species (rows) corresponding to patient CSF samples from the run (columns), showing reads to *C psittaci* in only the case patient sample and not in the other clinical, positive control (PC), and negative control (NC) samples on the run. The spiked bacteria in the PC consist of *Klebsiella pneumoniae* and *Streptococcus agalactiae* [17]. The heat map is color coded by normalized number of reads from green to red, with a gray color denoting 0 reads. Rows with an asterisk indicate reads that are not species-specific and thus are declassified to a higher taxonomic level. (B) Results report from clinical CSF mNGS testing of the case patient's CSF, showing detection of reads from *C psittaci* at levels below formal reporting thresholds. (C) Mapping of the 90 mNGS reads from *C psittaci* to reference genome CP024451.1; the reads are observed to span the entire 1,172,381-bp genome.

Our patient presented initially with an indolent course, including nonproductive cough and nonspecific symptoms in the setting of normal chest radiographic imaging, which developed into meningitis. His CSF demonstrated pleocytosis, which is not typically described in psittacosis [6]. Although serologic testing was negative for *C psittaci*, molecular testing with clinical mNGS and confirmatory PCR was positive. Due to the lack of routine testing and a relatively insensitive serologic method of diagnosis, the true specificity of *C psittaci* PCR testing in an unconfirmed clinical sample is unclear [11]. However, the analytic sensitivity and specificity of confirmed human samples of *C psittaci* seems to be 100% [12]. In addition, it remains uncertain the amount of time clinical specimens may remain PCR positive after exposure and inoculation. Not uncommonly, sensitivity may decrease with time since exposure to the pathogen and with prior antibiotic use [13].

The typical incubation period for *C psittaci* is up to 14 days, making the exposure in Italy 2 months prior an unusual inference. Re-exposure is also plausible, because the Black-hooded parakeet is common in parts of Malibu and the Pacific Palisades, areas where the patient would frequently run or hike [14]. The CSF is an immune-privileged site, so the organism may have established an intracellular reservoir in the central nervous system before reaching a threshold of symptomatic infection.

Furthermore, he had an episode of microscopic hematuria that had been unexplained, and this may be seen in psittacosis [15]. Ultimately, it is impossible to determine whether the 2 periods of symptoms were a related process or whether exposure to parrots in Europe or in Southern California had led to his infection with *C psittaci*. Resolution of his symptoms with 5 days of empiric levofloxacin therapy suggests potential efficacy of this drug in cases of psittacosis meningitis.

**CONCLUSIONS**

Clinical mNGS is increasingly being used for the identification of infections from rare and/or unexpected pathogens or in the setting of unusual clinical presentations that are challenging for clinicians to diagnose [16–21]. The identification of reads from *C psittaci* in the CSF at subthreshold levels underscores the clinical utility of communicating these findings as part of the mNGS report [3]. Subthreshold results can be used to guide further diagnostic testing and inform treatment decisions when placed in clinical context, generally after consultation via a clinical microbial sequencing board teleconference [22].

**Acknowledgments**

We thank the patient and his family for allowing us to describe his clinical course.

**Author contributions.** All authors have seen the manuscript and have significantly contributed.

**Financial support.** This work was funded in part by the California Initiative to Advance Precision Medicine (to M. R. W., S. M., and C. Y. C.), Charles and Helen Schwab Foundation (to C. Y. C.), and the UCSF Center for Accelerated Innovation (CAI), under National Institutes of Health (NIH) National Heart, Lung, and Blood Institute UC CAI Grant U54HL119893, NIH National Institute of Neurological Disorders and Stroke Grant K08NS096117 (to M. R. W.), and National Center for Advancing Translational Sciences UCSF CTSI Grant UL1TR001872.

**Potential conflicts of interest.** All authors: No reported conflicts of interest. All authors have submitted the ICMJE Form for Disclosure of Potential Conflicts of Interest.

## References

1. Hogerwerf L, DE Gier B, Baan B, VAN DER HOEK W. *Chlamydia psittaci* (psittacosis) as a cause of community-acquired pneumonia: a systematic review and meta-analysis. *Epidemiol Infect* **2017**; 145:3096–105.
2. Chiu CY, Miller SA. Clinical metagenomics. *Nat Rev Genet* **2019**; 20:341–55.
3. Wilson MR, Sample HA, Zorn KC, et al. Clinical metagenomic sequencing for diagnosis of meningitis and encephalitis. *N Engl J Med* **2019**; 380:2327–40.
4. Gu W, Deng X, Lee M, et al. Rapid pathogen detection by metagenomic next-generation sequencing of infected body fluids. *Nat Med* **2021**; 27:115–24.
5. Branley JM, Weston KM, England J, et al. Clinical features of endemic community-acquired psittacosis. *New Microbes New Infect* **2014**; 2:7–12.
6. Hughes P, Chidley K, Cowie J. Neurological complications in psittacosis: a case report and literature review. *Respir Med* **1995**; 89:637–8.
7. Ionescu AM, Khare D, Kavi J. Birds of a feather: an uncommon cause of pneumonia and meningoencephalitis. *BMJ Case Rep* **2016**; 2016:bcr2016216879.
8. Walder G, Schönherr H, Hotzel H, et al. Presence of *Chlamydophila psittaci* DNA in the central nervous system of a patient with status epilepticus. *Scand J Infect Dis* **2003**; 35:71–3.
9. Yung AP, Grayson ML. Psittacosis—a review of 135 cases. *Med J Aust* **1988**; 148:228–33.
10. Leroy O, Beuscart C, Chidiac C, et al. [Treatment of pneumonia caused by Legionella, Mycoplasma, Chlamydiae and Rickettsia using ofloxacin]. *Pathol Biol (Paris)* **1989**; 37:1137–40.
11. McGovern OL, Kobayashi M, Shaw KA, et al. Use of real-time PCR for *Chlamydia psittaci* detection in human specimens during an outbreak of psittacosis - Georgia and Virginia, 2018. *MMWR Morb Mortal Wkly Rep* **2021**; 70:505–9.
12. Wolff BJ, Morrison SS, Winchell JM. Development of a multiplex TaqMan real-time PCR assay for the detection of *Chlamydia psittaci* and *Chlamydia pneumoniae* in human clinical specimens. *Diagn Microbiol Infect Dis* **2018**; 90:167–70.
13. Nieuwenhuizen AA, Dijkstra F, Notermans DW, van der Hoek W. Laboratory methods for case finding in human psittacosis outbreaks: a systematic review. *BMC Infect Dis* **2018**; 18:442.
14. Garret KL. Population status and distribution of naturalized parrots in Southern California. *Western Birds* **1997**; 28:181–195.
15. Chang KP, Veitch PC. Fever, haematuria, proteinuria, and a parrot. *Lancet* **1997**; 350:1674.
16. Solomon IH, Ganesh VS, Yu G, et al. Fatal case of chronic Jamestown Canyon virus encephalitis diagnosed by metagenomic sequencing in patient receiving rituximab. *Emerg Infect Dis* **2021**; 27:238–42.
17. Naccache SN, Peggs KS, Mattes FM, et al. Diagnosis of neuroinvasive astrovirus infection in an immunocompromised adult with encephalitis by unbiased next-generation sequencing. *Clin Infect Dis* **2015**; 60:919–23.
18. Murkey JA, Chew KW, Carlson M, et al. Hepatitis E virus-associated meningoencephalitis in a lung transplant recipient diagnosed by clinical metagenomic sequencing. *Open Forum Infect Dis* **2017**; 4:ofx121.
19. Mongkolrattanothai K, Naccache SN, Bender JM, et al. Neurobrucellosis: unexpected answer from metagenomic next-generation sequencing. *J Pediatric Infect Dis Soc* **2017**; 6:393–8.
20. Wilson MR, O'Donovan BD, Gelfand JM, et al. Chronic meningitis investigated via metagenomic next-generation sequencing. *JAMA Neurol* **2018**; 75:947–55.
21. Wilson MR, Suan D, Duggins A, et al. A novel cause of chronic viral meningoencephalitis: Cache Valley virus. *Ann Neurol* **2017**; 82:105–14.
22. Miller S, Naccache SN, Samayoa E, et al. Laboratory validation of a clinical metagenomic sequencing assay for pathogen detection in cerebrospinal fluid. *Genome Res* **2019**; 29:831–42.