

Infliximab treatment–induced paradoxical psoriasiform reaction in patient with psoriasis vulgaris showing positive lymphocyte transportation test reaction

Yasue Ishii-Osai, MD, Akihiro Yoneta, MD, Noriko Mizugaki, MD, Hitomi Takahashi, MD, and Toshiharu Yamashita, MD
Sapporo, Japan

Key words: cyclosporine; infliximab; lymphocyte transportation test; paradoxical psoriasis; psoriasis; tumor necrosis factor alfa antagonists.

Tumor necrosis factor alfa (TNF- α) antagonists are commonly used to treat inflammatory disorders and are considered particularly effective in the treatment of moderate to severe psoriasis. Paradoxically, however, new-onset occurrence or worsening of psoriasis has been increasingly recognized among patients treated with TNF- α antagonists. We report on a 60-year-old man who developed a severe psoriatic condition with diffuse alopecia during infliximab therapy for psoriasis, resulting in the discontinuation of infliximab. Lymphocyte transportation test (LTT) results were positive. Currently, there are few reports of LTT-positive cases that are related to paradoxical reactions by TNF- α antagonists. We discuss the relationship between paradoxical reaction and the mechanisms of LTT.

CASE REPORT

Before admittance to our clinic, a 60-year-old man with a 7-year history of psoriasis vulgaris received treatment consisting of topical steroids, topical vitamin D analogs, ultraviolet therapy, and cyclosporine at 2 different hospitals. Because his psoriasis showed no signs of improvement from these treatments, in May 2013 he received 5 mg/kg of infliximab at weeks 0, 2, and 6. One and a half months after the initiation of the infliximab treatment, pruritic scaly plaques developed on his trunk. After another 2 weeks, he became erythrodermic over his entire body (Fig 1, A and B). He showed diffuse

Abbreviations used:

IFN- α : interferon alfa
LTT: lymphocyte transportation test
TNF- α : tumor necrosis factor–alfa

alopecia on the scalp, and thick scales were observed on the palms and soles (Fig 1, C and D). A skin biopsy specimen showed psoriasiform epidermal hyperplasia with hyperkeratosis and parakeratosis, telangiectasia, perivascular lymphocytic infiltrate, and a small number of eosinophils in the papillary dermis (Fig 2).

Serologic analysis found eosinophilia (total white blood cells $8 \times 10^3/\mu\text{L}$ with 15.2% eosinophils). LTT was performed twice. The stimulation index (SI) was 237% (normal range, <180%) at the second week after the rashes appeared and 183% at the fourth month. Consequently, an infliximab-induced paradoxical reaction was diagnosed.

Infliximab was discontinued, and treatment with topical steroids and maxacalcitol commenced. However, there was no response to the topical therapies, and cyclosporine was subsequently started (2.5 mg/kg/d). Marked improvement was observed immediately, and the psoriasiform eruption disappeared after 9 months. Complete hair regrowth was observed after 12 weeks. The cyclosporine dosage was tapered to 1.5 mg/kg/d, and there has been no recurrence to date (November 2014).

From the Department of Dermatology, Sapporo Medical University School of Medicine.

Funding sources: None.

Conflicts of interest: None declared.

Correspondence to: Yasue Ishii-Osai, MD, Department of Dermatology, Sapporo Medical University School of Medicine, Sapporo, 060-8543, Japan. E-mail: y-osai@sapmed.ac.jp.

JAAD Case Reports 2015;1:230-3.
2352-5126

© 2015 by the American Academy of Dermatology, Inc. Published by Elsevier, Inc. This is an open access article under the CC BY-NC-ND license (<http://creativecommons.org/licenses/by-nc-nd/4.0/>).

<http://dx.doi.org/10.1016/j.jidcr.2015.05.007>

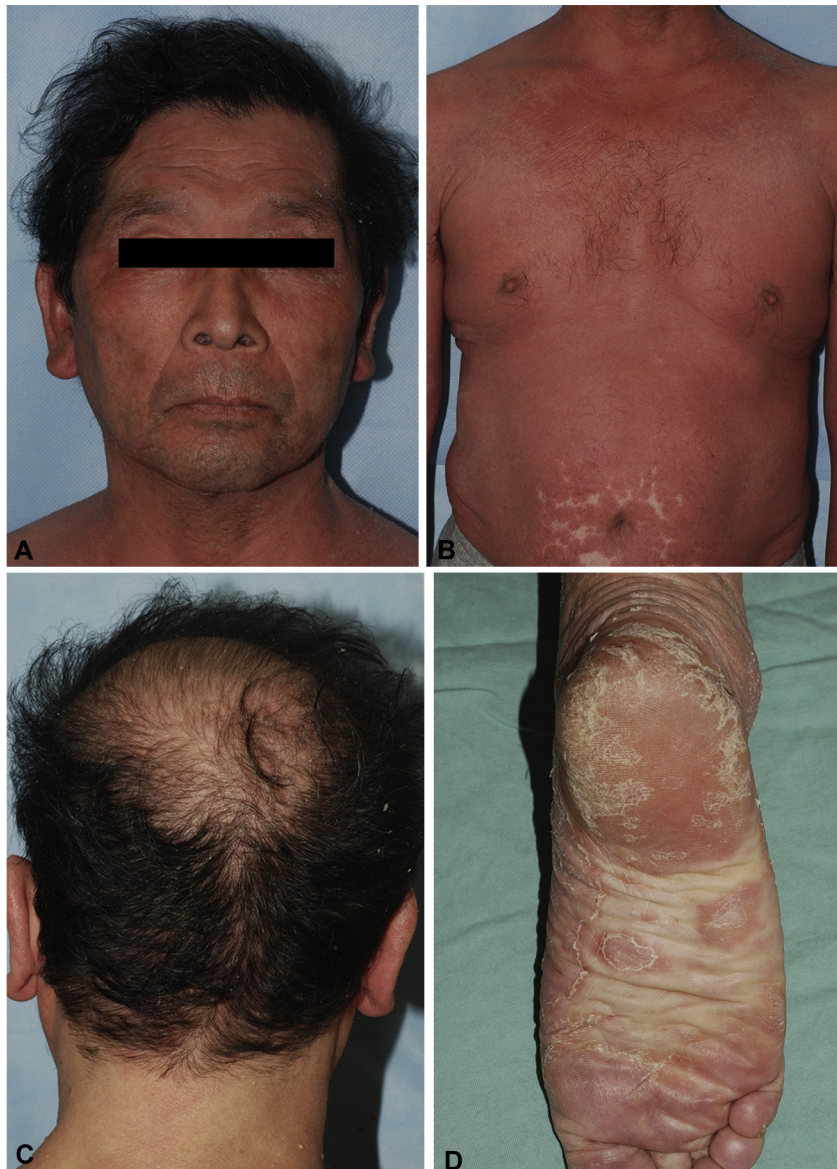


Fig 1. Clinical appearance on admission. **A,** Face. **B,** Body. **C,** Scaly erythema associated with alopecia. **D,** The right sole.

DISCUSSION

If successfully used, TNF- α antagonists can lead to significant improvement of disease activity in patients with a variety of autoimmune diseases and inflammatory disorders, particularly psoriasis. However, in recent years, there have been increasing reports of induced or exacerbated psoriasis among patients receiving anti TNF- α therapy.

These adverse reactions have been noted in all TNF- α inhibitors and have occurred in patients with any disease in which these agents are used as treatment. The incidence of TNF- α inhibitor-induced psoriasis has been estimated at 1.5% to 5%.^{1,2} Duration of therapy before onset or worsening of psoriasis has ranged from 2 weeks to 48 months.³

Interestingly, rash prognosis varies widely according to individual cases. Collamer et al⁴ analyzed 114 cases of paradoxical psoriasis, among which most patients (61%) were able to continue TNF- α antagonist therapy. However, 25% had to discontinue treatment, and some who later resumed therapy with the same agent or another TNF- α inhibitor suffered relapses.

The mechanism of TNF- α inhibitor-induced paradoxical psoriasis remains unclear. The most widely accepted hypothesis suggests there is an interaction between TNF- α and interferon alfa (IFN- α). IFN- α is an important cytokine that controls natural immunity and is mainly produced from plasmacytoid dendritic cells through stimuli such as infection or trauma.

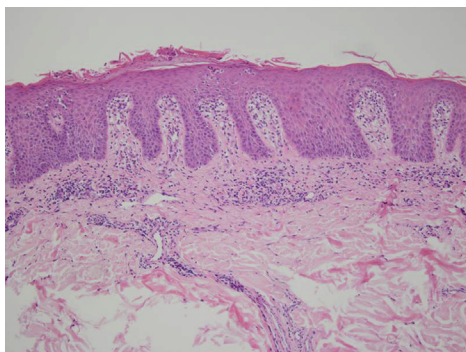


Fig 2. Histologic specimen. Psoriasiform epidermal hyperplasia, telangiectatic blood vessels, perivascular lymphocytic infiltrate, and a small number of eosinophils in the papillary dermis. (Hematoxylin-eosin stain; original magnification: $\times 40$.)

IFN- α is also identified as a key element in the early phase of psoriatic induction.^{5,6} TNF- α negatively regulates IFN- α production.⁷ Therefore, anti-TNF- α therapy could increase IFN- α expression at the tissue level and induce psoriasis. Seneschal et al⁸ found a stronger production of the human myxovirus resistance protein 1 that represented a specific marker for type I IFN signaling in psoriasiform eruptions under TNF- α treatment.

There are cases that could continue using the TNF- α antagonist or show improvement if treatment were changed to other types of biologic therapies such as anti-interleukin-12/23 antibodies or anti-interleukin-17A antibodies.⁴ This finding suggests that the increase of IFN- α may only be a manifestation trigger, and the following course may be the same as that of primary psoriasis. In addition, there is a large time lag between administration and development of psoriatic lesions. It is presumably because the balance between TNF- α and IFN- α varies among individuals. In addition, certain environmental triggers (infections, ultraviolet irradiation, trauma) may be involved in the development of psoriasis.

The main mediator of adverse drug reactions is typically lymphocytes. LTT is a test to identify antigen-specific T cells to specific drugs in vitro. The peripheral blood T cells are cultured with the incriminated drug, and their subsequent proliferation was measured by harvesting ³H-thymidine. The results were expressed as the SI (SI = counts per minute with drug/without drug.)

Although there is no consensus about when the test should be performed, Kano et al⁹ found that LTT should be performed within 1 week after the onset of Stevens-Johnson syndrome or toxic epidermal necrolysis and 5 to 8 weeks after the onset of the cutaneous eruptions in cases of drug-

induced hypersensitivity syndrome or drug reaction with eosinophilia and systemic symptoms. This finding suggests that regulatory T cells that increase during the acute stage may play a role in the suppression of T-cell proliferation in patients with drug-induced hypersensitivity syndrome/drug reaction with eosinophilia and systemic symptoms.⁹

There are no reports indicating LTT shows a false-positive result in patients treated with anti-TNF agents. Therefore, in this study, LTT was performed at 2 weeks (the acute stage) and again at 4 months (at the time in which the influence of this medicine was expected to be negligible and return to the normal upper limit).

The patient's condition did not change even after infliximab was discontinued, so cyclosporine treatment commenced. Cyclosporine is an immune suppressant and has been used to treat post-organ transplantation complications and autoimmune diseases. The main role of this agent is to suppress T cells. Recently, reports indicate that cyclosporine has the capacity to affect antigen-presenting cells such as B cells and dendritic cells. Tajima et al¹⁰ reported that cyclosporine reduces IFN- α production from the CD11c⁻ subset of dendritic cells infected with the Sendai virus. This study suggested that cyclosporine plays a role in suppressing both the courses of T cells and plasmacytoid dendritic cells that produce IFN- α .

There are several reports of new-onset psoriasis paradoxically following TNF- α antagonist therapy. To our knowledge, this case is a rare example of erythroderma associated with alopecia that developed during infliximab therapy and showed a positive LTT result. In cases such as these, exact diagnosis and early treatment intervention are necessary.

REFERENCES

1. Wendling D, Balblanc JC, Briançon D, et al. Onset or exacerbation of cutaneous psoriasis during TNF- α antagonist therapy. *Joint Bone Spine*. 2008;75:315-318.
2. Harrison MJ, Dixon WG, Watson KD, et al. Rates of new-onset psoriasis in patients with rheumatoid arthritis receiving anti-tumour necrosis factor alpha therapy: results from the British Society for Rheumatology Biologics Register. *Ann Rheum Dis*. 2009;68(2):209-215.
3. de Gannes GC, Ghoreishi M, Pope J, et al. Psoriasis and pustular dermatitis triggered by TNF-[alpha] inhibitors in patients with rheumatologic conditions. *Arch Dermatol*. 2007;143(2):223-231.
4. Collamer AN, Guerrero KT, Henning JS, Battafarano DF. Psoriatic skin lesions induced by tumor necrosis factor antagonist therapy: a literature review and potential mechanisms of action. *Arthritis Rheum*. 2008;59(7):996-1001.
5. Nestle FO, Conrad C, Tun-Kyi A, et al. Plasmacytoid predendritic cells initiate psoriasis through interferon-alpha production. *J Exp Med*. 2005;202(1):135-143.

6. Eriksen KW, Lovato P, Skov L, et al. Increased sensitivity to interferon-alpha in psoriatic T cells. *J Invest Dermatol.* 2005; 125(5):936-944.
7. Palucka AK, Blanck JP, Bennett L, Pascual V, Banchereau J. Cross-regulation of TNF and IFN-alpha in autoimmune diseases. *Proc Natl Acad Sci U S A.* 2005; 102(9):3372-3377.
8. Seneschal J, Milpied B, Vergier B, Lepreux S, Schaeverbeke T, Taïeb A. Cytokine imbalance with increased production of interferon-alpha in psoriasiform eruptions associated with antitumour necrosis factor-alpha treatments. *Br J Dermatol.* 2009;161(5):1081-1088.
9. Kano Y, Hirahara K, Mitsuyama Y, Takahashi R, Shiohara T. Utility of the lymphocyte transformation test in the diagnosis of drug sensitivity: dependence on its timing and the type of drug eruption. *Allergy.* 2007;62(12):1439-1444.
10. Tajima K, Amakawa R, Ito T, Miyaji M, Takebayashi M, Fukuhara S. Immunomodulatory effects of cyclosporin A on human peripheral blood dendritic cell subsets. *Immunology.* 2003;108(3):321-328.