

Anabasis articulata exerts an anti-arthritic effect on adjuvant-induced arthritis in rats

Zaid Hamzah Abdulhusain,
Makarim A. Mahdi¹,
Waleed K. Abdulsahib²,
Layth S. Jasim¹

Department of Pharmaceutical
Chemistry, College of Pharmacy,
University of Al-Qadisiyah,

¹Department of Chemistry, College of
Education, University of Al-Qadisiyah,
Al Diwaniyah, ²Department of
Pharmacology and Toxicology, College
of Pharmacy, Al Farahidi University,
Baghdad, Iraq

J. Adv. Pharm. Technol. Res.

ABSTRACT

Anabasis articulata (AA) is commonly found in the Iraqi desert and is utilized in traditional medicine to cure kidney infections, eczema, fever, and diabetes. The paper aimed to identify the anti-arthritic impact of AA on arthritis models in rats. Complete Freund's Adjuvant (CFA) was used intradermally (ID) for the induction of arthritis. The author classified animals into four groups randomly: The first group took normal saline (control), the second group received AA orally for 14 days before induction and continue 17 days after induction, the third group was induced by CFA and received normal saline orally (model group), and the fourth group took AA orally 17 days after induction. AA administration increased body weight (BW) but decreased arthritis index (AI), histopathological scores, and vascular endothelial growth factor expression in synovial cells. AA has an important antiangiogenesis and anti-arthritic activity in arthritis model rats.

Key words: *Anabasis articulate*, adjuvant-induced arthritis, vascular endothelial growth factor, Arthritis

INTRODUCTION

Rheumatoid arthritis (RA) is a late-stage multisystem disease that primarily affects the synovium, resulting in synovium loss, articular cartilage loss, and near-joint erosion.^[1] The disease has a natural history of progressive joint damage and deformities, with extra-articular signs appearing in a small number of people. Continuous treatment strategies have successfully provided significant clinical benefits to the majority of patients, particularly when the disease is diagnosed and treated early.^[2] In developed countries, the prevalence of RA is generally stated more in the male

population than in females.^[3] Four groups exist for the treatment of the disease, comprising anti-inflammatory nonsteroidal drugs, antirheumatic disease-modifying drugs, steroidal anti-inflammatory drugs, and biological agents that are frequently indicated for the management of RA.^[4] CFA is the best model for producing arthritis in animals because it closely resembles human arthritis in many ways.^[5]

Anabasis articulata (AA) is commonly found in the Iraqi desert. It is widely used in folk medicine for the management of elevated glucose levels, lowering high temperatures, inflammatory skin conditions, and some kidney infections.^[6,7] In a previous study, the LD50 value of AA methanol extract was found to be 26.18 g/kg, indicating that the herb is safe to use for medical purposes.^[8] AA has flavones, alkaloids, tannins, saponins, and resins. The three major constituents detected through gas chromatography-mass spectrometry (GC-MS)

Address for correspondence:

Dr. Waleed K. Abdulsahib,
Department of Pharmacology and Toxicology, College of
Pharmacy, Al Farahidi University, Baghdad 10070, Iraq.
E-mail: waleedkalel22@yahoo.com

Submitted: 11-Jun-2022

Revised: 13-Jul-2022

Accepted: 18-Jul-2022

Published: 10-Oct-2022

Access this article online

Quick Response Code:



Website:

www.japtr.org

DOI:

10.4103/japtr.japtr_440_22

This is an open access journal, and articles are distributed under the terms of the Creative Commons Attribution-NonCommercial-ShareAlike 4.0 License, which allows others to remix, tweak, and build upon the work non-commercially, as long as appropriate credit is given and the new creations are licensed under the identical terms.

For reprints contact: WKHLRPMedknow_reprints@wolterskluwer.com

How to cite this article: Abdulhusain ZH, Mahdi MA, Abdulsahib WK, Jasim LS. *Anabasis articulata* exerts an anti-arthritic effect on adjuvant-induced arthritis in rats. J Adv Pharm Technol Res 2022;13:276-80.

analysis of methanol extract were glycine, scopoletin, and 2-methoxy 4-vinylphenol, with a minor one was 1,2-dimethylpiperidine.^[9] Several biological activities were attributed to saponins, flavones, and alkaloids, such as their antidiabetic, anti-arthritic, and antitumoral properties.^[6] The study's purpose is the assessment of the anti-arthritic and anti-inflammatory impacts of AA on rats.

MATERIALS AND METHODS

Plant extract preparation

Stems of AA were obtained from a local herbal apothecary in Baghdad. The authentication of the herb was performed under the supervision of Dr. Ibrahim Salih Abbas, Professor (Ph.D.) in medicinal plants, Pharmacognosy Department, Al-Mustansiriyah University, Iraq. A specimen (99,334) of the plant was put down at the Herbarium of the Faculty of Pharmacy, Al Farahidi University. The maceration process (cold method) was used for the extraction, after which the substance was concentrated by the rotary evaporator with a vacuum (Buchi, Switzerland) to get the final crude extract.

Chemical and reagents

Complete Freund's Adjuvant, ethyl ether, formalin, hematoxylin (H), and eosin (E) stain were purchased from Sigma-Aldrich (Germany). Santa Cruz Biotechnology, Inc. Europe provided the primary antibody of vascular endothelial growth factor (VEGF) (C-1): sc-7269 and the detection kit of secondary immune peroxidase (ImmunoCruz™ mouse labeled streptavidin-biotin Staining System: sc-2050).

Experimental animals

Two-month-old male rats were obtained from Al-Nahrain University (Baghdad, Iraq). The animals were placed at $22 \pm 3^\circ\text{C}$ in a light/dark cycle for 12 h with softwood shavings as bedding. They were provided easy access to water and were fed a standard commercial pellet diet. All animal experiments were designed in conformity with the Animal Ethics Committee of Al-Nahrain University-College of Medicine under the number (NUCM-6622).^[10] A 100 mg/kg dose of the tested herb was administered once daily through intragastric gavage. The experimental design consisted of four groups (each with eight animals). Group 1: rats were injected with normal saline ID and given DW orally (control). Group 2: rats were given AA orally for 14 days before induction and continued until day 17 after immunization. Group 3: rats were injected with CFA ID and received DW orally (model group). Group 4: rats were given AA on the same day of induction and continued until day 17 after immunization. Arthritis was induced by ID injection of 50 μl CFA at the tail's base.^[10] For additional analyses, on day 17 of postimmunization, all animals were killed under anesthesia with ethyl ether.

Clinical arthritis assessment

Rats were evaluated every 2 days starting on the 7th day following immunization for clinical indicators, such as AI and BW.

Arthritis index

AI was calculated by examining and noting the severity of pathological changes in all body joints. The five graded scales of arthritis index were used, with (0): no swelling, (1) little toe joint swelling, (2) swelling on the metatarsophalangeal joint and foot, (3) hind paw below ankle swelling, and (4) the hind paw including ankle swelling. Each rat was assigned a point value, with a maximum possible score of 12 points.^[11]

Measurement of the body weight of the rats

BW of all groups was measured every 2 days for 14 days starting on day 7 after immunization (onset of arthritis).

Histopathological examination

All animals were euthanized after 17 days of immunization. The hind paws above the joint of the knee were amputated and embedded in a 10% neutral buffered formalin solution. Before embedding in paraffin and sectioning in the midsagittal plane, paws were decalcified. Hematoxylin and eosin were used to stain the tarsal joint articulation slices, which were then inspected under a microscope.

The assessment of the arthritis histological changes

The following scoring system was used by the observer to evaluate the cartilage and bone destruction: In terms of mononuclear cell infiltration (MCI), a score of 3, 2, 1, and 0 was given for severe, moderate, mild, and no infiltration, respectively. To assess the destruction of the bone and cartilage caused by pannus formation (PF): a score of 3, 2, 1, and 0 was given for severe change (invasion of the pannus into the subchondral bone), moderate change (pannus invasion into cartilage/subchondral bone), minor change (pannus invasion within cartilage), and no change, respectively. Furthermore, the observer used the following scores to assess vascularity (V): 3 indicated many blood vessels; 2 indicated some blood vessels; 1 indicated a small number of blood vessels; and 0 indicated almost no blood vessels.^[12]

Immunohistochemistry of vascular endothelial growth factor in joint synovium

By immunohistochemistry, VEGF (C-1): diluted 1:100 sc-7269 was utilized to detect the 121, 165, and 189 amino acid splice variants of rat VEGF (including paraffin-embedded sections). ImmunoCruz Staining System used a horseradish peroxidase-streptavidin complex to tissue slices that were formalin fixed and paraffin embedded.^[13]

Immunohistochemical stain evaluation

Brown cytoplasmic staining of lining synoviocytes indicated positive immunohistochemical staining for VEGF. These scoring methods were used to quantify VEGF expressions in tissue specimens of all groups. Score 1 indicated <10%

positive lining synoviocytes, score 2 indicated 10%–25% positive cells, score 3 indicated 25%–50% positive cells, and score 4 indicated more than 50% positive cells.^[14]

Statistical analysis

One-way analysis of variance was used to compare the groups. Then, a Tukey test comparison was made. For statistical analysis, the authors used Statistical Package for the Social Sciences (SPSS) 23.0 software, and set the significance level at ($P < 0.05$). The outcomes were presented in the form of mean \pm standard deviation of the mean.

RESULTS

Arthritis index

When compared to the induced group, daily administration of AA decreased the arthritis score significantly for both

treated ($P = 0.0034$) and prophylaxis ($P = 0.0023$) groups. These findings suggest that AA prevented the onset and reduced arthritis's severity in adjuvant-induced arthritis (AIA) rats, as shown in Figure 1a.

Bodyweight measurement

When compared to the induced group, daily administration of AA to the prophylaxis group increased ($P = 0.0042$) BW significantly. Furthermore, the rat weight of the AA-treated group had a more significant ($P = 0.0013$) increase. The findings denoted that administrating AA orally inhibited inflammatory-induced body weight loss in AIA rats, as shown in Figure 1b.

Histological effects

Histological examination of the foot joints performed on day 17 illustrated that rats in both groups 2 and 4 showed lower

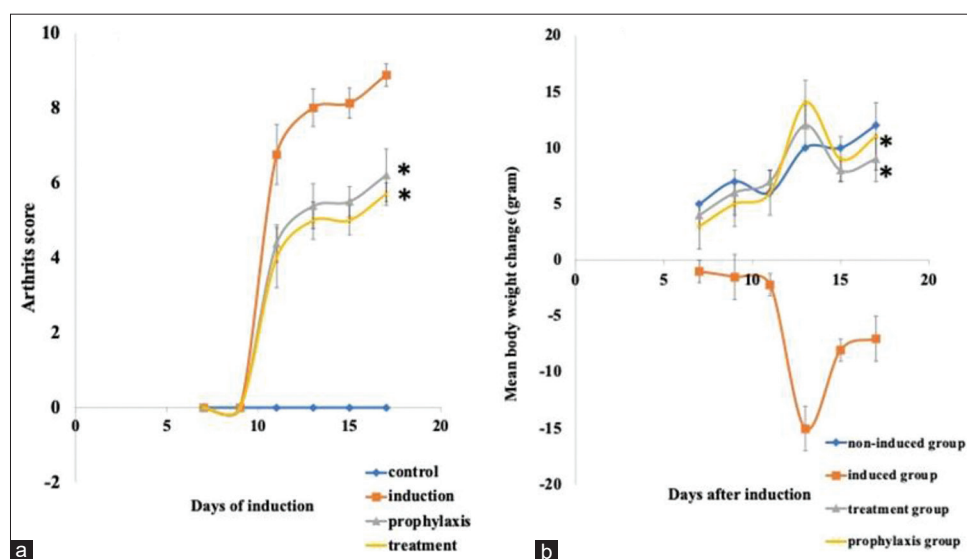


Figure 1: Inhibition of clinical arthritis by AA administration to AIA rats, (a) represents AI, and (b) represents BW ($n = 8$). Data are shown as (mean \pm SD), ($n = 8$). $**P < 0.01$ compared to prophylactic and treated compared to the model group. AA: *Anabasis articulata*, AIA: Adjuvant-induced arthritis, AI: Arthritis index, BW: Body weight, SD: Standard deviation

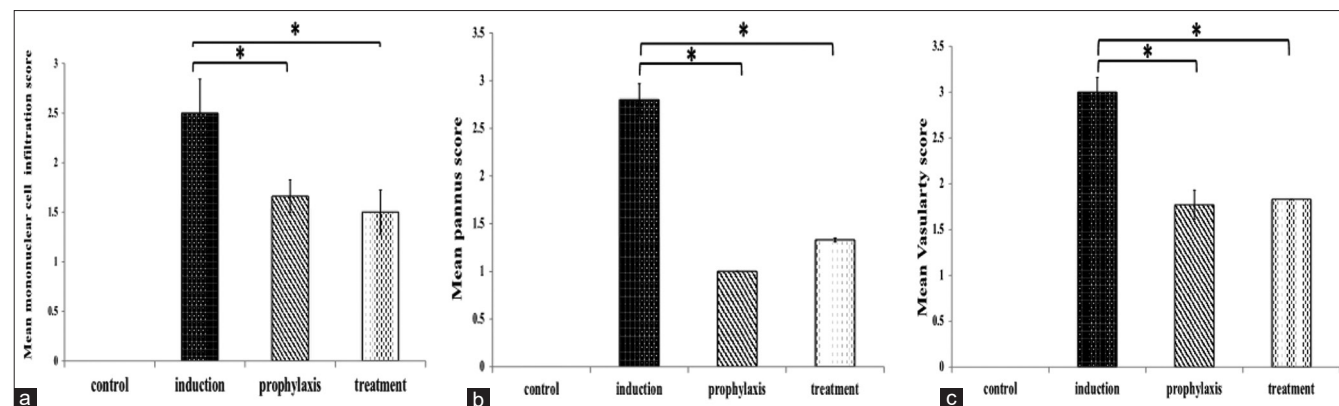


Figure 2: Effect of AA on histopathological scores of the hind limb illustrate: (a): MCI scores, and (c): V scores. Data are shown as (mean \pm SD), ($n = 8$). $*P < 0.01$ compared to the prophylactic and treated compared to the model group. AA: *Anabasis articulata*, MCI: Mononuclear cell infiltration, PF: Pannus formation, SD: Standard deviation

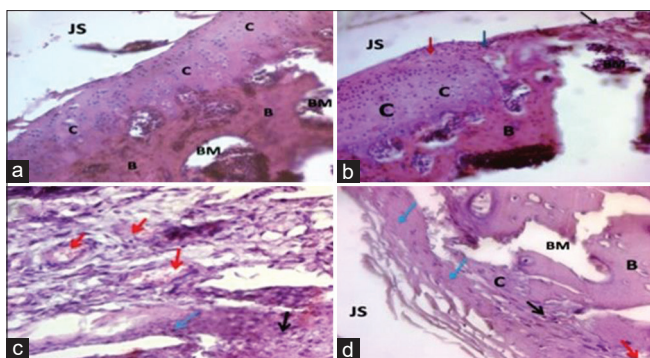


Figure 3: Effect of AA on histological changes on joint tissue of AIA rats, (a): Group 1 shows zero histological scores, (b): Group 2 shows mild MCI and cartilage and bone destruction by PF and few V, (c): Group 3 shows severe MCI and destruction of cartilage and bone by PF and high V, (d): Group 4 shows mild MCI and change of cartilage and bone by PF and a few V. H and E stain ($\times 40$), J: joint space, C: cartilage, BM: bone marrow and B: bone. MCI is represented by (black arrow), PF pannus (blue arrow), and V (red arrow): AA: *Anabasis articulata*, AIA: Adjuvant-induced arthritis, MCI: Mononuclear cell infiltration, PF: Pannus formation

scores for MCI, V, and PF in synovial tissues than those in Group 3 ($P < 0.01$; [Figure 2]). Furthermore, comparing the above groups with the control group showed no significant differences ($P > 0.05$). These findings indicated anti-inflammatory and antiangiogenic effects of AA, as shown in Figure 3.

Expression of vascular endothelial growth factor in synovial tissues

The expression of VEGF dramatically increased in the synoviocytes of induced rats (immunohistochemical score 3.8 ± 0.11). This increase was significant compared to the control group (1.22 ± 0.14) ($P = 0.00076$). Furthermore, a significant decrease was observed in VEGF expression in synoviocytes in both the prophylaxis (1.66 ± 0.16) and treated groups, as shown in Figures 4 and 5.

DISCUSSION

The induction of arthritis by CFA is a commonly used model because it shares many immunological and clinical similarities with human arthritis.^[15] CFA causes obvious swelling of the rat's ankle, hind paw, and toe, with the greatest inflammation occurring between days 11 and 17, as well as an obvious reduction in body weight in comparison to the control group. BW variation in CFA-induced rats is an important feature for assessing the medicinal agent's response and the disease's interval in terms of inflammation.^[16] Arthritis induction was also found to cause an increase in arthritis index score and paw swelling. In CFA-induced rats, paw swelling denotes the strength of inflammation, whereas paw swelling depression after treatment denotes the drug's anti-arthritic activity.^[14,15] Prophylaxis administration of AA results in an obvious

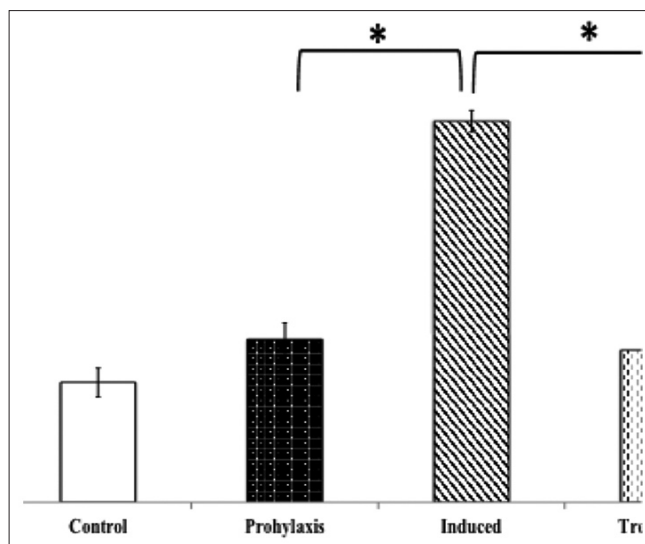


Figure 4: Effect of AA on the expression of VEGF score ($n = 8$). $*P < 0.05$ in the case of comparison of the prophylactic and treated group to the induction (model) group. AA: *Anabasis articulata*, VEGF: Vascular endothelial growth factor

increase in BW and a well-meaning decrease in clinical parameters, such as a decline in the swelling of the ankle, toe, and hind paw. Administering AA to the treatment group increased BW and significantly decreased the swelling of the toe, hind paw, and ankle. In a previous study, GC-MS analysis of AA revealed the presence of glycine, coumarin, alkaloid, and phenol.^[8,9] Pan *et al.* demonstrated that scopoletin, one constituent of AA, improved clinical symptoms of arthritis in rats.^[17] Wang *et al.* demonstrated that plants with a high phenol content inhibited arthritis caused by CFA.^[18] Li *et al.* demonstrated that glycine could prevent peptidoglycan polysaccharide-induced reactive arthritis in rats. All of the above findings support our findings on the anti-arthritic effect of AA.^[19] It has recently been established that VEGF has a major role in RA. The amount of VEGF expressed in tissues and synovial fluid correlates with the grade of joint damage severity. VEGF expression begins early and continues throughout the disease course.^[13,14] Nonspecific angiogenesis inhibitors produced significant clinical benefits in a variety of models of arthritis, including ovalbumin-induced arthritis and collagen-induced arthritis (CIA).^[20] Miotla and colleagues demonstrated a rapid reduction in clinical symptoms in CIA after inhibiting VEGF activity.^[21] The suppression of angiogenesis and inflammation within the joint, facilitated by VEGF, is elegant healing in arthritis because VEGF is found in the synovial fluid and synovium of people with RA.^[17] AA effectively inhibits VEGF expression in synoviocyte cells in both the prophylaxis and treated groups when compared to the model group and near normal when compared to the control group. These outcomes agree with previous studies that demonstrated the antiangiogenic effect of AA accomplished in rat aorta ring and chick chorioallantoic membrane assays.^[8,9] Although we must

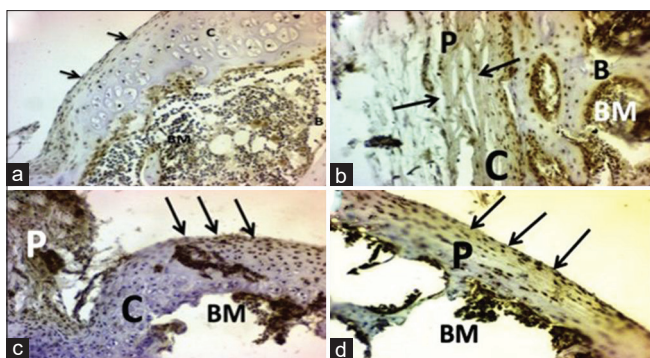


Figure 5: Effect of AA on IE of VEGF, (a): Section of joint tissue of Group 1 showing positive IE of VEGF in less than 10% of lining synoviocytes, (b) Is a section from joint tissue of Group 2 showing positive IE of VEGF between 10% and 25% of lining synoviocytes. (c) Represents a section of joint tissue of Group 3 that shows positive IE of VEGF over 50% of lining synoviocytes: scores 4, and (d) Represents a section of joint tissue of Group 4 showing positive IE of VEGF between 10% and 25% of lining synoviocytes: score 2. AA: *Anabasis articulata*, IE: Immunohistochemistry expression, VEGF: Vascular endothelial growth factor

determine which explanation is precise if we are to form better arthritis treatments. The complete inhibition of the disease is very promising for detecting suitable healing agents for this incapacitating disease.

CONCLUSIONS

The methanolic extract of AA demonstrated clear protective and anti-arthritic effects in rats by CFA and held promise for future RA treatment.

Acknowledgment

We would like to thank the Pharmacology Department in Medicine College – the Al-Nahrain University for assistance in accomplishing this study.

Financial support and sponsorship

Nil.

Conflicts of interest

There are no conflicts of interest.

REFERENCES

- van Delft MA, Huizinga TW. An overview of autoantibodies in rheumatoid arthritis. *J Autoimmun* 2020;110:102392.
- DeMizio DJ, Geraldino-Pardilla LB. Autoimmunity and inflammation link to cardiovascular disease risk in rheumatoid arthritis. *Rheumatol Ther* 2020;7:19-33.
- Xu Y, Wu Q. Prevalence trend and disparities in rheumatoid arthritis among US adults, 2005-2018. *J Clin Med* 2021;10:3289.
- Lalor AF, Brooker JE, Rozbroj T, Whittle SL, Hill CL, Rowett D,

et al. Factors influencing clinician prescribing of disease-modifying anti-rheumatic drugs for inflammatory arthritis: A systematic review and thematic synthesis of qualitative studies. *Semin Arthritis Rheum* 2022;55:151988.

- Schinnerling K, Rosas C, Soto L, Thomas R, Aguillón JC. Humanized mouse models of rheumatoid arthritis for studies on immunopathogenesis and preclinical testing of cell-based therapies. *Front Immunol* 2019;10:203.
- Al-Joufi FA, Jan M, Zahoor M, Nazir N, Naz S, Talha M, et al. *Anabasis articulata* (Forssk.) Moq: A good source of phytochemicals with antibacterial, antioxidant, and antidiabetic potential. *Molecules* 2022;27:3526.
- Abdulsahib WK. The effect of *Anabasis articulata* stems extract on lowering intraocular pressure in the glaucoma rat model (Conference Paper). *Iraqi J Pharm Sci* 2021;30:1-8.
- Abudalsahib W, Abd A, Jumaa B. Antiangiogenic activity of Iraqi *Anabasis articulata* stems *in vivo* study. *Int J Sci Res* 2016;5:220-6.
- Abdulsahib K, Abdulkareem A, Ban Jumaa Q, Hayder S. Antiangiogenesis and antioxidant effect of *Anabasis articulata* stems extracts. *Int J Pharm Sci Rev Res* 2016;41:88-94.
- Goyal A, Agrawal N. Quercetin: A potential candidate for the treatment of arthritis. *Curr Mol Med* 2022;22:325-35.
- Chyuan IT, Tsai HF, Liao HJ, Wu CS, Hsu PN. An apoptosis-independent role of TRAIL in suppressing joint inflammation and inhibiting T-cell activation in inflammatory arthritis. *Cell Mol Immunol* 2018;15:846-57.
- Rutgers M, van Pelt MJ, Dhert WJ, Creemers LB, Saris DB. Evaluation of histological scoring systems for tissue-engineered, repaired and osteoarthritic cartilage. *Osteoarthritis Cartilage* 2010;18:12-23.
- Ao L, Gao H, Jia L, Liu S, Guo J, Liu B, et al. Matrine inhibits synovial angiogenesis in collagen-induced arthritis rats by regulating HIF-VEGF-Ang and inhibiting the PI3K/Akt signaling pathway. *Mol Immunol* 2022;141:13-20.
- Taylor PC. VEGF and imaging of vessels in rheumatoid arthritis. *Arthritis Res* 2002;4 Suppl 3:S99-107.
- Billiau A, Matthys P. Modes of action of Freund's adjuvants in experimental models of autoimmune diseases. *J Leukoc Biol* 2001;70:849-60.
- Naik SR, Wala SM. Arthritis, a complex connective and synovial joint destructive autoimmune disease: Animal models of arthritis with varied etiopathology and their significance. *J Postgrad Med* 2014;60:309-17.
- Pan R, Gao XH, Li Y, Xia YF, Dai Y. Anti-arthritic effect of scopoletin, a coumarin compound occurring in *Erycibe obtusifolia* Benth stems, is associated with decreased angiogenesis in synovium. *Fundam Clin Pharmacol* 2010;24:477-90.
- Wang WQ, Wang FH, Qin WX, Liu HY, Lu B, Chung C, et al. Joint antiangiogenic effect of ATN-161 and anti-VEGF antibody in a rat model of early wet age-related macular degeneration. *Mol Pharm* 2016;13:2881-90.
- Li X, Bradford BU, Wheeler MD, Stimpson SA, Pink HM, Brodie TA, et al. Dietary glycine prevents peptidoglycan polysaccharide-induced reactive arthritis in the rat: Role for glycine-gated chloride channel. *Infect Immun* 2001;69:5883-91.
- Bäckström NF, Dahlgren UI. Bystander suppression of collagen-induced arthritis in mice fed ovalbumin. *Arthritis Res Ther* 2004;6:R151-60.
- Miotla J, Maciewicz R, Kendrew J, Feldmann M, Paleolog E. Treatment with soluble VEGF receptor reduces disease severity in murine collagen-induced arthritis. *Lab Invest* 2000;80:1195-205.