

Left-to-right crossed fused renal ectopia with pyelonephritis mimicking appendix mass

Friday Emeakpor Ogbetere^{1,2}¹Urology Division, Department of Surgery, Edo University, Iyamho, ²Department of Surgery, Central Hospital, Auchi, Edo State, Nigeria

Abstract

Crossed fused renal ectopia (CFRE) is an uncommon developmental anomaly of the genitourinary system whereby the two kidneys are located on the same side of the body and joined together, while the ureter of the ectopic kidney still enters the bladder in its normal side. CFRE has variable clinical presentations and usually discovered incidentally when patients are investigated for abdominal complaints. Treatment may be conservative when renal function is preserved with no associated symptomatic urological complications. Highlighted here is the unusual presentation of left-to-right CFRE with acute pyelonephritis as an appendix mass in a 19-year-old female.

Keywords: Acute pyelonephritis, appendix mass, left-to-right crossed fused, renal ectopia

Address for correspondence: Dr. Friday Emeakpor Ogbetere, Urology Division, Department of Surgery, Edo University, Km 7, Auchi-Abuja Expressway, PMB 04, Iyamho, Auchi, Edo State, Nigeria.

E-mail: fridayemeakpor@gmail.com

Received: 26.04.2020, **Revised:** 05.07.2020, **Accepted:** 25.08.2020, **Published:** 19.01.2021.

INTRODUCTION

Crossed renal ectopia is a rare urinary system anomaly with two conventional types: crossed unfused renal ectopia and crossed fused renal ectopia (CFRE). The latter accounts for 90% of crossed renal ectopia.^[1] Gupta *et al.*^[2] reported the autopsy incidence of CFRE to be 1:1,900. Abeshouse and Bhisitkul^[3] noted a live incidence of 1:1000.

Most CFRE cases are asymptomatic and diagnosed by chance while investigating for unrelated abdominal complaints.^[1,4,5] Symptomatic cases have varied modes of presentation.^[1,5] Presented here is a case report of CFRE with acute pyelonephritis mimicking an appendix mass which was treated conservatively with success.

CASE REPORT

A 19-year-old single female presented to our clinic with a 5-day history of vague abdominal pain that later became localized to the right iliac fossa, with fever of moderate grade and nausea with two episodes of vomiting without urinary symptoms. She had no previous history of urinary tract infection. Her last menstrual period was 14 days before the onset of symptoms. Physical examination revealed mild tenderness in the right iliac fossa. A vague mass was noticed in the right iliac fossa with ill-defined features. The rest of the examination was unremarkable. She was assessed as a case of an appendix mass.

An abdominal ultrasonography demonstrated both kidneys on the right of the midline with no kidney tissue on the left side. Multidetector computed tomography (MDCT)

This is an open access journal, and articles are distributed under the terms of the Creative Commons Attribution-NonCommercial-ShareAlike 4.0 License, which allows others to remix, tweak, and build upon the work non-commercially, as long as appropriate credit is given and the new creations are licensed under the identical terms.

For reprints contact: reprints@medknow.com

How to cite this article: Ogbetere FE. Left-to-right crossed fused renal ectopia with pyelonephritis mimicking appendix mass. *Urol Ann* 2021;13:73-5.

Access this article online	
Quick Response Code:	Website: www.urologyannals.com
	DOI: 10.4103/UA.UA_67_20

urography showed that the left kidney ectopically located on the right side of the body, lying inferomedial, and fused to the right kidney [Figure 1]. There was a heterogeneous enhancement of the ectopic kidney with mild edema. The right ureter drained into the bladder on the ipsilateral side. The left ureter crosses to the left aspect of the midline before entering the urinary bladder. The calyces, the renal pelvis, and the ureters are normal in caliber [Figure 2]. Both kidneys excreted contrast promptly without detectable differential excretion. In addition, the appendix was in the retrocecal position with no features, suggestive of inflammation. A urine culture yielded growth of *Escherichia coli* which was sensitive to ceftriaxone. The renal function and other laboratory investigations revealed no abnormalities. Further, the pregnancy test done was negative. A diagnosis of left-to-right CFRE with acute pyelonephritis was made, and ceftriaxone was given for 5 days according to the antimicrobial sensitivity pattern. She was discharged 7 days after and has not had symptoms at follow-up.

DISCUSSION

The development of the kidney begins in the 4th week of intrauterine life by inductive interaction between the ureteric bud and the metanephric blastema.^[5] Developmental anomalies can occur due to errors in the development, migration, and rotation of the kidneys. Although the exact cause of CFRE is not known, it is believed that the abnormal development of the ureteric bud and metanephric blastema during the 4th–8th week of gestation may be responsible.^[1] In addition, the time and amount of fusion as well as the extent of rotation determine the final shape and location of the kidneys.^[6] CFRE is the second most commonly observed renal fusion anomaly after horseshoe kidney.^[2]

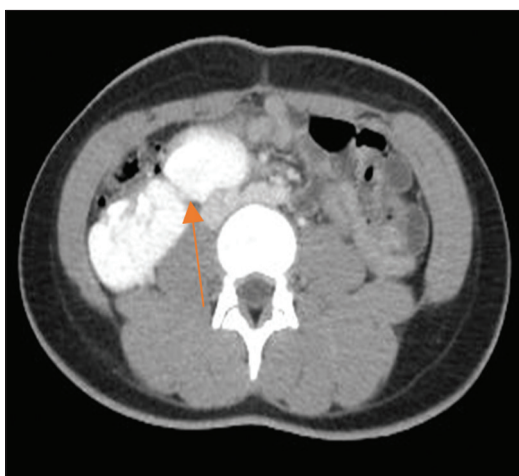

Figure 1: An axial image of the patient showing right fusion of the two kidneys

McDonald and McClellan^[7] classified CFRE into six standard types, with the most prevalent being unilateral fused kidney with inferior ectopia. The others are S-shaped kidney, unilateral lump kidney, L-shaped kidney, disc kidney, and fused kidney with superior ectopia. Left-to-right crossover is more common with the upper pole of the ectopic kidney fused to the lower pole of the orthotopically located kidney in most instances.^[1] This index patient had left-to-right fused kidney with inferior ectopia and a laterally oriented hilum.

A large proportion of patients with this developmental anomaly are asymptomatic and often undetected. That said, presentation to health units by patients with CFRE is usually as a result of complications. These complications range from recurrent urinary tract infections and nephrolithiasis to hydronephrosis, vesicoureteric reflux, and renal insufficiency.^[1] In this index case, a left-to-right CFRE was detected with the complication of acute pyelonephritis.

Acute or chronic abdominal pain appears to be the most common mode of presentation in CFRE patients with complications. The two cases of CFRE reported by Abeshouse and Bhisitkul^[3] presented with chronic abdominal pain. In some other cases, detection was during investigations for abdominal pain, abdominal mass, and urinary tract infection.^[1] This index patient presented with vague abdominal pain which later localized to the right iliac fossa.

In the second decade of life, vague abdominal pain localizing at the right iliac fossa with associated mass is often considered as an appendix mass^[8]. When considering the appendix mass, it would be wise to keep pathology

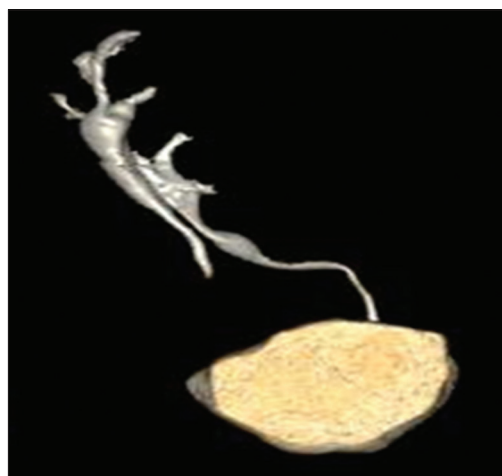


Figure 2: A volume-rendered multidetector computed tomography urography of the patient with crossed fused renal ectopia showing pelvicalyceal system and the ureters. The left ureter crossed the midline and open into the urinary bladder on the left side

such as CFRE with acute pyelonephritis in mind and investigate in this vein as CFRE can mimic the appendix mass as noted in this case report. Failure to consider CFRE with acute pyelonephritis in suspected appendix pathology such as appendix mass and acute appendicitis may result in negative appendectomy and persistence of symptoms even after surgery.^[9]

The imaging modalities used for investigating renal fusion anomalies include ultrasonography, intravenous urography, renal scintigraphy, MDCT urography, and magnetic resonance imaging.^[1,4] These investigations should be carried out based on the patient's specific needs. This patient had the CFRE detected incidentally with abdominopelvic ultrasonography while investigating for the cause of her abdominal pain. This modality of investigation is readily available and affordable and should be handy in evaluating patients with abdominal pain. In addition, ultrasonography can detect complications such as nephrolithiasis and hydronephrosis.^[3,5] MDCT urography is the modality of choice in the investigation of renal fusion anomalies.^[4,10] For detail characterization and to rule out other associated complications, this index patient had an MDCT urography done [Figures 1 and 2].

There is no laid down protocol for the management of CFRE. The treatment is symptom based and targeted at the underlying complications. Our patient was placed on antibiotics according to the sensitivity pattern and she recovered within 7 days. She is being followed up in the urologic clinic.

CONCLUSION

CFRE is a rare developmental genitourinary anomaly. This case report showed the uncommon finding of left-to-right CFRE with acute pyelonephritis who presented with symptoms mimicking appendix mass. The differential diagnosis of intra-abdominal mass, especially in the lower abdomen, should include CFRE. In patients who present with chronic vague abdominal pain or those with acute

or recurrent abdominal pain, for which the diagnosis of appendix mass is being entertained, renal anomalies, though rare, should be considered as a differential.

Declaration of patient consent

The authors certify that he has obtained all appropriate patient consent forms. In the form the patient has given her consent for her images and other clinical information to be reported in the journal. The patients understand that her name and initials will not be published and due efforts will be made to conceal their identity, but anonymity cannot be guaranteed.

Financial support and sponsorship

Nil.

Conflicts of interest

There are no conflicts of interest.

REFERENCES

1. Solanki S, Bhatnagar V, Gupta AK, Kumar R. Crossed fused renal ectopia: Challenges in diagnosis and management. *J Indian Assoc Pediatr Surg* 2013;18:7-10.
2. Gupta T, Goyal SK, Aggarwal A, Chawla K, Kaur H, Sahni D. Congenital renal anomalies in Indian population. *J Postgrad Med Edu Res* 2017;51:12-6.
3. Abeshouse BS, Bhisitkul I. Crossed renal ectopia with and without fusion. *Urol Int* 1959;9:63-91.
4. Jiménez Pacheco A, Arrabal Polo M, Arrabal Martín M, Zuluaga Gómez A. Pyelonephritis in crossed-fused renal ectopia. *Nefrologia* 2009;29:277-8.
5. Babu CSR, Sharma V, Gupta OP. Renal Fusion Anomalies: A Review of Surgical Anatomy. *Anat Physiol* 2015;S5:001.
6. Patel TV, Singh AK. Crossed fused ectopia of the kidneys. *Kidney Int* 2008;73:662.
7. McDonald JH, McClellan DS. Crossed renal ectopia. *Am J Surg* 1957;93:995-1002.
8. Niharika M, Prabhakara RY, Poornima D, Navamani S. None resolving appendicular mass: A rare case report. *J Dent Med Sci* 2016;15:44-9.
9. Tudevдорj S, Javkhlantur B, Bat IB, Ganbat O, Batsaikhan BE. Acute pyelonephritis of crossed right fused renal ectopia. *Surg Med Open Acc J* 2017;1:SMOAJ.000502.
10. Sharma V, Buba CS, Gupta OP. Crossed fused renal ectopia multidetector computed tomography study. *Int J Anat Res* 2016;2:305-9.