



OPEN ACCESS

Effect of wrist dorsiflexion on ultrasound-guided radial artery catheterisation using dynamic needle tip positioning technique in adult patients: a randomised controlled clinical trial

Qingyu Xiao , Dejiang Xu, Shaohui Zhuang

Handling editor Lara Nicole Goldstein

► Additional material is published online only. To view please visit the journal online (<http://dx.doi.org/10.1136/emermed-2020-209504>).

Department of Anaesthesiology, The First Affiliated Hospital of Shantou University Medical College, Shantou, Guangdong, China

Correspondence to

Dr Shaohui Zhuang, Anaesthesiology, The First Affiliated Hospital of Shantou University Medical College, Shantou, Guangdong, China; doctorzsh@163.com

Received 5 February 2020
Revised 15 October 2020
Accepted 21 October 2020
Published Online First
26 January 2021

ABSTRACT

Background It is generally recommended to keep the wrist joint mildly dorsiflexed during radial artery catheterisation. However, wrist dorsiflexion might decrease the success rate of radial artery catheterisation with dynamic needle tip positioning technique. Therefore, we assessed the success rates of two groups with or without wrist dorsiflexion by 5 cm wrist elevation in adult patients.

Methods This randomised controlled clinical trial was performed between March and December 2018 in the First Affiliated Hospital of Shantou University Medical College, China. We recruited 120 adult patients undergoing major surgical procedures and randomly allocated them into two groups: dorsiflexion group (group D) and neutral group (group N). The primary outcome was first-attempt success rates of two groups. Secondary outcomes were overall success rates within 5 min; numbers of insertion and cannulation attempts; overall catheterisation time; duration of localisation, insertion and cannulation; and complication rates of catheterisation.

Results First-attempt success rate was 88.3% in group D and 81.7% in group N ($p=0.444$). The overall success rate within 5 min was 93.3% in group D compared with 90.0% in group N ($p=0.743$). Numbers of insertion and cannulation attempts, overall catheterisation time, duration of localisation and insertion, and complication rates did not show a significant difference between the two groups. Cannulation time was longer in group N (35.68 s) than that in group D (26.19 s; $p<0.05$).

Conclusion Wrist dorsiflexion may not be a necessity for ultrasound-guided radial artery catheterisation using dynamic needle tip positioning technique in adult patients.

Trial registration number ChiCTR1800015262.

INTRODUCTION

Arterial catheterisation is a commonly performed invasive procedure in the emergency department, intensive care unit and operating theatre to facilitate accurate haemodynamic monitoring and frequent blood sampling.¹ Ultrasonography has been increasingly used for radial artery catheterisation. The combined short-axis and out-of-plane technique using dynamic needle tip positioning (DNTP) has been shown to have a higher success rate compared with the combined long-axis and in-plane technique.²

Key messages

What is already known on this subject

- It is generally recommended to keep the wrist joint mildly dorsiflexed during radial artery catheterisation.
- Wrist dorsiflexion may decrease the success rate of radial artery catheterisation with dynamic needle tip positioning technique.

What this study adds

- This randomised controlled clinical trial showed that wrist dorsiflexion by 5 cm wrist elevation did not alter the dimension of the radial artery, including width, height and depth.
- Our results suggested that wrist dorsiflexion did not affect first-attempt success rate, overall success rate, overall catheterisation time or complication rate, but decreased cannulation time of ultrasound-guided radial artery catheterisation using dynamic needle tip positioning technique in adult patients.

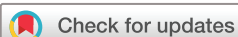The generally recommended positioning for radial artery catheterisation is to keep the wrist joint mildly dorsiflexed.³ However, in prior studies, the artery became more superficial with wrist dorsiflexion⁴ and DNTP was challenging in superficial target vessels because needle tip control was difficult at shallow depths immediately after skin perforation.⁵ Also, radial artery height was decreased with wrist dorsiflexion, which was a potential disadvantage for cannulation.⁶ Moreover, extreme wrist dorsiflexion may attenuate the pulse by stretch or extrinsic tissue pressure and injure the median nerve.³

In this study, we aimed to investigate whether slight wrist dorsiflexion by 5 cm wrist elevation could affect the success rate, overall catheterisation time and complication rate of ultrasound-guided radial artery catheterisation using a DNTP technique in adult patients.

MATERIALS AND METHODS

Ethics approval

This study was approved by the Institutional Review Board of the First Affiliated Hospital of Shantou University Medical College. Consent was obtained from patients or their surrogates for procedures



© Author(s) (or their employer(s)) 2021. Re-use permitted under CC BY-NC. No commercial re-use. See rights and permissions. Published by BMJ.

To cite: Xiao Q, Xu D, Zhuang S. *Emerg Med J* 2021;**38**:524–528.



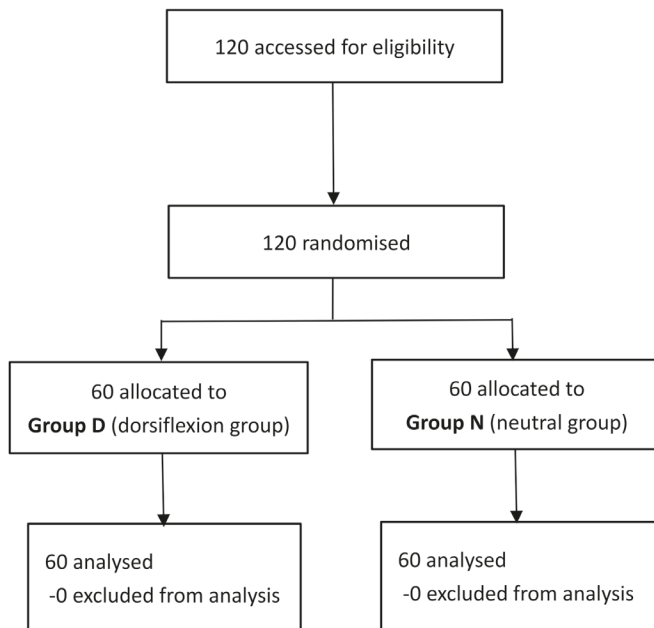


Figure 1 Consolidated standards of reporting trials flow diagram.

where radial artery catheterisation was indicated. The study was registered at the Chinese Clinical Trial Registry (registration number: ChiCTR1800015262).

Population

Patients older than 18 years undergoing major surgical procedures that required invasive continuous blood pressure monitoring or frequent arterial blood sampling as determined by the attending anaesthesiologists between March and December 2018 in the First Affiliated Hospital of Shantou University Medical College, China were eligible for recruitment in this study. Patients with abnormal Allen test, radial or ulnar artery occlusion, peripheral vascular diseases (arterial atherosclerosis, primary or secondary vasculitis, angioma and Raynaud's disease), coagulopathy (International Normalised Ratio ≥ 1.5 or platelet count $\leq 10 \times 10^9/L$), any infection, trauma or scars at the insertion site were excluded. Patients did not incur the cost of the intervention in the research.

Patient and public involvement

Patients were not involved in the conception or design of the study or asked to disseminate the study results.

Sample size estimation

A previous study showed that the first-attempt success rate of ultrasound-guided radial artery catheterisation with mild wrist extension was about 65%.⁷ Assuming a 25% increase in first-attempt success rate, with a two-sided significance level (α) of 0.05 and power (β) of 90%, 54 patients in each group (total 108 cases) were required to obtain a significant result. To compensate for any possible data losses, we enrolled 120 cases, 60 cases in each group (figure 1).

Randomisation

Randomisation was performed through an interactive web response system (Brightech Clinical Information Management System). The randomisation assignments were computer generated with randomly selected block sizes and then placed in sealed opaque envelopes.

DNTP technique⁸

First, a short-axis out-of-plane image of the radial artery is obtained around the proximal wrist crease using a high-frequency linear ultrasound probe. Then the needle and catheter puncture the skin at an angle of 30° – 40° until the hyperechoic needle tip is viewed on the ultrasound screen. After that, the ultrasound probe is advanced proximally along the arm and away from the site of needle insertion until the hyperechoic needle tip disappears from the ultrasound image. The needle is then advanced a few millimetres until the tip is seen again (figure 2). This stepwise process is repeated as necessary, modifying the angle of approach to keep the needle tip in the centre of the arterial lumen. When at least 1 cm of the needle is inside the arterial lumen, the catheter is threaded off the needle and connected to the monitor.

Study design

The designated group for the patient was revealed when a sealed opaque envelope containing a piece of paper with either group D or group N printed on it was opened. The patient's arm was abducted from the body by the operator. In group D, the wrist was slightly dorsiflexed with palm up and a cotton fabric roll with a diameter of 5 cm was placed on the extensor surface at the point of flexion, and the phalanges were taped and fixed to the operation board. In group N, the patient's wrist was not dorsiflexed. The ultrasound machine (FUJIFILM SonoSite, Washington, DC) and high-frequency linear probe (13–6 MHz, FUJIFILM SonoSite) were used for all catheterisations. Before needle puncture, a recorder (not any one of the operators) obtained a cross-sectional image of the targeted radial artery in short-axis view at a depth of 1.5 cm, then measured and recorded

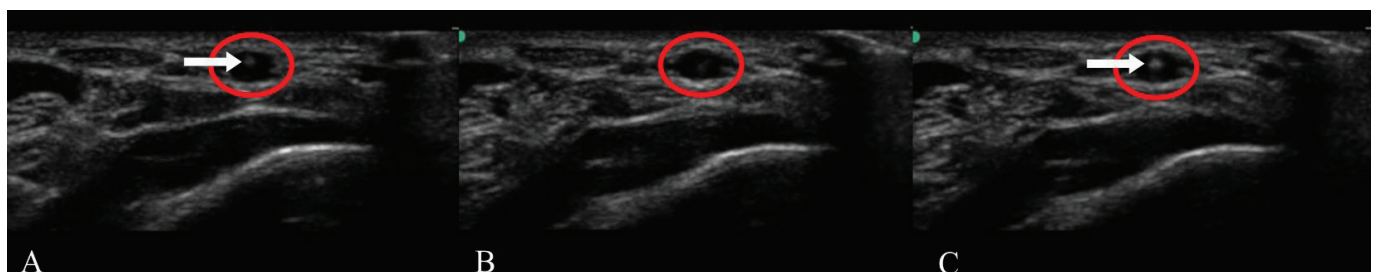

Figure 2 Dynamic needle tip positioning technique. (A) The radial artery was punctured. The hyperechoic needle tip was visualised in the lumen of the radial artery. (B) With ultrasound probe being moved proximally along the arm and away from the needle insertion point, hyperechoic needle tip disappeared from the ultrasound image. (C) With advancement of the needle, the needle tip was seen again in the image. The radial artery was indicated by a red circle. The needle tip was indicated by a white arrow.

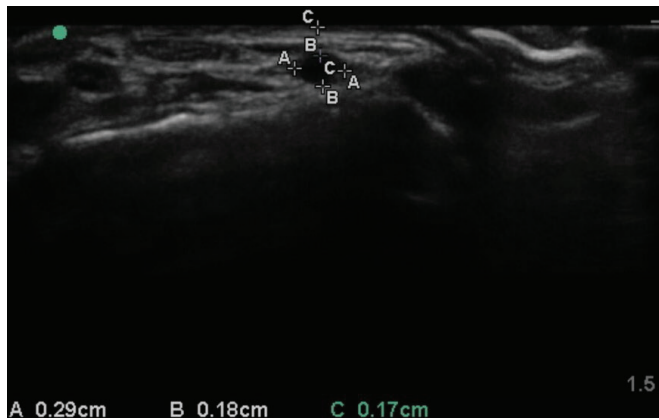


Figure 3 Measurements of the radial artery (A: width, B: height, C: depth).

the heights, widths and depths of the artery using the calibre tool of the ultrasound machine (figure 3).

Four trained operators were assigned to both groups and were blinded to the measurement data. After the patient was positioned, they performed the procedure. A universal sterile technique protocol was followed throughout. The patient's wrist was disinfected with iodine and then properly draped. Using a 20G angio-catheter (Introcan-W B. Braun Melsungen AG, Melsungen, Germany), they applied the DNTP technique. The timer was started when the ultrasound probe contacted the skin. Three timepoints were recorded (figure 4). Timepoint 1: when the needle punctured the skin (localisation time). Timepoint 2: when blood could be viewed inside the transparent flashback chamber of the needle (insertion time). Timepoint 3: when the catheter was completely placed into the artery with arterial waveform appearing on the monitor (cannulation time).

Overall success was successful catheterisation with less than three attempts at insertion and three attempts at cannulation within 5 min. One needle puncture of the skin was counted as one insertion. When the catheter was completely threaded off the needle core, it was counted as one cannulation.

Complications included any thrombosis, ischaemia, haematoma, tissue swelling, vascular spasm, nerve injury, infection and pain within 24 hours after initiation of the procedure.

Outcome assessment

The primary outcome was first-attempt success rates of two groups. Secondary outcomes were overall success rates within 5 min; numbers of insertion and cannulation attempts; overall catheterisation time; duration of localisation, insertion and cannulation; and complication rates of catheterisation. Cannulation time was analysed by subdividing the successfully catheterised cases based on gender, age, insertion blood pressure and body mass index (BMI).

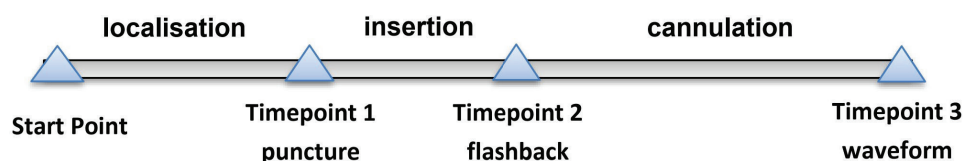


Figure 4 Time segments of ultrasound-guided radial artery catheterisation.

Table 1 Characteristics of patients

	Group D	Group N
Gender (male/female)	34/26	36/24
Age (years)	59.65±12.26	59.52±12.66
ASA-PS (II/III/IV)	45/15/0	47/12/1
BMI (kg/m ²)	22.11±3.49	21.68±3.22
Wrist circumference* (cm)	15.58±1.16	15.46±1.17
History of arterial puncture (%)	10.0	15.0

*Circumference at the radial styloid process perpendicular to the long axis of the forearm.

ASA-PS, American Society of Anaesthesiologists Physical Status; BMI, Body Mass Index.

Statistical analysis

We used SPSS V.23.0 for statistical analysis. First-attempt success rates, overall success rates, numbers of insertion and cannulation attempts, complication rates were compared using the χ^2 test or Fisher exact test. We performed multivariable logistic regression and included groups, ASA-PS, BMI, wrist circumference, medical history of diabetes mellitus, hypertension, dyslipidaemia, history of arterial puncture, insertion hypotension, arterial depth, arterial area as variables to investigate the association between baseline factors and first-attempt success rate. Continuous data were expressed as mean±SD after normality analysis. Analysis of overall catheterisation time; duration of localisation, insertion and cannulation; and subgroup analysis of cannulation time were performed applying a two-sample independent t test or Mann-Whitney U test. A two-tailed value of $p < 0.05$ was considered statistically significant.

RESULTS

One hundred and twenty patients aged 22–83 years old were enrolled in the study. No patient drop-out or violation of the protocol was observed. There was no significant difference in the characteristics between the two groups (table 1).

Table 2 presents the measurements of the radial artery in a short-axis out-of-plane image. Depth of the artery was, on average, somewhat higher in group N.

Primary and secondary outcomes are presented in table 3. First-attempt success rates, overall success rates, numbers of insertion and cannulation attempts did not show significant differences between the two groups. Multivariable logistic regression analysis showed that other baseline factors were not associated with the primary outcome (online supplemental table S1).

Table 4 illustrates the time for the successful placement of the arterial catheter in each group. There was no significant difference in overall catheterisation time between the two groups. No significant difference was noted in time to ultrasound localisation of the radial artery and insertion between the two groups. Cannulation time was 9.49 s longer in group N than in group D ($p = 0.01$).

Table 2 Measurements of the radial artery

	Group D	Group N
Height (mm)	2.34±0.34	2.41±0.46
Width (mm)	3.05±0.59	3.01±0.56
Depth (mm)	1.71±0.65	1.96±0.76
Area (mm ²)*	22.79±6.93	23.45±8.02

*Area=π*Height*Width.

DISCUSSION

This randomised study found no significant difference in the first-attempt success rate between patients who had arterial catheters placed with or without wrist dorsiflexion. A previous study using the same technique with the wrist slightly extended by placing a towel roll showed a first-pass success rate of 83%,⁸ which was similar to the result in this study (88.3%). Without dorsiflexion, the first-attempt success rate was 81.7%, which was not significantly different from the wrist dorsiflexion group. Therefore, it can be implied that with the help of DNTP technique, wrist dorsiflexion did not make a difference to success rates of radial artery catheterisation.

Among the successfully catheterised patients, cannulation time was shorter with wrist dorsiflexion. We subdivided these cases into different groups based on gender, age, insertion blood pressure and BMI. We found that in the elderly patients ageing 65 years and above, cannulation time was similar with or without wrist dorsiflexion. The possible reason was that radial arteries show an age-related acceleration of atherosclerosis and atherosclerotic plaques can markedly reduce the distensibility.⁹ Dimension of the less distensible artery was not easily affected by extrinsic pressure from wrist dorsiflexion. Therefore, cannulation time was not affected by wrist dorsiflexion.

Selvaraj and Buhari performed sonographic measurements of radial artery dimensions with wrist extension at different angles in 48 young, healthy female subjects, and no statistically significant change in the dimension of the radial artery was observed.¹⁰ This finding matched the result of this study, where among female patients, radial dimension and cannulation time did not show the difference with or without wrist dorsiflexion.

Li *et al*'s study has proven that ultrasonic technology improved radial artery puncture and cannulation in patients who had a shock.¹¹ In that study, wrist dorsiflexion was thought to be helpful. However, our study showed that wrist dorsiflexion did not improve the success rate or shorten cannulation time when there was insertion hypotension. Hypotension is usually associated with peripheral artery constriction or collapse. In this case, different wrist angles with or without dorsiflexion have little effect on the cross-sectional area or depth of the radial artery. Therefore, for patients with insertion hypotension, there seemed no necessity to dorsiflex the wrist using DNTP technique.

Table 3 Primary and secondary outcomes of ultrasound-guided radial artery catheterisation

	Group D	Group N	P value	Relative risk (95% CI)
First-attempt success rate (%)	88.3	81.7	0.444	1.082 (0.930–1.258)
Overall success rate (%)	93.3	90.0	0.743	1.037 (0.931–1.155)
No. of insertion (1/2)	56/4	58/2	0.679	
No. of cannulation (1/2/3)	56/2/2	50/5/5	0.233	

Table 4 Duration of catheterisation in successful cases

Duration (s)	Group D	Group N	P value
Localisation	6.92±4.21	8.44±6.59	0.150
Insertion	13.67±17.01	10.35±13.03	0.254
Cannulation	26.19±19.16	35.68±18.72	0.010
Overall	46.78±27.09	54.47±23.79	0.117

There was no statistical difference in the incidence of complications between the two groups (6.7% in group D, 8.3% in group N, p=1.000).

Subgroup analysis of cannulation time in 110 successfully catheterised patients is described in the online supplemental table S2.

There are some limitations to this study. We focused on the effect of wrist dorsiflexion by using a 5 cm cotton fabric roll. The effect of different wrist angles on radial artery catheterisation using DNTP still requires further investigation. The groups were similar although the neutral group had a slightly greater depth of the radial artery; however, cannulation time was similar for both low and high BMI patients. Most of the enrolled patients were in relatively good physical status (ASA-PS I and II). The result may not be extrapolated to patients with very severe medical conditions.

In conclusion, wrist dorsiflexion did not affect first-attempt success rate, overall success rate, overall catheterisation time or complication rate, but decreased cannulation time of ultrasound-guided radial artery catheterisation using DNTP technique in adult patients. Wrist dorsiflexion may not be a necessity for ultrasound-guided radial artery catheterisation using DNTP technique in adult patients.

Acknowledgements The authors would like to thank Dr. Dongdong Yao and Dr. Xiaoke Huang for their kind support in performing the clinical trial, Dr. Jianjun Zhang and Dr. Caixia Liu for statistical consultation.

Contributors QX designed the study and wrote the first draft of the paper. QX and DX collected and analyzed the data. SZ provided technical guidance. All authors revised the paper.

Funding This work was supported by the Shantou City Science and Technology Plan Project, Guangdong Province, China (Grant Number: 2016–11).

Competing interests None declared.

Patient consent for publication Not required.

Provenance and peer review Not commissioned; externally peer reviewed.

Data availability statement Data are available upon reasonable request.

Supplemental material This content has been supplied by the author(s). It has not been vetted by BMJ Publishing Group Limited (BMJ) and may not have been peer-reviewed. Any opinions or recommendations discussed are solely those of the author(s) and are not endorsed by BMJ. BMJ disclaims all liability and responsibility arising from any reliance placed on the content. Where the content includes any translated material, BMJ does not warrant the accuracy and reliability of the translations (including but not limited to local regulations, clinical guidelines, terminology, drug names and drug dosages), and is not responsible for any error and/or omissions arising from translation and adaptation or otherwise.

Open access This is an open access article distributed in accordance with the Creative Commons Attribution Non Commercial (CC BY-NC 4.0) license, which permits others to distribute, remix, adapt, build upon this work non-commercially, and license their derivative works on different terms, provided the original work is properly cited, appropriate credit is given, any changes made indicated, and the use is non-commercial. See: <http://creativecommons.org/licenses/by-nc/4.0/>.

ORCID iD

Qingyu Xiao <http://orcid.org/0000-0002-0475-2416>

REFERENCES

- 1 Abdalla UEM, Elmaadawey A, Kandeel A. Oblique approach for ultrasound-guided radial artery catheterization vs transverse and longitudinal approaches, a randomized trial. *J Clin Anesth* 2017;36:98–101.

- 2 Clemmesen L, Knudsen L, Sloth E, *et al.* Dynamic needle tip positioning - ultrasound guidance for peripheral vascular access. A randomized, controlled and blinded study in phantoms performed by ultrasound novices. *Ultraschall Med* 2012;33:E321–5.
- 3 Becky S, Atilio B, Shahar B, *et al.* Cardiovascular monitoring. In: Miller RD, ed. *Miller's Anesthesia*. 8th ed. Philadelphia, PA: Churchill Livingstone Inc, 2015: p.1350.
- 4 Kucuk A, Yalcin F, Yuce HH, *et al.* Forty-five degree wrist elevation is optimal for ultrasonography guided long axis radial artery cannulation both for young and elderly subjects. *Acta Medica Mediterr* 2013;29:291–4.
- 5 Sloth E, Gopalasingam N, Obad DS, *et al.* Dynamic needle tip positioning-para vessel approach. *Paediatr Anaesth* 2016;26:459–60.
- 6 Aydoğan H, Kucuk A, Boyacı FN, *et al.* Optimal wrist position for long and short axis ultrasound guided radial artery cannulation. *Clin Ter* 2013;164:e253–7.
- 7 Liu C, Mao Z, Kang H, *et al.* Comparison between the long-axis/in-plane and short-axis/out-of-plane approaches for ultrasound-guided vascular catheterization: an updated meta-analysis and trial sequential analysis. *Ther Clin Risk Manag* 2018;14:331–40.
- 8 Kiberenge RK, Ueda K, Rosauer B. Ultrasound-Guided dynamic needle tip positioning technique versus palpation technique for radial arterial cannulation in adult surgical patients: a randomized controlled trial. *Anesth Analg* 2018;126:120–6.
- 9 Moon K-W, Kim J-H, Yoo K-D, *et al.* Evaluation of radial artery atherosclerosis by intravascular ultrasound. *Angiology* 2013;64:73–9.
- 10 Selvaraj V, Buhari FS. Ultrasound evaluation of effect of different degree of wrist extension on radial artery dimension at the wrist joint. *Ann Card Anaesth* 2016;19:63–7.
- 11 Li X, Fang G, Yang D, *et al.* Ultrasonic technology improves radial artery puncture and cannulation in intensive care unit (ICU) shock patients. *Med Sci Monit* 2016;22:2409–16.