

## Clinical Study

# Facing Contrast-Enhancing Gliomas: Perfusion MRI in Grade III and Grade IV Gliomas according to Tumor Area

**Anna Luisa Di Stefano,<sup>1,2</sup> Niels Bergsland,<sup>3</sup> Giulia Berzero,<sup>1,4</sup> Lisa Farina,<sup>5</sup>  
Elisa Rognone,<sup>5</sup> Matteo Gastaldi,<sup>6</sup> Domenico Aquino,<sup>7</sup> Alessandro Frati,<sup>8</sup>  
Francesco Tomasello,<sup>9</sup> Mauro Ceroni,<sup>2,6</sup> Enrico Marchioni,<sup>1</sup> and Stefano Bastianello<sup>2,5</sup>**

<sup>1</sup> Neuro-Oncology Unit, C. Mondino National Neurological Institute, 27100 Pavia, Italy

<sup>2</sup> Department of Brain and Behavioral Sciences, University of Pavia, 27100 Pavia, Italy

<sup>3</sup> Magnetic Resonance Laboratory, IRCCS Don Gnocchi Foundation, 20148 Milan, Italy

<sup>4</sup> Neuroscience Consortium, University of Pavia, Monza Policlinico and Pavia Mondino, 27100 Pavia, Italy

<sup>5</sup> Neuroradiological Department, C. Mondino National Neurological Institute, 27100 Pavia, Italy

<sup>6</sup> General Neurology Unit, C. Mondino National Neurological Institute, 27100 Pavia, Italy

<sup>7</sup> Department of Neuroradiology, IRCCS Foundation Neurological Institute C. Besta, 20133 Milan, Italy

<sup>8</sup> Department of Neurosurgery, IRCCS Neuromed, Pozzilli (IS), University of Rome La Sapienza, 00185 Rome, Italy

<sup>9</sup> Department of Neurosurgery, University of Messina, 98122 Messina, Italy

Correspondence should be addressed to Anna Luisa Di Stefano; [annaluisadistefano@gmail.com](mailto:annaluisadistefano@gmail.com)

Received 14 February 2014; Accepted 6 March 2014; Published 3 April 2014

Academic Editor: Lombardi Giuseppe

Copyright © 2014 Anna Luisa Di Stefano et al. This is an open access article distributed under the Creative Commons Attribution License, which permits unrestricted use, distribution, and reproduction in any medium, provided the original work is properly cited.

Tumoral neoangiogenesis characterizes high grade gliomas. Relative Cerebral Blood Volume (rCBV), calculated with Dynamic Susceptibility Contrast (DSC) Perfusion-Weighted Imaging (PWI), allows for the estimation of vascular density over the tumor bed. The aim of the study was to characterize putative tumoral neoangiogenesis via the study of maximal rCBV with a Region of Interest (ROI) approach in three tumor areas—the contrast-enhancing area, the nonenhancing tumor, and the high perfusion area on CBV map—in patients affected by contrast-enhancing glioma (grades III and IV). Twenty-one patients were included: 15 were affected by grade IV and 6 by grade III glioma. Maximal rCBV values for each patient were averaged according to glioma grade. Although rCBV from contrast-enhancement and from nonenhancing tumor areas was higher in grade IV glioma than in grade III (5.58 and 2.68; 3.01 and 2.2, resp.), the differences were not significant. Instead, rCBV recorded in the high perfusion area on CBV map, independently of tumor compartment, was significantly higher in grade IV glioma than in grade III (7.51 versus 3.78,  $P = 0.036$ ). In conclusion, neoangiogenesis encompasses different tumor compartments and CBV maps appear capable of best characterizing the degree of neovascularization. Facing contrast-enhancing brain tumors, areas of high perfusion on CBV maps should be considered as the reference areas to be targeted for glioma grading.

## 1. Introduction

Gliomas are the most common brain primary neoplasms and are classified based on histologic parameters including atypia, vascular endothelial proliferation, necrosis, and mitosis [1, 2]. A common histopathological characteristic for both grade III and grade IV glioma is vascular endothelial proliferation, which is known to correspond to blood brain barrier disruption and tumoral neoangiogenesis [3, 4] as

evidenced by contrast-enhancement observed using conventional Magnetic Resonance Imaging (MRI). Although neuro-radiological necrosis is a hallmark of glioblastoma (GBM; grade IV glioma), it is not a constant finding. Therefore it can be difficult to distinguish between grade III and grade IV gliomas using conventional MRI.

Dynamic Susceptibility Contrast (DSC) Perfusion-Weighted Imaging (PWI) measures concentration of a paramagnetic contrast material in the organ, providing reliable information

on blood flow and vascularization. Among other perfusion parameters such as Cerebral Blood Flow (CBF) and Mean Transit Time (MTT), Cerebral Blood Volume (CBV) was shown to best correlate with tumoral neoangiogenesis and subsequently glioma grading. In particular, Relative Cerebral Blood Volume (rCBV), reflecting increased capillary density, was shown to be significantly higher in high grade gliomas (grade III and grade IV gliomas) than low grade gliomas (grade II glioma) and with higher values in grade IV [5].

Although rCBV increase is recognized as a surrogate marker of malignancy [6–8], differentiation between grade III and grade IV glioma is not consistently reproducible [8–11].

Furthermore, rCBV increases in glioblastoma multiforme (GBM) peritumoral area [10] and the peculiar pattern of rCBV increase surrounding glioblastoma contrast-enhancing tumor bed [12, 13] raises the question of where measuring rCBV values may best distinguish between grade III and grade IV gliomas.

In this study we investigated rCBV differences in patients with grade III and grade IV glioma using a Region of Interest (ROI-) based method in three different tumor areas: the contrast-enhancing area, the nonenhancing tumor, and the high perfusion area on CBV map.

The aim of the study was to determine which tumor compartments showed rCBV differences related to glioma grade.

## 2. Materials and Methods

We examined perfusion MRI from 21 patients affected by histologically proven high grade gliomas: fifteen patients were affected by grade IV glioma and 6 patients by grade III glioma.

Twelve patients underwent a DSC perfusion examination before surgery and 9 with residual tumor were examined after surgery after a median of 6.8 months. All patients undergoing perfusion after surgery had residual tumor and were not in progression at the time of DSC perfusion examination. All patients in this study were affected by primary disease and in particular grade IV glioma patients were all affected by primary GBM.

Demographical characteristics of patients are detailed in Table 1. Glioma grading was assessed by an experienced neuropathologist according to WHO criteria 2007 [2]. The study was approved by the local Institutional Review Board and all patients provided informed consent.

All participants were scanned using a 1.5T Philips Intera Gyroscan (Philips Medical System, Best, The Netherlands) with a maximum slew rate of  $150 \text{ Tm}^{-1} \text{ s}^{-1}$  and a maximum gradient amplitude of  $30 \text{ mT/m}$ . All scans were performed using an 8-channel SENSE (sensitivity encoding parallel imaging) head coil.

The scanning protocol included the following.

An axial 2D spin-echo (SE) T2-weighted Fluid Attenuated Inversion Recovery (FLAIR) image: echo time (TE)/repetition time (TR)/inversion time (TI) = 140/11000/2800 ms, flip angle (FA) =  $90^\circ$ , echo train length (ETL) = 50, acquisition matrix =  $256 \times 188$ , FOV =  $250 \text{ mm}^2$  (for an in-plane resolution of  $0.9 \text{ mm} \times 1.3 \text{ mm}$ ), slice thickness = 5 mm, gap =

TABLE 1: Patients' clinical data and tumor diagnosis.

WHO glioma grade	Number of patients	Age (years) (median, range)	Sex ratio (male/female)
III	6	49 (24–66)	6.0
IV	15	63 (23–80)	1.5

1 mm, number of excitations (NEX) = 2, and number of slices = 24.

An axial 2D SE T1-weighted image: TE/TR = 15/649.5 ms, FA =  $90^\circ$ , ETL = 1, acquisition matrix =  $260 \times 209$ , FOV =  $250 \text{ mm}^2$  (in-plane resolution of  $0.9 \text{ mm} \times 1.2 \text{ mm}$ ), slice thickness = 5 mm, gap = 1 mm, NEX = 2, and number of slices = 24.

An axial 3D perfusion weighted gradient echo (GRE) sequence (Principles of Echo Shifting with a Train of Observations, PRESTO) for Dynamic Susceptibility Contrast MRI: TE/TR = 8/16.72 ms (effective T2 = 23.71 ms), FA =  $7^\circ$ , ETL = 7, acquisition matrix =  $64 \times 64$ , FOV =  $220 \text{ mm}^2$  (in-plane resolution of  $3.44 \text{ mm} \times 3.44 \text{ mm}$ ), slice thickness = 3 mm, NEX = 1, and number of slices = 30 with 40 temporal localizations. This sequence was acquired with a standard dose of 0.2 mmol/Kg body weight of gadopentetate dimeglumine (Gd-DTPA) contrast agent (Gadovist) which was injected at a rate of 4 mL/s, followed by a 20 mL continuous saline flush. Using a 0.05 mmol/Kg dose, presaturation of the baseline signal prior to the PWI acquisition was done to reduce T1-effects as well as potential contrast leakage effects due to blood brain barrier disruption.

An axial 3D T1-weighted fast field echo (FFE) sequence after the PWI: TE/TR = 4.6/25 ms, FA =  $30^\circ$ , ETL = 1, acquisition matrix =  $256 \times 256$ , FOV =  $250 \text{ mm}^2$  (in-plane resolution of  $0.98 \text{ mm} \times 0.98 \text{ mm}$ ), slice thickness = 1.6 mm, gap = 0, NEX = 1, and number of slices = 170.

Postprocessing was performed using Olea Medical PerfScape software (version 2.0). The DSC acquisition was corrected for patient motion using the built-in feature of PerfScape. The T1 SE, FLAIR, and T1 3D FFE images were then coregistered and resampled into the space of the DSC MRI. It is well known that disruption of the blood brain barrier, as is common in high grade tumors, can lead to inaccurate measures of CBV [14]. As such, the correction for leakage effects option in PerfScape was employed.

Relative CBV (rCBV) was calculated from three separate ROIs that were placed in three different compartments: the area of contrast-enhancement, the nonenhancing tumor, and high perfusion area seen on the CBV color overlay maps. In the contrast-enhancement area, necrosis was excluded from CBV measure. The nonenhancing surrounding tumor ROIs corresponded to areas of T2/FLAIR hyperintensity outside contrast-enhancement. We ensured that T2/FLAIR ROIs were not placed in areas of contrast-enhancement as all images were coregistered. Placement of ROIs on the CBV map was performed in high perfusion areas independently of the contrast-enhancement and T2/FLAIR ROI locations.

Morphology and size of the ROIs were constant (elliptical- $40 \text{ mm}^2$  area) and the maximum value was recorded for each compartment according to Law et al. [15].

TABLE 2: Mean rCBV values according to histological grading. Relative Cerebral Blood Volume (rCBV) was measured with the ROI-based approach in three distinct areas: the high perfusion area on CBV map (“CBV map” in the table), the contrast-enhanced area (“CE” in the table), and the nonenhancing tumor (“Non-CE” in the table). Only rCBV values measured in the high perfusion area in CBV map showed significant difference between grade III and grade IV gliomas.

WHO glioma grade	CBV map	P	rCBV; mean (SD)			
			CE	P	Non-CE	P
Glioma grade III	3.78 (1.70)	<b>0.036</b>	3.01 (1.02)	0.27	2.20 (1.73)	0.71
Glioma grade IV	7.51 (3.84)		5.58 (5.48)		2.68 (2.93)	

All values were normalized to a corresponding ROI placed in contralateral normal brain parenchyma. All ROIs were placed by two operators (A.D, N.B.) via consensus. Maximal rCBV values for each patient were averaged according to glioma grade.

Differences between grades and tumor areas were tested using *t*-test. ANOVA was used in order to compare rCBV values in different subgroups of patients. Contingency analysis was performed by Fisher’s exact test. In all analyses we considered a *P* value of 0.05 (two-sided) as being statistically significant.

### 3. Results

Twelve patients underwent a DSC perfusion examination before surgery (3 patients affected by grade III glioma and 9 patients affected by grade IV glioma) and 9 patients with residual tumor were examined after surgery after a median of 6.8 months (3 patients affected by grade III glioma and 6 by grade IV glioma). Distribution of patients according to the timing of perfusion MRI (presurgery versus postsurgery) was not significantly different between grade III glioma and grade IV (*P* = 0.67).

In the grade III glioma subgroup, 2 patients were affected by anaplastic oligodendroglioma and 4 patients by anaplastic astrocytoma; in the grade IV glioma subgroup all patients were affected by glioblastoma.

Mean rCBV values from patients are detailed in Table 2. In the grade III glioma subgroup, mean rCBV was higher in the contrast-enhanced area than nonenhancing tumor (3.01 and 2.20, resp., *P* = 0.11); rCBV recorded in CBV map, independently of tumor compartment as seen on conventional MRI, was 3.78.

In glioma grade IV, mean rCBV was higher in contrast-enhanced area than nonenhancing tumor (5.58 and 2.68, resp., *P* = 0.04); the mean rCBV recorded in the CBV map was 7.51.

Between glioma grade III and glioma grade IV, no significant differences in rCBV were observed in the contrast-enhancement area and in the nonenhancing tumor (*P* = 0.27 and 0.71, resp.). Inversely, mean rCBV was significantly higher in grade IV gliomas than in grade III (*P* = 0.036) in the high perfusion area of CBV map independently of tumor compartment, as seen on conventional MRI (Figure 1).

### 4. Discussion

Neovascular proliferation is a hallmark of malignant gliomas and PWI is useful in glioma grading through detection

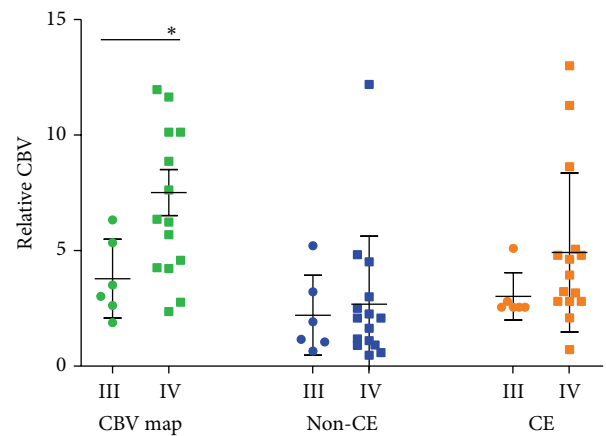


FIGURE 1: Scatter-plot diagram representing rCBV values according to grade and tumor area. Circles represent grade III, squares grade IV. Green color represents rCBV values measured in CBV map; blue color represents rCBV values measured in the nonenhancing tumor (Non-CE); orange color represents rCBV values measured in enhancing area (CE). Lines correspond to mean value and error bars to standard error of the mean. Only rCBV values measured in the high perfusion area in CBV map showed significant difference between grade III and grade IV gliomas.

of vascular density and of the grade of tumor-associated neovascularization [7, 16].

The measure of rCBV is commonly used in order to predict glioma grade or to differentiate radionecrosis from tumor recurrence in a diagnostic setting. Several reports on rCBV increases in peritumoral area of glioblastoma [10, 13] have suggested that there is a mismatch between the extension of effective vascular proliferation and area of contrast-enhancement.

In this work we mapped rCBV maximal increase in two different compartments of glioma grade III and glioma grade IV—the contrast-enhancing area and nonenhancing tumor with a ROI-based method. rCBV was also recorded in high perfusion area of CBV map independently of corresponding tumor area on conventional MRI.

Values of rCBV recorded in this work are consistent with the other reports in the literature [6]. As expected we found a significantly higher rCBV in contrast-enhanced area than in nonenhancing tumor in the grade IV glioma subgroup.

Concerning rCBV differences according to the tumor grade, we did not find significant differences of rCBV values recorded in contrast-enhancing area or nonenhancing tumor between grades III and IV.

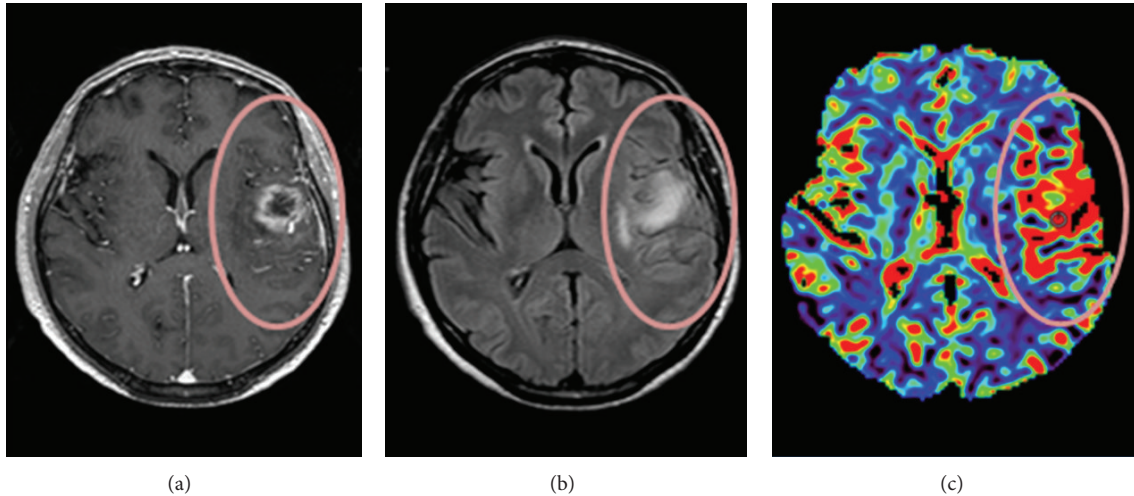


FIGURE 2: Axial coregistered contrast-enhanced axial T1-weighted image (a), FLAIR image (b), and CBV map (c) from a patient affected by glioma grade IV. In the CBV map (c) warmer colors indicate higher CBV values suggesting higher perfusion and neovascularization. Comparison of CBV map (c) and contrast-enhanced axial T1-weighted image highlights a mismatch area (surrounded by the circle) corresponding to the extension of the high perfusion area outside the contrast-enhancement: this indicates a more extensive neovascularization than that shown by conventional MRI (a, b).

Only measures of rCBV in the high perfusion area on the CBV map showed a significant difference between grade III glioma and grade IV, with higher values in grade IV.

Taken together, these results support the idea that neoangiogenesis heterogeneously encompasses both contrast-enhancing and nonenhancing tumor areas. The contrast-enhancing areas appear to reflect a higher degree of neoangiogenesis, although the difference with respect to nonenhancing areas was significant only in grade IV glioma subgroup.

Interestingly, we did not find significant differences in maximal rCBV in neither of these two areas when comparing grades III and IV. This suggests that basing rCBV measurements on signal characteristics of conventional MRI may not be sufficient to distinguish between grade III and grade IV gliomas.

Glioblastoma has been shown to present with a more heterogeneous neovascularization than grade III glioma [12]. In particular glioblastoma present, more so than with lower grades, areas with low perfusion due to necrosis, area of focal rCBV increase, and also increased rCBV values in peritumoral normal-appearing parenchyma [14, 17].

In particular, a special pattern of rCBV increase in peritumoral area can occur in a “stripe like” fashion which has been termed a “striate sign.” This feature has been described as mostly represented in glioblastoma rather than lower grade gliomas and in particular with respect to grade III glioma [12, 13]. The same authors showed that this specific pattern of rCBV in peritumoral area was significantly associated with normalized choline increase and with the subsequent appearance of contrast-enhancement in the same area [12, 13]. A similar example of mismatch between high perfusion area from CBV map and contrast-enhancement observed in our patients is shown in Figure 2. Histopathologically, these

patterns of rCBV may reflect diffuse migration of glioma cells along vascular channels of the white matter tracts spreading beyond the visible tumor border [18].

Taken together, these results support the hypothesis that only the rCBV map represents extensively the neovascular phenomena, its extension into apparently normal surrounding parenchyma, and its quantitative difference among glioma grades.

Limits of the study are the small sample size and potential sampling differences from the ROI-dependent method of measure which may increase interobserver variability. Nevertheless the latter is the most used in clinical routine. Additionally, all ROIs were placed in consensus by two authors. The fact that some patients were scanned before surgery and other patients afterwards presents an additional confound. However, we did not find any significant differences between the pre-/posttreatment groups (results not shown). Nevertheless, we cannot rule out the possibility that surgical intervention in some patients may have influenced the results.

In conclusion, maximal rCBV values measured directly on the CBV map seem to best characterize the extensive neoangiogenesis phenomena of high grade gliomas and quantitative difference of microvascular density between grade III and grade IV glioma. Such measurements should be considered as the reference map for glioma grading and potentially for serial measures of rCBV modification during antiangiogenic treatment.

### Conflict of Interests

The authors declare that there is no conflict of interests regarding the publication of this paper.

## Acknowledgments

The study was supported by a Grant of the National Ministry of University and Research, PRIN 2008 “2008979 M8 K.003.” The authors are grateful to OLEA Medical for providing OLEA PerfScape Software for postprocessing perfusion analysis. Dr. Di Stefano is supported by an investigator Fellowship from Collegio Ghislieri, Pavia, Italy.

## References

- [1] D. N. Louis, H. Ohgaki, O. D. Wiestler et al., “The 2007 WHO classification of tumours of the central nervous system,” *Acta Neuropathologica*, vol. 114, no. 2, pp. 97–109, 2007.
- [2] D. N. Louis, H. Ohgaki, O. D. Wiestler, and W. K. Cavenee, *WHO Classification of Tumours of the Central Nervous System*, IARC, Lyon, France, 2007.
- [3] R. Felix, W. Schorner, and M. Laniado, “Brain tumors: MR imaging with gadolinium-DTPA,” *Radiology*, vol. 156, no. 3, pp. 681–688, 1985.
- [4] B. L. Dean, B. P. Drayer, C. R. Bird et al., “Gliomas: classification with MR imaging,” *Radiology*, vol. 174, no. 2, pp. 411–415, 1990.
- [5] J. R. Petrella and J. M. Provenzale, “MR perfusion imaging of the brain: techniques and applications,” *American Journal of Roentgenology*, vol. 175, no. 1, pp. 207–219, 2000.
- [6] T. Sugahara, Y. Korogi, M. Kochi et al., “Correlation of MR imaging-determined cerebral blood volume maps with histologic and angiographic determination of vascularity of gliomas,” *American Journal of Roentgenology*, vol. 171, no. 6, pp. 1479–1486, 1998.
- [7] H. J. Aronen, F. S. Pardo, D. N. Kennedy et al., “High microvascular blood volume is associated with high glucose uptake and tumor angiogenesis in human gliomas,” *Clinical Cancer Research*, vol. 6, no. 6, pp. 2189–2200, 2000.
- [8] E. A. Knopp, S. Cha, G. Johnson et al., “Glial neoplasms: dynamic contrast-enhanced T2\*-weighted MR imaging,” *Radiology*, vol. 211, no. 3, pp. 791–798, 1999.
- [9] N. Fayed, J. Dávila, J. Medrano, and S. Olmos, “Malignancy assessment of brain tumours with magnetic resonance spectroscopy and dynamic susceptibility contrast MRI,” *European Journal of Radiology*, vol. 67, no. 3, pp. 427–433, 2008.
- [10] S. Cha, E. A. Knopp, G. Johnson, S. G. Wetzel, A. W. Litt, and D. Zagzag, “Intracranial mass lesions: dynamic contrast-enhanced susceptibility-weighted echo-planar perfusion MR imaging,” *Radiology*, vol. 223, no. 1, pp. 11–29, 2002.
- [11] R. Sanz-Requena, A. Revert-Ventura, L. Martí-Bonmatí, Á. Alberich-Bayarri, and G. García-Martí, “Quantitative MR perfusion parameters related to survival time in high-grade gliomas,” *European Radiology*, vol. 23, no. 12, pp. 3456–3465, 2013.
- [12] S. Blasel, K. Franz, M. Mittelbronn et al., “The striate sign: peritumoural perfusion pattern of infiltrative primary and recurrent gliomas,” *Neurosurgical Review*, vol. 33, no. 2, pp. 193–203, 2010.
- [13] S. Blasel, K. Franz, H. Ackermann, S. Weidauer, F. Zanella, and E. Hattingen, “Stripe-like increase of rCBV beyond the visible border of glioblastomas: site of tumor infiltration growing after neurosurgery,” *Journal of Neuro-Oncology*, vol. 103, no. 3, pp. 575–584, 2011.
- [14] J. L. Boxerman, K. M. Schmainda, and R. M. Weisskoff, “Relative cerebral blood volume maps corrected for contrast agent extravasation significantly correlate with glioma tumor grade, whereas uncorrected maps do not,” *American Journal of Neuroradiology*, vol. 27, no. 4, pp. 859–867, 2006.
- [15] M. Law, R. J. Young, J. S. Babb et al., “Gliomas: predicting time to progression or survival with cerebral blood volume measurements at dynamic susceptibility-weighted contrast-enhanced perfusion MR imaging,” *Radiology*, vol. 247, no. 2, pp. 490–498, 2008.
- [16] B. R. Rosen, J. W. Belliveau, J. M. Vevea, and T. J. Brady, “Perfusion imaging with NMR contrast agents,” *Magnetic Resonance in Medicine*, vol. 14, no. 2, pp. 249–265, 1990.
- [17] I. C. Chiang, Y. T. Kuo, C. Y. Lu et al., “Distinction between high-grade gliomas and solitary metastases using peritumoral 3-T magnetic resonance spectroscopy, diffusion, and perfusion imaging,” *Neuroradiology*, vol. 46, no. 8, pp. 619–627, 2004.
- [18] P. J. Kelly, C. Daumas-Duport, and D. B. Kispert, “Imaging-based stereotaxic serial biopsies in untreated intracranial glial neoplasms,” *Journal of Neurosurgery*, vol. 66, no. 6, pp. 865–874, 1987.