



## Case report

## Thymoma-associated T-cell immunodeficiency after radiotherapy: A case report

Kensuke Nakagawara<sup>a</sup>, Shotaro Chubachi<sup>a,\*</sup>, Shuhei Azekawa<sup>a</sup>, Shiro Otake<sup>a</sup>, Ayaka Saito<sup>a</sup>, Masahiko Okada<sup>a</sup>, Ko Lee<sup>a</sup>, Katsunori Masaki<sup>a</sup>, Naoyoshi Koike<sup>b</sup>, Hirofumi Kamata<sup>a</sup>, Ichiro Kawada<sup>a</sup>, Shigeaki Suzuki<sup>c</sup>, Makoto Ishii<sup>a</sup>, Koichi Fukunaga<sup>a</sup>

<sup>a</sup> Division of Pulmonary Medicine, Department of Medicine, Keio University School of Medicine, Tokyo, Japan

<sup>b</sup> Department of Radiology, Keio University School of Medicine, Tokyo, Japan

<sup>c</sup> Division of Neurology Medicine, Department of Medicine, Keio University School of Medicine, Tokyo, Japan

## ARTICLE INFO

## Keywords:

Thymoma  
T-cell immunodeficiency  
Myasthenia gravis  
Radiotherapy  
Oral candidiasis  
Pneumonias

## ABSTRACT

Acquired immunodeficiency in thymoma (Good's syndrome) without hypogammaglobulinemia is a rare condition. Here we describe the case of a 29-year-old Japanese woman with thymoma-associated T cell immunodeficiency after radiation therapy. She was admitted to the hospital with refractory pneumonia, which resulted from as T cell immunodeficiency, as revealed through low peripheral lymphocytes and oral candidiasis triggered through radiotherapy and required long-term antimicrobial therapy. Although radiotherapy is commonly administered for thymoma, our findings suggest that physicians should consider carrying out lymphocyte counts during thymoma treatment.

## 1. Introduction

Thymoma, originating from epithelial cells, is a rare thymus tumor and is typically treated through surgical resection, and metastatic tumors and lesions may be treated through chemotherapy or radiation therapy. The tumor is often associated with various autoimmune diseases including myasthenia gravis, pure red cell aplasia, and acquired immunodeficiency, which are affected by tumor progression and treatment. Good's syndrome is a typical thymoma-associated humoral and cellular immunodeficiency with hypogammaglobulinemia and confers opportunistic infections. In this case report, we report a case of intractable pneumonia with T-cell immunodeficiency resulting from radiotherapy for thymoma.

## 2. Case presentation

A 29-year-old woman presented with fever and productive cough at our hospital. She had undergone thymectomy for thymoma 9 years ago and had comorbid myasthenia gravis, pure red cell aplasia, and autoimmune hepatitis. She was prescribed immunosuppressants including cyclosporine (200 mg/d) and prednisolone (5 mg/d). Radiotherapy was initiated for a recurrent thymoma lesion 2 weeks before her admission

delivered to a total dose of 54 Gy in 27 fractions (Fig. 1). Her bone marrow was an area spared from radiation therapy.

Pneumococcal pneumonia episode in the previous months were remarkable in her medical history. Her chest examination revealed bilateral coarse crackles and rhonchi. Laboratory examination revealed leukocytosis with a left shift and elevated C-reactive protein. Hypogammaglobulinemia, fungal antigens, and Mycobacterium tuberculosis infection were unremarkable on the interferon-gamma release assay and anti-HIV antibodies. Chest computed tomography (CT) revealed infiltrations and a granular shadow in the bilateral lobes (Fig. 2A). She was diagnosed with broncho-pneumonia and hospitalized.

After admission, a 14-d course of piperacillin-tazobactam was initiated for broncho-pneumonia, and her symptoms and laboratory findings improved. However, after switching from piperacillin-tazobactam to an oral antimicrobial (levofloxacin), pneumonia reexacerbated (Fig. 2B).

Therefore, piperacillin-tazobactam treatment was resumed and pneumonia was under control again; however, drug fever and granulocytopenia caused by piperacillin-tazobactam was observed and hence cefepime was administered as an alternative. However, severe drug eruptions were observed 4 d after switching to cefepime, and drug eruption exacerbated even after a switch to meropenem. Therefore, antimicrobial treatment was discontinued. Antimicrobial therapy with

\* Corresponding author. Division of Pulmonary Medicine, Department of Medicine, Keio University School of Medicine, Tokyo, 160-8582, Japan.

E-mail address: [bachibachi472000@live.jp](mailto:bachibachi472000@live.jp) (S. Chubachi).

<https://doi.org/10.1016/j.rmcr.2021.101408>

Received 22 February 2021; Received in revised form 14 March 2021; Accepted 24 March 2021

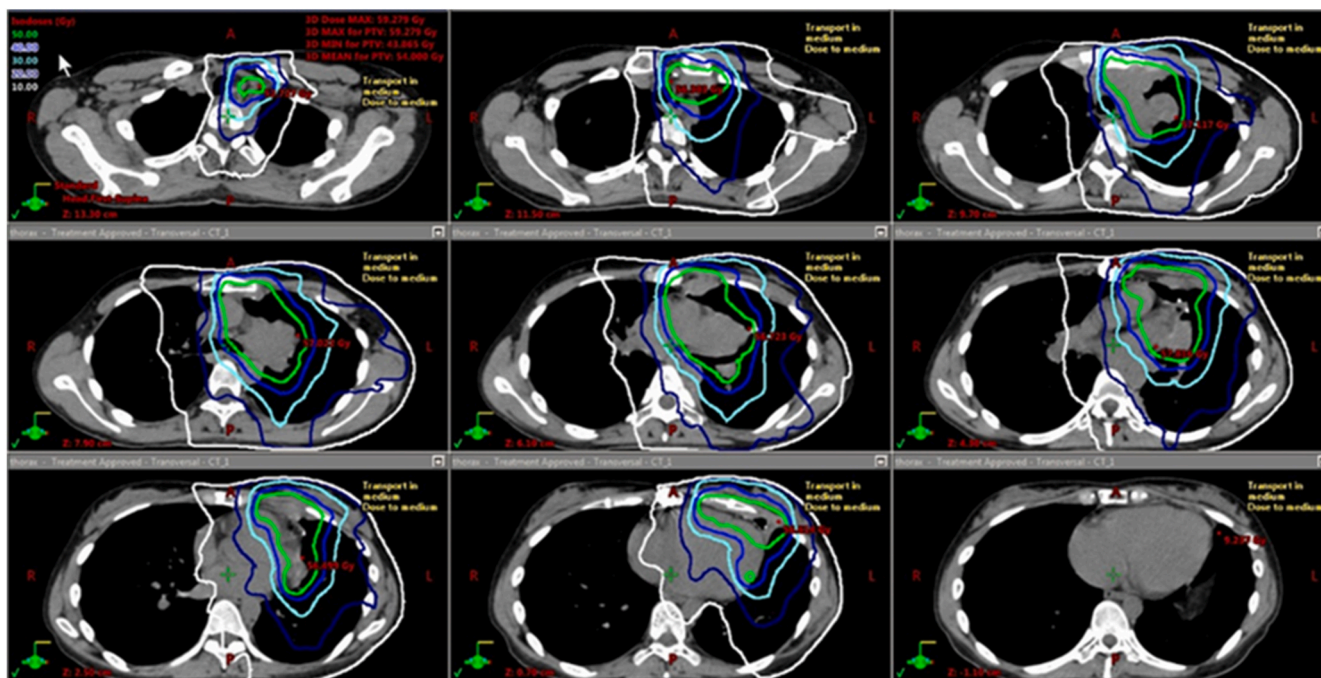
Available online 2 April 2021

2213-0071/© 2021 The Authors.

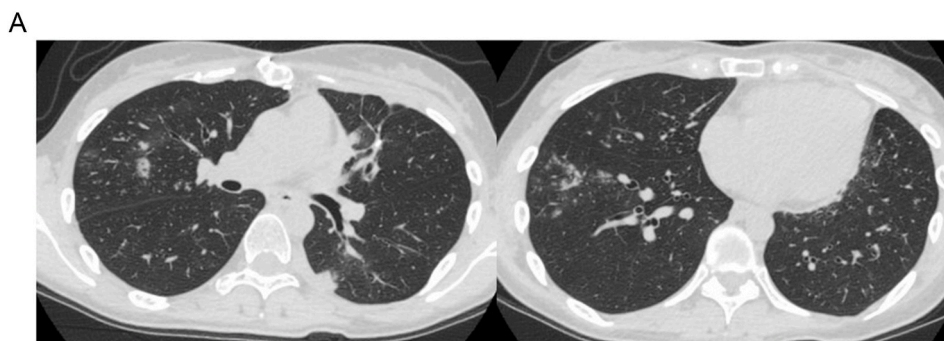
Published by Elsevier Ltd.

This is an open access article under the CC BY-NC-ND license

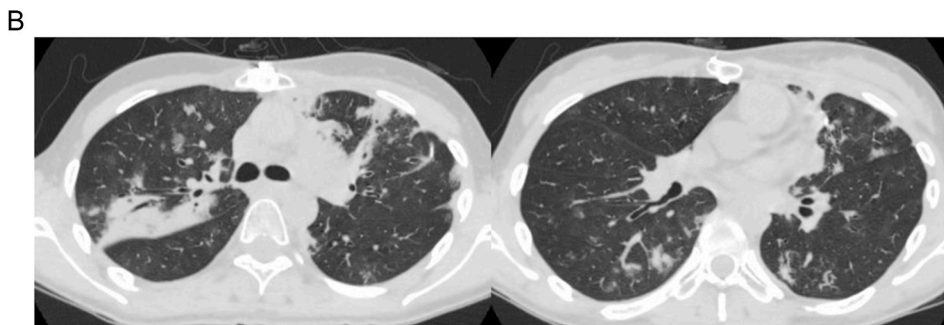
(<http://creativecommons.org/licenses/by-nc-nd/4.0/>).



**Fig. 1.** Dose distribution map of the radiation against the relapsed thymoma. She received Volumetric Modulated Arc Therapy for a recurrent thymoma lesion with left pleural dissemination, avoiding her bone marrow; isodose line of radiation treatment. The green line represents 50 Gy, the light blue line represents 30 Gy, and the white line represents 10 Gy. (For interpretation of the references to colour in this figure legend, the reader is referred to the Web version of this article.)



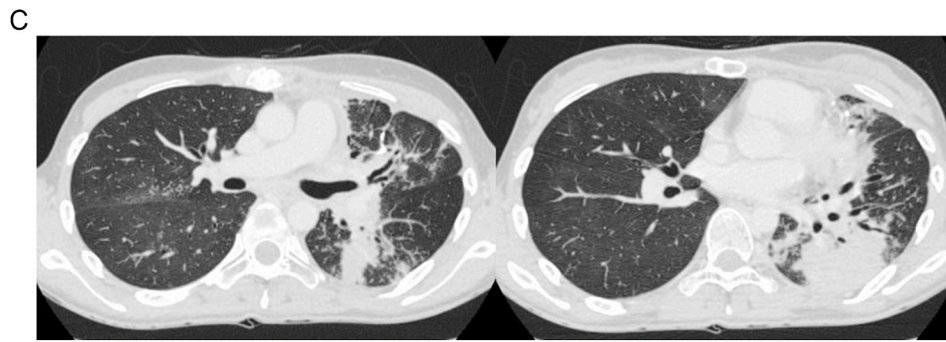
**Fig. 2A.** Chest computed tomographic images upon hospitalization. Chest computed tomography revealed centrilobular granular and infiltrative shadows and thickening of the bronchial wall in bilateral lung fields.



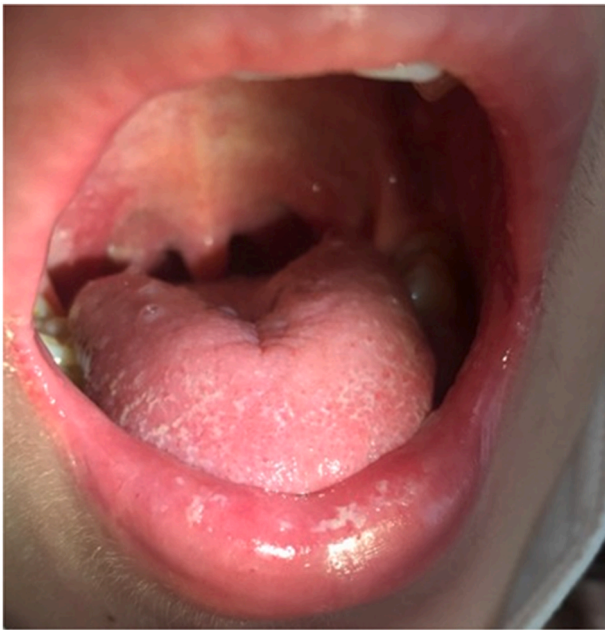**Fig. 2B.** Chest computed tomographic images upon pneumonia exacerbation. The centrilobular granular and infiltrative shadows were re-exacerbated and extensive infiltrative shadows were observed around the bronchi in the right upper lobe.

cefepime, piperacillin-tazobactam, and meropenem were administered for 21 d. Drug eruption improved with no treatment after discontinuation of antimicrobial therapy. Immunodeficiency was suspected as the

cause of recurrent lower respiratory tract infections because peripheral CD4-positive cells were reduced to 284  $\mu\text{L}$ , and lymphocytopenia ( $<1,000/\mu\text{L}$ ) occurred after radiation therapy for recurrent thymoma.



**Fig. 2C.** Chest computed tomographic images on the third onset of pneumonia. Consolidation of the right upper lobe improved, and a novel extensive infiltrative shadow was observed from the upper region to the basilar region of the left lower lobe.



**Fig. 3.** Candidiasis in the oral cavity and oropharynx with comorbid lymphocytopenia.

Hypogammaglobulinemia was not observed; nonetheless, immunoglobulin was administered at 5,000 mg once daily for three consecutive days for severe infection. Furthermore, cyclosporine was gradually tapered to 100 mg/d after admission to control pneumonia. After discontinuation of antimicrobial therapy, fever recurred and the oxygen demand increased, and CT revealed new consolidation in her lower lobe of the left lung (Fig. 2C).

For the third treatment cycle for pneumonia, a combination of vancomycin and doripenem, plus immunoglobulin, was initiated, because methicillin-resistant *Staphylococcus aureus* (MRSA) and *Pseudomonas fluorescens* were detected in sputum cultures after hospitalization. Despite intensive treatment, no improvement in the oxygen demand and fever was observed. Since the patient had pneumonia refractory to broad-spectrum antimicrobial agents, pneumonia caused by agents other than bacterial was suspected as the cause of the respiratory failure and pneumonia findings on chest CT. Simultaneously, candidiasis was noted in the oral cavity (Fig. 3), and the decline in CD4-positive cells suggested T-cell immunodeficiency.

Furthermore, based on elevated serum  $\beta$ -D glucan levels and a positive PCR test for *Pneumocystis jirovecii* in sputum samples, *P. jirovecii* pneumonia was diagnosed as a cause of respiratory failure. Along with antimicrobial treatment, sulfamethoxazole (3,600 mg/d) and

trimethoprim (720 mg/d) were initiated, and prednisolone was administered at 80 mg/d. Respiratory failure improved rapidly, and the infiltrative shadow on chest X-ray was obliterated. Prednisolone was tapered to a maintenance dose over 2 weeks, and anti-biotherapy and sulfamethoxazole/trimethoprim were administered for 3 weeks each and completed. During hospitalization, the peripheral lymphocyte count was elevated to almost 2,000/ $\mu$ L, and she was discharged on hospitalization day 99 without pneumonia recurrence after treatment for *P. jirovecii* pneumonia. Her clinical course after admission is described in Fig. 4. During her hospitalization, her gammaglobulin levels remained within the normal range, while her peripheral lymphocyte counts tended to slowly increase.

### 3. Discussion

Here we report the case of a woman with recurrent lower respiratory tract inflammation after radiation therapy for recurrent thymoma. She experienced three recurring episodes of pneumonia a few months immediately after radiotherapy. In each case, chest CT revealed infiltrative and centrilobular granular shadows at different sites, suggesting the involvement of systemic immunodeficiency in the background. Comorbid oral candidiasis and reduction of peripheral blood lymphocytes and CD4-positive cells further evidenced her condition. T-cell immunodeficiency associated with lymphocyte depletion was speculated to be the cause of the refractory pneumonia. Furthermore, the recurrence of lower respiratory infections was under control owing to elevated absolute lymphocyte counts during the clinical course (Fig. 4).

Immunosuppressive medications such as prednisone and cyclosporine were suspected as the cause of T-cell immunodeficiency, whereas the patient had been taking these drugs for almost one year before she was hospitalized, and pneumonia, which had developed 2 months before radiation therapy, had been in remission upon 3 weeks of antimicrobial treatment despite taking immunosuppressants (prednisone 5mg/d and cyclosporine 200 mg/d). Her peripheral blood lymphocytes were markedly reduced before and after radiation therapy (Fig. 5). Additionally, in this case, the intractable pneumonia developed after the radiotherapy. Therefore, the radiotherapy-induced T-cell immunodeficiency may have played a more important role in the development of the refractory pneumonia than the immunosuppressive medications.

Good's syndrome with hypogammaglobulinemia, low or absent B-cells in peripheral blood, and various defects in cell-mediated immunity, is an immunodeficiency reportedly associated with thymoma [1,2]. The treatment for Good's syndrome initially involves resection of the thymic tumor, followed by immunoglobulin replacement [3]. However, in this case, T-cell immunodeficiency was suggested to result from lymphocytes, including CD4-positive cells without hypogammaglobulinemia and the development of oral candidiasis and *Pneumocystis* pneumonia.

A few cases of T-cell immunodeficiency after radiotherapy for



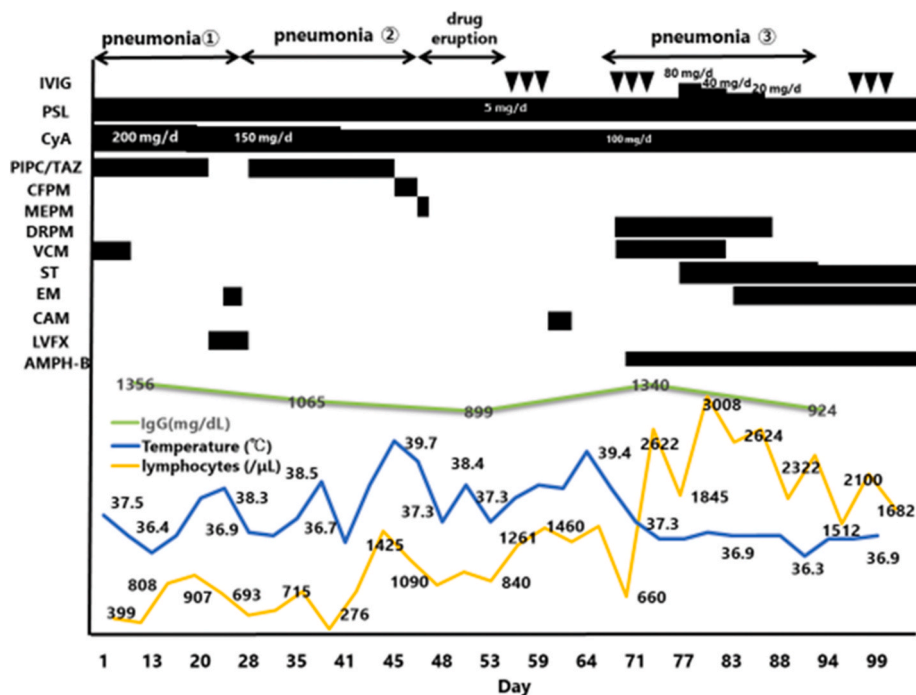


Fig. 4. Clinical course of the patient, assessed in accordance with gammaglobulin levels, fever type, and peripheral lymphocyte counts.

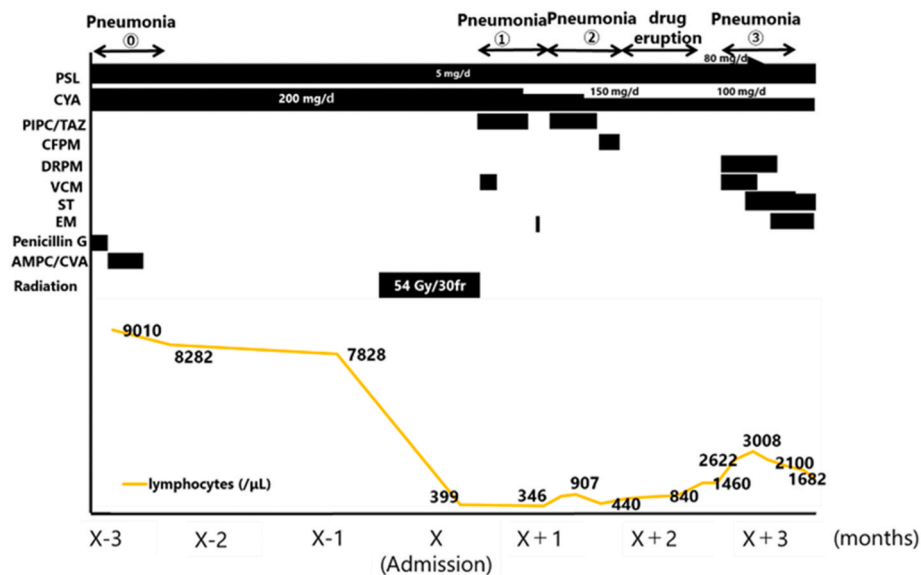


Fig. 5. Absolute lymphocyte count over a 7-month period.

thymoma have been previously reported [4,5]. Each case was similar to the present case, in that the lymphocyte count, including that of CD4-positive cells, was reduced, and systemic infections developed after radiotherapy. This case is different from previously reported cases in that we could identify a markedly reduced number of lymphocytes after irradiation. While it took years for the lymphocyte count to increase in these previously reported cases, it improved within a few months in the present case, suggesting that the period required for lymphocyte recovery after radiotherapy differs in each case.

Radiation therapy is a common treatment method for thymoma and generally does not cause immunodeficiency [6,7] because the bone marrow is generally not targeted during radiation therapy to prevent inducing a loss of hematopoietic capacity. We focused on pre-radiation an increase in lymphocytes in this case. Therefore, the monoclonal

thymoma-derived lymphocytes and polyclonal mature lymphocytes might have increased. Peripheral lymphocytosis is a characteristic finding in cases of thymoma-associated T-cell immunodeficiency [8]. Thymectomy for lymphocyte-rich and hematopoietic thymoma reportedly induces a marked reduction in the peripheral T-cell population. In patients presenting minimal thymopoiesis, minor effects on T-cell concentration have been observed [9]. In this case, cell-mediated immunity, further corroborated through thymoma-derived lymphocytosis before radiotherapy, might have been disrupted through lymphocyte depletion due to radiotherapy, resulting in the manifestation of background cellular immunodeficiency. The findings from the present case study suggest that clinicians should consider carrying out peripheral lymphocyte counts before and after radiation therapy for thymoma and consider the possibility of the development of T-cell immunodeficiency.

#### 4. Conclusion

We reported a case of refractory pneumonia associated with T-cell immunodeficiency after radiation therapy for thymoma. Clinicians need to be aware of the cell-mediated immunity of patients after radiotherapy for thymoma.

#### Funding

This report did not receive any specific grant from funding agencies in the public, commercial, or not-for-profit sectors.

#### Author's contribution

All of the authors ensure to task force for preparing the manuscript and approved the final version of the manuscript. All authors contributed to the clinical care for the patient in specialized settings.

#### Consent for publication

Written consent was obtained from the patient for publication of this case report and for use of accompanying images.

#### Submission declaration and verification

The present study was not published or is not currently submitted to any other journal.

#### Declaration of competing interest

None of the authors has any conflicts of interest or any financial ties to disclose.

#### Acknowledgments

We would like to thank Editage ([www.editage.jp](http://www.editage.jp)) for English language editing.

#### References

- [1] A.M. Masci, G. Palmieri, L. Vitiello, et al., Clonal expansion of CD8+ BV8 T lymphocytes in bone marrow characterizes thymoma-associated B lymphopenia, *Blood* 101 (8) (2003) 3106–3108.
- [2] M. Di Renzo, A. Pasqui, F. Bruni, et al., Thymoma and immunodeficiency, *N. Z. Med. J.* 117 (1188) (2004). U750.
- [3] P. Kelleher, S.A. Misbah, What is Good's syndrome? Immunological abnormalities in patients with thymoma, *J. Clin. Pathol.* 56 (1) (2003) 12–16.
- [4] J.L. Wickemeyer, S. Sekhsaria, Prolonged severe immunodeficiency following thymectomy and radiation: a case report, *J. Med. Case Rep.* 8 (2014) 457.
- [5] T. Kawamura, T. Naito, H. Kobayashi, et al., Acquired immunodeficiency associated with thymoma: a case report, *BMC Canc.* 19 (1) (2019) 762.
- [6] A.T. Berman, L. Litzky, V. Livolsi, et al., Adjuvant radiotherapy for completely resected stage 2 thymoma, *Cancer* 117 (15) (2011) 3502–3508.
- [7] M. Hetnał, K. Malecki, M. Wolanin, S. Korzeniowski, T. Walasek, Thymoma: results of treatment and role of radiotherapy, *Rep. Practical Oncol. Radiother.* 15 (1) (2010) 15–20.
- [8] P. Christopoulos, P. Fisch, Acquired T-cell immunodeficiency in thymoma, *Crit. Rev. Immunol.* 36 (4) (2016) 315–327.
- [9] G. Sempowski, J. Thomasch, M. Gooding, et al., Effect of thymectomy on human peripheral blood T cell pools in myasthenia gravis, *J. Immunol.* 166 (4) (2001) 2808–2817.