

Acute Bleeding In Duodenal Gastrointestinal Stromal Tumor

Marjan Mokhtare¹, Tarang Taghvaei^{2*}, Hafez Tirgar Fakheri³

1. GI Fellow, Department of Gastroenterology, Mazandaran University of Medical Sciences, Sari, Mazandaran, Iran
2. Assistant Professor, Department of Gastroenterology, Mazandaran University of Medical Sciences, Sari, Mazandaran, Iran
3. Professor, Department of Gastroenterology, Mazandaran University of Medical Sciences, Sari, Mazandaran, Iran

ABSTRACT

Gastrointestinal stromal tumors (GIST) are the most common mesenchymal tumors of the gastrointestinal tract. The biological pattern of these tumors ranges from benign-appearing small lesions to malignant sarcomas. Only 3%–5% of GISTs are found in the duodenum. A duodenal GIST is a rare source of upper gastrointestinal bleeding. A remarkable percentage of duodenal GISTs are localized in the third and fourth part of the duodenum and may not be noticed on standard upper endoscopy. Push enteroscopy is sometimes advisable to find these lesions. Surgical resection either limited or pancreaticoduodenectomy can be the treatment of choice. In general, adjuvant therapy with imatinib has been proved to extend survival in patients with GIST.

The current case, a 24-year-old male, presented with acute upper gastrointestinal bleeding from a submucosal ulcerated tumor located in the distal third part of the duodenum, 3 cm distal from the papilla of Vater. After primary care and blood transfusion in a local hospital, partial resection of the duodenum was performed as a definitive surgical therapy. Histopathology showed a GIST with a diameter of 3 cm and moderately malignant according to tumor grade, and <5 mitoses/10 high power field (HPF).

KEYWORDS

Gastrointestinal; Acute Bleeding; Stromal Tumor

Please cite this paper as:

Mokhtare M, Taghvaei T, Tirgar Fakheri H. Acute Bleeding In Duodenal Gastrointestinal Stromal Tumor. *Middle East J Dig Dis* 2013;5:47-51.

INTRODUCTION

Gastrointestinal stromal tumors (GISTs) are the leading type of mesenchymal tumors of the gastrointestinal tract. Forty to sixty percent of the tumors are found in the stomach, 30%-40% in the small intestine, 5% in the colon and rectum, and 5% in the esophagus.¹⁻⁶ Duodenal GISTs comprise a small subset, accounting for 12%-18% of tumors in the small intestine and 1%-4% of all GISTs. Complete surgical resection could still be the best choice in the treatment of GISTs though imatinib mesylate, a tyrosine kinase inhibitor may affect c-Kit positive tumors advantageously.^{2,7} All GISTs are potentially malignant even they may have a benign appearance, both gross and microscopically. The rate of recurrence and metastases is predicted by estimating the tumor diameter and the mitotic ratio.⁸ Because of the potential for malignancy, surgical management is the principal

* Corresponding Author:

Tarang Taghvaei, MD
Sari, Razi Street, Imam Khomeini
Hospital
Tel: + 98 151 2261700
Fax: + 98 1512263754
Email: tarang_taghvaei@yahoo.com
Received: 22 Oct. 2012
Accepted: 05 Dec. 2012

method in the therapy of localized GISTs. An en-bloc resection is advisable whenever possible.⁹ GISTs do not extensively penetrate at the microscopic level and seldom metastasize to the lymph nodes, unlike carcinomas. As a result, local excision might be more suitable when technically possible. A tumor found in the second portion of the duodenum is a difficult clinical entity because of its proximity to major anatomical structures, such as the duodenal papilla, pancreas, and the biliary and pancreatic ducts.²⁻⁵ If these structures are involved a pancreaticoduodenectomy must be performed.^{5,6} Although some argue that a pancreaticoduodenectomy provides better oncological control, others suggest the selective use of a partial resection of the duodenum in order to decrease operative morbidity and mortality.⁹

We report a case of duodenal GIST, located 3 cm distal to the papilla of Vater, who was successfully treated by a partial resection of the duodenum.

CASE REPORT

A 24-year-old male had no history of previous medical problem, but complained of acute upper gastrointestinal bleeding (hematemesis). A submucosal tumor located about 3 cm distal to the papilla of Vater was found by endoscopy. The lesion bulged beneath the mucosa with a central depressed ulceration, which was the origin of the massive bleeding. Following blood transfusion the bleeding spontaneously stopped (Figure 1).

Magnetic resonance imaging (MRI) was remarkable for a homogenous tumor of the duodenum (Figure 2). MRI and CT scans showed no metastases. The patient experienced another episode of bleeding for which a blood transfusion was performed due to a decreased hemoglobin level to 4g/dl. Fortunately the bleeding stopped again. Endoscopic ultrasonography showed a 12x10mm hypoechoic lesion that originated from the muscularis layer without any regional lymphadenopathy. The patient was diagnosed to have a duodenal GIST (Figure 3). Surgery was recommended and a laparotomy was done. The submucosal tumor was located in the distal third portion

of the duodenum, about 3 cm distal to the ampulla of Vater. No penetration of the pancreas or other adjacent organs was detected and there were no suspicious lymph nodes. The tumor was managed by a partial resection of the distal third and fourth portion of the duodenum with a 1cm safe margin on each side and an end-to-end anastomosis. His postoperative course passed without any problem and the patient was discharged on the fifth day after the operation. The diameter of the operated tumor was 3 cm (Figure 4,5). Histopathology showed a GIST with a typical spindle tumor cell structure (Figure 6). The overlying duodenal mucosa was ulcerated. The tumor had a thin fibrous capsule that reached the muscularis mucosae, but did not penetrate it. The tumor had a moderately malignant potential according to tumor grading and the excised margin was tumor-free. Immunohistochemistry was strongly positive for C- KIT and CD34 and DOG-1 and KI67 (the pathologic tumor mitotic labeling index which expression has positive correlation to tumor size) =8%, while desmin, smooth muscle, HH8, EMA and beta-catenin were negative. Mitotic activity was less than 5 mitoses/10 high power fields (Figure 7). No formal lymph node dissection was done, and as it was expected no lymph nodes were noticed in the resected specimen. The tumor diameter and low proliferative activity revealed a low risk for malignancy.

DISCUSSION

GISTs are commonly low grade mesenchymal tumors of the gastrointestinal tract considered to arise from pluripotent mesenchymal stem cells that have been categorized to differentiate into interstitial cells of Cajal.^{1,2,5} GISTs can arise for any tissue with Cajal cells including the stomach, small intestine, colon, rectum, omentum, oral cavity, biliary tree, and liver.⁵

The epidemiology of GISTs cannot be completely estimated. The average age of patients with GISTs is 53 years and only 5% are under the age of 30. Less than 4% of all GISTs are duodenal, therefore they show a rare tumor entity.^{1,2} Duodenal GISTs commonly involve the second part of the duodenum followed by the third, fourth, and first parts.¹

Duodenal GISTs are relatively small in size. The median size of the lesion is reported to be 4 cm in contrast to the median size of gastric and small intestinal GISTs of 6

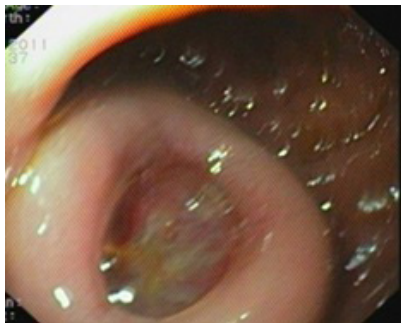


Fig.1:The lesion bulged under mucosa with a central depressed ulceration in endoscopic view

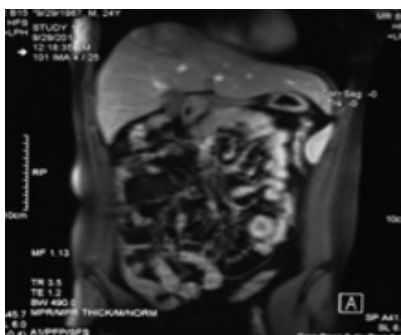


Fig.2: MRI was remarkable for a homogenous tumor of the duodenum

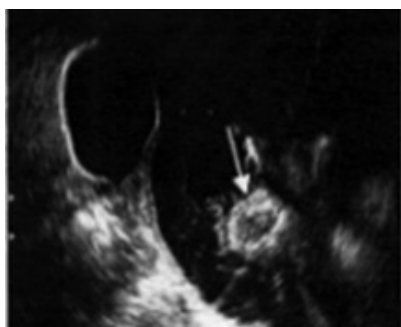


Fig.3: EUS showed a 12x10mm hypochoic lesion that originated from the muscularis layer without any regional lymphadenopathy

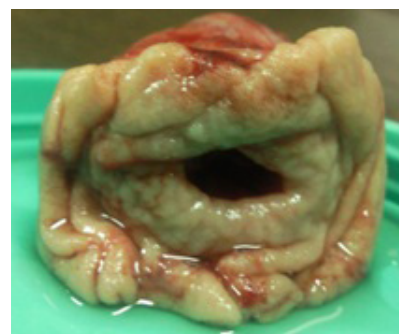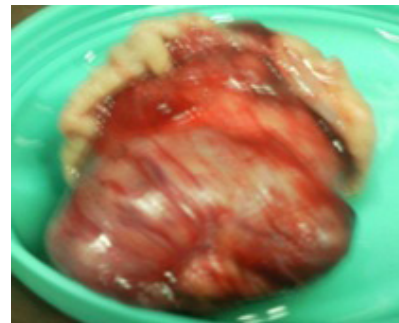


Fig.4,5: Gross appearance of surgical specimen

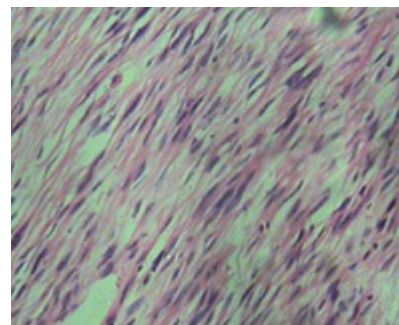


Fig.6: Histopathology showed a GIST with a typical spindle tumor cell structure

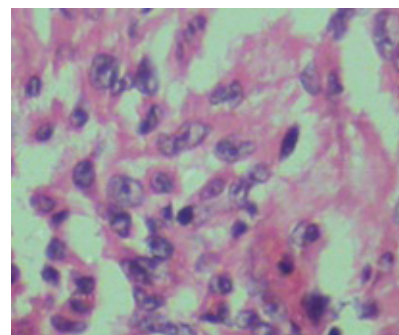


Fig.7: Mitotic activity was less than 5 mitoses/ 10 high power field

to 7 cm, respectively.^{1,5} Duodenal GISTs that are detected earlier when they are smaller are amenable to relatively minor resection or excisional surgery.¹⁻⁶ They may also have a favorable prognosis in comparison to GISTs from other sites of the gastrointestinal tract.^{1,2,4,6}

The clinical presentation of duodenal GISTs is extremely varied regarding their size, location and the presence of mucosal ulceration; and as a result the patients complained of gastrointestinal bleeding, epigastric pain,

obstructive jaundice, the presence of a palpable mass, and intestinal obstruction.¹⁻⁶

Persistent, significant bleeding, as in our patient, is unusual.^{2,4,5,6} While duodenoscopy could be enough in detecting these tumors, some problems may arise when the tumor is relatively small in diameter with very non-significant outward expansion or the lack of an ulcerated umbilication.^{2,4,6} In such conditions endoscopic ultrasound is highly helpful in determining whether the lesion is submucosal or arises from an intramural or extramural structure; it can also be performed to clarify the layer of origin of the intramural lesion.¹⁰

CT and MRI are the best imaging methods for estimating the primary lesion and finding the presence of metastasis. On CT scan, GISTs may be different from small homogenous to large necrotic masses. Small tumors are typically shown as distinctly demarcated smooth-walled homogenous soft tissue masses with moderate contrast enhancement. On the contrast, large tumors are likely to have central necrosis and cavitation in addition to heterogeneous enhancement.^{11,12}

Surgery is the treatment of choice for GISTs and sarcomas in general. It is the only option that provides definitive cure.¹³ Both radiotherapy and chemotherapy are only used as palliative measures in refractory cases. Selection of the type of surgical resection depends on primary tumor site and its growth pattern. Routine resection of lymph nodes is not recommended due to the low incidence of lymph node involvement. Laparoscopic management of stromal tumors is shown to be associated with recurrence rates. Laparoscopic results are comparable to open techniques for tumors smaller than 5cm.^{14,15} Total en bloc surgical resection of the tumor and surrounding tissue is reported to be successful in 50% to 90% of the cases.^{4,6} In some, resection may be advised for the relief of the local symptoms, most significantly bleeding.⁶

The choice of a surgical method depends on size, location and proximity to the duodenal papilla.^{1-6,16} For larger tumors that are located in the third and fourth portions of the duodenum, a segmental duodenectomy with side-to-end or end-to-end duodenojejunostomy may be done.¹⁷ Major resection through a pancreaticoduodenectomy or pancreatic sparing duodenectomy is advisable when the tumor is found in the second portion of the duodenum and involves the papilla, pancreas or the duodenal bulb, or if the common bile ducts tend to be smaller in diameter causing problem while reconstruction and an increased

chance of stenosis of the anastomosis after pancreaticoduodenectomy.^{1,2,6,16} In brief, wedge resection is advisable for small (<1 cm) GISTs of the duodenum if they are localized more than 2 cm from the ampulla of Vater. Segmental duodenectomy is advisable for large (>3 cm) tumors located in the third or fourth portions of the duodenum.⁶

Imatinib mesylate is used in the treatment of GISTs, either as neoadjuvant therapy or in patients with recurrent disease.^{7,18,19} A minority of the GISTs which contain kinase oncoproteins may be naturally resistant or respond weakly to imatinib mesylate.²⁰ Forty percent of patients with primary GISTs who had recurrent disease, were undergone complete resection. Most recurrences are either local or liver metastases that have a median follow up of 24 months.^{1,4} For duodenal GISTs, the recurrence-free survival rate at 1-,2-, and 3- years of follow-up following resection has been shown to be 94.2, 82.3, and 67.3%, respectively. The 1-,3-, and 5-year survival was 98.3, 87.4, and 82.0% respectively.²¹ In general five-year survival rate of patients after GIST resection varies from 30% to 80%.¹⁻⁶ The relapse rate for patients undergone surgery ranges from 5% in those with complete resections to 90% in patients with unresected or incompletely resected tumors.^{16,17,20,22} This obviously shows that duodenal GISTs are extremely different in their aggressiveness, from small indolent tumors to overt sarcomas.

Our patient had a successful tumor resection but he was non-compliant for taking imatinib. There was no recurrence during ten months of follow-up. However, his prognosis will be clearer after additional, prolonged follow-up.

CONFLICT OF INTEREST

The authors declare no conflict of interest related to this work.

REFERENCES

1. Miettinen M, Kopczynski J, Makhlof HR, Sarlomo-Rikala M, Gyorffy H, Burke A, et al. Gastrointestinal stromal tumours, intramural leiomyomas, and leiomyosarcomas in the duodenum. A clinicopathological, immunohistochemical and molecular genetic study of 167 cases. *Am J Surg Pathol* 2003;**27**:625-41.
2. Chung JC, Chu CW, Cho GS, Shin EJ, Lim CW, Kim HC, et al. Management and outcome of gastrointestinal

- stromal tumours of the duodenum. *J Gastrointest Surg* 2010;**14**:880-3.
3. Mennigen R, Wolters HH, Schulte B, Pelster FW. Segmental resection of the duodenum for gastrointestinal stromal tumour (GIST). *World J Surg Oncol* 2008;**6**:105.
 4. Gervaz P, Huber O, Morel P. Surgical management of gastrointestinal stromal tumours. *Br J Surg* 2009;**96**:567-78.
 5. Asakawa M, Sakamoto Y, Kajiwara T, Nara S, Esaki M, Shimada K, et al. Simple segmental resection of the second portion of the duodenum for the treatment of gastrointestinal stromal tumours. *Langenbecks Arch Surg* 2008;**393**:605-9.
 6. Bucher P, Egger JF, Gervaz P, Ris F, Weintraub D, Villiger P, et al. An audit of surgical management of gastrointestinal stromal tumours(GIST). *Eur J Surg Oncol* 2006;**32**:310-4.
 7. Cohen MH, Cortazar P, Justice R, Pazdur R. Approval summary: Imatinib mesylate in the adjuvant treatment of malignant gastrointestinal stromal tumor. *Oncologist* 2010;**15**:300-7.
 8. Nilsson B, Bümbling P, Meis-Kindblom JM, Odén A, Dor tok A, Gustavsson B, et al. Gastrointestinal stromal tumors: the incidence, prevalence, clinical course, and prognostication in the preimatinib mesylate era – a populationbased study in western Sweden. *Cancer* 2005;**103**:821-9.
 9. Goh BK, Chow PK, Kesavan S, Yap WM, Wong WK. Outcome after surgical treatment of suspected gastrointestinal stromal tumors involving the duodenum: is limited resection appropriate? *J Surg Oncol* 2008;**97**:388-91.
 10. Aydin A, Tekin F, Günşar F, Güler A, Tunçyürek M, Ilter T. Value of endoscopic ultrasonography for upper gastrointestinal stromal tumours. A single center experience. *Turk J Gastroenterol* 2004;**15**:233-7.
 11. Ghanem N, Althoefer C, Furtwängler A, Winterer J, Schäfer O, Springer O, et al. Computed tomography in gastrointestinal stromal tumour. *Eur Radiol* 2003;**13**:1669-78.
 12. Sandrasegaran K, Rajesh A, Rushing DA, Rydberg J, Akisik FM, Henley JD. Gastrointestinal stromal tumour. CT & MRI finding. *Eur Radiol* 2005;**15**:1407-14.
 13. Demetri GD, Benjamin RS, Blanke CD, Blay JY, Casali P, Choi H, et al. NCCN Task Force report: management of patients with gastrointestinal stromal tumor (GIST)update of the CCNclinical practice guidelines. *J Natl Compr Canc Netw* 2007;**5**:1-29.
 14. Iwahashi M, Takifuji K, Ojima T, Nakamura M, Nakamori M, Nakatani Y, et al. Surgical management of small gastrointestinal stromal tumors of the stomach. *World J Surg* 2006;**30**:28-35.
 15. Novitsky YW, Kercher KW, Sing RF, Heniford BT. Long-term outcomes of laparoscopic resection of gastric gastrointestinal stromal tumors. *Ann Surg* 2006;**243**:738-45; discussion 745-7.
 16. Blay JY, Bonvalot S, Casali P, Choi H, Debiec-Richter M, Dei Tos AP, et al. Consensus meeting for the management of gastrointestinal stromal tumour. Report of the GIST consensus conference of 20-21 march 2004 under the auspices of ESMO. *Ann Oncol* 2005;**16**:566-78.
 17. Goh BK, Chow PK, Ong HS, Wong WK. Gastrointestinal stromal tumour involving the second and third portion of the duodenum: treatment by partial duodenectomy and Roux-en-Y duodenojejunostomy. *J Surg Oncol* 2005;**91**:273-5.
 18. Pennacchioli E, Colombo C, Berselli M, Gronchi A. Update on management of GIST and post surgical use of imatinib. *Open Access Surgery* 2010;**3**:63-71.
 19. Demetri GD, van Mehren M, Blanke CD, Van den, Abbeele AD, Eisenberg B, et al. Efficacy and safety of imatinib mesylate in advanced gastrointestinal stromal tumours. *N Engl J Med* 2002;**347**:472-80.
 20. Mohiuddin K, Nizami S, Munir A, Memon B, Memon MA. Metastatic duodenal GIST: role of surgery combined with imatinib mesylate. *Int Semin Surg Oncol* 2007;**9**:1-6.
 21. Johnston F, Kneuert P, Cameron J, Sanford D, Fisher S, Turley R, et al. Presentation and Management of Gastrointestinal Stromal Tumors of the Duodenum: A Multi- Institutional Analysis. *Ann Surg Oncol* 2012;**19**:3351-60.
 22. Corless CL, Schroeder A, Griffich D, Town A, McGreevory L, Harrell P, et al. PDGFRA mutations in gastrointestinal stromal tumours: frequency, spectrum and in vitro sensitivity to imatinib. *J Clin Oncol* 2005;**23**:5357-64.